

Concise Review

Clin Shoulder Elbow 2024;27(3):386-395
<https://doi.org/10.5397/cise.2023.01032>

Basic to advanced elbow arthroscopy: the history, basic set up, and indications

Erica Kholinne¹, In-ho Jeon², Jae-Man Kwak³

¹Department of Orthopedic Surgery, St. Carolus Hospital, Faculty of Medicine, Universitas Trisakti, Jakarta, Indonesia

²Department of Orthopedic Surgery, Asan Medical Center, University of Ulsan College of Medicine, Seoul, Korea

³Department of Orthopedic Surgery, Uijeongbu Eulji Medical Center, Eulji University School of Medicine, Uijeongbu, Korea

Elbow arthroscopy presents challenges; however, its indications and advantages over traditional open surgery are swiftly evolving. Despite being less widely performed than on other joints such as the knee, shoulder, ankle, and hip, arthroscopic management of the elbow has potential. The goals of this review are to describe and broaden the current applications of elbow arthroscopy. Additionally, we will provide insights and strategies to enhance the effectiveness of elbow arthroscopy.

Keywords: Elbow; Arthroscopy; Epicondylitis; Synovitis; Arthritis

INTRODUCTION

Elbow arthroscopy is performed less frequently than arthroscopy for other joints such as the shoulder and knee. This is mainly due to the limited indications for elbow arthroscopy, infrequency of elbow pathologies requiring this surgical approach, and the technical complexity associated with arthroscopy on the elbow joint. Complications are more common in elbow arthroscopy (6% minor, 1% major complications) than in arthroscopies of other joints [1]. The risk of neurovascular injury is heightened in elbow arthroscopy due to the presence and proximity of neurovascular structures to the joint and the portals used for the procedure. The purpose of this review paper is to enable orthopedic surgeons initiating elbow arthroscopy to approach it more safely and easily.

HISTORY AND ADVANCEMENTS

The history of elbow arthroscopy can be traced back to 1931,

when Michael Burman conducted the inaugural procedure at New York University's anatomy laboratory [2]. Despite early challenges, subsequent innovations, including the introduction of smaller arthroscopes in 1971, paved the way for successful procedures performed by surgeons like Ito [3] and Maeda [4]. Further advancements were made in 1985 by Andrews and Carson [5], who detailed techniques and indications for elbow arthroscopy. The initial reports indicated higher complication rates, but the 1970s and 1980s witnessed an increase in elbow arthroscopy due to improved instruments, enhanced understanding of arthroscopic anatomy, and novel techniques, resulting in increased safety.

Initially serving diagnostic and loose fragment removal purposes, the concept of arthroscopic elbow procedures originated with Burman and gained wider acceptance through studies by Lynch et al. [6], Andrews and Carson [5], and Poehling et al. [7]. As diagnostic elbow arthroscopy gained traction, it progressively delved into more complex pathologies through surgical interven-

Received: November 18, 2023 Revised: January 4, 2024 Accepted: January 11, 2024

Correspondence to: Jae-Man Kwak

Department of Orthopedic Surgery, Uijeongbu Eulji Medical Center, Eulji University School of Medicine, 712 Dongil-ro, Uijeongbu 11759, Korea
Tel: +82-31-951-1724, Fax: +82-31-951-1724, E-mail: jman.kwak@gmail.com, ORCID: <https://orcid.org/0000-0002-4395-8345>

© 2024 Korean Shoulder and Elbow Society.

This is an Open Access article distributed under the terms of the Creative Commons Attribution Non-Commercial License (<https://creativecommons.org/licenses/by-nc/4.0/>) which permits unrestricted non-commercial use, distribution, and reproduction in any medium, provided the original work is properly cited.

tion. Presently, elbow arthroscopy has become a standard approach for various conditions including debridement, drilling, autograft or allograft replacement for capitellar defects, repairing lateral epicondylitis, managing arthritis and ankyloses, and treating fractures involving the radial head, capitellum, and distal humerus. Different forms of elbow instability, such as varus, valgus, and posterolateral instability, necessitate diagnostic arthroscopy and debridement. Notably, varus and posterolateral rotatory instability can be addressed through arthroscopic repair or reconstruction. Other relevant indications encompass triceps tendon repair, olecranon bursitis debridement, removal of olecranon spurs, alleviating ulnar nerve constriction at the proximal cubital tunnel, addressing coronoid fractures, and managing partial tears of the distal biceps.

INDICATIONS AND CONTRAINDICATIONS

The likelihood of neurovascular damage during elbow arthroscopy is comparatively higher than in other joints due to the proximity of neurovascular structures to portals and the operating area. The suitability of elbow arthroscopy is optimal when the surgeon possesses arthroscopic expertise gained from training or experience with other joints. For certain patients, previous surgical intervention around the elbow could be a factor that discourages elbow arthroscopy. While a prior subcutaneous transposition of the ulnar nerve does not necessarily rule out elbow arthroscopy, the feasibility depends on identification of the ulnar nerve [8]. On the other hand, preceding submuscular or intramuscular ulnar nerve transposition is generally considered un-

suitable. Certain conditions or situations might not be addressed effectively using arthroscopy and could be better suited for an open procedure, such as advanced joint destruction in arthritis. Reconstruction of the medial ulnar collateral ligament, as well as the removal and repair of medial epicondylitis accompanied by irritation of the ulnar nerve (type 2 medial epicondylitis), should be carried out using an open approach after initial diagnostic arthroscopy due to the proximity of the ulnar nerve. While arthroscopic ulnar nerve decompression just proximal to the medial epicondyle can be performed skillfully, patients experiencing ulnar nerve compression in the distal section of the cubital tunnel where the nerve enters the flexor carpi ulnaris are better suited for open decompression. Indications and contraindications of elbow arthroscopy are outlined in Table 1 [9-14].

Currently, any indication for elbow surgery can also serve as a potential indication for arthroscopic or arthroscopically assisted management, subject to anatomical compatibility. Often, the procedure can be more effectively carried out using arthroscopy than through an open approach. There exist certain procedures that have traditionally been performed using an open method but that can, in experienced hands, be safely conducted arthroscopically [15]. We believe that the decision between arthroscopic and open elbow surgery depends more on the experience of the surgeon than on the patient's specific condition. As a result, the indications outlined in this review will be categorized based on surgeon expertise rather than solely on the pathological aspect, providing a general guideline for when a surgeon's proficiency allows progression to a higher level of skill in elbow arthroscopy.

Table 1. Indications and contraindications of elbow arthroscopy [9-14]

Indication	Contraindication
1. Loose body removal	Relative
2. Synovectomy	1. Prior elbow surgery
3. Septic arthritis lavage and debridement	2. Previous elbow trauma
4. Contracture release	3. Previous subcutaneous transposition of the ulnar nerve
5. Lateral epicondylitis release	4. Severe posttraumatic/degenerative arthritis
6. Osteoarthritis - excision of the osteophyte	5. Ulnar nerve entrapment distal to elbow joint
7. Osteochondritis dissecans of the capitellum	Absolute
8. Radial head excision	1. Previous submuscular/intramuscular transposition of the ulnar nerve
9. Assisted reduction and fixation of fractures	
10. Posterior elbow impingement	
11. Posterolateral synovial plica syndrome	
12. Olecranon bursitis	
13. Elbow instability (LUCL repair, rare)	

LUCL: lateral ulnar collateral ligament.

PATIENT POSITIONING

An optimal setup for elbow arthroscopy should allow comprehensive access to the elbow from all angles and unrestricted elbow flexion during the surgical procedure. There are three commonly utilized positions for elbow arthroscopy. The use of a tourniquet is highly recommended as it aids greatly in providing a clear field of vision during elbow arthroscopy.

Supine Position

Initially introduced by Andrews and Carson [5], this positioning involves the patient lying flat with the shoulder abducted to 90°, the elbow flexed at a 90° angle, and the forearm suspended using finger straps over a pulley with attached weights, facilitating joint distraction (Fig. 1A). This arrangement offers rapid positioning, favorable airway access for anesthetists, and simplified orientation for the surgeon. However, it necessitates a dedicated assistant to stabilize the limb, and addressing the posterior compartment may be challenging. Alternatively, a pneumatic or mechanical arm holder can be employed to flex the shoulder to 90° and move the forearm across the chest. With the forearm suspended over the chest, the neurovascular structures shift anteriorly, enhancing portal placement safety. Due to the maneuverability of the arm, access to both compartments is unhindered, eliminating the need for an assistant to stabilize the limb. Additionally, the supine position facilitates conversion to an open procedure by dismantling the traction device and positioning the limb over the arm board, if required.

Lateral Decubitus Position

The lateral decubitus position, outlined by O'Driscoll and Morrey [16], entails the patient lying on their side, with the torso secured to the operating table and an axillary roll placed on the opposite side (Fig. 1B). The operated elbow is positioned on a padded bolster, the shoulder in internal rotation and flexion, and the elbow at a 90° flexion angle. Placing the bolster proximally over the arm allows unrestricted flexion. This position is preferred by the author due to its superior airway access compared to the prone position. A slight 20° tilt toward the operating surgeon may be beneficial in preventing compression of the antecubital fossa [17].

Prone Position

Introduced by Poehling et al. [7], the patient assumes a prone position with the chest supported by rolls at the table's edge. The shoulder is abducted to 90°, and the arm is positioned over the support to enable free elbow movement across a wide range of flexion (Fig. 1C). However, this position is less favored due to potential obstruction of airway access for anesthetists.

ARTHROSCOPY SET-UP AND EQUIPMENT

Elbow arthroscopy is feasible using a conventional 4-mm arthroscope equipped with a 30° angled lens. For specialized views, employing a 70° angled lens can be advantageous, particularly when aiming for a corner perspective. A 2.7-mm arthroscope

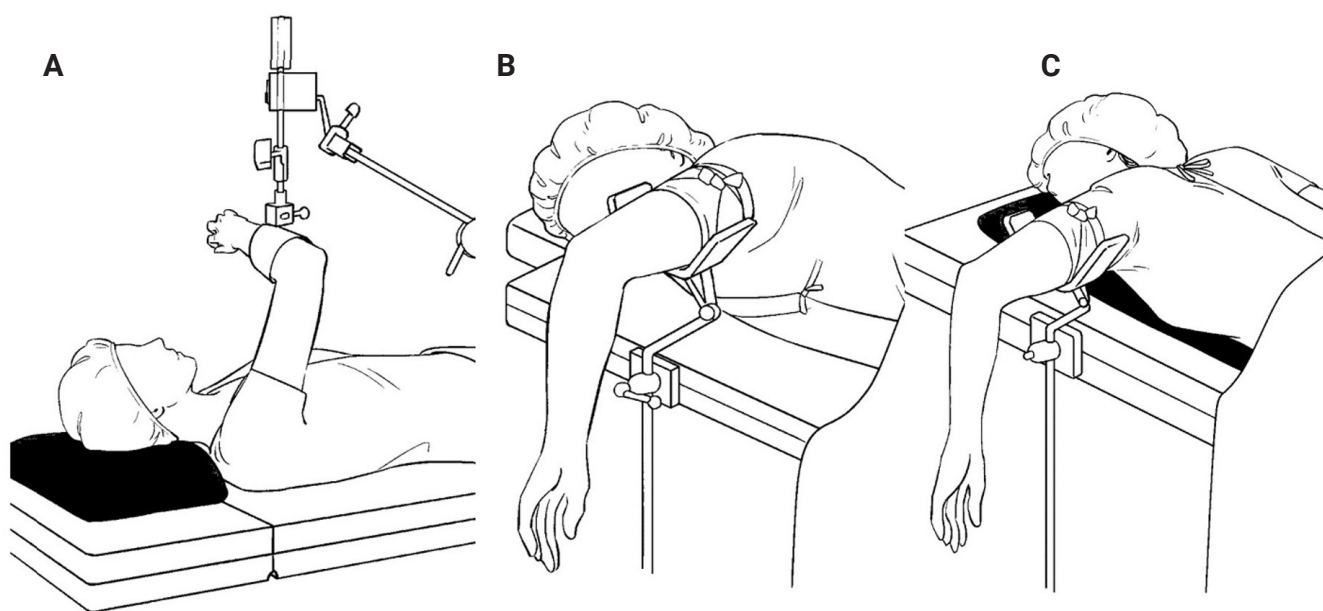


Fig. 1. Patient positioning: (A) supine, (B) lateral decubitus, (C) prone.

should be available, especially for smaller patients. Due to the relatively compact size of the elbow joint, an arthroscopy sheath devoid of side vents for inflow is recommended to maintain optimal visualization and control. To avert potential harm to articular cartilage upon insertion, blunt trocars are employed. Fluid pressure can be managed through gravity-driven inflow or, if a mechanical pump is utilized, it is advised to maintain pressure below 30 mmHg. Throughout the procedure, standard arthroscopic tools such as biters, graspers, burrs, and shavers are employed. The use of shaver suction tubing is generally avoided due to the residual negative pressure in the tubing, even when the suction is turned off. Retractor devices are utilized as necessary during the procedure.

Surgical Anatomy

In terms of arthroscopic visualization, the elbow joint can be categorized into two compartments: an anterior compartment and a posterior compartment. The sequence for visualizing the elbow joint depends on the location of the pathology rather than the surgeon's preference. Before initiating the procedure, it is advisable to establish preoperative anatomical markers, including bony landmarks (such as lateral and medial epicondyles, radial head, and olecranon tip), as well as the course of the ulnar nerve (Fig. 2).

To prevent fluid from extravasating to the forearm, an elastic bandage can be applied around the forearm, extending proximally to just below the elbow joint. The diagnostic observation procedure for the elbow unfolds as follows: Initially, around 15–25 mL of saline is injected *via* the soft spot, identifiable by palpation on the lateral side of the elbow (Fig. 3, Supplementary Video 1) [18]. A contracted elbow joint exhibits reduced compliance with

this volume, and exceeding it is associated with capsular rupture, potentially causing fluid leakage and increased pressure within the forearm compartments. Such capsular rupture may lead to compromised visualization due to capsule collapse. Elbow flexion increases the space between bone and neurovascular structures. While joint insufflation augments the distance between the joint and neurovascular structures, it does not alter the relationship between the capsule and neurovascular structures [6]. After joint distension, the viewing portal is established.

Joint distension is essential in creating a viewing portal as it reduces the risk of neurovascular injury. In elbow arthroscopy, understanding the relationship between the joint capsule and the neurovascular structures is crucial for safe and effective surgical intervention. The elbow's capsule is closely related to several important neurovascular structures including the brachial artery, the median nerve, the radial nerve, and the ulnar nerve. Due to

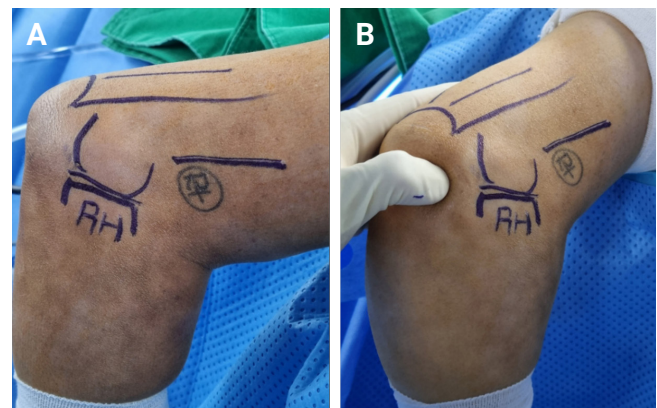


Fig. 3. (A, B) Soft spot can be placed one finger posterior from radiocapitellar joint line.

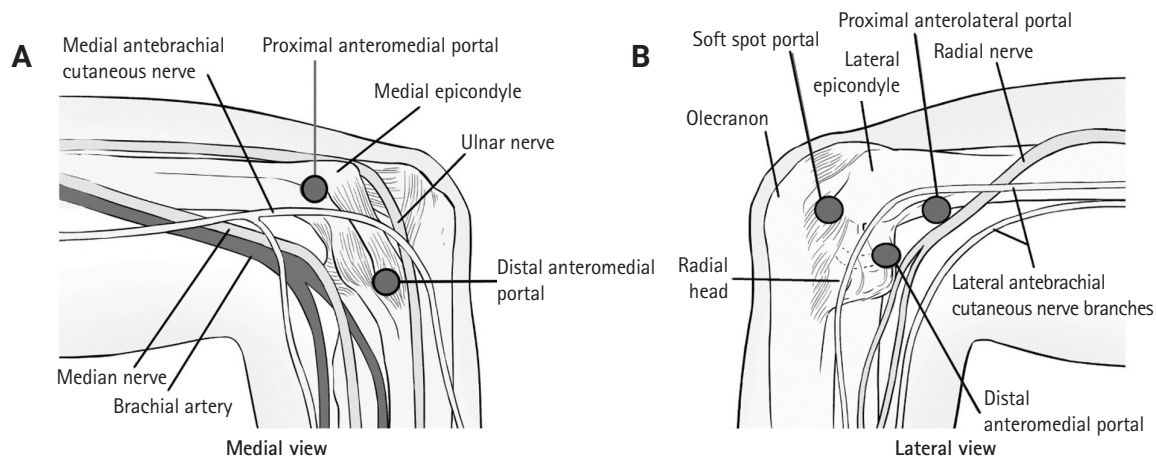


Fig. 2. Portal establishment with related surgical anatomy. (A) Medial view. (B) Lateral view.

their proximity, there is a risk of injury to these structures during arthroscopic procedures. The risk of neurovascular complications in elbow arthroscopy, while low, is significant due to the dense arrangement of these structures around the elbow. Surgeons must have a thorough knowledge of the anatomical layout to minimize the risk of injury.

Portal Establishment and Diagnostic Rounding

After achieving joint distention, portals are created for intra-articular visualization. Within the anterior elbow compartment, these portals encompass the proximal anteromedial portal (serving as the main viewing portal) (Figs. 4 and 5), the proximal anterolateral portal (Fig. 6), the anteromedial portal, and the anterolateral portal. Meanwhile, the posterior elbow compartment encompasses the soft spot portal (Fig. 3), the direct posterior portal (Fig. 7), and the posterolateral portal. (Table 2)

Proximal Anteromedial Portal

Introduced by Poehling et al. [7] and widely adopted, the proximal anteromedial portal serves as a prominent viewing point (Fig. 5). This portal provides visualization of the lateral compartment of the elbow, encompassing the radial head, capitellum, coronoid, lateral capsule, and gutter (Fig. 5). To establish this portal, placement is 2 cm proximal to the medial epicondyle and just anterior to the palpable medial intermuscular septum (Fig. 4). The blunt trocar sheath is then guided toward the radial head using the surgeon's index finger, maintaining contact with the bone to ensure safe clearance from the ulnar nerve. Given the portal's proximal location and near-parallel trajectory with the nerve, caution is exer-

cised to prevent any nerve interference. The creation of this portal poses a potential risk to the medial antebrachial cutaneous nerve.

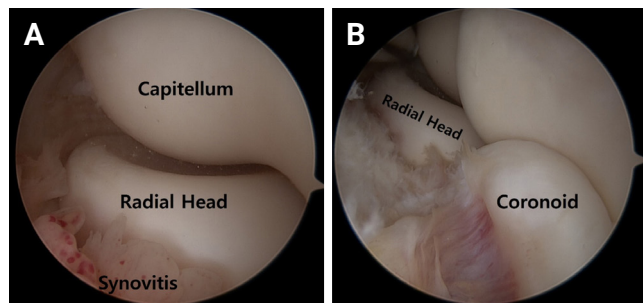


Fig. 5. (A) Typical viewing area using the proximal anteromedial portal. (B) Extended view of the coronoid.

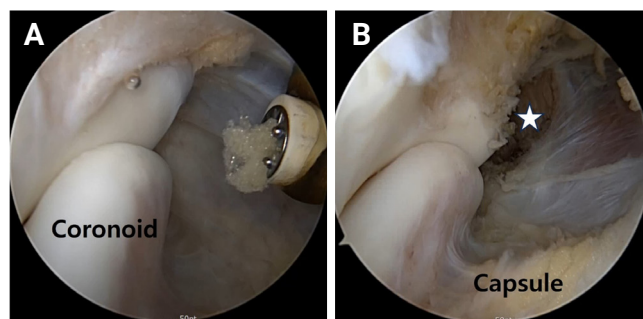


Fig. 6. Proximal anterolateral portal for visualization of the anteromedial compartment of the elbow (A), showing a released pathologic capsule and flexor tendon group in a case of medial epicondylitis (asterisk; B).

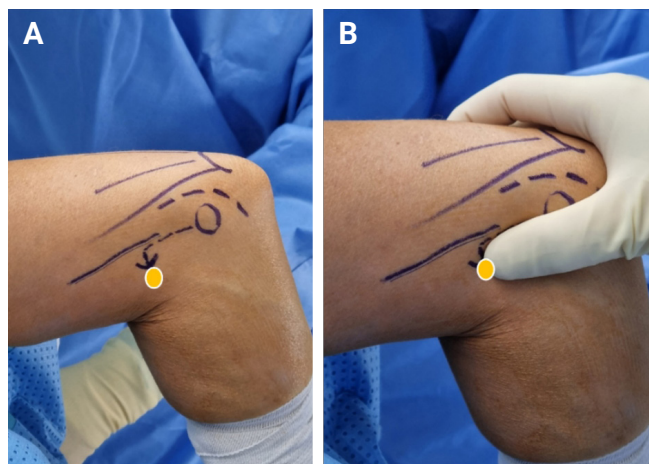


Fig. 4. (A, B) Thumb technique for establishing the proximal anteromedial portal. The interphalangeal joint of the thumb was placed proximal and distal to the margin of the medial epicondyle. The tip of the thumb points to the portal placement (yellow circle).

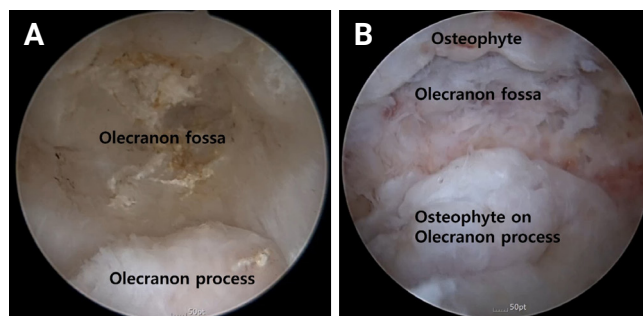


Fig. 7. (A) Direct posterior portal for visualization of the olecranon tip and fossa. (B) Olecranon osteophyte in primary osteoarthritis of the elbow.

Table 2. Portals for anterior and posterior compartment

Anterior portal	Posterior portal
• Proximal anteromedial portal (main viewing portal) (Figs. 4 and 5)	• Soft spot portal
• Proximal anterolateral portal	• Direct posterior portal
• Anteromedial portal	• Posterolateral portal
• Anterolateral portal	

Proximal Anterolateral Portal

The proximal anterolateral portal, as introduced by Field et al. [19] and popularized, adheres to a standardized placement 2 cm above the lateral epicondyle, aligned precisely with the anterior cortex of the distal humerus under direct visual guidance (Fig. 6). This portal facilitates visual access to the elbow's medial compartment, encompassing the coronoid, medial capsule, and gutter. It is crucial to exercise caution regarding the radial nerve, which is at potential risk; hence, it is advised to avoid excessive proximal positioning of the portal.

Anteromedial Portal

The anteromedial portal, commonly positioned 2 cm anterior and distal to the medial epicondyle (Fig. 7B), serves as an accessory portal to the proximal anteromedial portal, particularly when addressing pathology necessitating arthroscopic intervention within the medial recess of the elbow joint. Typically, an inside-out technique is employed to establish the anteromedial portal, often assisted by a Wissinger rod. Notably, due to the direct proximity of the median nerve to the cannula when the elbow is extended, it is advisable to create the anteromedial portal with the elbow in a flexed position to enhance safety. This approach facilitates optimal visualization of the lateral capsule. As the portal moves anteriorly, there is a progressively higher risk to the anterior branch of the medial antebrachial cutaneous nerve.

Distal Anterolateral Portal

The typical placement for the distal anterolateral portal is situated 1 cm anterior and 1 cm distal to the lateral epicondyle [5]; however, caution is warranted as risk to the posterior interosseous nerve increases with distal and anterior movement [6].

Direct Lateral (Soft Spot) Portal

This portal is formed in the soft spot of the elbow, as the name suggests (Fig. 3). It is strategically placed to provide a clear view of the posterior and inferior capitellum as well as the radioulnar joint. Its boundaries are defined by the radial head, lateral epicondyle, and olecranon tip, shaping a safe area for portal creation. However, care should be exercised as the portal shifts anteriorly, which increases the potential risk to the lateral antebrachial cutaneous nerve.

Direct Posterior (Trans-Triceps) Portal

The established placement for the direct posterior portal is at the midline of the triceps tendon, precisely 3 cm proximal to the olecranon tip. This portal serves as the principal viewing point for the posterior compartment, essential for interventions like

osteophyte removal from the olecranon (Fig. 7) and release of the posterior capsule, while ensuring consideration for the distal triceps anatomy. The creation of this portal is associated with a relatively secure process.

Posterolateral Portal

The accepted location for the posterolateral portal is 3 cm above the olecranon tip and just lateral to the triceps border. This portal proves highly effective in offering visual access to the radiocapitellar joint, which is instrumental for tasks such as eliminating the posterolateral plica or conducting debridement of osteochondritis dissecans (OCD) affecting the capitellum. However, the posterior antebrachial cutaneous nerve is at potential risk due to its proximity to this portal.

There are several procedures in the elbow joint that can be performed arthroscopically: (1) synovectomy (for septic arthritis, rheumatoid arthritis, hemophilia, tuberculosis, pigmented villonodular synovitis), (2) OCD debridement, loose body removal, (3) lateral epicondylitis (arthroscopic extensor carpi radialis brevis [ECRB] & plica release), (4) medial epicondylitis (arthroscopic flexor pronator release), and (5) valgus extension overload syndrome (VEOS).

Arthroscopic synovectomy

Synovectomy is traditionally performed with open surgery. When performing synovectomy for patients with rheumatoid arthritis, care must be taken to avoid nerve injury because of the thin and weak capsule. A non-aggressive arthroscopic shaver without suction is preferred to reduce the risk of nerve injury. Care must be taken when removing synovium at the anterior compartment because of the proximity to the radial nerve and at the posteromedial gutter because of the proximity to the ulnar nerve. When motion is impeded, anterior and/or posterior capsulectomy will improve range of motion. It is advised that capsulectomy be performed as the last step to maintain visualization. Synovectomy can be performed as an outpatient procedure. When capsulectomy is performed concomitantly, a continuous brachial plexus block is recommended to allow passive motion exercise at 48 hours postoperative.

OCD of the capitellum

Unstable OCD lesions require surgical treatment, which can be managed with an arthroscopic approach. Arthroscopic debridement aims to create a stable lesion and enhance healing through chondral abrasion or microfracture, establishing a favorable environment for cartilage regeneration. Additionally, loose bodies can be removed or impinging posteromedial olecranon osteo-

phytes can be debrided in cases of advanced OCD lesions or concomitant posteromedial impingement, respectively. The proximal anteromedial portal is the starting viewing portal for OCD debridement.

Following this, respective portals should be created with the outside-in needle under direct view. As the capitellar OCD are located posteriorly, the viewing portal is crucial for success of the procedure [20-22]. Loose bodies may be located in the coronoid fossa, medial gutter, or proximal radioulnar joint and are challenging to remove [23]. The surgeon should always confirm the presence of lateral or medial instability in OCD cases because the OCD might result from the instability. The next step involves achieving proper visualization of the capitellar OCD lesion, which is located posterolaterally on the capitellum. Trochlear and radial head lesions can be addressed adequately using standard portals. There are several ways to visualize the capitellar OCD: (1) the dual lateral portal, (2) soft spot and posterolateral, and (3) soft spot and distal ulnar portal techniques [24].

The dual portals are made 1 cm from each other at the center of the soft spot [25]. Their proximity creates competition between the instrument and scope ("sword fighting"). The posterolateral portal is any portal lateral to the paratricipital and 3 cm proximal to the tip of the olecranon [26]. This technique might be awkward since the arthroscope is pointed toward the surgeon when viewing the capitellum [27]. The distal ulnar portal is made 3 cm distal to the posterior radiocapitellar joint and lateral to the ulnar border [27]. A study by Trofa et al. [24] showed that the dual lateral, distal ulnar, and posterolateral approaches resulted in comparable degrees of visualization of the capitellar OCD. The mean percentages of capitellum visualized were approximately 68.8%, 66.3%, and 63.5% for dual lateral, distal ulnar, and posterolateral techniques, respectively.

Once proper visualization of the OCD lesion is established, the lesion is graded using the classification system proposed by the International Cartilage Repair Society (ICRS) [28]. Grade 1: a stable lesion characterized by a continuous but softened area that is covered by intact articular cartilage; grade 2: a lesion with partial articular cartilage discontinuity; the lesion remains stable when probed; grade 3: a more severe lesion presenting complete articular cartilage discontinuity but without dislocation of the cartilage, sometimes referred to as "dead *in situ*"; grade 4: the most severe classification within this system, grade 4 describes either an empty defect, a defect with a dislocated fragment, or a loose fragment within the cartilage bed.

Lesion stability can be assessed using a probe. Stable lesions with an intact cartilage cap and soft consistency upon probing (ICRS grade 1) may be candidates for retrograde drilling. Unsta-

ble lesions exhibiting full-thickness cartilage lesions with partial or circumferential discontinuity (ICRS grade 2 or 3) should be debrided. Debridement can be performed using an arthroscopic resector until the subchondral bone is visualized. Additionally, microfracture can induce fibrocartilage healing. An unstable lesion with partial flap or discontinuity requires fragment fixation, which is an advanced technique.

Loose bodies frequently result from traumatic incidents leading to osteochondral fractures or osteophyte fractures. Other contributing factors include persistent OCD or synovial chondromatosis. These loose bodies typically are located in areas such as the olecranon fossa, coronoid fossa, or above the radiocapitellar joint. Prior to surgical intervention, X-ray and computed tomography scan imaging is highly beneficial, providing precise locations of loose bodies for removal during the procedure. Water turbulence should be avoided during the extraction process to not dislodge the loose bodies.

Lateral epicondylitis

The arthroscopic management of lateral epicondylitis demands a thorough understanding of the anatomy of the common extensor origin and the lateral ulnar collateral ligament as the important adjacent structure [11,29]. At the elbow joint, the extensor carpi radialis longus (ECRL) lies on top of the tendinous portion of the ECRB. When performing an open procedure for lateral epicondylitis, the muscular portion of the ECRL must be exposed to visualize the tendinous ECRB. The arthroscopic approach offers an advantage in debriding the ECRB without insulting the integrity of the ECRL. The diamond-shaped footprint of ECRB is located just distal to the lateral epicondyle [30].

Diagnostic arthroscopy is conducted using the proximal anteromedial portal as the main viewing portal and proximal lateral working portal. Any presented anterior synovitis is resected. The lateral capsule is evaluated based on the Baker classification. The annular ligament is inspected for snapping and impingement to the radial head. The lateral capsule is dissected to enable visualization to the tendinous portion of the ECRB with the shaver. The ECRB is resected until the overlying muscular portion of the ECRL is visualized. (Fig. 8) The arthroscope is later moved to the posterior site for inspection of the synovial plica, which is also resected. Care must be taken to avoid injury to the lateral collateral ligament complex, which will result in posterolateral rotatory instability by its positioning anterior to the radial head equator.

Medial epicondylitis

Enthesopathy of the medial epicondyle is less common than in the lateral epicondyle. The etiology of medial epicondylitis is

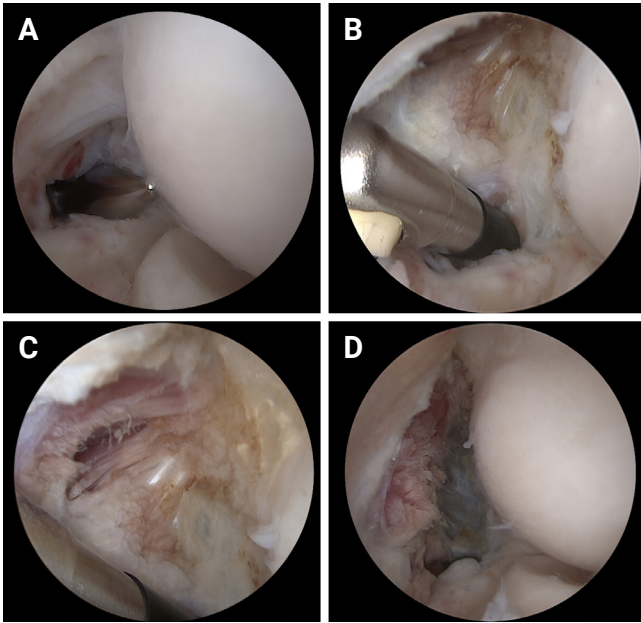


Fig. 8. Extensor carpi radialis brevis (ECRB) release procedure. (A) Capsular release using a direct anterolateral portal. (B) Extended release of proximal attachment of the capsule. (C) The whitish tissue is the ECRB tendon. (D) Release of the ECRB tendon with preservation of the ECRL tendon (muscular region).

thought to be associated with microtrauma and degeneration of the origin of the flexor carpi radialis and pronator teres. The pathologic origin of the flexor pronator origin may be angiofibroblastic. The aim of arthroscopic treatment of medial epicondylitis is to reduce the tension from the flexor pronator muscle [31].

The proximal anterolateral portal is the main viewing portal for this procedure and is created by the inside-out technique. A 70° arthroscope is helpful to inspect the full origin of the flexor-pronator complex at the anterosuperior aspect of the medial epicondyle. Capsulectomy was performed with a radiofrequency ablator, and degenerated tissue removal was performed with the resector until the superficial fibers of the anterior bundle of the medial collateral ligament were seen. Capsulectomy should start at the anterior part of the coronoid and continue to the medial epicondyle. Decortication of the edge of the medial epicondyle was performed using a resector. Presurgical marking of the maximum point of tenderness is useful to confirm complete removal of the flexor pronator origin. The surgeon must evaluate the presence of cartilage lesions as well as the MCL sprain, both of which have been found to be associated with medial epicondylitis [32-34].

VEOS IMPINGEMENT SYNDROME

The posterolateral or direct posterior portal can be used as the viewing portal, while the other portal can serve as the working portal for instrumentation, including graspers or resectors. The posterior portals are kept as far apart as possible to allow optimal triangulation because of the limited space at the posterolateral side [35]. The surgeon should pay attention to the ulnar nerve because of the proximity to the medial gutter. Removal of pathologic osteophytes is performed with an arthroscopic burr and small osteotome, and the osteophytes should not impinge on the native bone. Prior to osteophyte removal, generous removal of fibrous tissue on the overlying olecranon fossa should occur to allow detailed visualization. A hooded resector is used when performing osteophyte removal at the medial side to avoid insult to the ulnar nerve. Additionally, a periosteal elevator acting as a retractor could be used to protect the ulnar nerve during the procedure. Over-resection of the olecranon tip may induce stress on the MCL, destabilizing the elbow joint [36]. Bony debris and loose bodies are extracted, and the synovium should be inspected for additional loose bodies. After osteophyte debridement, assessment of the trochlear chondral surface and olecranon fossa is performed to identify loose bodies, kissing lesions, or osteochondral defects.

COMPLICATIONS

Several factors contribute to the recognized potential complications associated with arthroscopic elbow surgery. The generally accepted complications of arthroscopic elbow surgery include: (1) Iatrogenic nerve palsy and vascular injury, with a higher risk for patients with underlying rheumatoid arthritis and severe elbow contracture, as well as with intraoperative use of suctioning for tissue debridement [13,37]. (2) Infection. (3) Compartment syndrome, with the risk reduced by postoperative application of a tourniquet to the forearm, preventing fluid extravasation. (4) Elbow stiffness or heterotopic ossification (rare).

CONCLUSIONS

The field of arthroscopic intervention for elbow disorders is continuously evolving, driven by ongoing research and technological advancements. The complexity of the elbow's anatomical components, located close to the joint, contributes to the challenges of elbow arthroscopy, posing a relatively high potential for significant complications. Diligent practice, repeated exposure, and continuous hands-on experience are crucial in reducing these

risks, leading to improved outcomes comparable to the successes seen in arthroscopy for other joints.

NOTES

ORCID

Erica Kholinne <https://orcid.org/0000-0002-4326-8205>
In-ho Jeon <https://orcid.org/0000-0002-9289-9193>
Jae-Man Kwak <https://orcid.org/0000-0002-4395-8345>

Author contributions

Conceptualization: IHJ, JMK. Data curation: EK. Formal analysis: EK. Investigation: EK, IHJ. Methodology: EK, JMK. Project administration: JMK. Resources: JMK. Supervision: IHJ, JMK. Validation: JMK. Visualization: JMK. Writing – original draft: EK. Writing – review & editing: IHJ, JMK.

Conflict of interest

None.

Funding

None.

Data availability

None.

Acknowledgments

None.

SUPPLEMENTARY MATERIALS

Supplementary materials can be found via <https://doi.org/10.5397/cise.2023.01032>.

REFERENCES

1. Pederzini LA, Di Palma F, Safran MR, Bain GI. Elbow arthroscopy: state of the art. *J ISAKOS* 2017;2:279–94.
2. Burman MS. Arthroscopy or the direct visualization of joints: an experimental cadaver study. 1931. *Clin Orthop Relat Res* 2001;(390):5–9.
3. Ito K. The arthroscopy anatomy of the elbow joint. *Arthroscopy* 1979;4:2–9.
4. Maeda Y. Arthroscopy of the elbow joint. *Arthroscopy* 1980;5:5–8.
5. Andrews JR, Carson WG. *Arthroscopy of the elbow*. *Arthroscopy* 1985;1:97–107.
6. Lynch GJ, Meyers JF, Whipple TL, Caspari RB. Neurovascular anatomy and elbow arthroscopy: inherent risks. *Arthroscopy* 1986;2:190–7.
7. Poehling GG, Whipple TL, Sisco L, Goldman B. Elbow arthroscopy: a new technique. *Arthroscopy* 1989;5:222–4.
8. Sahajpal DT, Blonna D, O'Driscoll SW. Anteromedial elbow arthroscopy portals in patients with prior ulnar nerve transposition or subluxation. *Arthroscopy* 2010;26:1045–52.
9. Jeon IH. Arthroscopic treatment for lateral epicondylitis of the elbow. *J Korean Shoulder Elbow Soc* 2007;10:17–22.
10. Chun CH, Kim JW, Lim JC. Results of arthroscopic debridement of the elbow osteoarthritis. *J Korean Shoulder Elbow Soc* 2009;12:53–60.
11. Park JY, Kim JW, Chun CH, et al. Clinical results of arthroscopic treatment for lateral epicondylitis of elbow. *Clin Should Elbow* 2011;14:187–92.
12. Jang SH, Song HE. Arthroscopic excision of intra-articular osteochondroma of the elbow: a case report. *Clin Should Elbow* 2016;19:172–5.
13. Chung SW. Arthroscopic treatment of elbow osteoarthritis and arthroscopic ulnar nerve decompression. *Clin Should Elbow* 2016;19:256–63.
14. Park SG, Shin DS, Choi JH, Na HD, Park JW. Arthroscopic excision of delayed diagnosed intra-articular osteoid osteoma of the elbow: a case report. *Clin Shoulder Elb* 2018;21:162–8.
15. Song HS, Yoon HM. Pathophysiology of stiff elbow. *Clin Should Elbow* 2010;13:286–92.
16. O'Driscoll SW, Morrey BF. Arthroscopy of the elbow: diagnostic and therapeutic benefits and hazards. *J Bone Joint Surg Am* 1992;74:84–94.
17. Steinmann SP. Elbow arthroscopy: where are we now. *Arthroscopy* 2007;23:1231–6.
18. O'Driscoll SW, Morrey BF, An KN. Intraarticular pressure and capacity of the elbow. *Arthroscopy* 1990;6:100–3.
19. Field LD, Altchek DW, Warren RF, O'Brien SJ, Skyhar MJ, Wickiewicz TL. Arthroscopic anatomy of the lateral elbow: a comparison of three portals. *Arthroscopy* 1994;10:602–7.
20. Ruch DS, Cory JW, Poehling GG. The arthroscopic management of osteochondritis dissecans of the adolescent elbow. *Arthroscopy* 1998;14:797–803.
21. Baker CL 3rd, Romeo AA, Baker CL Jr. Osteochondritis dissecans of the capitellum. *Am J Sports Med* 2010;38:1917–28.
22. Coates KE, Poehling GG. Osteochondritis dissecans lesions and loose bodies of the elbow. In: Pederzini L, ed. *Elbow arthroscopy*. Springer; 2013. p. 25–33.
23. Pederzini LA, Bain G, Safran MR. *Elbow arthroscopy*. Springer; 2013.

24. Trofa DP, Gancarczyk SM, Lombardi JM, Makhni EC, Popkin CA, Ahmad CS. Visualization of the capitellum during elbow arthroscopy: a comparison of 3 portal techniques. *Orthop J Sports Med* 2017;5:2325967117712228.
25. Davis JT, Idjadi JA, Siskosky MJ, ElAttrache NS. Dual direct lateral portals for treatment of osteochondritis dissecans of the capitellum: an anatomic study. *Arthroscopy* 2007;23:723-8.
26. AAOS OVT. Elbow arthroscopy: basic setup and portal placement [Internet]. AAOS; 2021 [cited 2023 Nov 13]. Available from: https://www.aaos.org/videos/video-detail-page/24409__videos.
27. van den Ende KI, McIntosh AL, Adams JE, Steinmann SP. Osteochondritis dissecans of the capitellum: a review of the literature and a distal ulnar portal. *Arthroscopy* 2011;27:122-8.
28. Brittberg M, Winalski CS. Evaluation of cartilage injuries and repair. *J Bone Joint Surg Am* 2003;85-A Suppl 2:58-69.
29. Kim GM, Yoo SJ, Choi S, Park YG. Current trends for treating lateral epicondylitis. *Clin Shoulder Elb* 2019;22:227-34.
30. Cohen MS, Romeo AA, Hennigan SP, Gordon M. Lateral epicondylitis: anatomic relationships of the extensor tendon origins and implications for arthroscopic treatment. *J Shoulder Elbow Surg* 2008;17:954-60.
31. Kurvers H, Verhaar J. The results of operative treatment of medial epicondylitis. *J Bone Joint Surg Am* 1995;77:1374-9.
32. Oda T, Wada T, Yamamoto O, Saito A, Kondo M. Arthroscopic release of the pronator-flexor origin for medial epicondylitis. *Tech Shoulder Elb Surg* 2018;19:75-9.
33. Jang SH. Management of ulnar collateral ligament injuries in overhead athletes. *Clin Shoulder Elb* 2019;22:235-40.
34. Moon JG, Lee HD. Comparison of ulnar collateral ligament reconstruction techniques in the elbow of sports players. *Clin Shoulder Elb* 2020;23:41-7.
35. Noticewala MS, Vance DD, Trofa DP, Ahmad CS. Elbow arthroscopy for treatment of valgus extension overload. *Arthrosc Tech* 2018;7:e705-10.
36. Kamineni S, ElAttrache NS, O'driscoll SW, et al. Medial collateral ligament strain with partial posteromedial olecranon resection: a biomechanical study. *J Bone Joint Surg Am* 2004;86:2424-30.
37. Moon YL, Nam KY. Arthroscopic treatment of stiff elbow. *Clin Shoulder Elbow* 2010;13:299-302.