

Arthroscopic matched osteoplasty of the radial head for painful radiocapitellar osteoarthritis: surgical technique and case series

Dani Rotman^{1,2}, Adam C Watts¹

¹Wrightington Upper Limb Unit, Wrightington, Wigan and Leigh NHS Foundation Trust, Wigan, UK

²Department of Orthopedic, Laniado Hospital, Adelson School of Medicine, Ariel University, Netanya, Israel

Background: Radiocapitellar arthritis can cause pain, loss of motion, and impaired elbow function. Current surgical treatment options are limited. We have developed an original and simple surgical technique to address this, called arthroscopic matched osteoplasty of the radial head (AMOR). In AMOR, the radial head is partially resected and recontoured to match the capitellum and decompress the degenerate radiocapitellar articulation while preserving the ulnohumeral articulation where the cartilage is usually well preserved.

Methods: Indications and the surgical technique of the AMOR procedure are described. A retrospective observational service evaluation study was conducted from electronic patient records. Collected clinical outcomes included range of motion, pain level, subjective functional score, and general satisfaction with the results of the procedure. The radiographic outcome was radiocapitellar joint space.

Results: Between 2017 and 2021, eight consecutive patients underwent AMOR as part of an arthroscopic osteocapsular arthroplasty procedure. Radiographically, the mean radiocapitellar joint space improved from an average of 1.7 mm to 4.6 mm. Clinically, the mean pain score decreased from 8/10 to 3/10. Six of the eight patients (75%) were satisfied with their results. In two cases, initial improvement following surgery lasted less than 1 year, and one of these patients underwent total elbow arthroplasty for painful ulnohumeral osteoarthritis. There were no complications of surgery recorded.

Conclusions: AMOR is a safe treatment option for painful radiocapitellar osteoarthritis and can be incorporated as an “add-on” procedure by surgeons performing elbow osteocapsular arthroplasty in cases with a positive grip and grind test and radiographic evidence of radiocapitellar OA.

Level of evidence: IV.

Keywords: Osteoarthritis; Radial head; Osteoplasty; Resection; Arthroscopy

INTRODUCTION

Primary osteoarthritis (OA) of the elbow is a disabling condition that manifests with pain, loss of motion, and weakness [1]. It predominantly affects middle-aged men whose occupation involves heavy manual work [2,3]. Unlike other joints, the elbow uniquely incorporates two joints with distinct OA characteristics: the ulnohumeral (UH) and radiocapitellar (RC) joints. Painful arthro-

sis of the proximal radio-ulnar joint is rare. OA of the elbow manifests with a widespread formation of osteophytes and loose bodies; however, in the UH joint, the articular cartilage and joint spaces are often preserved until later stages, whereas the RC joint is prone to more severe cartilage damage [4] and joint space narrowing [3,5]. A possible explanation for this discrepancy is that OA changes manifest in the RC joint prior to those in the UH joint, resulting in a relatively more progressive arthritic condition

Received: December 20, 2023 Revised: March 29, 2024 Accepted: April 18, 2024

Correspondence to: Dani Rotman

Department of Orthopedic, Laniado Hospital, Divrei Khayim St 16, Netanya, 4244916, Israel

Tel: +972-527360185, Email: drotman@laniado.org.il, ORCID: <https://orcid.org/0000-0003-4013-0152>

© 2024 Korean Shoulder and Elbow Society.

This is an Open Access article distributed under the terms of the Creative Commons Attribution Non-Commercial License (<https://creativecommons.org/licenses/by-nc/4.0/>) which permits unrestricted non-commercial use, distribution, and reproduction in any medium, provided the original work is properly cited.

in the RC joint at any given point in time [4,6].

The first line of treatment for primary RC OA is non-surgical, including activity modification, nonsteroidal anti-inflammatory drugs [3], and intra-articular injections. Several surgical options exist for patients with ongoing symptoms despite nonsurgical treatment. Arthroscopic debridement usually provides good pain relief [7] but is insufficient in some patients [8]. Radial head resection [9,10] and prosthetic RC resurfacing [4] show good results in reducing pain but are less suitable for younger manual workers due to concerns about long-term complications [7,11].

The senior author has implemented a technique of arthroscopic matched osteoplasty of the radial head (AMOR). This method includes decompression of the articular joint by partially resecting the radial head and contouring the new articular surface to match the convexity of the capitellum. In keeping with the IDEAL framework for surgical development [12], the purpose of this phase 1 study is to report an assessment of the safety and effectiveness of the AMOR technique in the short-term in a single-surgeon series [12].

METHODS

Institutional Review Board approval of WWL NHS Foundation Trust (No. TrOrtho/CA/2022-23/57) was obtained. As a retrospective study, informed consent was waived by the Board.

Surgical Technique

Indications/contraindications

The indication for AMOR is primary, symptomatic OA of the RC joint. The specific contribution of the RC joint to the clinical picture is inferred by (1) history of activity-related lateral-sided elbow pain, (2) positive grip and grind test [13] (pain induced by axially loading and rotating the forearm), or (3) x-ray or computed tomography scan showing RC joint narrowing with a preserved UH joint space.

The contraindications for this surgery include active skin infection, elbow or forearm instability, and symptomatic UH joint space narrowing. Relative contraindications include a history of trauma leading to distortion of anatomic landmarks and a history of ulnar nerve transposition.

Positioning and preparation

The surgery is performed under general anesthesia. The patient is placed in the lateral decubitus position using a bean bag. Intra-articular infiltration of 10–20 mL of 7.5 mg/mL Ropivacaine local anesthetic is performed at least 5 minutes before the first

incision to aid with postoperative analgesia. Under anesthesia, the elbow range of motion is tested and documented, and stability is assessed. The arm is exsanguinated, and the high-arm tourniquet is inflated to 250 mmHg. The arm is positioned in a Tri-mano arm positioner with elbow attachment (Arthrex). The upper extremity is prepared using alcoholic chlorhexidine and draped using an extremity drape.

Arthroscopic approach

The technique for elbow osteocapsular arthroplasty was described by O'Driscoll and Blonn [14] and is performed as needed based on the patient's arthritic changes in the UH joint. The author routinely uses six portals: (1) a midline posterior portal located 4 cm proximal to the olecranon tip; (2) a proximal posterolateral portal located lateral to the posterior portal at the lateral edge of the triceps tendon 1 cm more proximal than the midline posterior portal; (3) a proximal lateral portal located at the midpoint of a line connecting the lateral epicondyle to the olecranon process and (4) a direct lateral "soft spot" portal 2 cm distal to this in line with the lateral border of the ulna; (5) an anteromedial portal located 2 cm proximal and 2 cm anterior to the medial epicondyle; and (6) a mid-anterolateral portal located 2 cm proximal and 3–4 cm anterior to the lateral epicondyle.

AMOR procedure

Removal of loose bodies and peri-articular osteophytes is undertaken where necessary. When grade 4 osteoarthritic changes are found in the proximal articular surface of the radial head in patients meeting the clinical indications for AMOR, the procedure is undertaken in two stages (resecting and reshaping) (Fig. 1) using the proximal lateral viewing portal and direct lateral working portal.

In the first stage, a 4 mm arthroscopic burr is used to resect 4 mm (a burr's width) of the proximal surface of the radial head. This is facilitated by removing bone to the correct depth over one segment of the radial head (Fig. 2A) and using this as a reference for subsequent removal of the rest of the RC articular surface to the same depth. Forearm rotation is needed to reach the entire radial head surface. Care must be taken not to penetrate the anterior capsule and injure the radial nerve.

In the second stage, an additional 4 mm is resected from the center of the radial head and then chamfered toward the rim, giving the radial head a concave surface that matches the shape of the capitellum (Fig. 2B). Grasping forceps or pituitary rongeur can be used to remove any remaining cartilage flaps from the rim of the radial head.

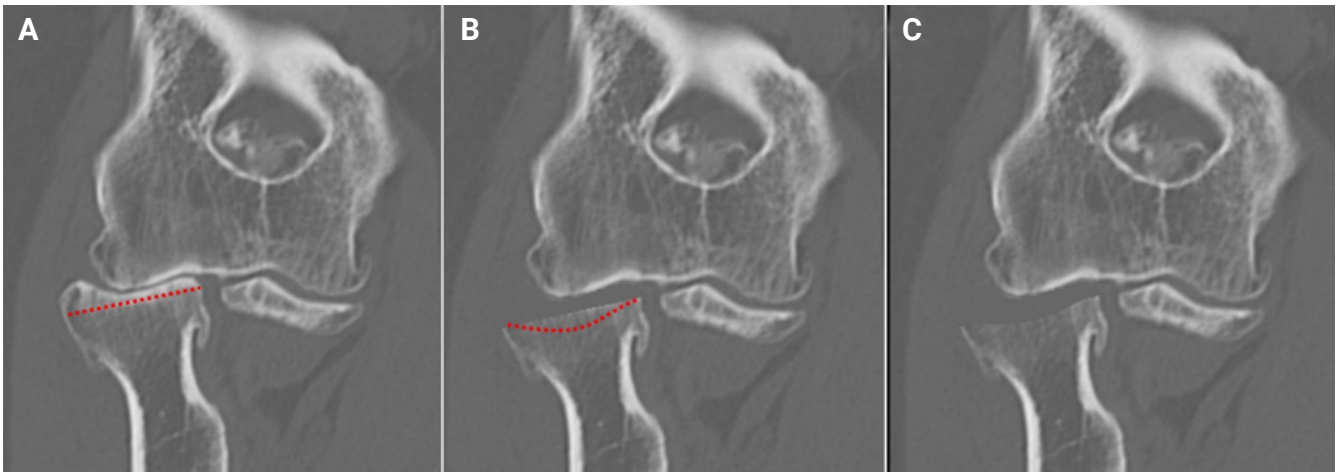


Fig. 1. Schematic drawing of the arthroscopic matched osteoplasty of the radial head procedure. (A) Significant radiocapitellar joint space narrowing is observed. The red dotted line represents the intended partial resection of 4 mm. (B) Following the first stage, 4 mm was resected off the proximal surface of the radial head. The red dotted line represents the intended recontouring. (C) Following the second stage, the radial head surface was contoured to a concave surface that matches the shape of the capitellum.

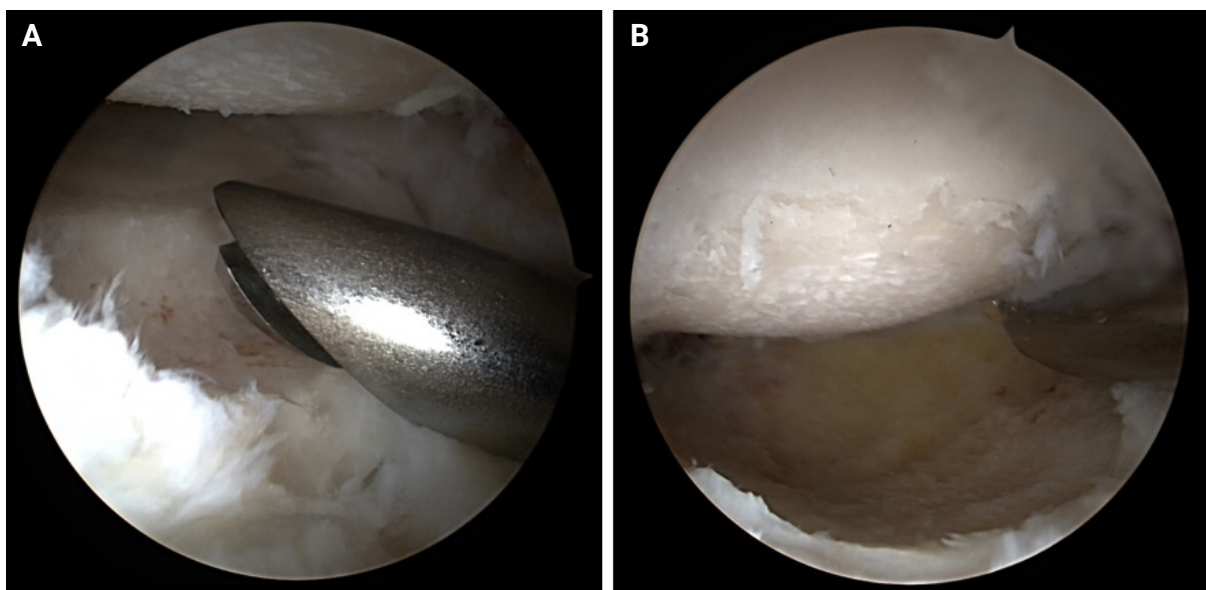


Fig. 2. Arthroscopic images from the arthroscopic matched osteoplasty of the radial head procedure. Viewed from the proximal lateral portal, the capitellum is at the top and the radial head is at the bottom. (A) An initial 4 mm step of the articular surface of the radial head was resected. This step was used as a template to complete a 4 mm resection of the articular surface of the radial head. (B) At the end of the procedure, the radial head's new concave surface matched the shape of the capitellum, with a large joint space.

Wound closure

Portal wounds are not sutured, but adhesive tape (Steri-strips) is used to oppose the edges, and a sterile dressing is applied. A padded dressing is retained for 48 hours, and a sling is provided for comfort.

Rehabilitation

Patients are discharged the same day after review by the in-patient physiotherapy team. They are advised to undertake imme-

diately full, active range of movement exercises, and formal physiotherapy is encouraged with a graduated loading program as tolerated.

Patient Cohort

A retrospective service evaluation was conducted of all patients who underwent the AMOR procedure between 2017 and 2021. The AMOR procedure was offered to patients who met the abovementioned criteria, namely individuals suffering from RC

arthritis with preserved UH joint space, preferably aged 50–60 years, who failed conservative treatment offered by their general practitioner.

Routine data collection occurred before and after surgery, and patients were asked to report their level of pain on a numeric rating scale (NRS) from zero (no pain) to 10 (severe pain) and to complete the shortened disabilities of the arm, shoulder and hand questionnaire (QuickDASH) questionnaire [15]. Range of movement was recorded using a hand-held goniometer. At follow-up, the single assessment numeric evaluation (SANE) for function was recorded using a scale from 0 (no function) to 10 (normal function) [16], and patients were asked to record whether they were satisfied or not with the outcome of the procedure. No statistical comparison of preoperative and postoperative data was undertaken due to the small sample size. Radiographs were assessed for this study, and the joint space of the RC joint and the UH joint was measured on an AP radiograph at the midpoint of each joint (Fig. 3) using Sectra radiology software.

RESULTS

Between 2017 and 2021, eight patients with a proper history, clinical examination, and radiographic imaging supporting the diagnosis of painful RC OA underwent the AMOR procedure as an addition to an arthroscopic UH osteocapsular arthroplasty. The median age of the patients was 60 years (range, 42–68 years), and seven were male. All patients were assessed clinically in the outpatient department after surgery, and plain radiographs were available for six of the eight before and after surgery. The median follow-up was 20 months (range, 5–66 months).

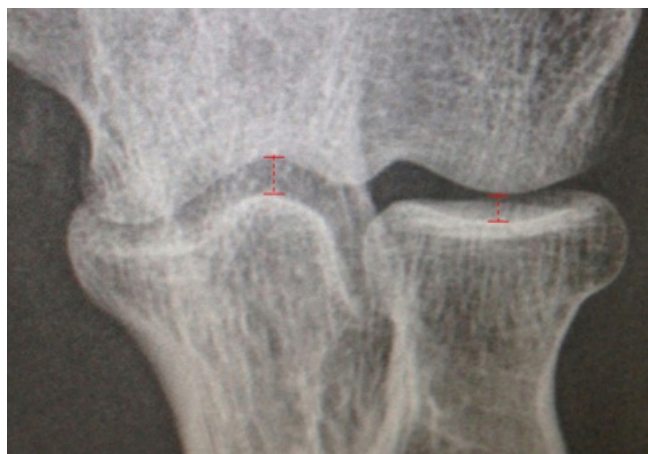

Fig. 3. An anteroposterior radiograph was used to measure the joint space at the midpoint of the radiocapitellar and ulnohumeral joints.

Radiographic Results

The RC joint space improved by a mean of 3 mm, whereas the mean UH joint space, measured as a reference, did not change (Figs. 4 and 5). The radiographic results for each patient are depicted in Table 1.

Clinical Results

The patient's range of motion before surgery and at last follow-up are described in Table 2. The mean NRS pain score was reduced from 8/10 (range, 6–10) to 3/10 (range, 0–8). The postoperative QuickDASH score was only available for four patients, but the average score improved from 49/100 (range, 23–89) to 26/100 (range, 5–54), including one patient for whom the QuickDASH score increased from 23 to 54 due to progression of UH OA. The average post-operative SANE score was 8/10 (range, 4–10). At the latest follow-up, six patients reported satisfaction with the procedure's outcome. However, two patients experienced only short-lived improvement (less than 1 year), of which one underwent subsequent total elbow arthroplasty, and the other is considering further surgical treatment.

Complications

No significant postoperative complications were noted. One patient (#2) who suffered from severe contracture preoperatively lost his improved range of motion within 1 year.

DISCUSSION

This paper describes a new surgical technique to treat RC OA, AMOR, developed mainly to address the young, heavy-labor population for which current treatment options are limited.

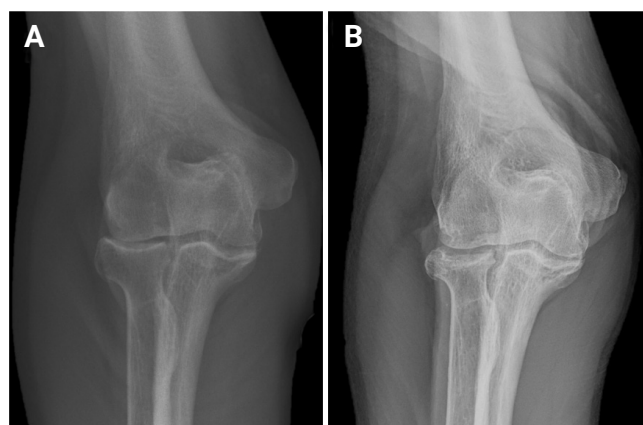


Fig. 4. (A) Preoperative and (B) 5.5 years postoperative anteroposterior elbow radiographs of patient no. 8, showing the maintained increased radiocapitellar joint space.

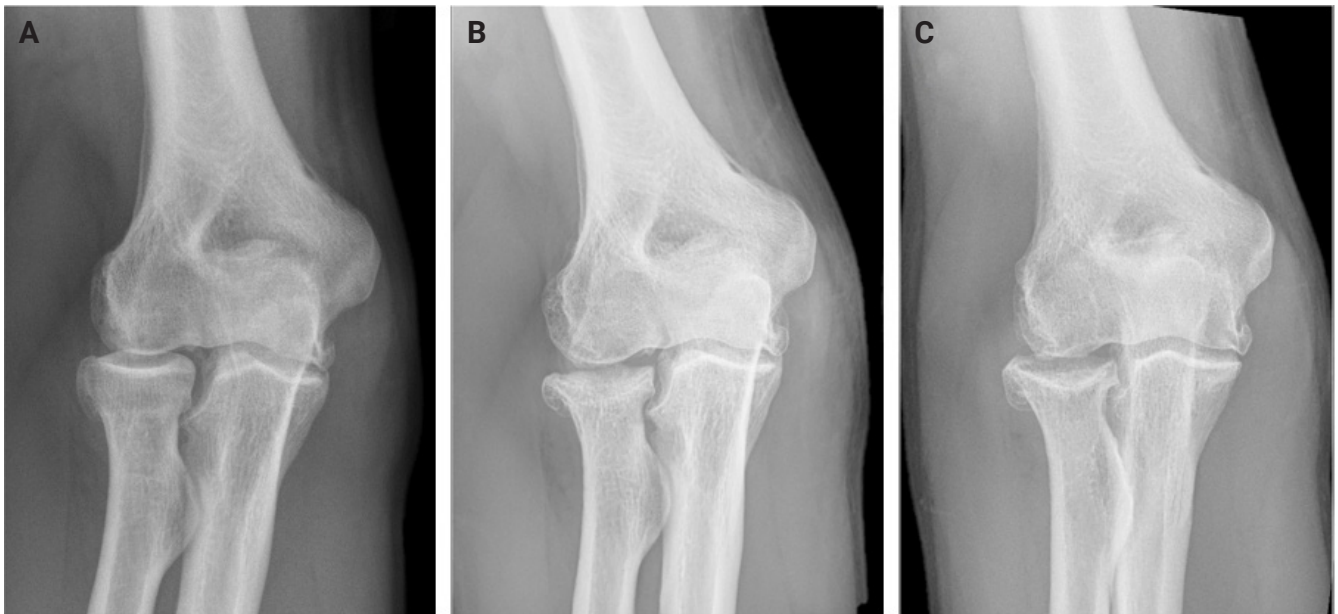


Fig. 5. (A) Preoperative, (B) 4 months and (C) at 2.5 years postoperative anteroposterior elbow radiographs of patient no. 4. No renarrowing was observed.

Table 1. Radiographic results of arthroscopic matched osteoplasty of the radial head

Age (yr)/sex	Follow-up (mo)	Pre-UH joint space (mm)	Post-UH joint space (mm)	Pre-RC joint space (mm)	Post-RC joint space (mm)
59/F	4	2.6	1.5	1.7	6.3
60/M	23	0.5	0.5	1.4	3.0
60/M	NA	3.0	NA	1.2	NA
55/M	29	3.6	3.8	3.0	7.0
42/M	3	3.7	4.2	1.1	4.4
66/F	18	4.0	3.8	1.5	3.7
68/M	NA	2.7	NA	1.2	NA
68/M	66	4.2	3.3	2.4	3.5
Mean	21 ^{a)}	3.0	2.9	1.7	4.7

UH: ulnohumeral, RC: radiocapitellar, NA: not available.

^{a)}Median value.

Table 2. Range of motion and clinical results of arthroscopic matched osteoplasty of the radial head

Age (yr)/sex	Follow-up (mo)	Pre-arc (°)	Post-arc (°)	Pre-rotation (°)	Post-rotation (°)	Subjective outcome
59/F	10	70	110	120	170	Satisfied with results
60/M	23	50	40	150	150	Improvement only lasted about a year, considering a second intervention
60/M	5	80	115	180	180	Satisfied with results
55/M	38	110	125	NA	100	Satisfied with results
42/M	17	90	NA	180	NA	Satisfied with results
66/F	60	75	90	180	180	Improvement only lasted a few months, underwent a total elbow arthroplasty
68/M	6	105	120	180	180	Satisfied with results
68/M	66	125	130	150	150	Satisfied with results
Mean	20 ^{a)}	88	104	160	168	

NA: not available.

^{a)}Median value.

While the promising results presented in this paper are short-term, they show the safety of this technique. Current surgical treatment options for patients with ongoing symptoms all have advantages and disadvantages, most of which limit their usability in younger patients. Arthroscopic debridement brings excellent results in an arthritic UH joint with marginal osteophytes [1]. Implementing a similar simple arthroscopic debridement technique in 25 young patients with advanced RC OA, Kelly et al. [7] reported that 24 of the patients improved after surgery, and 21 reported no or minimal pain. While these results are excellent, it is our experience that simple debridement is insufficient in some patients.

Radial head resection, using either an arthroscopic or open approach, sometimes with soft tissue interposition, is currently undertaken and has successfully been shown to reduce pain in RC OA [9-11]. There are concerns, however, that radial head resection increases the load across the lateral UH facet and accelerates arthrosis of that articulation and also disturbs forearm joint biomechanics, resulting in wrist pain [7,11]. Therefore, it is considered less suitable for younger manual workers [7].

Radial shortening was proposed by Hackl et al. [17,18] to decompress the RC joint in young and active patients with symptomatic RC OA. However, with no published clinical results, this intervention remains under evaluation. Prosthetic RC resurfacing has been shown to offer good short- to medium-term outcomes [4], albeit in a small number of patients. Nonetheless, there are concerns about prosthesis longevity in young, active manual workers.

Previous techniques describe excision of the whole radial head or removing a burr-width of bone to create a flat surface. The former risks forearm instability and the latter recurrent RC pain. The matched hemiresection preserves the radio-ulnar articulation while providing sufficient joint resection to prevent recurrent RC contact. The AMOR procedure is straightforward to perform for surgeons experienced with elbow arthroscopy.

The AMOR technique has three main advantages, making it especially suitable for the young, active population. (1) It does not significantly alter the elbow joint biomechanics. The proposed "shortening" of 4 mm decompresses the RC joint [18] but does not significantly alter UH joint mechanics [19]. (2) It allows quick recovery without postoperative limitations. (3) It does not limit future treatment options such as radial head resection, RC arthroplasty, or total elbow arthroplasty in cases of treatment failure or slow progression of arthrosis.

Our study has some limitations, namely the small number of patients and short-term follow-up. Also, there is a noted risk of selection bias as the treatment was offered only to select patients.

Finally, our study lacked a control group to compare the obtained results. Nonetheless, the main purpose of this publication is to report the AMOR technique and its safety.

CONCLUSIONS

AMOR is an alternative treatment option for patients with painful RC OA. As current treatment options are limited, this joint decompression procedure provides a safe option for working-aged people. While the presented results are short-term, they support the procedure's safety and suggest further investigation with longer follow up to determine whether this technique can be effective in other surgeons' practices in IDEAL stage 2 investigations [12]. We believe AMOR should be incorporated as an "add-on" procedure by surgeons performing elbow osteocapsular arthroplasty in cases with painful RC pathology with a positive grip-and-grind test on pre-operative evaluation.

NOTES

ORCID

Dani Rotman <https://orcid.org/0000-0003-4013-0152>
 Adam C Watts <https://orcid.org/0000-0003-0795-6462>

Author contributions

Conceptualization: ACW. Data curation: DR. Formal analysis: DR. Investigation: DR. Resources: ACW. Supervision: ACW. Visualization: DR. Writing – original draft: DR. Writing – review & editing: ACW.

Conflict of interest

None.

Funding

None.

Data availability

Contact the corresponding author for data availability.

Acknowledgments

None.

REFERENCES

1. Papatheodorou LK, Baratz ME, Sotereanos DG. Elbow arthritis: current concepts. *J Hand Surg Am* 2013;38:605–13.
2. Adla DN, Stanley D. Primary elbow osteoarthritis: an updated

- review. *Shoulder Elbow* 2011;3:41–8.
3. Martinez-Catalan N, Sanchez-Sotelo J. Primary elbow osteoarthritis: evaluation and management. *J Clin Orthop Trauma* 2021;19:67–74.
 4. Pooley J, Van der Linden D. Radiocapitellar arthroplasty. *J Clin Orthop Trauma* 2021;19:237–44.
 5. Dalal S, Bull M, Stanley D. Radiographic changes at the elbow in primary osteoarthritis: a comparison with normal aging of the elbow joint. *J Shoulder Elbow Surg* 2007;16:358–61.
 6. Murata H, Ikuta Y, Murakami T. An anatomic investigation of the elbow joint, with special reference to aging of the articular cartilage. *J Shoulder Elbow Surg* 1993;2:175–81.
 7. Kelly EW, Bryce R, Coghlan J, Bell S. Arthroscopic debridement without radial head excision of the osteoarthritic elbow. *Arthroscopy* 2007;23:151–6.
 8. Kokkalis ZT, Schmidt CC, Sotereanos DG. Elbow arthritis: current concepts. *J Hand Surg Am* 2009;34:761–8.
 9. Baghdadi YM, Morrey BF, Sanchez-Sotelo J. Anconeus interposition arthroplasty: mid- to long-term results. *Clin Orthop Relat Res* 2014;472:2151–61.
 10. McLaughlin RE 2nd, Savoie FH 3rd, Field LD, Ramsey JR. Arthroscopic treatment of the arthritic elbow due to primary radiocapitellar arthritis. *Arthroscopy* 2006;22:63–9.
 11. Hildebrand AH, Zhang B, Horner NS, King G, Khan M, Alolabi B. Indications and outcomes of radial head excision: a systematic review. *Shoulder Elbow* 2020;12:193–202.
 12. McCulloch P, Cook JA, Altman DG, Heneghan C, Diener MK, IDEAL Group. IDEAL framework for surgical innovation 1: the idea and development stages. *BMJ* 2013;346:f3012.
 13. Murray O, Macdonald D, Nunn T, McEachan J, Rymaszewski L. Management of the post-traumatic stiff elbow. *Shoulder Elbow* 2012;4:38–45.
 14. O'Driscoll SW, Blonna D. Osteocapsular arthroplasty of the elbow: surgical technique. *JBJS Essent Surg Tech* 2013;3:e15.
 15. Gummesson C, Ward MM, Atroshi I. The shortened disabilities of the arm, shoulder and hand questionnaire (QuickDASH): validity and reliability based on responses within the full-length DASH. *BMC Musculoskelet Disord* 2006;7:44.
 16. Razaeeian S, Wiese B, Zhang D, Krettek C, Meller R, Hawi N. Correlation between Oxford Elbow Score and Single Assessment Numeric Evaluation: is one simple question enough. *J Shoulder Elbow Surg* 2020;29:1223–9.
 17. Hackl M, Wegmann K, Kahmann SL, et al. Reply to the letter to the editor: shortening osteotomy of the proximal radius. *Knee Surg Sports Traumatol Arthrosc* 2017;25:3328–29.
 18. Hackl M, Wegmann K, Kahmann SL, et al. Radial shortening osteotomy reduces radiocapitellar contact pressures while preserving valgus stability of the elbow. *Knee Surg Sports Traumatol Arthrosc* 2017;25:2280–8.
 19. Ramazanian T, Müller-Lebschi JA, Merlet MH, et al. Effect of radiocapitellar joint over/under stuffing on elbow joint contact pressure. *J Hand Surg Am* 2023;48:403.