

## Ultrasonography in the management of lip complications caused by hyaluronic acid

Hyago Portela Figueiredo<sup>1</sup>, Fernanda Coimbra<sup>2</sup>, Tânia de Carvalho Rocha<sup>3</sup>,  
Micena Roberta Miranda Alves e Silva<sup>4,\*</sup>

<sup>1</sup>Undergraduate Dentistry Student, Federal University of Minas Gerais, Belo Horizonte, MG, Brazil

<sup>2</sup>Dental Surgeon Specializing in Implant Dentistry, Belo Horizonte, MG, Brazil

<sup>3</sup>Radiologist at the Hermes Pardini Group, Belo Horizonte, MG, Brazil

<sup>4</sup>Department of Morphology, Biological Sciences Institute, Federal University of Minas Gerais, Belo Horizonte, MG, Brazil

### ABSTRACT

Ultrasonography is highly accurate for evaluating soft tissues. Given that minimally invasive aesthetic procedures are on the rise, complications have become more prevalent. Thus, ultrasonography holds promise for assisting in the diagnosis and management of complications arising from these interventions. This report highlights the importance of ultrasonography in the treatment of complications caused by hyaluronic acid injection. A patient visited a dental office 24 hours after hyaluronic acid application, presenting pain and bruising in the middle and inferior thirds of the face on the right side. To evaluate blood vessels, the surgeon used Doppler-mode ultrasonography, which enabled the precise application of hyaluronidase to reestablish blood perfusion and preserve adjacent structures. Therefore, to avoid severe outcomes, such as necrosis or even amaurosis, the use of ultrasonography is suggested, improving the precision and safety of these procedures. (*Imaging Sci Dent* 2024; 54: 296-302)

**KEY WORDS:** Lip; Ultrasonography, Doppler; Hyaluronic Acid; Ischemia

Ultrasonography (USG) has emerged as a very important imaging modality for assessing the soft tissues of the face and neck, owing to its superior diagnostic accuracy compared to other established methods.<sup>1,2</sup> It offers the advantages of not emitting ionizing radiation, providing real-time imaging, and being easily reproducible.<sup>1</sup>

Due to the increasing popularity of minimally invasive aesthetic procedures, such as hyaluronic acid (HA) injections into the lips, facial mapping has become crucial, both for identifying injectable products and for recognizing blood vessels to prevent complications.<sup>3-5</sup> Therefore, USG can be used to differentiate between HA, which appears as hypoechoic to anechoic on USG, depending on its composition,<sup>2,6</sup> and the hyaluronidase enzyme, which has a hyperechoic appearance.<sup>7</sup>

The complications of filler injections include bruising,

edema, skin irregularities, the Tyndall effect, granuloma formation, as well as more serious issues such as anaphylaxis, necrosis, and amaurosis (potentially temporary severe visual loss due to lack of blood flow to the optic nerve and retina). These latter 2 complications can result from either intravascular injection or arterial blood vessel compression.<sup>3,8</sup> Additionally, even when filler material is injected into areas like the lips, there remains a moderate risk of visual loss.<sup>9</sup>

USG with Doppler mode can be dynamically utilized to produce images for minimally invasive facial harmonization procedures. It provides crucial information about the location, types, and relationships of blood vessels with adjacent anatomical structures,<sup>10,11</sup> identifies anatomical variations, and guides the injection of hyaluronidase at sites with vascular obstruction.<sup>7,12</sup>

The objective of this report was to underscore the crucial role of USG guidance in the precise and safe administration of hyaluronidase injections, thereby preventing the exacerbation of the clinical condition in patients who have undergone lip filling procedures with HA.

Received January 26, 2024; Revised May 18, 2024; Accepted May 28, 2024  
Published online July 17, 2024

\*Correspondence to: Prof. Micena Roberta Miranda Alves e Silva  
Department of Morphology, Biological Sciences Institute, Federal University of Minas Gerais, Av. Antônio Carlos, 6627 - 31.270-901, Belo Horizonte, MG, Brazil  
Tel) 55-31-3409-3003, E-mail) micenarm@gmail.com

## Case Report

This study received approval from the Research Ethics Committee of the Federal University of Minas Gerais (CAAE: 11031219.4.0000.5149) and was conducted following the acquisition of the patient's consent form.

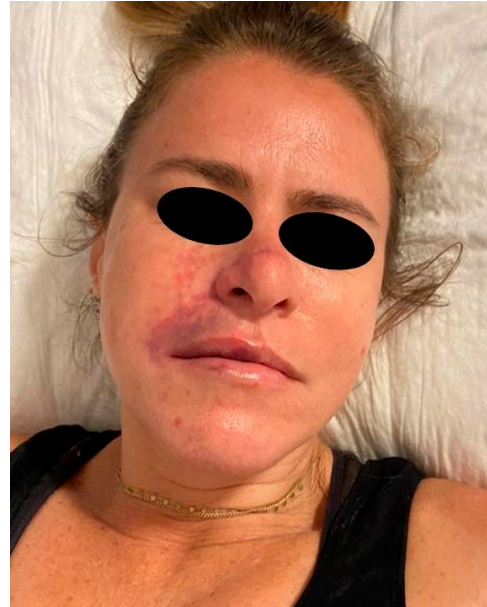A 53-year-old female patient visited the dental office 24 hours after receiving a 1 mL injection of HA with lidocaine into her upper and lower lips. She exhibited painful symptoms and ecchymosis in the area of the right upper lip, nose, and oral vestibule (Fig. 1). During the anamnesis, she reported no comorbidities and denied taking any medications. She also mentioned that approximately 2 years prior, she had undergone several cosmetic procedures, including the insertion of polydioxanone threads, a mini temporal lift, botulinum toxin injections, and zygomatic filler.

The signs and symptoms were suggestive of ischemia, likely due to the compression of the vessels supplying blood to the upper lip, caused by the HA injection. Consequently, the surgeon utilized USG images generated by a skilled sonographer using portable ultrasound equipment (SAEVO - EVUS 5, Alliage S/A Dental Medical Industries, Ribeirão Preto - Brazil). This equipment featured a high-frequency linear probe (7-16 MHz) and a highly sensitive color Doppler.

Using USG, it was clearly observed that the area affected by arterial compression was located in the region of the right upper lip. The filler material impacted the space between the subcutaneous layer and the orbicularis oris muscle. Laterally, the convergence of fibers from the zygomaticus minor, levator labii superioris and ala nasis, and levator labii superioris and levator anguli oris muscles was evident in the region of the modiolus (Fig. 2A). Compression of the branches stemming from the facial artery led to tissue hypoxia, resulting in changes in skin color and the lip mucosa, as depicted in Figure 1.

The facial artery was mapped by evaluating the region of the right upper lip with amplitude Doppler imaging. This technique enabled us to confirm a reduction in blood flow in the superior labial artery (Figs. 2B-C) and the right-sided angular artery (Fig. 2D).

Using amplitude Doppler mode, it was observed that the venous return in the medial corner of the right orbit remained unchanged (Fig. 2E). Additionally, ultrasonography (USG) revealed that the hypoechoic appearance with prominent echoes of the filler material was consistent with HA containing lidocaine, corroborating the information provided by the practitioner who administered the lip

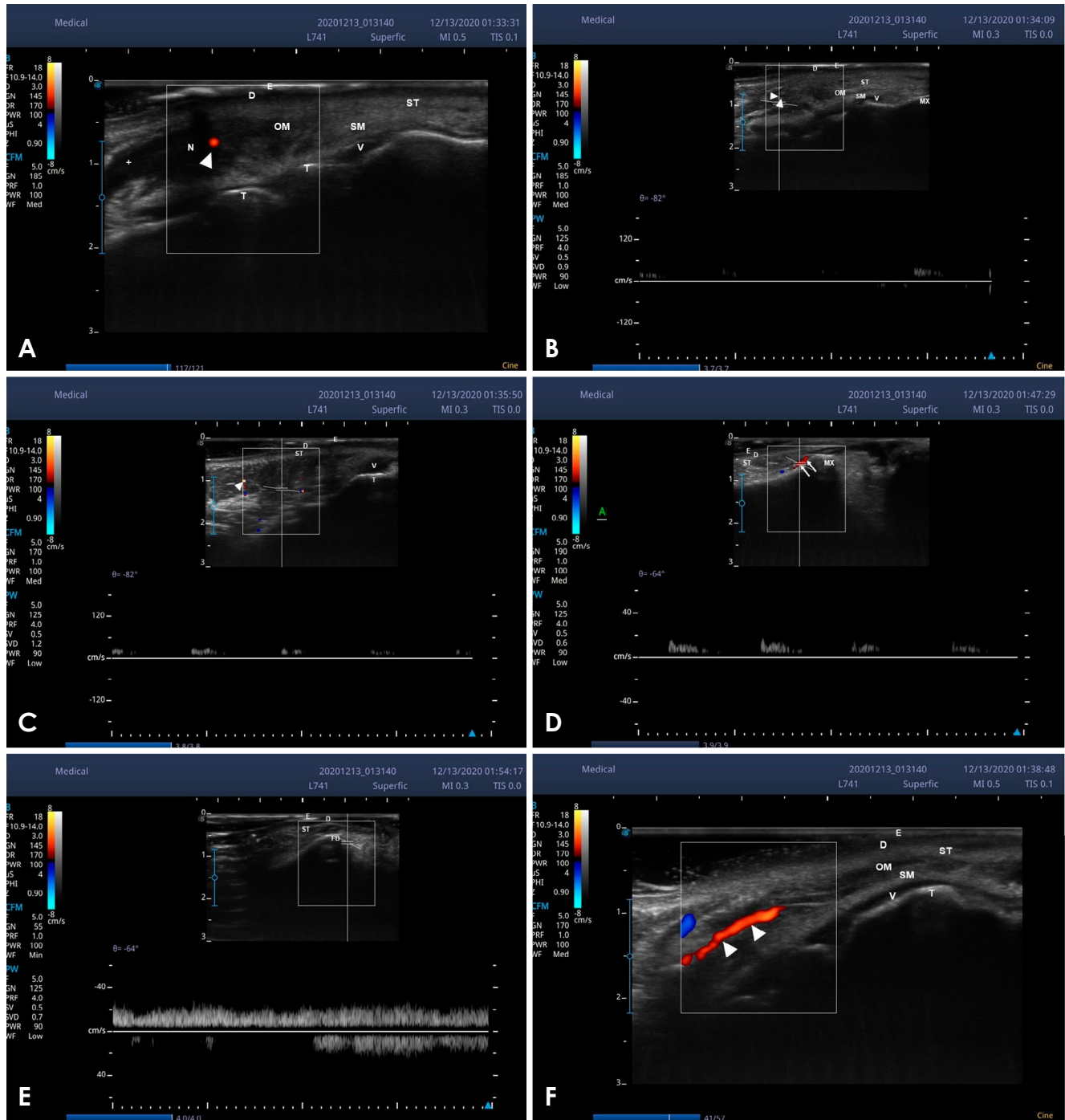


**Fig. 1.** Photograph of the patient's face obtained before ultrasound-guided hyaluronidase application.

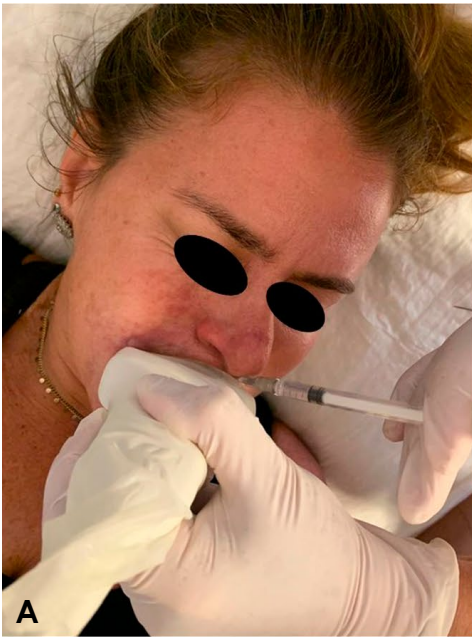filler. The branches of the right ophthalmic artery were examined, and no vascular involvement was detected (data not shown). It is also worth noting that an ultrasonographic image of the left side of the upper lip was obtained for comparison, confirming no alterations in contralateral arterial blood flow (Fig. 2F).

After identifying the affected regions through USG, the next step involved the guided administration of the hyaluronidase enzyme to alleviate the vascular blockage. It is important to note that the date and time of each hyaluronidase application are indicated in the upper right corner of the USG images presented in Figure 3. The treatment spanned 3 hours and consisted of five applications of the hyaluronidase enzyme, totaling 5 mL, administered to the patient's upper lip under USG guidance (Fig. 3A) to degrade HA. The clinician administered the enzyme precisely, using the USG images to avoid excess and prevent damage to surrounding tissues. This approach allowed for real-time visualization of the boundaries of the affected area (Fig. 3B), leading to the successful restoration of normal arterial flow in the region.

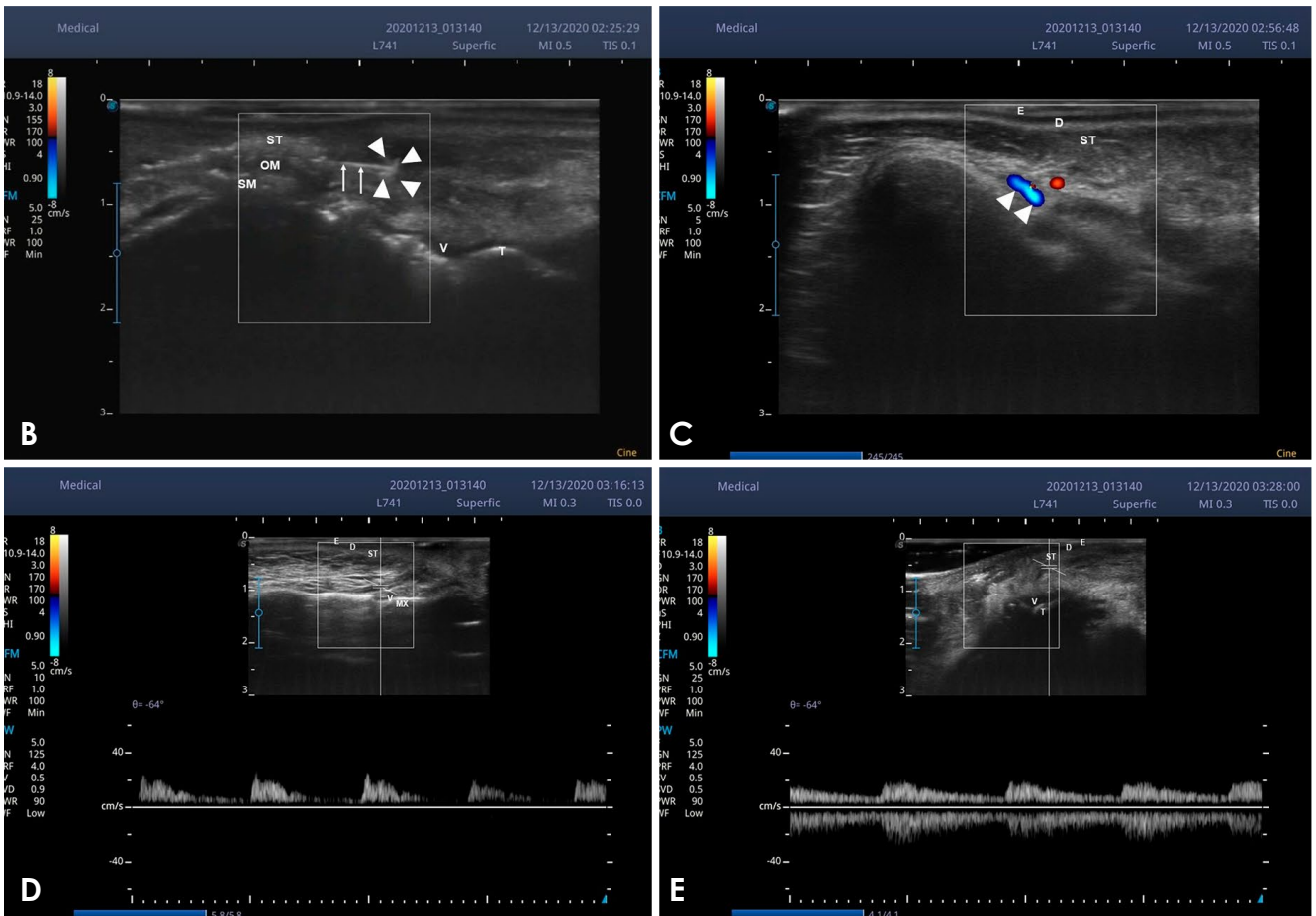
USG with Doppler mode was crucial for determining the precise location, depth, and characteristics of the filling material, as well as for mapping and analyzing the arterial flow in branches of the facial and ophthalmic arteries. The patient was discharged only after complete remission of symptoms and the restoration of arterial flow were confirmed by USG Doppler mode analysis (Figs.



**Fig. 2.** Ultrasonographic images of the patient’s face before applying hyaluronidase. A. Ultrasonographic image of the right upper lip region, with the transducer in a transverse position, demonstrating a hypoechoic area (N) in close proximity to the facial artery (▲) (Doppler). B. Transducer with transverse positioning, showing reduction in blood flow on Doppler. C. Doppler ultrasonographic image of the right upper lip region (nasolabial fold), with the transducer in an oblique position, showing impaired blood flow. D. Doppler ultrasonographic image of the right angular artery with the transducer in a longitudinal position, showing reduction in blood flow. E. Doppler ultrasonographic image of the medial corner region of the orbit on the right side, with the transducer in a longitudinal position, showing unchanged blood flow from the venous return of the angular vein. F. The transducer in a transverse position, showing an image of the upper left lip wherein blood flow is not compromised in the superior labial artery (▲▲). E: epidermis; D: dermis; ST: subcutaneous layer; OM: orbicularis oris muscle; SM: submucosa; V: vestibule; T: teeth; (+): meeting of fibers coming from the zygomaticus major, elevator of the upper lip and elevator of the angle of the mouth muscles; MX: maxilla; ▲▲: superior labial artery; small arrows: angular artery; FB: frontal bone.



**Fig. 3.** Ultrasonography images of the patient’s face during hyaluronidase application. A. The transducer positioned transversely during application of the enzyme. B. Ultrasonographic image of the right upper lip region to visualize the needle (arrows), hyaluronidase (▲: hyperechoic aspect). C. Ultrasonographic image of the right lip commissure region after the application of hyaluronidase. D. Doppler ultrasonographic image of the right upper lip region with the transducer in a transverse position showing the reestablishment of blood flow in the region of the subnasal artery, a branch originating from the superior labial artery, after application of hyaluronidase. E. Doppler ultrasonographic image of the right upper lip region, with the transducer in an oblique position to visualize the reestablishment of blood flow in the area surrounding the superior labial artery after new application of hyaluronidase. E: epidermis; D: dermis; ST: subcutaneous layer; OM: orbicularis oris muscle; SM: submucosa; V: vestibule; T: teeth; ▲▲: labial vessels; MX: maxilla.



3C-E). Additionally, the next day, an improvement in skin color was clinically observed following ultrasound-guided treatment (Fig. 4).

The patient had a positive perception of the treatment

outcome and felt comfortable due to the technical approach used and the elimination of pain.

The patient was monitored daily for 30 days and continued to receive monthly clinical follow-ups, with no fur-

ther complications from the lip fillers. To fully resolve the issue, the patient underwent 10 laser treatment sessions, following the application of hyaluronidase and 10 sessions in a hyperbaric chamber. Additionally, the prescribed medications included clavulanic acid (875 mg, 1 tablet every 12 hours for 15 days), cephalexin (500 mg, 1 tablet every 6 hours for 10 days), somagin (325 mg every 12 hours for 5 days), sildenafil (50 mg every 12 hours for 5 days), and dexamethasone (4 mg every 12 hours for 5 days).

## Discussion

USG guidance made it possible to evaluate the relationship between the HA application site and nearby critical structures, clearly identifying their depth and location.<sup>13</sup> Similarly, Doppler imaging was used to perform vascular mapping, effectively delineating a pattern along the entire length of the facial vessels<sup>10</sup> Subsequently, it was observed that the blood flow pattern in the case under study was altered, corroborating the clinical data gathered during the anamnesis concerning changes in skin color. Thus, the examination revealed that the filler was reducing the flow in the surrounding blood vessels, thereby visually supporting the clinical examination and confirming the diagnosis of vascular compression.<sup>14</sup>

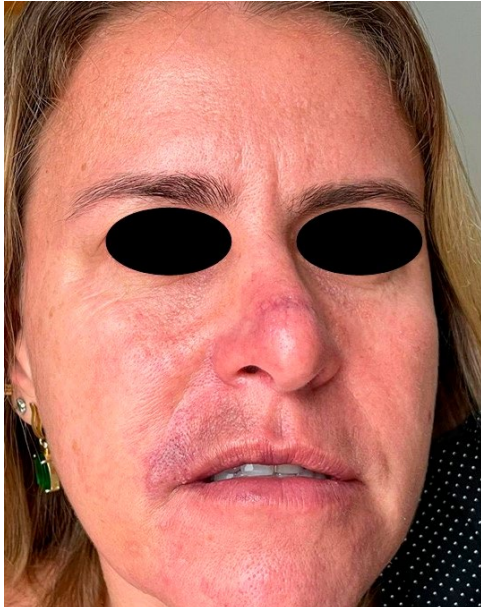According to Schelke et al.,<sup>13</sup> the clinical signs of vascular compression injuries can be mistaken for hematomas. Bruises typically appear a few hours after filler injections, whereas signs of vascular occlusion due to external compression generally become apparent the following day, as observed in the case discussed in this study.<sup>15</sup> Recognizing these subtle diagnostic differences is crucial to ensure timely intervention in cases that require it. Additionally, the literature advises immediately using hyaluronidase in instances of vascular complications from HA injections to prevent tissue necrosis and severe outcomes such as amaurosis.<sup>16</sup> Therefore, a thorough USG evaluation that identifies changes in the vascular area, coupled with the detection of an anechoic deposit (indicative of HA) and altered distal flow, is essential for accurate diagnosis and effective management of such cases, thereby preventing significant aesthetic defects.<sup>17</sup>

According to de Almeida et al.,<sup>18</sup> changes can occur immediately (within 24 hours), early (24 hours to 30 days), or late (after 30 days). In this study, the changes are classified as immediate onset, given that the patient received lip fillers the day before the ultrasound examination was requested. It is important to note that ischemic vascular complications arise from the reduction or obliteration of local blood

flow, leading to tissue hypoxia. The clinical progression may initially manifest as regional whitening, followed by an erythematous-cyanotic appearance, and can advance to bullous lesions within 3 days if blood flow is not restored. This may further develop into crusted lesions and tissue necrosis, typically occurring within 6 days, eventually leading to healing by secondary intention, which could result in significant aesthetic defects.<sup>19,20</sup> It is important to highlight that in the case presented herein, the patient exhibited areas with an erythematous-cyanotic appearance, prompting her to seek professional help due to concerns about both her facial appearance and the associated pain. The prompt intervention, coupled with the patient's proactive concern, undoubtedly played a crucial role in the successful outcome of the treatment.

One of the most alarming complications during a facial filler procedure is amaurosis. In a literature review conducted by Ozturk et al.,<sup>8</sup> 12 cases of amaurosis were reported caused by injections of dermal fillers in the region of the nose, glabella and nasolabial folds. Among them, 6 progressed to permanent blindness. The etiology of this complication is embolization through a material injected into the lumen of a facial vessel, a branch of the external carotid artery, which anastomoses with the ophthalmic artery, a branch of the internal carotid artery. Consequently, the injected material moves under high pressure, causing a retrograde flow into the peripheral vessels toward the ophthalmic arterial vessels, including the central retinal artery. Even in minimal quantities, retinal arterial embolism of iatrogenic origin can occur, particularly because it is a terminal branch with no anastomoses.<sup>8,11,21,22</sup> It is important to note that the lips and perioral region are considered to be at moderate risk for visual complications associated with HA injection.<sup>9</sup> Therefore, it is evident that USG examination plays a crucial role in providing rapid, objective, and effective intervention in cases of altered vascular flow as previously described. Additionally, USG helps in mapping the facial vessels preventively to avoid the severe complications associated with amaurosis.

Furthermore, the sonographer was able to accurately identify the nature of the filler material, as the HA mixed with lidocaine appeared as pseudocystic structures that were hypoechoic with internal echoes, consistent with findings reported in recent scientific literature.<sup>2,23</sup> Delorenzi<sup>20</sup> described a protocol where arteries with altered flow due to HA filler required injections of high concentrations of hyaluronidase, with the amount tailored to the size of the ischemic tissue. This approach yielded excellent clinical outcomes. Following the protocol recommended by the



**Fig. 4.** Photograph of the patient's face 1 day after ultrasound-guided hyaluronidase injection.

aforementioned author, and utilizing USG with Doppler mode, it was possible to administer hyaluronidase directly to the affected site. This allowed for real-time visualization and ensured the precise delivery of the enzyme without affecting the endogenous HA in the surrounding tissues.<sup>7</sup> Simultaneously, Doppler was used to monitor the restoration of normal blood flow. Thus, USG proved beneficial not only during the procedure but also in post-procedure evaluations, where it was employed to assess blood perfusion across the facial area. Additionally, a significant improvement in the appearance of livedo reticularis was observed shortly after the ultrasound-guided injection of hyaluronidase, indicating a typical resolution of vascular issues caused by the filler material.<sup>17</sup> There was also a noted progressive alleviation of painful symptoms following the enzyme treatment.

Lee et al.<sup>24</sup> reported that their clinical guidelines included a facial artery scan prior to the procedure and ultrasound-guided injection. They noted that none of the 80 cases evaluated using this method developed serious complications, such as necrosis or amaurosis.<sup>24</sup> Additionally, the literature described an inflammatory response at a site where polymethylmethacrylate (PMMA) had been previously injected and HA was subsequently administered.<sup>13</sup> Wortsman,<sup>2</sup> Wortsman et al.,<sup>6</sup> Schelke et al.<sup>13</sup> and Urdiales-Gálvez et al.<sup>25</sup> concurred in their findings that prior identification of PMMA using USG could have prevented this complication. They also noted that USG could differ-

entiate between all filler materials, thereby avoiding interactions among them.<sup>2,6,13,25,26</sup> In addition, Schelke et al.<sup>17</sup> demonstrated in 2023 that in 21 cases, rapid intervention guided by USG led to improved treatment outcomes.

Therefore, the effectiveness of using high-frequency USG in facial filling procedures includes the prevention of complications,<sup>2,6,13,25</sup> guidance during the injection (guided procedure)<sup>13,24</sup> and the treatment of adverse effects.<sup>7,17</sup>

It is also important to note other aesthetic procedures in which the incorporation of USG is advantageous.<sup>26-28</sup> Desyatnikova<sup>27</sup> described better aesthetic results and a reduced possibility of complications when filling the temporal region under USG guidance. Kadouch et al.<sup>26</sup> demonstrated the use of USG in lipofilling procedures involving autologous fat injection and found an improvement in the safety profile of the procedure. Beyond that, Crai<sup>28</sup> demonstrated the applicability of USG in measuring the volume of the cheek fat pad prior to bichectomy procedures to determine whether the procedure was indicated. Garcia et al.<sup>29</sup> reported a clinical case where a vascular complication caused by HA injected into the nasolabial fold was resolved by the application of hyaluronidase guided by USG. In this case, the importance of an early diagnosis was reinforced by checking the patient's signs and symptoms and making an assertive decision regarding the clinical approach to be carried out, noting that without immediate intervention, the patient could have faced serious complications.

The literature clearly supports the use of USG for increasing the predictability and safety of minimally invasive aesthetic procedures. Hong,<sup>30</sup> in a narrative review, highlighted the advantages of using USG for botulinum toxin injections. The real-time visualization of the cannula and the anatomical structures ensures precise procedures with a reduced risk of complications. Consequently, USG-guided botulinum toxin injections are particularly beneficial for treating masseter and parotid gland hypertrophy. This is largely due to the anatomical variations in the masseter and the precise placement of the toxin in the parotid glands for managing sialorrhea.<sup>30</sup> Additionally, USG improves the accuracy of botulinum toxin injections into the facial expression muscles, which is crucial for correcting asymmetries, deviations in the smile line, and gummy smiles.<sup>30</sup>

The efficiency of USG assistance in managing the case described, diagnosing, administering treatment with hyaluronidase, and addressing complications following a lip filling procedure with HA is noteworthy. Increasing the routine use of USG in HA injection procedures is likely to improve patient satisfaction and ensure greater safety for

injections performed by professionals.<sup>12,13</sup> By employing USG guidance, it was feasible to administer hyaluronidase decisively, thereby restoring normal blood flow and preserving the local anatomy, resulting in a more predictable and safer approach.

It is therefore recommended to establish a protocol for the use of USG guidance in facial harmonization. This examination provides crucial data that significantly impacts the success of the procedure and the management of any complications.

**Conflicts of Interest:** None

### References

1. Pallagatti S, Sheikh S, Puri N, Mittal A, Singh B. To evaluate the efficacy of ultrasonography compared to clinical diagnosis, radiography and histopathological findings in the diagnosis of maxillofacial swellings. *Eur J Radiol* 2012; 81: 1821-7.
2. Wortsman X. Identification and complications of cosmetic fillers: sonography first. *J Ultrasound Med* 2015; 34: 1163-72.
3. Jaguś D, Skrzypek E, Migda B, Woźniak W, Młosek RK. Usefulness of Doppler sonography in aesthetic medicine. *J Ultrason* 2020; 20: e268-72.
4. Velthuis PJ, Jansen O, Schelke LW, Moon HJ, Kadouch J, Ascher B, et al. A guide to Doppler ultrasound analysis of the face in cosmetic medicine. Part 1: standard positions. *Aesthet Surg J* 2021; 41: NP1621-32.
5. Velthuis PJ, Jansen O, Schelke LW, Moon HJ, Kadouch J, Ascher B, et al. A guide to doppler ultrasound analysis of the face in cosmetic medicine. Part 2: vascular mapping. *Aesthet Surg J* 2021; 41: NP1633-44.
6. Wortsman X, Wortsman J, Orlandi C, Cardenas G, Szazunic I, Jemec GB. Ultrasound detection and identification of cosmetic fillers in the skin. *J Eur Acad Dermatol Venereol* 2012; 26: 292-301.
7. Munia MA, Munia CG, Parada MB, Ben-Hurferraz Parente J, Wolosker N. Doppler ultrasound in the management of vascular complications associated with hyaluronic acid dermal fillers. *J Clin Aesthet Dermatol* 2022; 15: 40-3.
8. Ozturk CN, Li Y, Tung R, Parker L, Piliang MP, Zins JE. Complications following injection of soft-tissue fillers. *Aesthet Surg J* 2013; 33: 862-77.
9. Goodman GJ, Magnusson MR, Callan P, Roberts S, Hart S, McDonald CB, et al. A consensus on minimizing the risk of hyaluronic acid embolic visual loss and suggestions for immediate bedside management. *Aesthet Surg J* 2020; 40: 1009-21.
10. Tucunduva MJ, Tucunduva-Neto R, Saieg M, Costa AL, de Freitas C. Vascular mapping of the face: B-mode and doppler ultrasonography study. *Med Oral Patol Oral Cir Bucal* 2016; 21: e135-41.
11. Tansatit T, Phumyoo T, Jitree B, Sawatwong W, Rungsawang C, Jirasutat N, et al. Ultrasound evaluation of arterial anastomosis of the forehead. *J Cosmet Dermatol* 2018; 17: 1031-6.
12. Lee GS. Use of handheld ultrasound Doppler to prevent complications from intra-arterial injection of dermal fillers: clinical experience. *J Cosmet Dermatol* 2019; 18: 1267-70.
13. Schelke LW, Decates TS, Velthuis PJ. Ultrasound to improve the safety of hyaluronic acid filler treatments. *J Cosmet Dermatol* 2018; 17: 1019-24.
14. Lima VG, Regattieri NA, Pompeu MF, Costa IM. External vascular compression by hyaluronic acid filler documented with high-frequency ultrasound. *J Cosmet Dermatol* 2019; 18: 1629-31.
15. Haneke E. Adverse effects of fillers. *Dermatol Ther* 2019; 32: e12676.
16. Kassir M, Gupta M, Galadari H, Kroumpouzou G, Katsambas A, Lotti T, et al. Complications of botulinum toxin and fillers: a narrative review. *J Cosmet Dermatol* 2020; 19: 570-3.
17. Schelke LW, Velthuis P, Kadouch J, Swift A. Early ultrasound for diagnosis and treatment of vascular adverse events with hyaluronic acid fillers. *J Am Acad Dermatol* 2023; 88: 79-85.
18. de Almeida AT, Banegas R, Boggio R, Bravo B, Braz A, Casabona G, et al. Diagnosis and treatment of hyaluronic acid adverse events: Latin American expert panel consensus recommendations. *Surg Cosmet Dermatol* 2017; 9: 204-13.
19. DeLorenzi C. Complications of injectable fillers, part 2: vascular complications. *Aesthet Surg J* 2014; 34: 584-600.
20. DeLorenzi C. New high dose pulsed hyaluronidase protocol for hyaluronic acid filler vascular adverse events. *Aesthet Surg J* 2017; 37: 814-25.
21. Lazzeri D, Agostini T, Figus M, Nardi M, Pantaloni M, Lazzeri S. Blindness following cosmetic injections of the face. *Plast Reconstr Surg* 2012; 129: 995-1012.
22. Vanaman M, Fabi SG, Carruthers J. Complications in the cosmetic dermatology patient: a review and our experience (part 1). *Dermatol Surg* 2016; 42: 1-11.
23. Rocha LP, de Carvalho Rocha T, de Cássia Carvalho Rocha S, Henrique PV, Manzi FR, E Silva MR. Ultrasonography for long-term evaluation of hyaluronic acid filler in the face: a technical report of 180 days of follow-up. *Imaging Sci Dent* 2020; 50: 175-80.
24. Lee W, Kim JS, Moon HJ, Yang EJ. A safe doppler ultrasound-guided method for nasolabial fold correction with hyaluronic acid filler. *Aesthet Surg J* 2021; 41: NP486-92.
25. Urdiales-Gálvez F, De cabo-Francés FM, Bové I. Ultrasound patterns of different dermal filler materials used in aesthetics. *J Cosmet Dermatol* 2021; 20: 1541-8.
26. Kadouch J, Schelke LW, Swift A. Ultrasound to improve the safety and efficacy of lipofilling of the temples. *Aesthet Surg J* 2021; 41: 603-12.
27. Desyatnikova S. Ultrasound-guided temple filler injection. *Facial Plast Surg Aesthet Med* 2022; 24: 501-3.
28. Cral WG. The importance of ultrasound in excision of the buccal fat pad. *Aesthetic Plast Surg* 2022; 46: 1007-8.
29. Garcia AS, de Souza MBC, de Albergaria Barbosa JR, Canales GDLT, Oliveria RCG, Rizzatti-Barbosa CM. Treatment protocol for tissue necrosis caused by filling with hyaluronic acid. *Int J Health Sci* 2022; 2: 1-10.
30. Hong SO. Cosmetic treatment using botulinum toxin in the oral and maxillofacial area: a narrative review of esthetic techniques. *Toxins (Basel)* 2023; 15: 82.