

Case Report

Clin Shoulder Elbow 2024;27(2):263-266
<https://doi.org/10.5397/cise.2023.00654>

eISSN 2288-8721

Arthroscopic treatment of chronic calcific tendinitis with intraosseous migration: a case report

Jung Uk Kim, Pei Wei Wang

Department of Orthopedic Surgery, Gangseo Nanoori Hospital, Seoul, Korea

We present a case of calcific tendinitis in the shoulder, where calcifications were observed within both the tendon and the adjacent bone. At the time of acute onset, radiographs (including a plain radiograph) and magnetic resonance imaging revealed calcific tendinitis with intraosseous migration. The patient's symptoms did not improve after 5 months of conservative treatment. The patient underwent arthroscopic debridement of the calcific deposits, and the defect was repaired using the double-row repair technique. The patient's symptoms improved 3 months after arthroscopic treatment. We share our unusual experience with arthroscopic debridement in the treatment of chronic calcific tendinitis with intraosseous migration.

Keywords: Chronic calcific tendinitis; Intraosseous migration; Arthroscopic treatment; Calcific deposit removal; Case report

Calcific tendinitis is a prevalent condition characterized by the deposition of calcium hydroxyapatite within a tendon, and it has an incidence rate of up to 3% of the adult population [1]. The supraspinatus tendon is the most frequently affected tendinous site for calcific deposits, followed by the infraspinatus and subscapularis tendons [2]. While intraosseous migration of calcific tendinitis in the greater tuberosity of the humerus is rare, it is of great clinical importance as it may enable differentiation between an infection and a tumorous lesion [1]. Magnetic resonance imaging (MRI) can show cortical erosion, subcortical migration, and perilesional subchondral bone edema in calcific tendinitis with intraosseous migration [3]. However, there is no standard treatment method for chronic calcific tendinitis with intraosseous migration [2,4]. We present an unusual case of chronic calcific tendinitis with intraosseous migration that failed to respond to conservative treatment, along with our experience with arthroscopic management.

CASE REPORT

A 52-year-old, right-handed woman presented with intermittent left shoulder pain for the previous 5 months. The patient did not report any trauma or previous shoulder disorder. The patient had received symptomatic conservative treatment at local hospitals, comprising non-steroidal anti-inflammatory drugs, ultrasound-guided needle aspiration, subacromial steroid injection, and extracorporeal shockwave therapy, but she experienced no remission. Her pain had worsened over the last 2 weeks and was reported as a visual analog scale (VAS) score of 8. During the physical examination, the patient could only achieve limited active forward elevation of 30° due to pain. Her serum tests for C-reactive protein and rheumatoid factor and a complete blood count were all within normal limits.

Plain radiographs revealed a 20-mm amorphous calcified lesion within the supraspinatus tendon insertion area, with sclerot-

Received: July 20, 2023 Revised: October 5, 2023 Accepted: October 14, 2023

Correspondence to: Pei Wei Wang

Department of Orthopedic Surgery, Gangseo Nanoori Hospital, 187 Garogongwon-ro, Gangseo-gu, Seoul 07718, Korea

Tel: +82-2-1688-9797, E-mail: qodnl0810@naver.com, ORCID: <https://orcid.org/0000-0003-4723-4368>

© 2024 Korean Shoulder and Elbow Society.

This is an Open Access article distributed under the terms of the Creative Commons Attribution Non-Commercial License (<http://creativecommons.org/licenses/by-nc/4.0/>) which permits unrestricted non-commercial use, distribution, and reproduction in any medium, provided the original work is properly cited.

ic changes evident at the adjacent subchondral bone of the greater tuberosity (Fig. 1A). MRI showed the presence of a low-signal intensity intratendinous calcification within the supraspinatus tendon, with intraosseous migration to the subchondral bone of the greater tuberosity with adjacent bone marrow edema. There was no evidence of a tear in the rotator cuff tendon or any presence of effusion or synovitis (Fig. 2A-C).

Upon failing to achieve symptomatic relief after conservative management for 5 months, an arthroscopic treatment of calcific tendinitis was performed. The patient was placed in the lateral position under general anesthesia. The surgeon conducted diagnostic glenohumeral arthroscopy through a conventional posterior portal to rule out any significant intra-articular pathological conditions. Afterward, the arthroscope was moved into the subacromial space. Subacromial bursectomy was performed to alleviate pain and enhance the visualization of the calcific deposits. An 18-gauge spinal needle was used to percutaneously probe the inflamed supraspinatus tendon to locate the calcific deposits.

Calcium deposits became visible after the needle pierced the tendon, and they were removed by blunt pressure from the probe

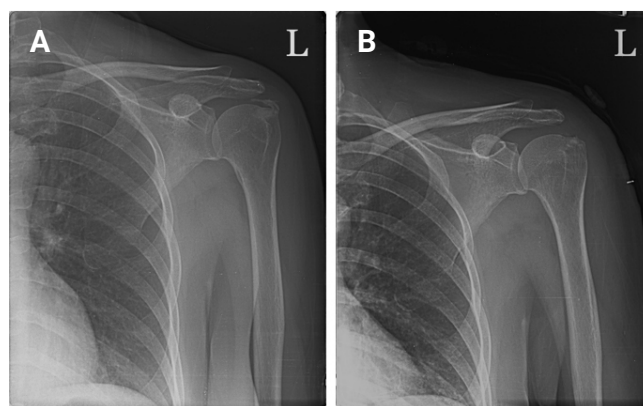


Fig. 1. (A) A preoperative anteroposterior projection of the left shoulder reveals an amorphous calcification within the supraspinatus insertion area of the greater tuberosity. Note the presence of subchondral sclerosis in the greater tuberosity. (B) A postoperative plain radiograph showing near complete removal of calcium deposits.

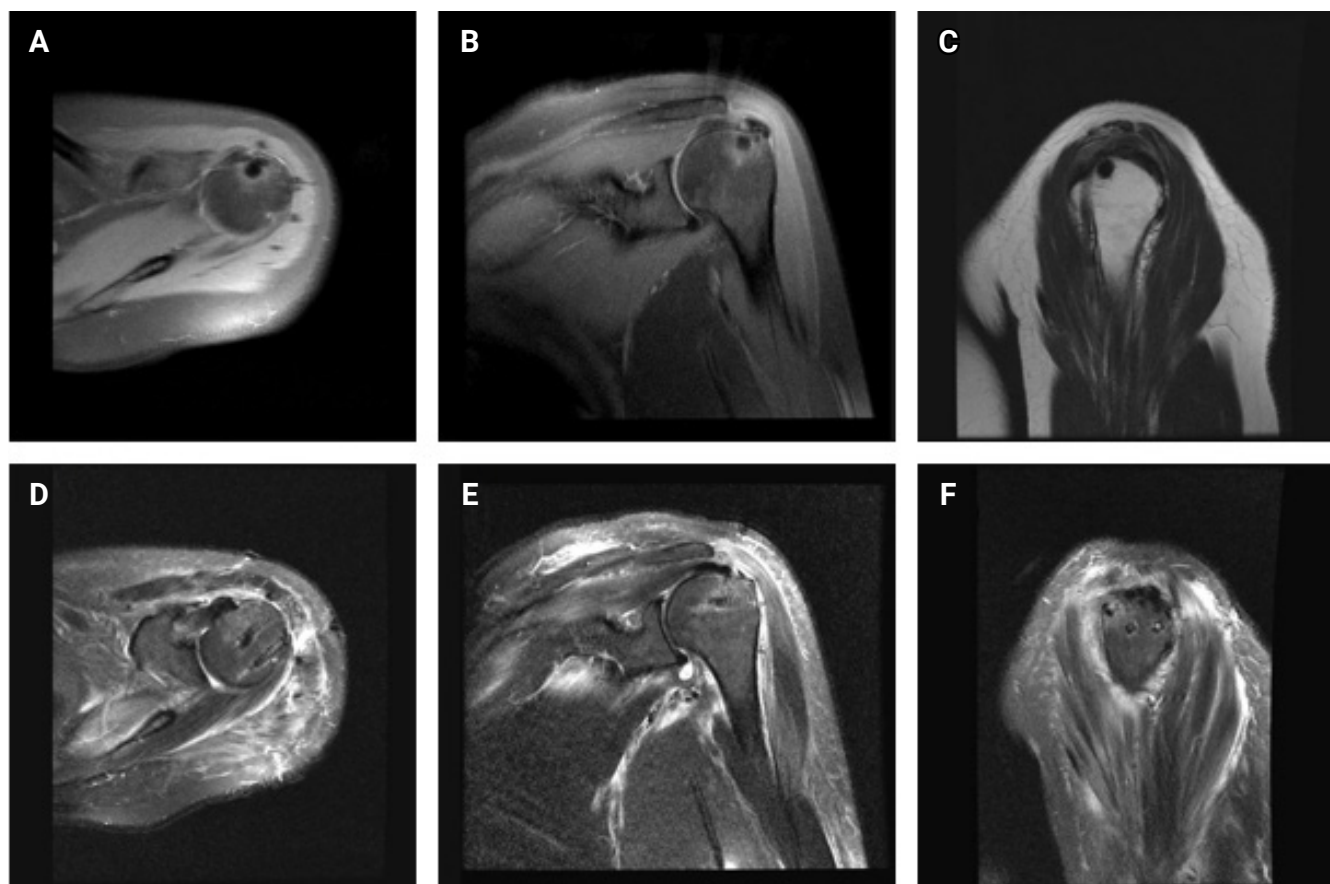


Fig. 2. (A-C) Preoperative magnetic resonance imaging (MRI) of the shoulder is shown in the axial, coronal, and sagittal views, respectively, illustrating low signal calcification at the supraspinatus and intraosseous migration to the greater tuberosity with perilesional subchondral bone edema. There is no evidence of a tear in the rotator cuff tendon or any presence of effusion or synovitis. (D-F) Postoperative MRI revealing no evidence of calcific deposits in the supraspinatus tendon or in the greater tuberosity.

and a shaver (Fig. 3A). Following tendon debridement, the site of intraosseous migration of the calcific deposits was identified using the probe. A small entry point was created, and the intraosseous calcific deposits were visualized through the arthroscopic opening and extracted from the osseous cavity. The cavity wall was curetted to end the surgery (Fig. 3B).

An approximately 10×15-mm tendon defect was observed following the debridement. A 2.8-mm Y-knot, all-suture anchor (Conmed Linvatec) containing two No. 2 braided UHMWPE sutures was placed just medial to the intraosseous lesion of the greater tuberosity, and two mattress sutures were used to tie the medial row. The lateral row anchor was placed distal to the greater tuberosity with a knotless 4.75-mm BioComposite SwiveLock anchor (Arthrex Inc.).

Following surgery, a plain radiograph and MRI were obtained, and the calcific lesions were observed to be nearly completely removed (Figs. 1B and 2D-F). The patient completed a postoperative rehabilitation program for rotator cuff repair after the surgery. The routine postoperative exercises were performed following 6 weeks of abduction brace wear. At the 3-month follow-up visit, the patient reported notable improvements, with a reduction in pain to a VAS score of 2 and complete restoration of her range of motion.

Informed consent was obtained from the patient who participated in this case report. Owing to the retrospective design of this study, approval of the Institutional Review Board was waived (No. NR-IRB 2023-007).

DISCUSSION

On rare occasions, patients may present with intraosseous migration of calcific deposits [1,5]. Although the prevalence of osseous migration has not been reported, Flemming et al. [1] reported 50 cases of calcific tendinitis, of which five showed osseous migration to the greater tuberosity. The inflammation caused by calcific tendinitis results in cortical erosion of the greater tuberosity, which leads to intraosseous migration and presents as a high signal on MRI in the surrounding bone marrow [3]. Our patient's preoperative simple radiograph revealed amorphous calcifications in the supraspinatus insertion and subchondral sclerosis within the greater tuberosity. On MRI, low-signal calcifications were detected at the supraspinatus, and intraosseous migration toward the greater tuberosity and perilesional subchondral bone edema were also noted. As reported by Jain et al., recognizing continuity between osseous lesions and calcific tendinitis is essential for accurate differential diagnosis from tumors and infections [6].

Most cases of symptomatic calcific tendinitis can be successfully treated conservatively with satisfactory clinical outcomes. When symptoms persist after 6 months of conservative treatment, the condition is referred to as chronic calcific tendinitis. Currently, ultrasound-guided needle aspiration is considered the best initial treatment method for chronic calcific tendinitis because it is less invasive than arthroscopic management. However, several articles have suggested that ultrasound-guided needle aspiration may not be sufficient in cases of intraosseous migration

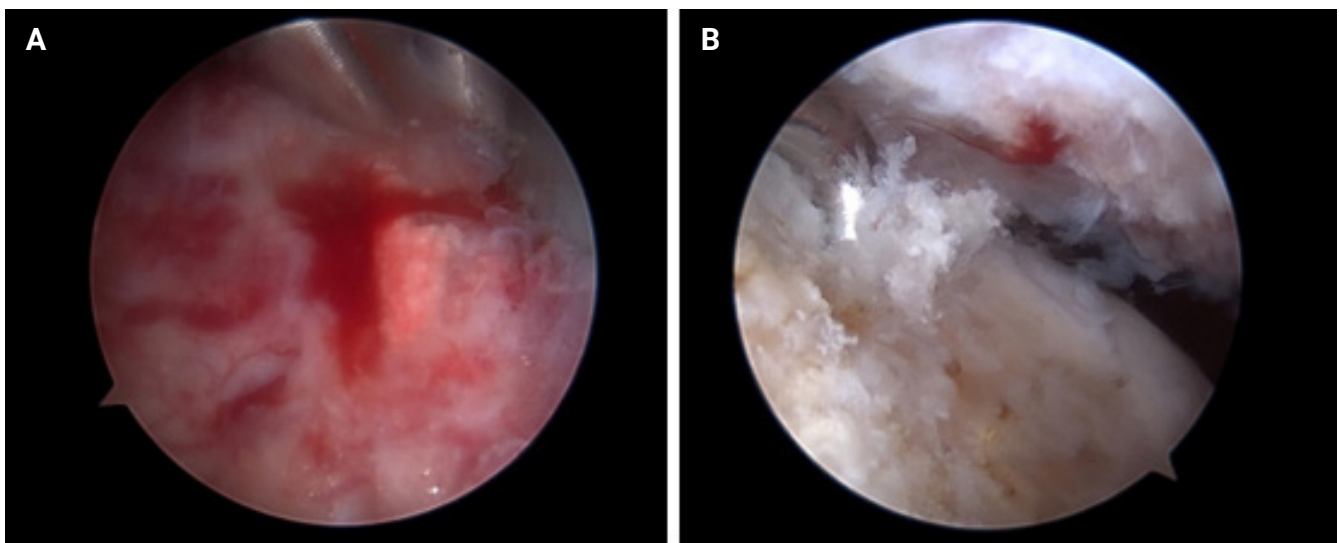


Fig. 3. (A) Arthroscopic view showing calcification at the insertion site of the supraspinatus tendon. Following the removal of the calcific deposits, a defect of 10×15 mm was visible in the footprint. (B) The intraosseous calcification was removed using a curette.

[2,4]. Our patient also failed to demonstrate remission of shoulder pain after ultrasound-guided needle aspiration and injection of subacromial steroids. Seyahi and Demirhan [4] reported that arthroscopic debridement of intraosseous calcific deposits is equally as effective and safe as arthroscopic removal of intratendinous deposits alone. Three months after surgery, our patient reported improvement in her symptoms following surgical removal of the intraosseous calcific deposits and repair of the supraspinatus tendon.

Debate exists over whether to completely remove calcific deposits during surgery, as well as whether to repair rotator cuff lesions caused by removal of calcium deposits [7,8]. Porcellini et al. [5] found a positive correlation between residual calcium deposits and persistent pain and recommended that these deposits be fully removed. In addition, significant improvement in clinical results was reported for the repaired group compared with the unrepaired group when the rotator cuff defect size was >1 cm. Our patient had an approximately 10 × 15-mm tendon defect after removal of the calcific deposits, and the supraspinatus tendon was repaired. In a medium- and long-term follow-up study by Pang et al. [9], rotator cuff repair offered better clinical and structural results than debridement alone. However, the results of Lee and Shin [10] did not seem to be influenced by concomitant repair of the rotator cuff or the size of the residual calcifications. The development of a gold standard guideline will require further research.

In conclusion, arthroscopic treatment can be beneficial for chronic calcific tendinitis with intraosseous migration that does not resolve with conservative treatment.

NOTES

ORCID

Jung Uk Kim <https://orcid.org/0009-0005-7004-8039>
 Pei Wei Wang <https://orcid.org/0000-0003-4723-4368>

Author contributions

Conceptualization: PWW. Visualization: PWW. Writing – original draft: PWW. Writing – review & editing: PWW, JUK.

Conflict of interest

None.

Funding

None.

Data availability

None.

Acknowledgments

None.

REFERENCES

1. Flemming DJ, Murphey MD, Shekitka KM, Temple HT, Jelinek JJ, Kransdorf MJ. Osseous involvement in calcific tendinitis: a retrospective review of 50 cases. *AJR Am J Roentgenol* 2003; 181:965–72.
2. Klontzas ME, Vassalou EE, Karantanas AH. Calcific tendinopathy of the shoulder with intraosseous extension: outcomes of ultrasound-guided percutaneous irrigation. *Skeletal Radiol* 2017;46:201–8.
3. Malghem J, Omoumi P, Lecouvet F, Vande Berg B. Intraosseous migration of tendinous calcifications: cortical erosions, subcortical migration and extensive intramedullary diffusion, a SIMS series. *Skeletal Radiol* 2015;44:1403–12.
4. Seyahi A, Demirhan M. Arthroscopic removal of intraosseous and intratendinous deposits in calcifying tendinitis of the rotator cuff. *Arthroscopy* 2009;25:590–6.
5. Porcellini G, Paladini P, Campi F, Paganelli M. Arthroscopic treatment of calcifying tendinitis of the shoulder: clinical and ultrasonographic follow-up findings at two to five years. *J Shoulder Elbow Surg* 2004;13:503–8.
6. Jain TP, Damiani M. Calcific tendinosis of rotator cuff with intraosseous extension. *J Med Imaging Radiat Oncol* 2020;64:250–1.
7. Maier D, Jaeger M, Izadpanah K, Bornebusch L, Suedkamp NP, Ogon P. Rotator cuff preservation in arthroscopic treatment of calcific tendinitis. *Arthroscopy* 2013;29:824–31.
8. Yoo JC, Park WH, Koh KH, Kim SM. Arthroscopic treatment of chronic calcific tendinitis with complete removal and rotator cuff tendon repair. *Knee Surg Sports Traumatol Arthrosc* 2010;18:1694–9.
9. Pang L, Li T, Li Y, et al. Combined arthroscopic rotator cuff repair leads to better clinical outcomes than isolated removal of calcific deposits for shoulder calcific tendinitis: a 2- to 5-year follow-up study. *Front Surg* 2022;9:912779.
10. Lee TK, Shin SJ. Functional recovery of the shoulder after arthroscopic treatment for chronic calcific tendinitis. *Clin Shoulder Elb* 2018;21:75–81.