

Review

Clin Shoulder Elbow 2024;27(2):247-253
<https://doi.org/10.5397/cise.2023.00640>

Acromioclavicular joint dislocation and concomitant labral lesions: a systematic review

Jad Mansour¹, Joseph E Nassar², Michel Estephan¹, Karl Boulos³, Mohammad Daher⁴

¹Division of Orthopedic Surgery and Sports Medicine, McGill University Health Centre, Montreal, QC, Canada

²American University of Beirut, Beirut, Lebanon

³Department of Orthopedic Surgery, Lebanese American University Medical Center-Rizk Hospital, Beirut, Lebanon

⁴Department of Orthopedic Surgery, Hôtel Dieu de France, Beirut, Lebanon

Acromioclavicular (AC) joint dislocations frequently co-occur with intra-articular glenohumeral pathologies. Few comprehensive studies have focused on labral tears specifically associated with AC joint trauma. This systematic review will address this gap. A comprehensive electronic search was conducted across PubMed, Cochrane Library, and Google Scholar (pages 1–20) spanning from 1976 to May 19, 2023. Seven studies met the inclusion criteria for this systematic review, consisting of three retrospective studies and four case series. These studies collectively involved 1,044 patients, of whom 282 had concomitant labral lesions. The pooled prevalence of intra-articular labral injuries associated with acute AC joint dislocation was 27%. The prevalence of these labral lesions varied significantly between studies, ranging from 13.9% to 84.0% of patients, depending on the study and the grade of AC joint dislocation. Various types of labral tears were reported, with superior labrum anterior to posterior (SLAP) lesions being the most common. The prevalence of SLAP lesions ranged from 7.2% to 77.4%, with higher grades of AC joint dislocations often associated with a higher prevalence of SLAP tears. Moreover, grade V dislocations exhibited a complete correlation with SLAP tears. The studies yielded contradictory findings regarding older age and higher grades of AC joint dislocation as risk factors for concurrent labral lesions. This review underscores the frequent association between labral lesions and AC joint dislocations, particularly in cases of lower-grade injuries. Notably, SLAP lesions emerged as the predominant type of labral tear.

Keywords: Acromioclavicular joint dislocation; Superior labrum anterior to posterior; Labral tear; Labrum

INTRODUCTION

The acromioclavicular (AC) joint is a diarthrodial joint in the shoulder between the distal clavicle and the acromion. The AC joint is stabilized by muscular and ligamentous structures including the deltoid and trapezoid muscles and the capsular, AC, and coracoclavicular ligaments [1]. AC joint separation is common among athletes and occurs following a traumatic injury to the shoulder [2]. This injury is roughly 10 times more frequent in men than in women [3]. AC joint separation accounts for 9% of

all shoulder injuries but 40% of all sports-related injuries [4,5]. The mechanism of injury is typically a fall or a direct blow to the shoulder with the arm adducted [6]. Many classifications have been proposed to describe AC joint dislocations. The Cadenat classification was published in 1917, followed by the Tossy classification in 1963 and the Rockwood classification in 1984 [7,8]. The Rockwood classification uses plain radiographs to categorize AC joint dislocations into six grades of severity and nature of ligament injuries and joint dislocation. The grades range from mild sprain in grade I to complex ligament rupture and dislocation in

Received: July 19, 2023 Revised: September 13, 2023 Accepted: September 24, 2023

Correspondence to: Jad Mansour

Division of Orthopedic Surgery and Sports Medicine, McGill University Health Centre, 845 Sherbrooke St, Montréal, QC H3A 0G4, Canada

E-mail: Jad.mansour09@gmail.com, ORCID: <https://orcid.org/0000-0002-7147-5076>

© 2024 Korean Shoulder and Elbow Society.

This is an Open Access article distributed under the terms of the Creative Commons Attribution Non-Commercial License (<http://creativecommons.org/licenses/by-nc/4.0/>) which permits unrestricted non-commercial use, distribution, and reproduction in any medium, provided the original work is properly cited.

grades IV to VI [3]. The higher is the classification of the injury, the worse is the prognosis.

Recent reports show that intra-articular glenohumeral pathologies (IAPs) often accompany low-grade AC joint dislocations, which challenges the notion that they are only seen in high-grade injuries [6]. Despite this, there is a lack of comprehensive studies on the occurrence of labral tears alongside AC joint dislocations. To fill this gap, our systematic review sought to accomplish two main objectives. First, we evaluated the prevalence of labral tears in AC joint dislocations. Second, we attempted to identify risk factors that may contribute to this association, such as age and grade of AC joint dislocation. We hypothesize that labral tears are a commonly overlooked pathology that may frequently co-occur in both low- and high-grade AC joint dislocations. We also suspect that certain risk factors make this co-occurrence more likely.

METHODS

Search Strategy

The Preferred Reporting Items for Systematic Reviews and Meta-Analyses (PRISMA) standards were followed in this investigation to study the association between AC joint dislocation and labral tears. Searches in PubMed, Cochrane, and Google Scholar (page 1–20) were conducted between 1976 and May 19, 2023, to identify qualified papers. A search query was formulated utilizing Boolean operators by combining MeSH (Medical Subject Headings) terms and keywords “Acromioclavicular” OR “AC” AND “labrum” OR “labral” OR “gleno*.” The literature search was complemented by examining reference lists from selected papers. Both title and abstract screening, as well as full-text screening, were independently conducted by two researchers (MD and JEN). Any discrepancies between the two researchers were resolved by consultation with a third investigator (JM). The PRISMA flowchart provides a summarized overview of the article selection process (Fig. 1).

The inclusion criteria were as follows: (1) randomized controlled trials, prospective clinical trials, retrospective studies, and case series and (2) studies where patients had both AC joint dislocation and labral tears. Studies with the following characteristics were excluded from this study: (1) case reports, narrative or systematic reviews, theoretical research, conference reports, expert comments, and economic analyses and (2) studies assessing AC joint degeneration rather than dislocation.

Data Extraction

Data extraction from the selected studies was also performed in-

dependently by two reviewers (MD and JEN) and comprised two components. The initial part encompassed essential details such as author names, publication year, journal information, study design, sample size, and potential biases in each study. The second component focused on the prevalence of the investigated relationship and its potential determinants, particularly age and AC joint dislocation grades. Any discrepancies between the investigators were resolved through discussion.

Risk of Bias Assessment

Two authors (MD and JM) independently assessed the risk of bias using the ROBINS-I tool for non-randomized studies [9]. Studies that had a critical risk of bias were excluded (Table 1) [1,2,6,10-13].

RESULTS

Characteristics of the Included Studies

Seven studies [1,2,6,10-13] met the inclusion criteria for this systematic review, comprising four case series and three retrospective studies. Overall, these studies included 1,044 patients, among whom 282 exhibited concomitant labral lesions (Table 2).

Prevalence of the Association

Pauly et al. [11] conducted a level IV, case series, prognostic study in which they evaluated the prevalence of glenohumeral injuries concomitant with acute grade III or V AC joint dislocations. Of 125 patients, 38 (30.4%) had glenohumeral pathology in addition

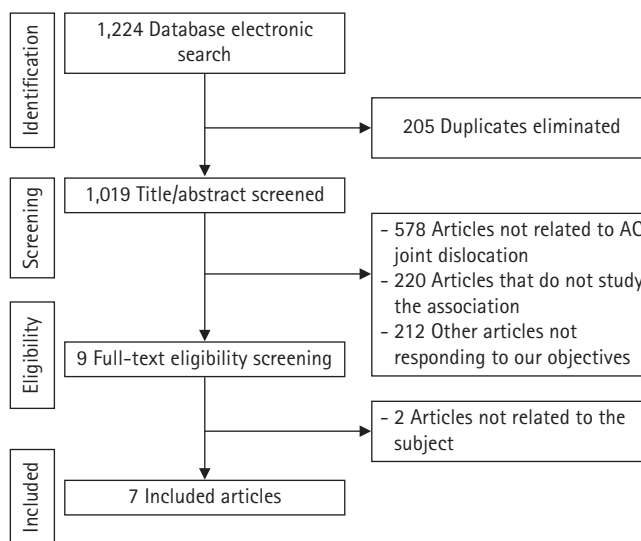


Fig. 1. Preferred Reporting Items for Systematic Reviews and Meta-Analyses (PRISMA) flowchart for article selection. AC: acromioclavicular.

to their AC joint dislocation [11]. Nine of the 38 patients suffered acute injuries (7.2%) along with the AC joint dislocation, including a superior labrum anterior to posterior (SLAP) type I lesion in one patient and a posterior labral tear in another. Eighteen patients developed degenerative glenohumeral pathologies, among whom five had an SLAP I tear and one had a SLAP III tear [11]. The remaining 11 patients were placed in the intermediate concomitant glenohumeral injuries group due to the unclear rela-

tionship between their injury and AC joint dislocation; none of the injuries in this group was a labral tear [11].

Another level IV case series study by Shah et al. [6] enrolled 62 patients with acute AC joint separation. A concomitant IAP was diagnosed in 48 patients (77.4%) using magnetic resonance arthrography (MRA); these pathologies included SLAP lesions (72.6%) and tears of the anterior (24.2%) and posterior labrum (4.8%). The SLAP tears varied in type and prevalence, with type

Table 1. Bias assessment of the included studies

Study	Confounding bias	Selection bias	Classification bias	Bias due to deviation from interventions	Bias due to missing data
Pauly et al. (2009) [10]	Low risk	Low risk	Low risk	Low risk	Low risk
Pauly et al. (2013) [11]	Low risk	Low risk	Low risk	Low risk	Low risk
Shah et al. (2020) [6]	Low risk	Low risk	Low risk	Low risk	Low risk
Tischer et al. (2009) [2]	Low risk	Low risk	Low risk	Low risk	Low risk
Ruiz Ibán et al. (2019) [12]	Low risk	Low risk	Low risk	Low risk	Low risk
Jensen et al. (2017) [13]	Low risk	Low risk	Low risk	Low risk	Low risk
Markel et al. (2017) [1]	Low risk	Low risk	Low risk	Low risk	Low risk

Table 2. Main characteristics and findings of the included studies

Study	Methods	Participants	Acromioclavicular joint injury	Associated labral pathologies	Diagnosis method
Pauly et al. (2009) [10]	Case series	40	3 Rockwood III 3 Rockwood IV 34 Rockwood V	2 SLAP II tears 1 SLAP IV tear	Arthroscopy
Pauly et al. (2013) [11]	Case series	125	6 Rockwood II 119 Rockwood V	6 SLAP I tears 1 SLAP III tear 1 Posterior labral tear	Arthroscopy
Shah et al. (2020) [6]	Case series	62	10 Rockwood I 29 Rockwood II 16 Rockwood III 7 Rockwood IV	14 SLAP I tears 30 SLAP II tears 1 SLAP III tear 15 Anterior labral tears 3 Posterior labral tears	Magnetic resonance arthrography arthroscopy
Tischer et al. (2009) [2]	Case series	77	5 Rockwood III 30 Rockwood IV 42 Rockwood V	3 SLAP I tears 2 SLAP II tears 3 SLAP III tear 3 SLAP IV tears	Arthroscopy
Ruiz Ibán et al. (2019) [12]	Retrospective study	201	110 Rockwood III 34 Rockwood IV 56 Rockwood V 1 Rockwood VI	2 SLAP I tears 4 SLAP II tears 6 Anteroinferior labral lesions 3 Anterior labral lesions 1 Posteroinferior labral lesion	Arthroscopy
Jensen et al. (2017) [13]	Retrospective study	376	186 Rockwood III 190 Rockwood V	60 SLAP I tears 20 SLAP II (or more) tears 73 Labral lesions (Bankart lesions, posterior Bankart lesions, labral fraying)	Arthroscopy
Markel et al. (2017) [1]	Retrospective study	163	60 Rockwood III 6 Rockwood IV 97 Rockwood V	28 SLAP tears	Arthroscopy

SLAP: superior labrum anterior to posterior.

1 constituting 31.1% of lesions, type 2 66.7%, and type 3 2.2%. Furthermore, four of the 14 patients with SLAP 1 tears presented with a second labral tear (2 anterior, 2 posterior) [6]. Similarly, the incidence of concomitant IAP in patients with Rockwood grades III through V AC joint dislocations was identified in a case series conducted by Tischer et al. [2]. The study comprised 77 patients, of whom 14 (18.2%) had intra-articular injuries identified alongside the AC joint dislocation. Eleven of these 14 patients had SLAP tears, with three being type 1, two type 2, three type 3, and three type 4 [2].

In a non-randomized prospective case series conducted by Pauly et al. [10], the prevalence of concomitant IAPs was investigated in patients treated arthroscopically for Rockwood grades III, IV, and V. The study included 40 patients, of whom six sustained traumatic intra-articular lesions (15%). Among them, two patients had a type II SLAP lesion, and one had a type IV SLAP lesion. Moreover, hemarthrosis was absent in SLAP tears, which is not the case with rotator cuff tears [10]. Ruiz Ibán et al. [12] conducted a retrospective observational multicenter study to assess the prevalence of IAPs concomitant with acute AC joint separations of Rockwood grades III, IV, V, and VI. Among the 201 patients enrolled in their study, 28 (13.9%) had accompanying intra-articular lesions with their AC joint injury (ACJI). Of these lesions, 16 were of labral origin, six anteroinferior labral lesions, three anterior labral lesions, one posteroinferior labral lesion, four type II SLAP tears, and two type I SLAP tears [12].

Additionally, in a retrospective study led by Jensen et al. [13], there was increased risk of IAPs concomitant with ACJIs grade III or V. A total of 376 patients was included in the study sample, of whom 229 were defined as having an acute ACJI (0–21 days after trauma) and 147 patients as having chronic ACJI (>21 days after trauma) [13]. Among these 376 patients, 317 (84%) had concomitant IAPs and 201 (53%) had at least one additional glenohumeral pathology [13]. Labral lesions were seen in 73 patients, SLAP I lesions in 60, and SLAP II lesions or higher in 20.

Furthermore, in a retrospective study conducted by Markel et al. [1], the incidences of concomitant IAP in patients with Rockwood grades III, IV, and V AC joint dislocations were identified. The study included a total of 163 patients in whom 28 (17.2%) had an associated SLAP tear [1]. The data highlight a significant but variable occurrence of IAPs in AC joint dislocations. The pooled prevalence of intra-articular labral injuries associated with acute AC joint dislocation was 27% (including 282 labral injuries in 1,044 patients with acute AC joint dislocations). This variation is especially pronounced when considering the specific grade of ACJI. The prevalence of intra-articular labral injuries associated with AC joint dislocation ranged from 13.9% to 84.0%

depending on the study and the grade of AC joint dislocation. Notably, SLAP lesions were frequently identified as the predominant type of labral tear. The prevalence of SLAP tears in patients with AC joint dislocations also varied across these studies depending on the grade of ACJI. The prevalence ranged from 7.2% to 77.4%, with higher grades of AC joint dislocations often associated with a higher prevalence of SLAP tears. Consequently, there is a clear need for a comprehensive understanding of IAP prevalence that accounts for the ACJI grade, which can aid in refining the diagnostic and treatment strategies for ACJIs.

Possible Risk Factors

Tischer et al. [2] found that no SLAP tears were present in cases of Rockwood grade III AC joint separation, and only three presented with Rockwood IV separations. The remaining eight patients with SLAP tears had a grade V AC joint dislocation. However, Pauly et al. [11] found no differences in the frequency or type of concomitant IAP associated with the AC joint separation across the Rockwood grades (III, IV and V). Moreover, Markel et al. [1] showed in a subgroup analysis that there is no difference concerning the etiology, type, or frequency of concomitant injuries during AC-separation by sex or Rockwood grade.

The incidence of IAPs in AC joint dislocations varied across Rockwood grades, with SLAP tears primarily associated with grade V dislocations. Every case of grade V dislocation (100%) presented with SLAP tears. In contrast, there were no significant differences in the frequency or type of IAP among Rockwood grades III, IV, and V. Furthermore, patients suffering from a SLAP tear alongside their AC joint separation were, on average, older than the average age of the studied group, although the trend was not statistically significant (42.1 vs. 35.5 years, $P=0.58$) [2]. However, neither Shah et al. [6] nor Ruiz Ibán et al. [12] demonstrated a significant association between age and the prevalence of concomitant labral tears ($P=0.36$ from Shah et al. [6]). The analysis of risk factors of IAPs in AC joint dislocations provides valuable insights into patient demographics and injury patterns. However, studies did not find significant differences in the prevalence of labral tears by age. This finding highlights the need for further research to establish a clearer understanding of these risk factors and their clinical implications [2,6,12].

DISCUSSION

The prevalence of concomitant labral injuries and AC joint dislocation was approximately 27%. This prevalent association may be explained by the shared mechanism of injury in these two entities. Direct or indirect trauma is the most common cause of AC-

joint separations, which often result from a fall, accident, or direct blow to the upper extremity with scapular depression [6]. Alternatively, an indirect injury can cause AC-joint separation because impact on the adducted hand or elbow drives the humeral head into the acromion [14]. These same mechanisms of injury can also damage active or passive stabilizers, such as muscle attachments, ligaments, labrum, and bony or cartilaginous structures. Similar mechanisms may lead to compression or traction injuries (in the case of traumatic SLAP lesions), which are frequently caused by a fall to the abducted or flexed arm [15-17]. These phenomena can explain the association between ACJIs and labral lesions.

Furthermore, Clavert et al. [18] demonstrated in a biomechanical study that SLAP type II lesions occurred in every simulated fall onto outstretched arms. In that study, a customized shoulder testing device that can imitate muscular stresses was attached to a servohydraulic testing system and used on 10 cadaveric shoulders to simulate a forward or backward fall [18]. Five SLAP lesions were discovered in the five shoulders used to simulate a forward fall. In contrast, only two SLAP lesions were identified in the five shoulders that were used to simulate backward falls. Shearing forces appeared to play a significant role in the development of this injury [18].

AC-joint reconstruction is performed solely through an all-arthroscopic trans-articular approach, and diagnostic shoulder arthroscopy is also conducted in these cases. However, for surgeons who use an open approach for AC-joint repair, preoperative MRI scans may be useful to determine which patients should undergo arthroscopy before the open procedure. For instance, Shah et al. [6] employed MRA, which has a reported sensitivity ranging from 89% to 100%, specificity ranging from 69% to 91%, and accuracy ranging from 74% to 92% for the detection of labral/SLAP lesions. Therefore, MRA may be an important diagnostic modality that clinicians should consider when it is clinically available [19-21]. Although an acute physical examination may be unreliable, routine use of MRA in the setting of acute AC joint separation may not be fiscally feasible and should be reserved for cases in which non-operative management has failed.

As for possible risk factors, the findings are still contradictory and inconclusive. Shah et al. [6] found no significant age difference between patients with and without concomitant labral pathologies. This was also demonstrated by Ruiz Ibán et al. [12] and Tischer et al. [2], who showed that the prevalence of associated lesions was not correlated with the subjects' sporting activity level, work site functional requirements, or age. Furthermore, Markel et al. [1] and Pauly et al. [11] did not find any difference

in the frequency of associated labral lesions between the different Rockwood types. However, according to Tischer et al. [2], there is a greater incidence of SLAP lesions in cases of Rockwood type V than there is in milder forms of AC joint instability.

Clinicians face several challenges when analyzing the association between AC joint dislocation and intraarticular pathologies. First, it is difficult to differentiate between pre-existing, asymptomatic labral lesions and those that were caused by the same trauma that caused the ACJI [11,22]. In fact, several studies have revealed that previous injuries or overuse may result in asymptomatic findings that can lead to unnecessary treatments [23-25]. Nevertheless, Pauly et al. [11] found that only a small proportion of IAPs (14.4%) in high-grade AC separation cases were unrelated to recent trauma based on the tissue appearance during arthroscopic surgery. This problem is even more prevalent in low grade AC joint dislocations. According to Mouhsine et al. [26], approximately 27% of grade 1 and 2 AC separation cases treated nonoperatively required additional surgery. Another study by Petri et al. [27] showed that more than 65% of patients who failed nonoperative management of grade 3 AC separation had intra-articular pathologies (IAPs) identified during eventual operative management. Since nonsurgical treatment is the primary method of managing low-grade AC joint separation, there is limited literature on its associated pathologies [1]. Second conducting a thorough examination of an acute AC separation can be difficult because it requires painful restriction of shoulder motion and strength. In addition, the clinical tests for SLAP tears are similar to those used for AC separation [6]. Furthermore, it is currently uncertain whether repair is necessary for these injuries, such as partial tears of labral structures, which may heal without surgery. Additionally, there is a lack of data on revisions after failed AC-joint repair due to overlooked intra-articular pathologies that may be due to the injury but are not problematic enough to require revision surgery [10]. However, ongoing shoulder pain after successful AC-joint repair may be caused by other injuries. It is the surgeon's responsibility to identify and treat these accompanying injuries [10].

This study has several limitations. For instance, there was a small number of included studies despite the extensive search method used across three databases. Furthermore, the inclusion and exclusion criteria for patients were different. The data used for the analysis were pooled, and the individual patient data were unavailable, which could have limited comprehensive analyses. Regardless, this was the first systematic review studying the prevalence of the association between acute AC joint dislocation and labral tears.

CONCLUSIONS

Our findings shed light on the intricate relationship between labral lesions and AC joint dislocations, which have a prevalence of approximately 27%. Notably, SLAP lesions emerged as the predominant type of labral tear and exhibited a grade-dependent pattern. Higher-grade AC joint dislocations are often associated with a higher prevalence of these tears. However, it is unknown whether these labral injuries were caused by the AC injury itself, or if they were present prior to the dislocation. Therefore, further high-quality research is warranted to clarify this prevalent association.

NOTES

ORCID

Jad Mansour <https://orcid.org/0000-0002-7147-5076>
 Mohammad Daher <https://orcid.org/0000-0002-9256-9952>

Author contributions

Data curation: JM, JEN, MD. Investigation: ME. Writing – original draft: JM, JEN, MD. Writing – review & editing: JM, ME, KB.

Conflict of interest

None.

Funding

None.

Data availability

Contact the corresponding author for data availability.

Acknowledgments

None.

REFERENCES

- Markel J, Schwarting T, Malcherczyk D, Peterlein CD, Ruchholtz S, El-Zayat BF. Concomitant glenohumeral pathologies in high-grade acromioclavicular separation (type III - V). *BMC Musculoskelet Disord* 2017;18:439.
- Tischer T, Salzmann GM, El-Azab H, Vogt S, Imhoff AB. Incidence of associated injuries with acute acromioclavicular joint dislocations types III through V. *Am J Sports Med* 2009;37:136–9.
- Gorbaty JD, Hsu JE, Gee AO. Classifications in brief: Rockwood classification of acromioclavicular joint separations. *Clin Orthop Relat Res* 2017;475:283–7.
- Chaudry Z, Almasri M, Hasan SS. Addressing arthroscopic-assisted acromioclavicular joint reconstruction in the Beach Chair Position with concomitant labral pathology in the lateral decubitus position. *Arthrosc Tech* 2022;11:e847–55.
- Enad JG, Gaines RJ, White SM, Kurtz CA. Arthroscopic superior labrum anterior-posterior repair in military patients. *J Shoulder Elbow Surg* 2007;16:300–5.
- Shah SS, Ferkel E, Mithoefer K. High prevalence of superior labral anterior-posterior tears associated with acute acromioclavicular joint separation of all injury grades. *Orthop J Sports Med* 2020;8:2325967120941850.
- Millett PJ, Braun S, Gobezie R, Pacheco IH. Acromioclavicular joint reconstruction with coracoacromial ligament transfer using the docking technique. *BMC Musculoskelet Disord* 2009;10:6.
- Tossy JD, Mead NC, Sigmund HM. Acromioclavicular separations: useful and practical classification for treatment. *Clin Orthop Relat Res* 1963;28:111–9.
- Sterne JA, Hernán MA, Reeves BC, et al. ROBINS-I: a tool for assessing risk of bias in non-randomised studies of interventions. *BMJ* 2016;355:i4919.
- Pauly S, Gerhardt C, Haas NP, Scheibel M. Prevalence of concomitant intraarticular lesions in patients treated operatively for high-grade acromioclavicular joint separations. *Knee Surg Sports Traumatol Arthrosc* 2009;17:513–7.
- Pauly S, Kraus N, Greiner S, Scheibel M. Prevalence and pattern of glenohumeral injuries among acute high-grade acromioclavicular joint instabilities. *J Shoulder Elbow Surg* 2013;22:760–6.
- Ruiz Ibán MA, Sarasquete J, Gil de Rozas M, et al. Low prevalence of relevant associated articular lesions in patients with acute III-VI acromioclavicular joint injuries. *Knee Surg Sports Traumatol Arthrosc* 2019;27:3741–6.
- Jensen G, Millett PJ, Tahal DS, Al Ibadi M, Lill H, Katthagen JC. Concomitant glenohumeral pathologies associated with acute and chronic grade III and grade V acromioclavicular joint injuries. *Int Orthop* 2017;41:1633–40.
- Mazzocca AD, Arciero RA, Bicos J. Evaluation and treatment of acromioclavicular joint injuries. *Am J Sports Med* 2007;35:316–29.
- Maffet MW, Gartsman GM, Moseley B. Superior labrum-biceps tendon complex lesions of the shoulder. *Am J Sports Med* 1995;23:93–8.
- Mileski RA, Snyder SJ. Superior labral lesions in the shoulder: pathoanatomy and surgical management. *J Am Acad Orthop Surg* 1998;6:121–31.
- Snyder SJ, Banas MP, Karzel RP. An analysis of 140 injuries to

- the superior glenoid labrum. *J Shoulder Elbow Surg* 1995;4:243-8.
18. Clavert P, Bonnomet F, Kempf JF, Boutemy P, Braun M, Kahn JL. Contribution to the study of the pathogenesis of type II superior labrum anterior-posterior lesions: a cadaveric model of a fall on the outstretched hand. *J Shoulder Elbow Surg* 2004;13:45-50.
 19. Applegate GR, Hewitt M, Snyder SJ, Watson E, Kwak S, Resnick D. Chronic labral tears: value of magnetic resonance arthrography in evaluating the glenoid labrum and labral-bicipital complex. *Arthroscopy* 2004;20:959-63.
 20. Bencardino JT, Beltran J, Rosenberg ZS, et al. Superior labrum anterior-posterior lesions: diagnosis with MR arthrography of the shoulder. *Radiology* 2000;214:267-71.
 21. Jee WH, McCauley TR, Katz LD, Matheny JM, Ruwe PA, Daigneault JP. Superior labral anterior posterior (SLAP) lesions of the glenoid labrum: reliability and accuracy of MR arthrography for diagnosis. *Radiology* 2001;218:127-32.
 22. Gill TK, Shanahan EM, Allison D, Alcorn D, Hill CL. Prevalence of abnormalities on shoulder MRI in symptomatic and asymptomatic older adults. *Int J Rheum Dis* 2014;17:863-71.
 23. Connor PM, Banks DM, Tyson AB, Coumas JS, D'Alessandro DF. Magnetic resonance imaging of the asymptomatic shoulder of overhead athletes: a 5-year follow-up study. *Am J Sports Med* 2003;31:724-7.
 24. Jost B, Zumstein M, Pfirrmann CW, Zanetti M, Gerber C. MRI findings in throwing shoulders: abnormalities in professional handball players. *Clin Orthop Relat Res* 2005;(434):130-7.
 25. Miniaci A, Mascia AT, Salonen DC, Becker EJ. Magnetic resonance imaging of the shoulder in asymptomatic professional baseball pitchers. *Am J Sports Med* 2002;30:66-73.
 26. Mouhsine E, Garofalo R, Crevoisier X, Farron A. Grade I and II acromioclavicular dislocations: results of conservative treatment. *J Shoulder Elbow Surg* 2003;12:599-602.
 27. Petri M, Warth RJ, Greenspoon JA, et al. Clinical results after conservative management for grade III acromioclavicular joint injuries: does eventual surgery affect overall outcomes. *Arthroscopy* 2016;32:740-6.