

Original Article

Clin Shoulder Elbow 2024;27(2):219-228
<https://doi.org/10.5397/cise.2023.01060>

eISSN 2288-8721

Long-term clinical and radiographic outcomes of arthroscopic acromioclavicular stabilization for acute acromioclavicular joint dislocation

Eduard Van Eecke¹, Bernard Struelens², Stijn Muermans¹

¹Department of Orthopedic Surgery, AZ Delta Roeselare, Roeselare, Belgium

²Department of Orthopedic Surgery, AZ West Veurne, Veurne, Belgium

Background: Standard open acromioclavicular (AC) stabilization is associated with increased postoperative complications including deltoid injury, infection, tunnel complications, loss of reduction, and wound/cosmetic concerns. Arthroscopy may offer superior visualization and advantages that limit these risks. The aim of this prospective non-randomized study is to evaluate advantages and long-term reliability of arthroscopic AC stabilization.

Methods: Thirty-two patients with acute grade III, IV and V AC dislocations underwent arthroscopic AC reconstruction with long-term assessment by clinical AC examination, Simple Shoulder Test, American Shoulder and Elbow Surgeons scores, visual analog scale, Specific AC Score and Quick Disabilities of the Arm, Shoulder and Hand scores. Radiographs verified conservation of initial reduction and presence of coracoclavicular (CC) ossifications. Complications, revision rate, and satisfaction were assessed and compared to the literature.

Results: Mean follow-up time was 67.6 months. All clinical outcome scores improved and differences were statistically significant ($P < 0.001$). Initial postoperative radiographs consistently showed complete reduction. Two patients experienced relapse to grade II AC dislocation without clinical implications. In total, 71.8% showed CC ossifications without functional impairment, and in 31.3% concomitant injuries were observed. Reintervention rate was 9.4%, and 96.9% of patients were satisfied with procedure outcomes.

Conclusions: Arthroscopic stabilization for acute AC joint dislocations offers satisfactory clinical and radiographic outcomes, and our results show that the arthroscopic technique is reliable in the long run. We report better reduction in maintenance, fewer complications, and similar reoperation rates compared to other techniques.

Level of evidence: III.

Keywords: Acromioclavicular dislocation; Shoulder; Arthroscopy; Sports; Trauma

INTRODUCTION

Acromioclavicular (AC) joint dislocation is a common shoulder injury and is reported to occur most frequently among the young and athletic populations [1]. Athletes involved in contact sports, skiing and cycling are at increased risk of this injury [2]. The in-

cidence of acute AC joint disruptions is high, accounting for 9% of all shoulder girdle injuries. Up to 40% of acute AC joint disruptions occur in elite athletes participating in competitive contact sports [1,3,4]. The mechanism of injury is typically a direct blow to the adducted shoulder or an axially directed force to the ipsilateral extremity. The stability of the AC joint is mainly pro-

Received: November 30, 2023 Revised: January 16, 2024 Accepted: January 20, 2024

Correspondence to: Eduard Van Eecke

Department of Orthopedic Surgery, AZ Delta Roeselare, Brugsesteenweg 80, 8800 Roeselare, Belgium

Tel: +32-4-7681-9657, E-mail: eduard.van.eecke@hotmail.com, ORCID: <https://orcid.org/0000-0001-9749-3785>

© 2024 Korean Shoulder and Elbow Society.

This is an Open Access article distributed under the terms of the Creative Commons Attribution Non-Commercial License (<http://creativecommons.org/licenses/by-nc/4.0/>) which permits unrestricted non-commercial use, distribution, and reproduction in any medium, provided the original work is properly cited.

vided by the coracoclavicular (CC) and AC ligaments [3]. In 1984, Rockwood described his six-part classification system for AC joint separations, and this remains the most common classification system in use today [4].

The management of AC joint dislocations is highly variable both in terms of surgical indication and proposed surgical technique. Nonoperative management is accepted for low-grade injuries (type I and II injuries), whereas operative management is indicated for type IV to VI [5]. Significant controversy remains regarding proper diagnosis and management of type III injuries [1,3-6].

The main goal of surgical treatment of AC joint dislocation is an anatomical reduction of the AC joint and to reconstruct the biomechanical forces of the CC ligaments [1]. Standard surgery for AC joint dislocation requires open approaches (e.g., Bosworth screw fixation, Weaver-Dunn procedure, clavicle hook plate fixation, ligament reconstruction) and is associated with an up to 27% rate of postoperative complications (e.g., surgical site infection, deltoid detachment, neurovascular injury due to extensive soft tissue dissection, osseous fractures from drill holes, osteolysis and loss of reduction) [5,6]. Radiographic loss of reduction rates are as high as 30 to 47% for both open and arthroscopic techniques [7-9]. In order to reduce these complications, there has been increased interest in the use of minimally invasive surgical techniques (the arthroscopic approach) to reconstruct the CC ligament [10].

These arthroscopic procedures theoretically offer superior view to the coracoid base, minimal soft tissue dissection, smaller incisions, fewer deep infections and the capacity to treat concomitant shoulder injuries. Literature review revealed an elevated risk for clavicular/coracoid fractures in open procedures compared to arthroscopic procedures, possibly due to increased soft tissue dissection in open surgery and suboptimal view on the coracoid base [5]. Furthermore, it has been stated that up to 40% of AC joint dislocations have associated other shoulder pathology such as partial articular supraspinatus tendon avulsion (PASTA) lesions, superior labrum from anterior to posterior (SLAP) lesions, labral tears and chondral defects [6,11,12]. In open surgical procedures these injuries will often be overlooked or missed. Arthroscopy offers not only diagnosis of such lesions but also the potential to treat these injuries simultaneously if desired. Good short-term results have been reported on arthroscopic AC fixation, however, there is scarce documentation on long-term results to confirm whether the initial results stand the test of time.

The purpose of this study was to document our surgical treatment of acute AC joint dislocations with an arthroscopic technique using the ZipTight Fixation System for AC Joint Reconstruction (Zimmer Biomet), and to assess clinical and radiographic long-term outcome compared to similar arthroscopic

and conventional open techniques.

METHODS

This study is a single-center, prospective, non-randomized, clinical and radiographic follow-up study. Research approval was obtained by the Ethics Committee of AZ Delta Roeselare (approval No. 21069; clinical trial No. B1172021000024). All patients who participated signed the patient information and consent form approved by the Ethics Committee.

From July 2011 through August 2018, 32 consecutive patients diagnosed with an acute AC joint dislocation were treated in our department with an arthroscopic technique making use of the knotless ZipTight single tunnel, double-button fixation system. Our technique is used for repair of acute grade III, IV and some grade V AC joint dislocations in slim patients (Rockwood classification). Diagnosis was obtained clinically and radiographically. We considered injuries presenting within 3 weeks to be acute. Exclusion criteria for this study involved patients older than 65 years, chronic AC joint dislocations, obesity, infection and lateral clavicle fractures. Other patients with AC joint injuries type I, II, and III (low functional demand patients) and those who refused surgical intervention were treated nonoperatively. All surgical procedures were performed by a single senior shoulder surgeon (SM) using a standardized procedure.

All patients were contacted for an additional clinical and radiographic assessment in the long term. Clinical assessment at last follow-up included the following data: AC stability, AC tenderness, AC compression test, shrug test, active and passive shoulder range of motion (ROM). Functional outcome was evaluated with retrospective preoperative and postoperative American Shoulder and Elbow Surgeons (ASES) scores, Simple Shoulder Test (SST), Specific AC Score (SACS) and Quick Disabilities of the Arm, Shoulder and Hand (DASH) scores. The subjective perception of pain was evaluated by a retrospective preoperative and postoperative visual analog scale (VAS). Additional anteroposterior (AP) radiographs of the AC joints were obtained in every patient at last follow-up to assess maintenance of CC reduction. Using these radiographs, CC distances were determined and compared with previously taken short-term postoperative radiographs by two independent researchers (EVE and SM). Since other studies revealed interobserver variability to be approximately 5 mm, a value of 5-mm increase was chosen to represent loss of reduction [6,13]. Possible AC osteoarthritis and CC ligament calcification/ossification were also documented. Postoperative complications and overall revision rates were documented. Finally, global satisfaction of the patients with the results

of the surgery was assessed with “satisfied” or “not satisfied.”

Statistical Analysis

Preoperative and postoperative outcome scores were subjected to statistical analysis. All statistical analyses were performed using statistical software GraphPad Prism version 10.0.0 (GraphPad Software). With regard to outcome scores, parametric and non-parametric univariate analyses were performed depending on whether data were normally distributed. Normality testing was performed with the D’Agostino-Pearson test. VAS and SACS data were normally distributed, and thus, paired sample t-tests were used to compare the difference between preoperative and postoperative outcomes scores. SST, ASES, and Quick DASH showed no normal distribution and were subjected to Wilcoxon’s signed-rank test (non-parametric test).

Surgical Technique

Our technique is mainly arthroscopic apart from a mini incision over the clavicle to allow for placement of the drill guide and room for a clavicular button. It is minimally invasive to the soft tissues without the need for splitting or detaching the deltoid muscle. It

avoids an open approach to the subclavicular space with minimal local neurovascular and soft tissue impingement.

Under general anesthesia, interscalene block and preoperative prophylactic antibiotics, the patient is placed in the beach chair position. Light pendular traction on the arm is optional and can be applied to create more anterior subdeltoid working space. The degree, direction and reducibility of the AC dislocation is examined and can best be determined under total relaxation. A diagnostic glenohumeral arthroscopy is then performed. If present, concomitant intra articular lesions are evaluated and judged for treatment. Possible labral, bicipital, tendinous or cartilaginous lesions are noted but in practice rarely need simultaneous surgical attention.

Next, the arthroscope is introduced in the subacromial space and a limited anterior bursectomy is performed through a mid-lateral portal to allow sufficient visualization of the anterior subacromial compartment. The camera is then switched to the lateral portal and an accessory anterolateral working portal is created. Through this latter portal the subcoracoid area is progressively cleaned with a soft tissue shaver and radiofrequency probe and the base of the coracoid is cleared of tissue until the medial edge of the coracoid is clearly visible and outlined (Fig. 1A). The axilla of the

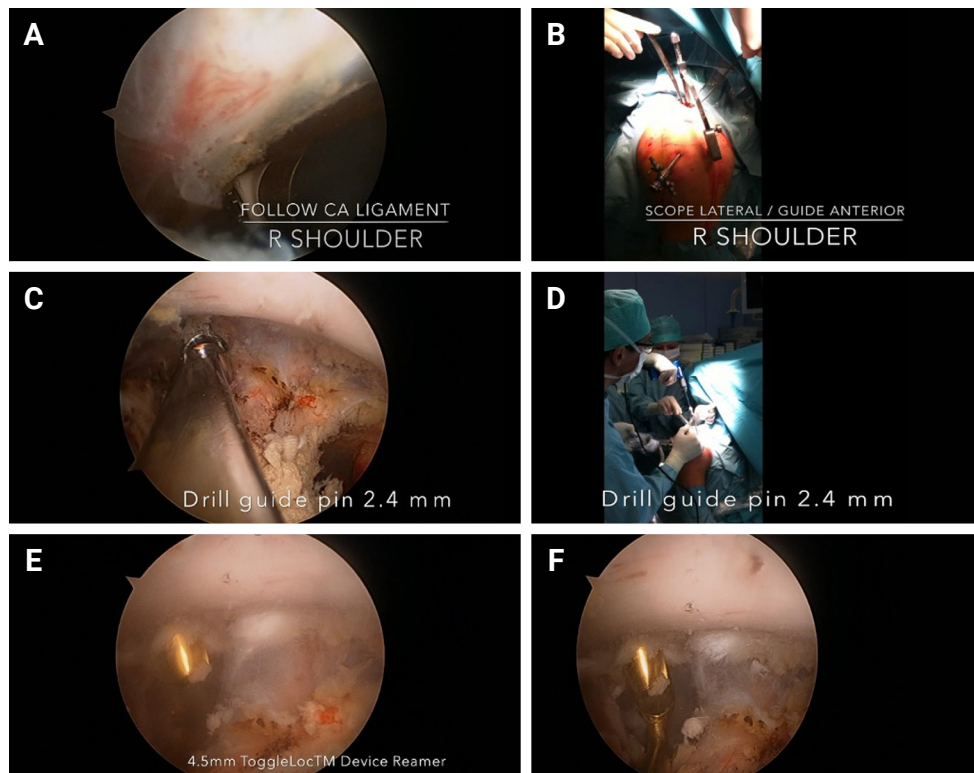


Fig. 1. Surgical Technique. (A) Subcoracoid area is cleaned with a soft tissue shaver and radiofrequency probe by following the coracoacromial ligament towards the base of the coracoid. (B) The arthroscope is switched lateral and guide is placed anterior to this position in the accessory anterolateral portal. (C, D) The 2.4-mm guide pin is drilled antegrade towards the coracoid, passing the 4 cortices. (E, F) Tunnel is drilled with the cannulated 4.5-mm drill, avoiding any accidental subcoracoid neurovascular injury by placing a protecting curette under the tip of the guide pin.

coracoid undersurface is clearly identified to be sure the drill hole can be as proximal as possible in the coracoid base to limit the risks of bone tunnel eccentricity and breakout.

The proximal entry position for the drill tunnel is then determined at the clavicular side. This is about 2.5 cm medial to the AC joint and mid to slightly posterior on the superior surface of the clavicle in an AP perspective. A mini-incision of 2 cm is made longitudinally centered on this point. The overlying trapezius is split, and the clavicle freed subperiosteally. Then a Biomet anterior cruciate ligament type guide is brought in the anterolateral portal: the distal pointed tip is centered mediolaterally on the coracoid base as proximal as possible (Fig. 1B). If confident about the position, the proximal drill sleeve of the guide is compressed against the previously determined entry point on the clavicle, thereby reducing the AC dislocation. This allows the tunnel to be drilled in a reduced position. Care is taken that the distal tip on the coracoid does not displace at this stage. The mediolateral position of the tunnel can optionally be checked with intraoperative radioscopy.

Next the 2.4-mm guide pin is drilled antegrade towards the coracoid, passing the four cortices (two of the clavicle and two of the coracoid), slowing down when perforating the undersurface of the coracoid in order to avoid damage to the plexus. This stage offers the biggest advantage of the arthroscopic technique as the camera allows a perfect view to judge the AP and mediolateral

intra-coracoid position of the tunnel to be drilled around the guide pin (Fig. 1C and D). Switching the camera briefly to the anterior or anterolateral portal further optimizes this view especially in the mediolateral direction. If satisfied, one can now remove the guide and drill the tunnel with the cannulated 4.5-mm drill, avoiding any accidental subcoracoid neurovascular injury by placing a protecting curette under the tip of the guide pin (Fig. 1E and F). This advantageous arthroscopic viewing phase almost entirely eliminates the most precipitous step for failure of the procedure by avoiding any off-track tunnel position in the coracoid that might lead to breakout of the implant in case of decentralized pin and tunnel position.

The cannulated 4.5-mm drill is left in place and the guide pin removed. A stiff monofilament polydioxanone (PDS) suture is passed antegrade through the cannulated drill and shuttled to the ZipTight's own shuttle suture (Fig. 2A and B). The PDS suture is retrieved distally from the anterolateral portal under arthroscopic view from the mid-lateral portal (Fig. 2C). The cannulated drill is removed, and the ZipTight implant is now tunneled with the distal button from clavicle to coracoid by distal pulling on the shuttle suture (Fig. 2D). The assistant holds the implant proximally under light tension with a good view on the clavicular hole in order to pass the vertically tilted coracoid button effortlessly through both bones (Fig. 3A).

Once the distal button has exited the coracoid, the suture re-

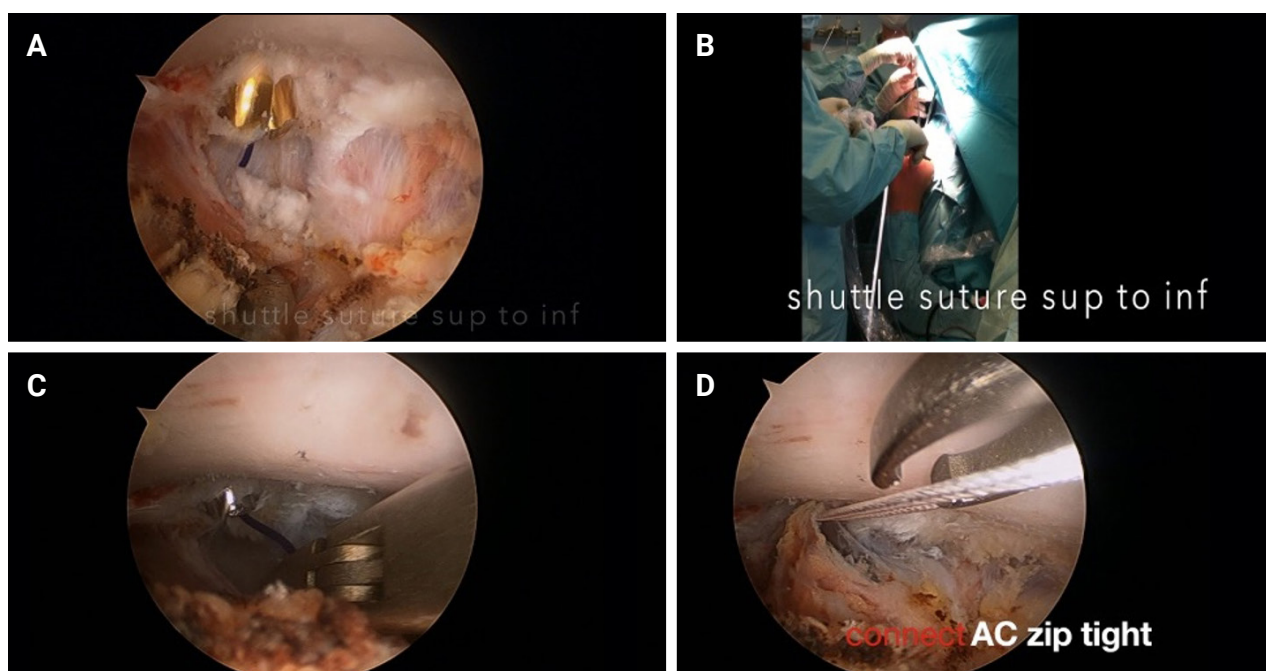


Fig. 2. Surgical technique. (A, B) A stiff suture is passed antegrade through the cannulated drill, shuttled to the ZipTight's own shuttle suture. (C, D) The shuttle suture is retrieved distally out of the anterolateral portal and connected the ZipTight device. AC: acromioclavicular.

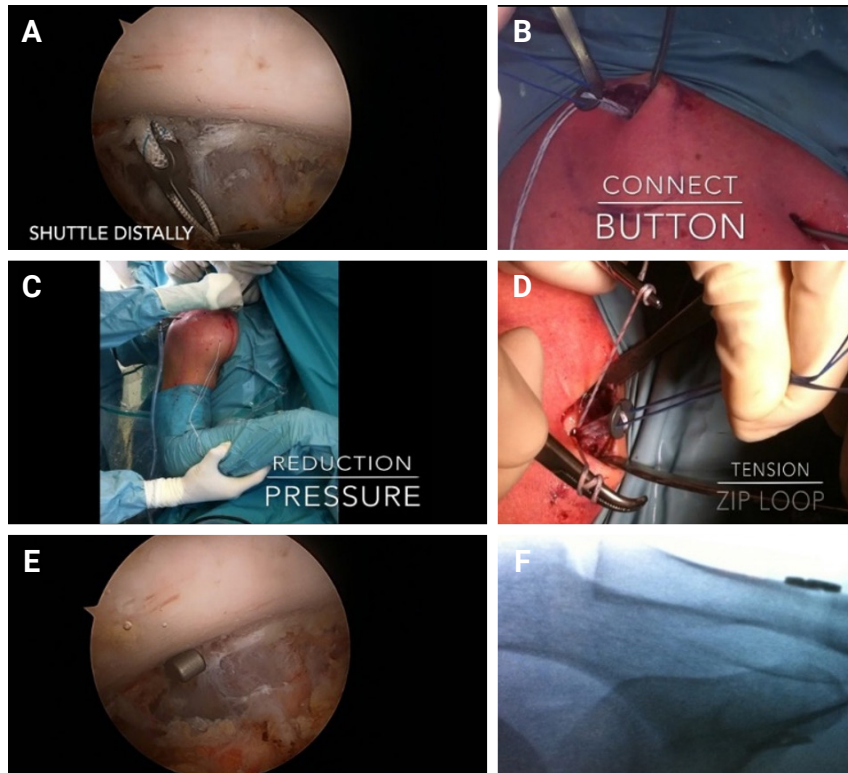


Fig. 3. Surgical technique. (A) The coracoid button is pulled through both the clavicle and coracoid. (B) The separately provided proximal button is positioned in the double loop of the implant on the proximal clavicle. (C) Reduction maneuver by the assistant with caudally directed thumb pushing on the lateral clavicle and proximally directed scapular movement indirectly by pushing the elbow proximally. (D) Tensioning of the implant by pulling the tensioning sutures. (E, F) Final verification of correct button position arthroscopically and with additional intraoperative radioscopy.

triever is used to put the button 90° across the longitudinal axis of the coracoid. The assistant now pulls the zip tight construct proximally to engage the distal button in this position. Next, the separately provided proximal button is positioned in the double loop of the implant on the proximal clavicle (Fig. 3B). The assistant makes a reduction maneuver with caudally directed thumb pushing on the lateral clavicle and proximally directed scapular movement by pushing the elbow proximally (Fig. 3C). In the meantime, the surgeon tensions the implant by pulling the tensioning sutures (Fig. 3D). Usually maximum tension is exerted until no residual shift is left.

The AC joint is checked clinically but as the shoulder often is somewhat swollen by this stage, we always verify it arthroscopically and with intra-operative radioscopy (Fig. 3E and F). The reduction of the AC joint is checked as well as the CC distance and mediolateral position of the buttons. When satisfied, the remainder of the pulling sutures can be cut off at the level of the clavicular button leaving no loose ends. This constitutes a supplemental advantage in that there is no need to tie a knot on top of the button that might be bothersome in a later stage. The portals and mini incision

on the clavicle are closed and a sterile dressing is applied.

Postoperative Care

After surgery we use a shoulder immobilizer for 3–4 weeks. Mobilization of the elbow and wrist are allowed immediately with pendulum exercises started after 1 week. The immobilizer can be discarded after 3–4 weeks after which physiotherapy is started with passive and active assisted exercises up to 6 weeks. Active ROM and strength exercises began at 6 weeks.

RESULTS

Thirty-two patients met the inclusion criteria and participated in the study. Of this cohort there were 30 male and 2 female patients. The mean age of the patients was 37.4 years (range, 24–60 years; standard deviation [SD], 10.4). According to Rockwood's classification there were 21 patients (65.6%) with grade III, 6 (18.7%) with grade IV and 5 (15.6%) with grade V injuries. Mean follow-up time was 67.6 months (range, 14–123 months; SD, 17.6) (Table 1).

All patients obtained a full ROM at final follow-up. Two patients (6.3%) experienced mild AC tenderness upon clinical examination. These same two patients had a positive resisted AC compression test. Two other patients had a positive shrug sign at last follow-up. No clinical AC instability was observed. There were no complaints about irritation related to the clavicular button.

Pain was evaluated by retrograde preoperative and postoperative VAS. Mean VAS scores fell from 7.2 (range, 3–10; SD, 1.8) preoperatively to 1.0 (range, 0–7; SD, 1.5) at final follow-up. Mean preoperative SST and ASES scores were 0.3 (range, 0–2; SD, 0.6) and 25.1 (range, 0–80; SD, 18.1), respectively. At final follow-up, mean postoperative SST and ASES scores were 11.7 (range, 10–12; SD, 0.6) and 96.3 (range, 68–100; SD, 6.5), respectively. SACS decreased from 80.5 (range, 43–100; SD, 15.3) to 6.1 (range, 0–26; SD, 7.4). Quick DASH scores improved from 79.8 (range, 31–100; SD, 20.1) preoperatively to 3.7 (range, 0–22; SD, 6.4) at final follow-up. All differences in preoperative and postoperative outcomes scores were statistically significant ($P < 0.001$)

Table 1. Patient demographics

Factor	Value
Sample size	32
Age (yr)	37.4 ± 10.4
Follow-up time (mo)	67.7 ± 17.6
Sex (male:female)	30:2
Grade of AC dislocation	
III	21 (65.6)
IV	6 (18.7)
V	5 (15.6)
Concomitant lesions	
PASTA (Tx: debridement)	4 (12.5)
SLAP type 1 (Tx: debridement)	5 (15.6)
SLAP type 4 (Tx: biceps tenodesis)	1 (3.1)

Values are presented as mean ± standard deviation or number (%). AC: acromioclavicular, PASTA: partial, articular, supraspinatus, tendon, avulsion, Tx: treatment, SLAP: superior labrum from anterior to posterior.

Table 2. Clinical findings

Variable	Preoperative	Postoperative	P-value*
Visual analogue scale	7.2 ± 1.8 (3–10)	1.0 ± 1.5 (0–7)	< 0.001
American Shoulder and Elbow Surgeons score	25.1 ± 18.1 (0–80)	96.3 ± 6.5 (68–100)	< 0.001
Simple Shoulder Test	0.3 ± 0.6 (0–2)	11.7 ± 0.6 (10–12)	< 0.001
Specific AC score	80.5 ± 15.3 (43–100)	6.1 ± 7.4 (0–26)	< 0.001
Quick Disabilities of Arm, Shoulder and Hand score	79.8 ± 20.1 (31–100)	3.7 ± 6.4 (0–22)	< 0.001

Values are presented as mean ± standard deviation (range).

AC: acromioclavicular.

*Significant difference ($P < 0.05$).

(Table 2). Thirty-one patients (96.9%) were satisfied with the procedure.

Radiographic evaluation using AP radiographs of the AC joint revealed a mean CC distance of 10.9 mm (range, 5.6–16.8 mm; SD, 2.6) at one day postoperatively. At final follow-up, mean CC distance was 12.2 mm (range, 8.4–21.1 mm; SD, 2.9). A mean difference of 1.3 mm was seen. Since other studies revealed interobserver variability to be approximately 5 mm, this suggested that there is no significant loss of reduction between short-term and long-term postoperative CC distance. In our series, two patients (6.3%) had a loss of reduction of > 5 mm between short term and final follow-up (5.1 and 8.1 mm); neither patient showed an increase of > 10 mm. These two patients had a radiographic relapse to grade II, but without clinical implications.

Twenty-three patients (71.8%) showed ossifications between the clavicle and the coracoid (Fig. 4). Ossifications did not impair ROM/strength/patient reported outcomes. Two patients (6.3%) showed radiographic signs of AC osteoarthritis. No signs of clavicular osteolysis were observed (Table 3).

During the diagnostic glenohumeral arthroscopy we found 31.3% of patients had concomitant lesions. Five SLAP type 1 le-

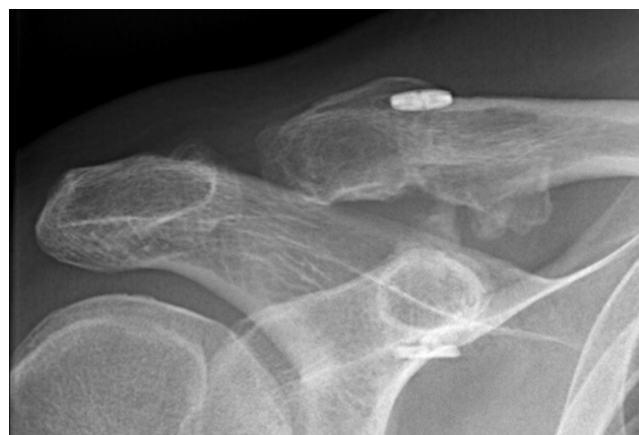

Fig. 4. Coracoclavicular ligament ossifications.

sions and four PASTA lesions were observed, and all were treated with arthroscopic debridement. There was one bucket handle tear of the superior labrum with loose biceps tendon (SLAP type 4). This lesion was treated with an arthroscopic biceps tenodesis.

Complications

One patient was intraoperatively converted to treatment with a hook plate (Synthes) due to coracoid tunnel breakout. One patient suffered a postoperative wound infection that was treated with hardware removal six weeks postoperatively without loss of reduction. One patient had a cut out of the clavicular tunnel two months postoperatively without loss of reduction of the AC joint. Despite immobilization, non-union of the clavicular tunnel developed and the implant was removed. At the time of reintervention, intraoperative evaluation revealed no loss of reduction after removal of the construct. A lateral clavicular plate (Synthes) was placed for treatment of pseudarthrosis. One patient had some persisting vague discomfort of unexplainable origin with perfect objective clinical and radiographic results. This was resolved within four weeks after late removal of the implant and was believed to be caused by some tensional pain due to the button construct. No cases of complex regional pain syndrome were observed. The overall revision/reintervention rate was 9.4% (3/32); these interventions were a result of acute infection, late clavicular stress fracture and unexplained pain (Table 4).

DISCUSSION

In this study we sought to illustrate the advantages and reliability

of an arthroscopic technique for acute grade III, IV and some grade V AC dislocations as compared to other available open techniques. We also want to stress the long-term reliability, which has rarely been reported in other studies. The first limitation of the study is the relatively small number of included patients. The most relevant limitation of this study; however, is the lack of a control group treated non-arthroscopically with the same implant. Therefore, our clinical and radiographic results will be compared with other open and arthroscopic reports in the literature. This technique is not appropriate for chronic dislocation or for several grade V injuries in obese or muscular patients and thus cannot be proposed as a single universal technique for all types of AC dislocation. However, the same goes for open procedures where the choice of procedure is personalized according to timing, surgeon, patient and injury variables.

Recent literature has confirmed that an arthroscopic single-tunnel CC stabilization is not sufficient for grade V injuries. Therefore, in all grade V injury cases, we perform an open procedure with allograft augmentation. One could state that an arthroscopic assisted procedure with a CC single tunnel, double-button construct and a self-locking ZipTight technology might not be as strong as other open procedures with the same indication. This could suggest our technique might lose reduction or fail altogether more easily. For this reason, we emphasized a long-term cohort of results in order to demonstrate the long-term reliability and healing potential. Furthermore, the application of this minimally invasive technique is restricted to acute injury because it relies on intrinsic, biological healing potential of the native CC ligaments. The double-button construct is merely there to keep the AC joint reduced in the early healing stage, bringing together the stumps of the conoid and trapezoid ligaments that in the early posttraumatic phase still have biologic healing potential. We consider injuries beyond 3 weeks not suitable for our technique as one expects that the torn ligaments have scarred and stumped by then with associated fading away of the initially liberated local growth factors. Beyond 3 weeks we perform an open technique with AC capsule reinforcement and CC tendinous allograft augmentation. The single arthroscopic technique of double-button construct would not be strong enough to

Table 3. Radiographic findings (n=32)

Variable	Percent (number)
CC loss of reduction	
> 5 mm	6.3 (2)
> 10 mm	0
CC ligament ossifications	71.8 (23)
AC osteoarthritis	6.3 (2)

CC: coracoclavicular, AC: acromioclavicular.

Table 4. Complications

Complication	Time after index surgery	Treatment	Reduction status
Coracoid tunnel breakout	Intraoperative	Conversion to hook plate	NA
Infection	6 wk	Implant removal	Intact
Late clavicular stress fracture	8 wk	Implant removal	Intact
Unexplained pain	3 yr	Implant removal	Intact

NA: not applicable.

resist the forces of a chronic dislocation without further healing potential.

Gowd et al. [5] systematically reviewed the outcomes and complications of different techniques of AC joint reconstruction. They report an overall complication rate of 14.2% in a heterogeneous group of 1,704 AC joint reconstructions with a mean follow-up of 34.3 months. The most common complications include infection, fracture of the coracoid or clavicle and hardware failure. Their mean infection rate is reported at 6.3% for both open and arthroscopic techniques, significantly higher than the 3.1% in our series. Another systematic review by Woodmass et al. [14] about complications in arthroscopic AC reconstruction reveals infection rates of 3.8%. They report no cases of deep infection following arthroscopic AC reconstruction. These findings are consistent with our results and confirm the theoretical advantage of arthroscopic surgery in reducing infection rate. This is particularly relevant when treating controversial grade III lesions, where the risk of infection associated with surgery may outweigh the benefits of AC joint reconstruction [14].

A recent meta-analysis by Gowd et al. [5] reveals a mean loss of reduction rate of 18.9% (19.3% in arthroscopic vs 18.5% in open techniques) and overall revision rate of 9.5% for all techniques [5]. There was no statistically significant difference between loss of reduction or revision rates for arthroscopic and open procedures. Our findings surpass these rates with a loss of reduction rate of only 6.3% and overall revision rate of 9.4% in the long term with a mean follow-up of 67 months. Our study thus illustrates a superior reduction maintenance and similar revision rate comparing to other open and arthroscopic techniques.

Some might argue against the arthroscopic approach as the constant lavage of physiological fluid during the procedure might wash away the remaining growth factors and biological healing properties. However, in open surgery the shoulder is rinsed as well during the procedure and the constant bleeding is drained by suction, sucking away the same biologicals. Furthermore, this rinsing argument is seldom used when discussing arthroscopic rotator cuff or Bankart surgery; now that these arthroscopic procedures have become the gold standard as opposed to their open alternatives, the washing away of biological healing factors is no longer seen as an active concern. Finally, the fact that the postoperative x-rays rather consistently show CC ossifications (71.8%) in the CC space suggests that bone marrow from the drill tunnel adds multipotent cells to the ligamentous healing area, regardless of an arthroscopic lavage effect. This can also be found in open procedures [15]. Scheibel et al. [16] described similar rates of CC ossifications (67.9%) and mention that these CC ossifications may be regarded as positive in terms of AC joint stability. CC os-

sifications did correlate inversely with the CC distance and did not impair ROM. Our results confirm these findings. Motta et al. [17] reported that CC ossifications increase the stiffness of the surgical reconstruction and are, therefore, positively correlated with a normal AC joint motion. In their findings, patients without CC ossifications had a more hypermobile/unstable AC joint.

There might be some indication that a single CC button construct is not sufficient to withstand both vertical and horizontal AP forces. To provide more AP stability to replace the function of the AC ligament, which is not repaired in a standard, across the board way in our technique except for according to the indications stated above, one can choose alternative procedures or implants. First, AC capsule reinforcement can be performed. Second, some studies have proposed using two implants to recreate the different directions of the trapezoid and conoid ligaments. Alternately, a single implant augmented with CC allograft ligament reconstruction through two extra clavicular bone tunnels can be used, or some companies also provide similar implants with a double tail on the clavicular part (e.g., Arthrex Twintail Tightrope). Gu et al. [18] compared double and single tunnel constructs and found no difference in clinical outcomes. However, radiological outcomes revealed the CC distance was significantly increased after 6 weeks in the single tunnel group compared to the double tunnel group. An important disadvantage of these double tunnel implants/techniques is the increased risk of fractures/tunnel break out [19].

Advantages of the arthroscopic approach thus lie in the minimally invasive exposure, better cosmetics, avoidance of partial deltoid detachment that might pose problems, and especially the superior viewing for adequate placement of the guide pin and drill tunnel. By this one advantage, some of the worst complications like misplacement of the tunnel with cutting out sideways or fracture of the coracoid (reported at rates of up to 20% in literature) can be limited [6]. These adverse events will lead to loosening of the construct with proximal migration, possible intraosseous migration of the distal button into the coracoid with loss of reduction, and the need to convert the procedure to another type of fixation either immediately or in a second stage. A recent literature review by Gowd et al. [5] revealed combined fracture rates in 5% of cases in open techniques compared to 3.4% in all-arthroscopic or arthroscopic-assisted techniques. Milewski et al. [20] described a combined clavicle/coracoid perioperative fracture rate of 18.5% with open and 10% with arthroscopic technique. Woodmass et al. [14] described a pooled fracture rate of 5.3% in arthroscopic fixation of AC separation, mainly at the level of the coracoid (7/1). Martetschläger et al. [6] also reported both open and arthroscopic techniques and found a mean rate of

20% with no statistical difference between both groups. In our study, we only had one such occasion with an intraoperative tunnel breakthrough (at the level of the coracoid) with need to convert to a hook plate (3.1%), which supports a low degree of fracture for arthroscopic techniques.

Another factor that may influence the fracture risk is the diameter of the bone tunnels used in AC joint repair. Limiting the diameter of the drill tunnel is an extra option to limit the risk of tunnel breakout, since biomechanical testing shows that smaller bone tunnels have an increased load to failure [19]. Newer techniques now allow bone tunnels of only 3 mm with retrograde passage of the implant, which will probably decrease the fracture risk in future. Besides increased diameter of the tunnel, the fracture risk should also increase with the number of tunnels [5].

The specific implant used in our study provides the opportunity to lock the system in the final step without the need for knot tying on top of the clavicular button (Fig. 4). In other implants this is often necessary, and this knot can cause hardware irritation or granuloma formation that requires removal in a later stage. Some other studies using a tightrope/endobutton fixation technique for AC joint reconstruction report hardware irritation rates of more than 25% [14,16,21,22]. Scheibel et al. [16] reported tenderness on the superior aspect of the implants in 39% of patients. Despite the high rate of hardware irritation, revision surgery for hardware removal was not routinely performed in any study [14,16]. This is in contrast to patients treated with open surgery with hook plates leading to a routine second surgery for removal.

Our findings match the earlier described high incidence of concomitant shoulder injuries (31.3%). Markel et al. [12] reported an incidence of almost 40% of co-existing shoulder injuries. However, in their study only 21.9% of all patients with concomitant pathology needed additional reconstructive surgery, since 70% of these injuries could be attributed to a mostly degenerative etiology. In our series, 31.3% concomitant injuries were seen, and only one patient with a SLAP type 4 injury required treatment (with arthroscopic biceps tenodesis). The main limitations of this study are the lack of a control group treated with open surgery and the small cohort size.

CONCLUSIONS

Arthroscopic stabilization for acute grade III, IV and some grade V AC joint dislocations offers satisfactory clinical and radiographic outcomes and our results demonstrate reliability of the arthroscopic technique in the long run. After a mean follow-up of 67.6 months, our clinical results showed a 100% clinical en-

forcement of AC joint reduction and a 93.7% rate of radiographic maintenance of reduction, exceeding reported rates of existing techniques. Additionally, we report high patient satisfaction rate, fewer complications and similar re-intervention rates compared to other techniques. We recommend this arthroscopic reconstruction as a readily reproducible technique and our findings refute the possible arguments against sufficient strength of a single tunnel arthroscopic technique.

NOTES

ORCID

Eduard Van Eecke <https://orcid.org/0000-0001-9749-3785>

Bernard Struelens <https://orcid.org/0000-0003-1465-0445>

Author contributions

Conceptualization: EVE, BS, SM. Data curation: EVE, SM. Formal analysis: EVE, SM. Funding acquisition: SM. Investigation: EVE, SM. Methodology: EVE, BS, SM. Project administration: EVE, SM. Resources: SM. Supervision: SM. Validation: EVE, SM. Visualization: EVE, SM. Writing – original draft: EVE, SM. Writing – review & editing: EVE, SM.

Conflict of interest

The senior author (Stijn Muermans, MD) has educational consultancy agreements with Zimmer Biomet. No other potential conflicts of interest relevant to this article were reported.

Funding

None.

Data availability

Contact the corresponding author for data availability.

Acknowledgments

None.

REFERENCES

1. Martetschläger F, Kraus N, Scheibel M, Streich J, Venjakob A, Maier D. The diagnosis and treatment of acute dislocation of the acromioclavicular joint. *Dtsch Arztebl Int* 2019;116:89–95.
2. Cutbush K, Hirpara KM. All-arthroscopic technique for reconstruction of acute acromioclavicular joint dislocations. *Arthrosc Tech* 2015;4:e475–81.
3. Campagna V, Piccinni V, Rotundo G, Candela V, Gumina S. The Kite technique: a new all-arthroscopic technique for the

- treatment of acute acromioclavicular joint dislocation. *Knee Surg Sports Traumatol Arthrosc* 2021;29:2055–63.
4. DeBerardino TM, Pensak MJ, Ferreira J, Mazzocca AD. Arthroscopic stabilization of acromioclavicular joint dislocation using the AC graftrope system. *J Shoulder Elbow Surg* 2010;19(2 Suppl):47–52.
 5. Gowd AK, Liu JN, Cabarcas BC, et al. Current concepts in the operative management of acromioclavicular dislocations: a systematic review and meta-analysis of operative techniques. *Am J Sports Med* 2019;47:2745–58.
 6. Martetschläger F, Horan MP, Warth RJ, Millett PJ. Complications after anatomic fixation and reconstruction of the coracoclavicular ligaments. *Am J Sports Med* 2013;41:2896–903.
 7. Glanzmann MC, Buchmann S, Audigé L, Kolling C, Flury M. Clinical and radiographical results after double flip button stabilization of acute grade III and IV acromioclavicular joint separations. *Arch Orthop Trauma Surg* 2013;133:1699–707.
 8. Çarkçı E, Polat AE, Gürpınar T. The frequency of reduction loss after arthroscopic fixation of acute acromioclavicular dislocations using a double-button device, and its effect on clinical and radiological results. *J Orthop Surg Res* 2020;15:136.
 9. Choi NH, Lim SM, Lee SY, Lim TK. Loss of reduction and complications of coracoclavicular ligament reconstruction with autogenous tendon graft in acute acromioclavicular dislocations. *J Shoulder Elbow Surg* 2017;26:692–8.
 10. Loriaut P, Casabianca L, Alkhaili J, et al. Arthroscopic treatment of acute acromioclavicular dislocations using a double button device: clinical and MRI results. *Orthop Traumatol Surg Res* 2015;101:895–901.
 11. Warth RJ, Martetschläger F, Gaskill TR, Millett PJ. Acromioclavicular joint separations. *Curr Rev Musculoskelet Med* 2013;6:71–8.
 12. Markel J, Schwarting T, Malcherczyk D, Peterlein CD, Ruchholtz S, El-Zayat BF. Concomitant glenohumeral pathologies in high-grade acromioclavicular separation (type III - V). *BMC Musculoskelet Disord* 2017;18:439.
 13. Millett PJ, Horan MP, Warth RJ. Two-year outcomes after primary anatomic coracoclavicular ligament reconstruction. *Arthroscopy* 2015;31:1962–73.
 14. Woodmass JM, Esposito JG, Ono Y, et al. Complications following arthroscopic fixation of acromioclavicular separations: a systematic review of the literature. *Open Access J Sports Med* 2015;6:97–107.
 15. Rehbein K, Jung C, Becker U, Bauer G. Treatment of acute AC joint dislocation by transosseal acromioclavicular and coracoclavicular fiberwire cerclage. *Z Orthop Unfall* 2008;146:339–43.
 16. Scheibel M, Dröschel S, Gerhardt C, Kraus N. Arthroscopically assisted stabilization of acute high-grade acromioclavicular joint separations. *Am J Sports Med* 2011;39:1507–16.
 17. Motta P, Bruno L, Maderni A, Tosco P, Mariotti U. Acromioclavicular motion after surgical reconstruction. *Knee Surg Sports Traumatol Arthrosc* 2012;20:1012–8.
 18. Gu F, Tan L, Wang T, et al. Comparison of single versus double TightRope system in the treatment of acute acromioclavicular joint dislocation. *J Shoulder Elbow Surg* 2021;30:1915–23.
 19. Dumont GD, Russell RD, Knight JR, et al. Impact of tunnels and tenodesis screws on clavicle fracture: a biomechanical study of varying coracoclavicular ligament reconstruction techniques. *Arthroscopy* 2013;29:1604–7.
 20. Milewski MD, Tompkins M, Giugale JM, Carson EW, Miller MD, Diduch DR. Complications related to anatomic reconstruction of the coracoclavicular ligaments. *Am J Sports Med* 2012;40:1628–34.
 21. Cohen G, Boyer P, Pujol N, Hamida Ferjani B, Massin P, Hardy P. Endoscopically assisted reconstruction of acute acromioclavicular joint dislocation using a synthetic ligament: outcomes at 12 months. *Orthop Traumatol Surg Res* 2011;97:145–51.
 22. Salzmann GM, Walz L, Buchmann S, Glabgyl P, Venjakob A, Imhoff AB. Arthroscopically assisted 2-bundle anatomical reduction of acute acromioclavicular joint separations. *Am J Sports Med* 2010;38:1179–87.