



Radiologic Insertion of a Covered Esophageal Stent Using the Rendezvous Technique: A Case Report

랑데부 방법을 이용한 영상의학적 식도 커버드 스텐트 삽입술: 증례 보고

Yoojin Park, MD, Suyoung Park, MD*, Jung Han Hwang, MD, Jeong Ho Kim, MD, So Hyun Park, MD

Department of Radiology, Gil Medical Center, Gachon University College of Medicine, Incheon, Korea

In this report, we present a case of a radiotherapy-induced tracheoesophageal fistula treated with the fluoroscopy-guided insertion of a covered stent through the gastrostomy route using both the antegrade and retrograde approaches. The initial antegrade endoscopic and fluoroscopic stent insertion procedure failed due to severe esophageal stricture. Compared to the endoscopic approaches, fluoroscopy-guided radiologic procedures are generally less invasive and more successful because they allow for a better understanding of the anatomy outside the lumen during the procedure and enable the use of devices with smaller diameters.

Index terms Tracheoesophageal Fistula; Stent; Gastrostomy; Fluoroscopy; Interventional Radiology

INTRODUCTION

A tracheoesophageal fistula (TEF) is a life-threatening complication that occurs in up to 15% of esophageal cancer cases (1). Surgical treatments for TEF include esophagectomy with colon interposition and gastric transposition. These procedures have a high risk of postoperative complications (2), and certain patients may not be suitable candidates for surgery. In these cases, a covered stent insertion is often used as a palliative treatment for TEFs. Covered stents can be inserted endoscopically or radiologically and have positive long-term outcomes (1, 3). However, when

Received December 4, 2023
Revised January 10, 2024
Accepted January 29, 2024
Published Online July 16, 2024

Corresponding author
Suyoung Park, MD
Department of Radiology,
Gil Medical Center,
Gachon University
College of Medicine,
21 Namdong-daero 774beon-gil,
Namdong-gu, Incheon 21565,
Korea.

Tel 82-32-460-3063
Fax 82-32-460-3065
E-mail spgir@naver.com

This is an Open Access article distributed under the terms of the Creative Commons Attribution Non-Commercial License (<https://creativecommons.org/licenses/by-nc/4.0>) which permits unrestricted non-commercial use, distribution, and reproduction in any medium, provided the original work is properly cited.

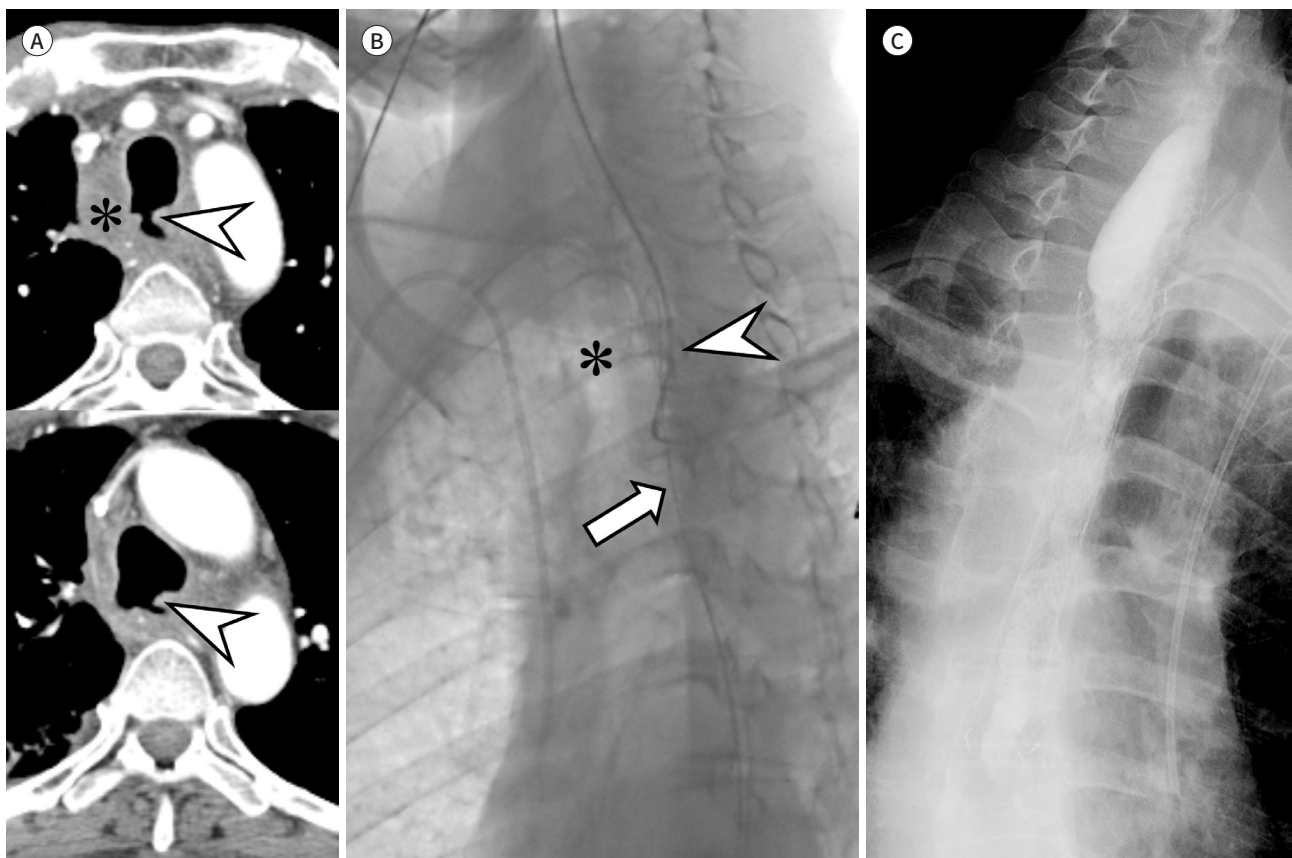
the esophageal stenosis is tight, it can be difficult to find the correct esophageal lumen with a guidewire, and misplacement of the stent in TEF can lead to severe complications (4).

In this report, we discuss a case in which a covered stent was successfully inserted under fluoroscopic guidance using both antegrade and retrograde approaches when a covered stent could not be inserted via the antegrade route, both endoscopically and fluoroscopically, due to esophageal stricture and fistula.

CASE REPORT

A 52-year-old male patient with dysphagia for 1 month underwent an endoscopy and contrast-enhanced CT that revealed a terminal-stage squamous cell carcinoma of the upper esophagus of approximately 6 cm in length. The cancer was compressing the lower trachea and right main bronchus, and the patient underwent percutaneous radiologic gastrostomy (16-Fr Entuit BR; Cook Medical, Bloomington, IN, USA) for enteral nutrition and palliative

Fig. 1. Preprocedural assessment, guidewire cannulation, and postprocedural outcome evaluation of esophageal covered stent insertion. **A.** Preprocedural contrast-enhanced CT images show the reduced state of the esophageal cancer (asterisk) and two tracheoesophageal fistula foci (arrowheads). **B.** Fluoroscopic image shows the successfully cannulated retrograde guidewire (arrow) in the occluded segment of the esophagus. The antegrade catheter (arrowhead) was used as a landmark during retrograde cannulation. The anteriorly located trachea (asterisk) is also shown. **C.** Postprocedural esophagography shows the patent stent lumen with the exclusion of the tracheoesophageal fistula.



chemoradiotherapy before discharge.

One month after the final radiotherapy session, the patient returned to the outpatient clinic with symptoms of cough, sputum, and dysphagia. A contrast-enhanced chest CT revealed a significant decrease in the extent of the esophageal cancer. However, the scan identified two new TEF foci (Fig. 1A) and aspiration pneumonia in the right lower lobe of the lung.

An endoscopic covered stent insertion using a classic antegrade (peroral) approach to treat the TEF was attempted; however, the endoscope could not pass through the occluded esophageal segment and the procedure failed. Therefore, the patient was referred to the interventional radiology department for a radiologic covered stent insertion. The patient was warned of the risk of aspiration but insisted on moderate sedation and received 3 mg of intravenous midazolam before the procedure. Close monitoring and continuous suction were maintained throughout the insertion process.

Initially, cannulation of the occluded segment was attempted with a 5-Fr diagnostic catheter (Cobra, A&A MD, Sungnam, South Korea) and a 0.035-in guidewire (Glidewire, Terumo Interventional Systems, Somerset, NJ, USA) using the antegrade approach, but this method proved unsuccessful. The catheter and guidewire were left in place as landmarks for retrograde cannulation.

A second identical catheter and guidewire were then retrogradely inserted through the enteral feeding route of the gastrostomy tube and entry into the lower esophagus was achieved. The fluoroscopic detector was rotated 50° obliquely, and retrograde cannulation was successfully performed using the previously placed antegrade catheter and guidewire as guidance (Fig. 1B). A through-and-through route was thereby created.

An 18-mm diameter, 12-cm long covered stent (Niti-S; Taewoong, Seongnam, South Korea) was then inserted to sufficiently cover the proximal and distal parts of the occluded segment. Postprocedural esophagography (Fig. 1C) revealed that the stent remained in position without migration and there was good contrast passage through the stent lumen. No evidence of leakage into the respiratory system was noted.

This study was approved by the Institutional Review Board of our institution (IRB No. 2023-354), and the requirement for informed consent was waived.

DISCUSSION

Endoscopic or radiologic insertion of an esophageal stent is typically performed using the antegrade approach. However, in cases with an overt TEF and occluded esophagus, forceful cannulation of the TEF can result in a large perforation that can cause life-threatening mediastinitis. In such cases, a retrograde approach can be attempted if the gastrostomy route is available, and several reports have described the use of the endoscopic antegrade-retrograde rendezvous technique in these situations (5-7).

However, endoscopy has limitations when passing through narrow strictures. Endoscopic devices have large diameters and only provide an intraluminal view of the esophagus, and this creates a challenge for cannulating occluded lesions in patients with severe esophageal stenosis. In these situations, the endoscopy cannot enter because the area beyond the occlusion is not visible. Conversely, the fluoroscopy-guided approach can access narrow areas

with smaller-caliber devices and provide a comprehensive view of the shape, course, and location. Cannulation is simplified and a thorough evaluation of the entire procedure is possible. Therefore, in cases where endoscopic access is not feasible due to an obstructed esophagus, the fluoroscopy-guided approach can be an alternative treatment method.

The through-and-through rendezvous technique is widely used in biliary interventions (8), urinary interventions (9), and trauma interventions (10). This technique is particularly useful when antegrade and retrograde guidewires fail to pass through the occlusive/stenotic lesion and cannot reach the correct lumen. A snare catheter can be used to position the guidewire beyond the lesion from one direction within the correct lumen by capturing the rendezvoused guidewire from another direction in a third space. In our patient, attempts to reach the lower esophageal lumen using the antegrade direction alone were unsuccessful with endoscopy and fluoroscopy. Instead, the guidewire inside the correct lumen was reached using the retrograde approach through the patient's preexisting gastrostomy route.

In summary, our patient had a TEF due to esophageal cancer that was difficult to cannulate using the antegrade endoscopic approach, and we successfully inserted a covered stent using the antegrade-retrograde rendezvous technique under fluoroscopic guidance.

Author Contributions

Conceptualization, P.S.; data curation, P.S.H.; resources, H.J.H., K.J.H.; writing—original draft, P.Y.; and writing—review & editing, P.S.

Conflicts of Interest

The authors have no potential conflicts of interest to disclose.

ORCID iDs

Yoojin Park  <https://orcid.org/0009-0009-2126-2409>
Suyoung Park  <https://orcid.org/0000-0001-9688-3239>
Jung Han Hwang  <https://orcid.org/0000-0002-0872-0956>
Jeong Ho Kim  <https://orcid.org/0000-0002-1404-2821>
So Hyun Park  <https://orcid.org/0000-0001-9935-2863>

Funding

None

REFERENCES

1. Shin JH, Song HY, Ko GY, Lim JO, Yoon HK, Sung KB. Esophagorespiratory fistula: long-term results of palliative treatment with covered expandable metallic stents in 61 patients. *Radiology* 2004;232:252-259
2. Rasmussen SR, Nielsen RV, Fenger AS, Siemsen M, Ravn HB. Postoperative complications and survival after surgical resection of esophageal squamous cell carcinoma. *J Thorac Dis* 2018;10:4052-4060
3. Ross WA, Alkassab F, Lynch PM, Ayers GD, Ajani J, Lee JH, et al. Evolving role of self-expanding metal stents in the treatment of malignant dysphagia and fistulas. *Gastrointest Endosc* 2007;65:70-76
4. Cozorici A, Porumb V, Lunca S, Grigoras I, Ristescu I, Jitaru I, et al. Technical difficulties and procedural complications in closing malignant esophageal-respiratory fistulas. *Acta Clin Croat* 2021;60:703-710
5. Shahein AR, Dempsey A, Boyd R, Quiros JA, Arbizu RA. Combined antegrade-retrograde Rendezvous technique to dilate near complete distal esophageal stenosis. *J Pediatr Gastroenterol Nutr* 2020;71:e146
6. Velásquez-Rodríguez JG, Maisterra S, Gornals JB. Technical variant of EUS-guided recanalization for complete esophageal stenosis: balloon-target assisted Rendezvous approach. *Dig Endosc* 2021;33:e54-e55
7. de Campos ST, Rio-Tinto R, Fidalgo P, Bispo M, Marques S, Devière J. Endoscopic reconstruction of an oral

feeding route using a rendezvous approach. *GE Port J Gastroenterol* 2021;29:420-425

8. Houghton E. Complex percutaneous biliary procedures: review and contributions of a high volume team. *Int J Gastrointest Interv* 2019;8:10-19
9. Keoghane SR, Deverill SJ, Woodhouse J, Shennoy V, Johnston T, Osborn P. Combined antegrade and retrograde access to difficult ureters: revisiting the rendezvous technique. *Urolithiasis* 2019;47:383-390
10. Jeon CH, Kwon H, Kim JH, Bae M, Wang IJ, Kim H, et al. Complete posterior urethral disruption accompanied by complex pelvic fractures: clinical outcomes of fluoroscopic primary posterior urethral realignment. *J Vasc Interv Radiol* 2021;32:343-349

랑데부 방법을 이용한 영상의학적 식도 커버드 스텐트 삽입술: 증례 보고

박유진 · 박수영* · 황정한 · 김정호 · 박소현

저자들은 방사선 치료 후 발생한 기관-식도루에 대해, 투시경을 이용하여 입(정방향) 과 위루 (역방향)를 통하여 식도에 커버드 스텐트를 삽입한 증례를 보고한다. 투시경적 접근법은 내시경적 접근법과 비교하여 덜 침습적이고 성공률이 높을 수 있는데, 이는 투시경적 접근법이 시술 중 식도 바깥쪽의 구조를 파악할 수 있고, 더 얇은 구경의 기구들을 사용하기 때문이다.

가천대학교 의과대학 길병원 영상의학과