



**Jimin Lim<sup>1</sup>, Jin Hyuk Paek<sup>1,2</sup>,  
Hyeong Chan Shin<sup>3</sup>,  
Woo Yeong Park<sup>1,2</sup>, Kyubok Jin<sup>1,2</sup>,  
Misun Choe<sup>3</sup>, Seungyeup Han<sup>1,2</sup>,  
Yaerim Kim<sup>1,2</sup>**

<sup>1</sup>Division of Nephrology, Department of Internal Medicine, Keimyung University School of Medicine, Daegu; <sup>2</sup>Keimyung University Kidney Institute, Daegu; <sup>3</sup>Department of Pathology, Keimyung University School of Medicine, Daegu, Korea

Received: October 16, 2023

Accepted: October 24, 2023

Corresponding author: Yaerim Kim, MD, PhD  
 Division of Nephrology, Department of Internal Medicine, Keimyung University Dongsan Hospital, Keimyung University School of Medicine, 1035 Dalgubeol-daero, Dalseo-gu, Daegu 42601, Korea  
 Tel: +82-53-258-7745, Fax: +82-53-258-4739  
 E-mail: yaerim86@dsmc.or.kr

No potential conflict of interest relevant to this article was reported.

We would like to respect and appreciation to all medical staff around the world who are making a dedicated sacrifice against COVID-19. This study was supported by grant from the Keimyung University Dongsan Hospital (KUDH to Yaerim Kim).



© Korean Vaccine Society.

This is an Open Access article distributed under the terms of the Creative Commons Attribution Non-Commercial License (<https://creativecommons.org/licenses/by-nc/4.0>) which permits unrestricted non-commercial use, distribution, and reproduction in any medium, provided the original work is properly cited.

# Acute interstitial nephritis with acute kidney injury after COVID-19 vaccination: a case report

In the context of the massive spread of coronavirus disease 2019 (COVID-19), the development of a COVID-19 vaccine is urgently needed. The Pfizer-BioNTech COVID-19 vaccine has been widely applied across global populations. Herein, we report a case of acute interstitial nephritis with acute kidney injury in a young healthy subject after administration of the COVID-19 vaccine. A 20-year-old man was admitted with abdominal discomfort and nausea. He had received the Pfizer-BioNTech COVID-19 vaccine 6 days before. At 9 days after vaccination, his kidney function was decreased, with serum creatinine levels of 1.8 mg/dL. Even with supportive care with hydration, his kidney function worsened, and he underwent a kidney biopsy. The pathology findings revealed diffuse interstitial infiltration of inflammatory cells, predominantly comprising lymphocytes, with preservation of the glomerulus. No abnormal findings were noted by immunofluorescence or electron microscopy. Based on a diagnosis of drug-related acute interstitial nephritis, we treated the patient with high-dose prednisolone. After administration of prednisolone, kidney function slowly improved. A close linkage between COVID-19 vaccination and acute interstitial nephritis should be considered in the clinic, despite the low incidence.

**Keywords:** Interstitial nephritis, Acute kidney injury, COVID-19, Case report, Vaccination

## Introduction

The coronavirus disease 2019 (COVID-19) pandemic, which has been characterized by the massive spread of the virus and high fatality rates due to COVID-19, has made the development of vaccines an urgent need. The World Health Organization determined that eleven vaccines against COVID-19, including the AstraZeneca/Oxford, Johnson and Johnson, Moderna, Pfizer BioNTech, Sinopharm, and Sinovac vaccines, meet the necessary criteria for safety and efficacy. Since the first vaccination on December 4, 2020, approximately 13.2 billion vaccinations have been performed worldwide, and 130 million vaccinations have been performed in Korea since the first vaccination on September 4, 2022.

The Pfizer-BioNTech COVID-19 vaccine is comprising of nucleoside-modified messenger RNA (mRNA) encoding a mutated form of the full-length spike protein of severe acute respiratory syndrome coronavirus 2 (SARS-CoV-2) and was the first approved mRNA vaccine [1]. Despite widespread worry about the unexpected side effects of this vaccine, its efficacy and safety as a COVID-19 vaccine were revealed to be acceptable in a large population-based clinical trial [2]. The safety profile of the vac-

cine appears to be comparable with those of other virus vaccines; however, given the expedited process, in-depth monitoring for rare or unexpected side effects is necessary.

Vaccination-related kidney disease has been sporadically reported irrespective of the vaccine type. Most cases involved glomerular disease representing nephrotic syndrome. Recently, several reports have focused on glomerular diseases, such as minimal change disease and immunoglobulin (Ig)A nephropathy, after COVID-19 vaccination [3-5]. Acute interstitial nephritis (AIN) is usually a concomitant finding with other glomerular diseases, and there have been few reports of AIN occurring in isolation after COVID-19 vaccination. However, this has been dismissed as reports of side effects creating potential barriers to large-scale vaccination efforts. Herein, we aim to report the case of AIN with acute kidney injury after Pfizer-BioNTech COVID-19 vaccination in a healthy adult.

## Case Report

A 20-year-old man came to the hospital with abdominal discomfort and nausea. He was previously healthy and was not taking any medicine or herbal medication. He had been performing required military service since June 2020. The patient received the 1st dose of the Pfizer-BioNTech COVID-19 vac-

cine (Pfizer, New York, NY, USA) on June 10, 2021. He experienced abdominal discomfort and nausea 6 days after vaccination, and he was admitted to the hospital on June 19, 2021. On the day of admission, his vital signs were stable. The initial laboratory findings showed increased C-reactive protein (10.85 mg/dL) and serum creatinine (sCr) levels (1.8 mg/dL) with normal results in assessments of the levels of creatine phosphokinase (81 IU/L), aspartate aminotransferase (16 IU/L), and alanine aminotransferase (20 IU/L) (Table 1). Blood and urine culture resulted in no growth of any bacteria. Chest and abdomen X-rays showed nonspecific findings. He was given symptomatic treatment with cimetidine 20 mg, pantoprazole 40 mg, and tiotropamide 50 mg based on 0.9% normal saline hydration. Although the gastrointestinal symptoms subsided, the deteriorated kidney function was sustained.

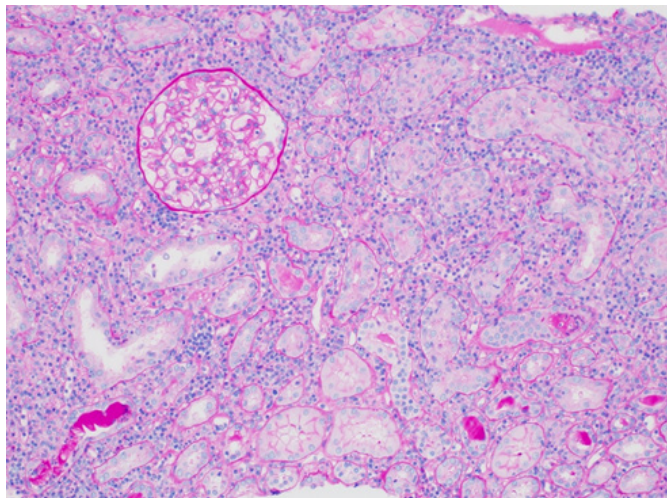
On day 7 of hospitalization, kidney function had worsened (sCr, 2.42 mg/dL) and he had developed proteinuria with a urine protein-to-creatinine ratio of 0.49 g/gCr. A kidney biopsy was performed to evaluate the cause of acute kidney injury. Among the 32 glomeruli, there were no signs of sclerotic changes. A relatively diffuse interstitial infiltration of inflammatory cells was observed, predominantly consisting of lymphocytes, rare plasma cells, histiocytes, neutrophils, and eosinophils (Fig. 1). Mild and patchy interstitial fibrosis with tubular atrophy was noted. No granuloma was identified. Some

**Table 1.** Serial laboratory findings

Variable	On admission	D7 <sup>a)</sup>	D17	D27
Complete blood cells				
White blood cell (10 <sup>3</sup> /μL)	9.21	7.76	9.95	10.94
Hemoglobin (g/dL)	13.4	11.6	12.0	12.0
Platelet (10 <sup>3</sup> /μL)	279	266	296	249
Neutrophil (%)	76.5	72.7	67.3	69.6
Lymphocyte (%)	12.5	15.2	19.8	20.0
Monocyte (%)	8.5	7.5	8.7	7.7
Eosinophil (%)	2.2	4.0	3.7	2.2
Sodium (mEq/L)	145	138	139	142
Potassium (mEq/L)	3.9	3.4	3.7	4.0
Blood urea nitrogen (mg/dL)	21.2	22	22	23
Creatinine (mg/dL)	1.80	2.42	1.45	1.41
Estimated glomerular filtration rate (mL/min/1.73 m <sup>2</sup> )	53.0	37.1	68.8	71.2
Albumin (g/dL)	4.4	3.9	3.7	4.1
C-reactive protein (mg/dL)	10.9	5.3	2.1	1.2
Urine albumin	1+	1+	Trace	Trace
Urine protein to creatinine ratio	ND	0.55	0.39	0.21

D, admission date; ND, not done.

<sup>a)</sup>Methylprednisolone 1 mg/kg was administered from hospital day 10.



**Fig. 1.** Light microscopic findings. Diffuse inflammatory cell infiltration was observed in the interstitium and tubules. Inflammatory cells consisted of lymphocytes, histiocytes, neutrophils, eosinophils, and plasma cells. The glomerulus was relatively unremarkable (PAS stain,  $\times 200$ ).

of the tubules showed tubulitis with patchy infiltration of inflammatory cells and occasional cellular casts. Tubular epithelial injury with regenerative changes, including loss of brush borders, dilatation, flattening, and rare mitotic figures, was noted. The glomeruli rarely showed lymphocytes in the capillary lumen but were otherwise unremarkable. The vessels were unremarkable and did not exhibit vasculitis. On immunohistochemical staining, the infiltrated lymphocytes were mainly CD3- and CD4-positive helper T cells. Immunofluorescence assessments of IgG, IgA, IgM, C3, C4, C1q, lambda, and kappa expression showed no significant deposits in the glomeruli, tubules, and interstitium. No abnormal findings were observed in the glomeruli on electronic microscopy.

Based on a diagnosis of drug-related AIN, we treated the patient with prednisolone 1 mg/kg for 10 days and then tapered it to half of that dose. Renal function was finally improved to the normal range after 2 months of treatment. We finally tapered out the prednisolone treatment over 3 months, and the most recent serum creatinine level was 0.89 mg/dL.

This study was approved by the institutional review board of Keimyung University Dongsan Hospital (IRB no., 2021-07-007). Written informed consent was obtained from the patient for publication of this case report and any accompanying images. Written informed consent was obtained from the patient for publication of this case report and any accompanying images. All authors of the manuscript have read and agreed to its content and are accountable for all aspects of the accuracy

and integrity of the manuscript in accordance with the International Committee of Medical Journal Editors criteria.

## Discussion

The development of COVID-19 vaccines has played a crucial role in restraining the exponential spread of COVID-19. Aggressive vaccination should be performed across the globe based on the extensive evaluation and comprehension of side effects. We reported a case of AIN in a healthy young adult after vaccination for COVID-19. Although it was not a common side effect, this case showed the possibility of the development of interstitial nephritis after vaccination even in healthy subjects without comorbid disease. To make a diagnosis of vaccination-induced AIN, we additionally considered other factors, including herbal medication and other offending drugs, such as proton pump inhibitors, antibiotics, and nonsteroidal anti-inflammatory drugs. However, there was no evidence of exposure to these drugs prior to kidney function deterioration.

The first step in the treatment of drug-induced AIN is the discontinuation of the offending drug. However, this case developed after one shot of the vaccination, and there was no chance to protect against re-exposure to the drug. Corticosteroids use is controversial, but the benefit of corticosteroid use in drug-induced AIN has been reported [6,7]. Cytokine production via inhibition of the key proinflammatory transcription factor nuclear factor- $\kappa$ B has a pivotal role in promoting renal inflammation in AIN [8]. Glucocorticoids block cytokine production and suppress cytokine-mediated tubulointerstitial inflammation in AIN [9]. In this contest, we used prednisolone as a rescue therapy in this case, and the kidney function was fully recovered.

The Pfizer-BioNTech COVID-19 vaccine is based on RNA particles modified with nucleosides, which enter host cells via lipid nanoparticles, produces the SARS-CoV-2 spike (S) protein and stimulates the immune system to produce antibodies against it [10]. The vaccine protects against infection via innate and adaptive immune responses triggered by S protein-specific memory T cells and B cells and anti-S protein antibodies. These immune responses could be linked to immune-mediated diseases, including glomerular disease [4,11]. The initiation of AIN is linked to the expression of endogenous or exogenous antigens processed by tubular cells [12]. Tamm-Horsfall protein is a representative protein, as endogenous antigens induce AIN. This case could be related to a similar process, although the details of the process are unclear.

More than 75% of biopsy-proven AIN is caused by medication exposure. This is a dose-independent mechanism that results in symptom recurrence after subsequent uses of the offending drug [13]. Determining the cause of AIN is difficult because of the various confounding factors. However, in this case, the patient was a healthy young adult without a history of adverse drug reactions. The clinical presentation of deteriorated kidney function 1 week after exposure to the vaccine with typical kidney pathology findings suggested that AIN was closely related to vaccination in the present case. Although 13.5% of subjects who received one dose of the Pfizer-BioNTech COVID-19 vaccine reported systemic side effects [14], there have been reported few cases of typical AIN in a healthy population.

Immunizations are a cornerstone of the nation's efforts to protect people from infectious diseases. Despite the successes of vaccination, pharmacovigilance is an increasingly important topic of public interest. It has been shown that vaccination prevents hospitalization and reduces mortality, so it remains the best option for the pandemic to finally be considered endemic [15]. Therefore, although the incidence is extremely low, the risk of AKI with AIN after Pfizer-BioNTech COVID-19 vaccination warrants consideration based on this case report.

## ORCID

Jimin Lim <https://orcid.org/0000-0003-2457-4466>

Jin Hyuk Paek <https://orcid.org/0000-0001-8875-1260>

Hyeong Chan Shin <https://orcid.org/0000-0002-3716-7678>

Woo Yeong Park <https://orcid.org/0000-0003-2662-2898>

Kyubok Jin <https://orcid.org/0000-0002-7836-8863>

Misun Choe <https://orcid.org/0000-0002-1412-5360>

Seungyeup Han <https://orcid.org/0000-0002-7561-6534>

Yaerim Kim <https://orcid.org/0000-0003-1596-1528>

## References

- Kariko K, Muramatsu H, Welsh FA, et al. Incorporation of pseudouridine into mRNA yields superior nonimmunogenic vector with increased translational capacity and biological stability. *Mol Ther* 2008;16:1833-40.
- Polack FP, Thomas SJ, Kitchin N, et al. Safety and efficacy of the BNT162b2 mRNA COVID-19 vaccine. *N Engl J Med* 2020;383:2603-15.
- Hanna C, Herrera Hernandez LP, Bu L, et al. IgA nephropathy presenting as macroscopic hematuria in 2 pediatric patients after receiving the Pfizer COVID-19 vaccine. *Kidney Int* 2021;100:705-6.
- Maas RJ, Gianotten S, van der Meijden WA. An additional case of minimal change disease following the Pfizer-BioNTech COVID-19 vaccine. *Am J Kidney Dis* 2021;78:312.
- Hassanzadeh S, Djamali A, Mostafavi L, Pezeshgi A. Kidney complications following COVID-19 vaccination; a review of the literature. *J Nephroarmacol* 2022;11:e01.
- Muriithi AK, Leung N, Valeri AM, et al. Biopsy-proven acute interstitial nephritis, 1993-2011: a case series. *Am J Kidney Dis* 2014;64:558-66.
- Gonzalez E, Gutierrez E, Galeano C, et al. Early steroid treatment improves the recovery of renal function in patients with drug-induced acute interstitial nephritis. *Kidney Int* 2008;73:940-6.
- Raghavan R, Shawar S. Mechanisms of drug-induced interstitial nephritis. *Adv Chronic Kidney Dis* 2017;24:64-71.
- Donati A, Krishnan N. Should corticosteroids be used to treat biopsy-proven drug-induced acute interstitial nephritis?: PRO. *Kidney360* 2022;3:1306-9.
- Arunachalam PS, Scott MK, Hagan T, et al. Systems biological assessment of human immunity to BNT162b2 mRNA vaccination. *Res Sq [Preprint]* 2021 Apr 22. <https://doi.org/10.21203/rs.3.rs-438662/v1>
- Abeyagunawardena AS, Goldblatt D, Andrews N, Trompeter RS. Risk of relapse after meningococcal C conjugate vaccine in nephrotic syndrome. *Lancet* 2003;362:449-50.
- Praga M, Gonzalez E. Acute interstitial nephritis. *Kidney Int* 2010;77:956-61.
- Rossert J. Drug-induced acute interstitial nephritis. *Kidney Int* 2001;60:804-17.
- Menni C, Klaser K, May A, et al. Vaccine side-effects and SARS-CoV-2 infection after vaccination in users of the COVID Symptom Study app in the UK: a prospective observational study. *Lancet Infect Dis* 2021;21:939-49.
- Machado BA, Hodel KV, Fonseca LM, et al. The importance of vaccination in the context of the COVID-19 pandemic: a brief update regarding the use of vaccines. *Vaccines (Basel)* 2022;10:591.