

## Original Article



# Ventral Anterior Cingulate Atrophy as a Predisposing Factor for Transient Global Amnesia

Jeewon Suh <sup>1,2,3</sup> Young Ho Park <sup>1,2</sup> Hang-Rai Kim <sup>4</sup> Jae-Won Jang <sup>5</sup>  
SangHak Yi <sup>6</sup> Min Ju Kang <sup>7</sup> Yun Jung Bae <sup>8,9</sup> Byung Se Choi <sup>8,9</sup>  
Jae Hyoung Kim <sup>8,9</sup> SangYun Kim <sup>1,2</sup>

<sup>1</sup>Department of Neurology, Seoul National University Bundang Hospital, Seongnam, Korea

<sup>2</sup>Department of Neurology, Seoul National University College of Medicine, Seoul, Korea

<sup>3</sup>Department of Neurology, National Medical Center, Seoul, Korea

<sup>4</sup>Department of Neurology, Dongguk University Ilsan Hospital, Goyang, Korea

<sup>5</sup>Department of Neurology, Kangwon National University Hospital, Kangwon National University College of Medicine, Chuncheon, Korea

<sup>6</sup>Department of Neurology, Wonkwang University School of Medicine and Regional Cardiocerebrovascular Center, Iksan, Korea

<sup>7</sup>Department of Neurology, Veterans Health Service Medical Center, Seoul, Korea

<sup>8</sup>Department of Radiology, Seoul National University Bundang Hospital, Seongnam, Korea

<sup>9</sup>Department of Radiology, Seoul National University College of Medicine, Seoul, Korea

## OPEN ACCESS

**Received:** Dec 10, 2023

**Revised:** Jan 25, 2024

**Accepted:** Feb 16, 2024

**Published online:** Mar 26, 2024

### Correspondence to

SangYun Kim

Department of Neurology, Seoul National University Bundang Hospital, 82 Gumi-ro 173beon-gil, Bundang-gu, Seongnam 13620, Korea.

Email: neuroksy@snu.ac.kr

### Young Ho Park

Department of Neurology, Seoul National University Bundang Hospital, 82 Gumi-ro 173-beon-gil, Bundang-gu, Seongnam 13620, Korea.

Email: kumimesy@snu.ac.kr


© 2024 Korean Dementia Association

This is an Open Access article distributed under the terms of the Creative Commons Attribution Non-Commercial License (<https://creativecommons.org/licenses/by-nc/4.0/>) which permits unrestricted non-commercial use, distribution, and reproduction in any medium, provided the original work is properly cited.


### ORCID iDs

Jeewon Suh 


<https://orcid.org/0000-0003-3509-6447>

Young Ho Park 

<https://orcid.org/0000-0002-2756-1786>

Hang-Rai Kim 

<https://orcid.org/0000-0003-4197-4541>

Jae-Won Jang 

<https://orcid.org/0000-0003-3540-530X>

SangHak Yi 

<https://orcid.org/0000-0002-2701-9807>

## ABSTRACT

**Background and Purpose:** This study aimed to evaluate the brain magnetic resonance imaging (MRI) of patients with acute transient global amnesia (TGA) using volumetric analysis to verify whether the brains of TGA patients have pre-existing structural abnormalities.

**Methods:** We evaluated the brain MRI data from 87 TGA patients and 20 age- and sex-matched control subjects. We included brain MRIs obtained from TGA patients within 72 hours of symptom onset to verify the pre-existence of structural change. For voxel-based morphometric analyses, statistical parametric mapping was employed to analyze the structural differences between patients with TGA and control subjects.


**Results:** TGA patients exhibited significant volume reductions in the bilateral ventral anterior cingulate cortices (corrected  $p < 0.05$ ).

**Conclusions:** TGA patients might have pre-existing structural changes in bilateral ventral anterior cingulate cortices prior to TGA attacks.

**Keywords:** Transient Global Amnesia; Magnetic Resonance Imaging; Atrophy; Cingulate Cortex

## INTRODUCTION

Transient global amnesia (TGA) is a syndrome characterized by sudden onset of retrograde and anterograde amnesia that lasts up to 24 hours; however, the exact cause of TGA is still unknown.<sup>1</sup> Previous studies have reported that psychological stress, physical stress, and temperature change are the precipitating factors.<sup>1</sup> Although these factors are very common events in everyday life, majority of people do not experience TGA events. Therefore, it is plausible that people who will develop TGA later have some predisposing factors that

Min Ju Kang   
<https://orcid.org/0000-0002-7736-6073>  
Yun Jung Bae   
<https://orcid.org/0000-0002-1779-4949>  
Byung Se Choi   
<https://orcid.org/0000-0001-6310-1798>  
Jae Hyoung Kim   
<https://orcid.org/0000-0002-0545-4138>  
SangYun Kim   
<https://orcid.org/0000-0002-9101-5704>

#### Conflict of Interest

The authors have no financial conflicts of interest.

#### Author Contributions

Conceptualization: Park YH, Yi S, Kim S; Data curation: Suh J, Kim HR, Kang MJ, Bae YJ, Choi BS, Kim JH; Formal analysis: Suh J, Park YH, Jang JW; Investigation: Suh J, Kang MJ; Methodology: Park YH, Kim HR, Jang JW, Yi S, Bae YJ, Choi BS, Kim JH, Kim S; Resources: Kang MJ, Bae YJ, Choi BS, Kim JH; Software: Yi S; Supervision: Park YH, Kim S; Validation: Suh J, Park YH, Kim HR, Jang JW, Yi S; Visualization: Yi S; Writing - original draft: Suh J; Writing - review & editing: Suh J, Park YH, Kim S.

are not present in the others. Many TGA patients show distinctive punctate lesions in the hippocampus on brain magnetic resonance imaging (MRI) diffusion-weighted images.<sup>2</sup> However, these lesions tend to disappear after a certain period, and little is known about structural abnormalities in the brain. To identify the underlying mechanisms and pathophysiology, brain volumetry could be a useful way to detect changes that cannot be detected visually.<sup>3</sup> This study aimed to evaluate the brain MRI data from patients with acute TGA using volumetric analysis to verify whether the brains of TGA patients have pre-existing structural abnormalities.

## METHODS

### Subjects

We retrospectively reviewed the medical records of a consecutive series of TGA patients who visited Seoul National University Bundang Hospital from June 2014 to November 2016 and fulfilled the diagnostic criteria of TGA as stated by Hodges and Warlow.<sup>4</sup> The patients were included on the basis of the following criteria: (i) the patients had never experienced a TGA attack earlier, (ii) the patients' age at the time of examination was between 50 and 75 years, (iii) the patients had no history of cognitive decline before the TGA attack, and (iv) brain MRI was obtained within 72 hours of symptom onset. We excluded all patients whose brain MRI data were inappropriate for volumetric analysis or showed any structural abnormality (e.g., brain tumor or stroke). The patients were evaluated through neurological examination, brain MRI, and routine blood tests.

The control group comprised 20 age- and sex-matched subjects with normal cognition who had participated in a previous study by Wang et al.<sup>5</sup> Informed consent was not required due to the retrospective nature of the study. The waiver for informed consent was approved by the Institutional Review Board (IRB) of Seoul National University Bundang Hospital.

### Brain MRI protocol

MRI was conducted using a 3-tesla MR system (Intera Achieva or Ingenia; Philips Healthcare, Best, the Netherlands) with a 16-channel neurovascular coil or a 32-channel head coil. The MRI protocol included high-resolution and conventional diffusion-weighted imaging (DWI), T1- and T2-weighted imaging, fluid-attenuated inversion recovery imaging, conventional gradient-echo imaging in the transverse plane, T1-weighted imaging in the sagittal plane, 3D time-of-flight angiography of the intracranial region, contrast-enhanced angiography, and contrast-enhanced T1-weighted imaging. DWI was repeated 3 days after symptom onset with the same imaging parameters.<sup>6</sup> Sagittally oriented 3D T1-weighted images with a 1 mm<sup>3</sup> isotropic voxel size were obtained.

### MRI data processing and analysis

A voxel-based analysis was performed using SPM 8 (Institute of Neurology, University College London, London, UK), which was implemented using MATLAB 12 (The Math-Works Inc., Natick, MA, USA). Prior to statistical analysis, all 3D T1-weighted MRI images were spatially normalized into a standard template (International Consortium for Brain Mapping space template—East Asian brain) to remove intersubject variability. The spatially normalized images were then segmented into gray matter, white matter, and cerebrospinal fluid components using an automated process. The images were then smoothed by convolution using a 6 mm isotropic Gaussian kernel. Statistical comparisons between TGA patients and

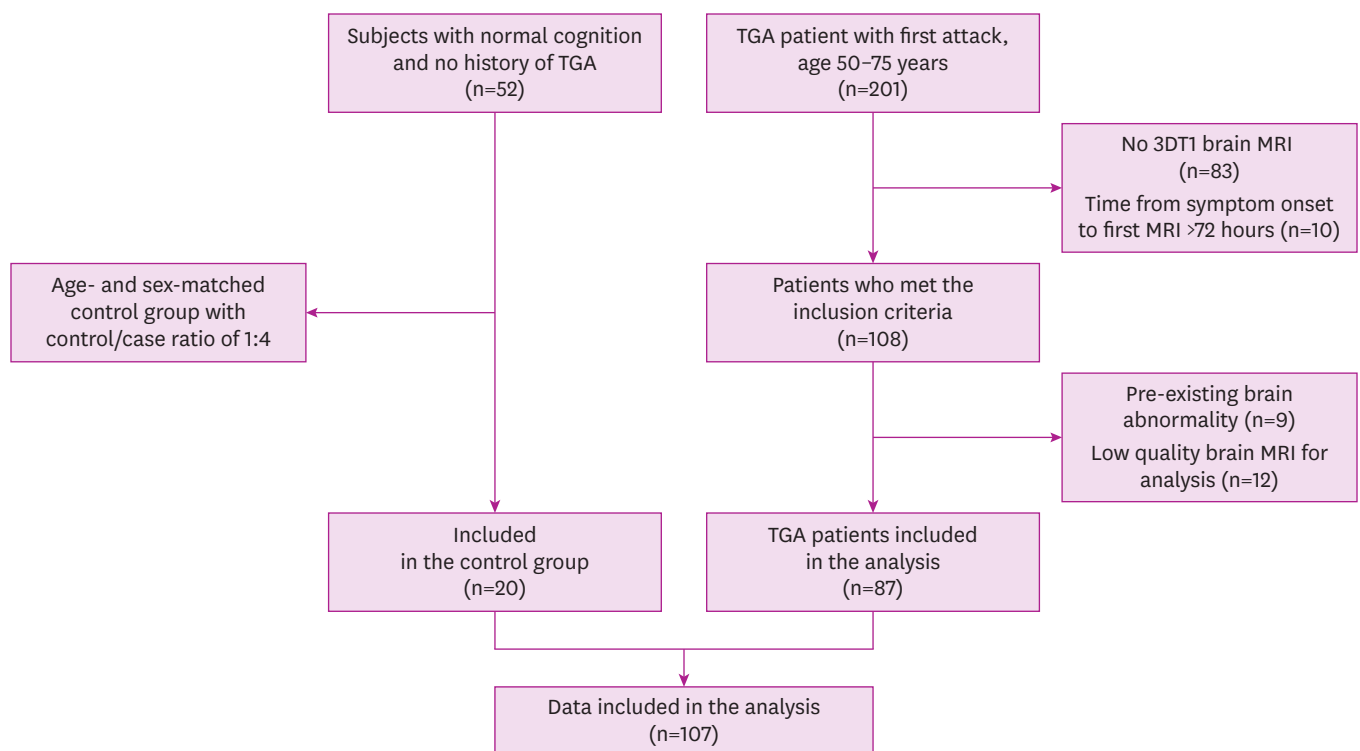
normal controls were performed on a voxel-by-voxel basis by using *t* statistics and generating SPM (*t*) maps. The resulting maps were thresholded using family-wise error (FWE) corrected  $p < 0.05$ . Age and sex were entered as covariates. We also perform voxel-based morphometric (VBM) analysis comparing the TGA patients whose MRI showed characteristic focal DWI lesions in the hippocampus with the TGA patients who did not have any focal DWI lesions.

**Statistical analysis**

Baseline demographic characteristics were compared between TGA patients and normal controls as well as between the included and excluded patients using a Mann–Whitney *U* test or Fisher’s exact test, as appropriate. We also compared the demographics of TGA patients with and without characteristic focal hippocampal lesions on DWI using the same statistical methods. We used SPSS version 19 (SPSS Inc., Chicago, IL, USA). The study protocol was approved by the IRB of Seoul National University Bundang Hospital (B-1803-457-102).

**RESULTS**

We identified 108 consecutive patients with TGA who arrived at the hospital and underwent brain MRI within 72 hours of symptom onset. We excluded 9 patients because their brain MRI showed pre-existing structural abnormalities, such as brain tumor (n=2) or chronic stroke (n=7). In addition, 12 patients were excluded because their brain MRI images were of a very low quality for volumetric analysis. The flow chart of the study population included in the analysis is presented in **Fig. 1**. There were no significant differences in the demographic characteristics between the included and excluded patients (**Supplementary Table 1**). The



**Fig. 1.** The flow chart of the study population included in the analysis.  
TGA: transient global amnesia, MRI: magnetic resonance imaging.

**A Predisposing Factor for TGA**

**Table 1.** Characteristic findings from patients with transient global amnesia

Characteristics	All (n=87)	Patients with DWI lesions (n=77)	Patients without DWI lesions (n=10)	p-value
Female	61 (70.1)	55 (71.4)	6 (60.0)	0.458
Age (yr)	61.48±6.59	61.35±6.74	62.50±5.56	0.553
Symptom duration in hours	6.00 (3.00–8.00)	5.25 (3.00–8.00)	7.00 (4.50–8.25)	0.318
Time from symptom onset to MRI in hours	9.00 (6.00–13.00)	9.00 (6.00–13.00)	8.25 (7.00–10.00)	0.928
Number of focal hippocampal lesions				
0	10 (11.5)			
1	36 (46.8)			
2	24 (27.6)			
3 or more	17 (19.5)			
Precipitating factor				
Physical stress	18 (20.7)	15 (19.5)	3 (30.0)	0.425
Emotional stress	28 (32.2)	26 (33.8)	2 (20.0)	0.490
Temperature change	2 (2.3)	2 (2.6)	0 (0.0)	0.980
Valsalva activity	14 (16.1)	13 (16.9)	1 (10.0)	0.594
Water contact	5 (5.7)	4 (5.2)	1 (10.0)	0.539
Others	4 (4.6)	3 (3.9)	1 (10.0)	0.386
Past medical history				
Hypertension	28 (32.2)	26 (33.8)	2 (20.0)	0.381
Diabetes	5 (5.7)	4 (5.2)	1 (10.0)	0.539
Hyperlipidemia	27 (31.0)	25 (32.5)	2 (20.0)	0.423
Ischemic heart disease	4 (4.6)	3 (3.9)	1 (10.0)	0.386
Migraine	5 (6.5)	5 (6.5)	0 (0.0)	0.407

Data are presented as mean±standard deviation or median (interquartile range) or number (%).  
DWI: diffusion-weighted imaging, MRI: magnetic resonance imaging.

median time interval from TGA symptom onset to MRI was 9.0 hours. The proportion of TGA patients with characteristic 1-5 mm punctate hyperintense lesions in the lateral portion of the hippocampus on DWI was 67.8% (56 out of 87 patients) on the initial MRI and 88.5% (77 out of 87 patients) on the 3-day follow-up MRI. The characteristics of the TGA patients are listed in **Table 1**. The demographic findings showed no significant differences between TGA patients with and without DWI lesions (**Table 1**).

The VBM analysis, comparing 87 TGA patients and 20 normal controls, revealed that TGA patients exhibited significant volume reductions in the bilateral ventral anterior cingulate cortices (**Table 2** and **Fig. 2**) at FWE-corrected  $p < 0.05$ .

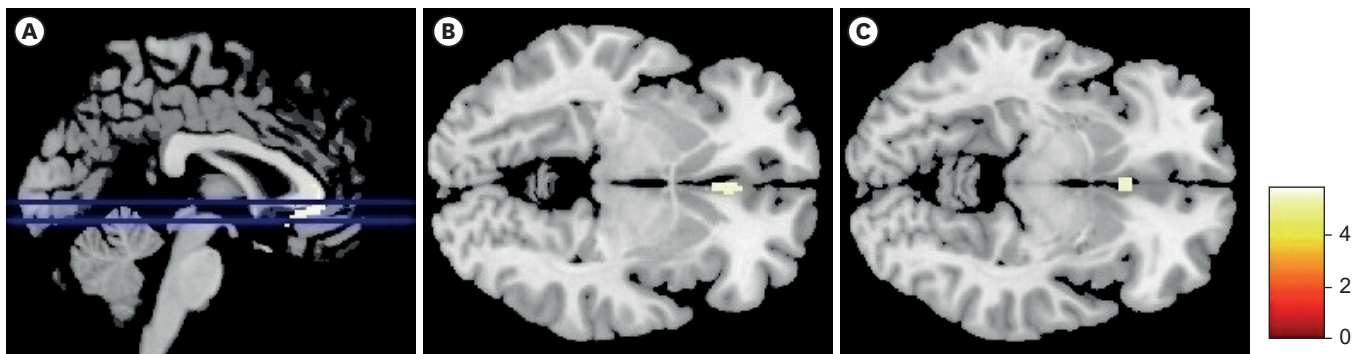
VBM analysis comparing 10 TGA patients whose MRI showed no characteristic focal DWI lesions in the hippocampus with 77 TGA patients who did have characteristic focal DWI lesions showed no statistically significant differences.

## DISCUSSION

In this study, the volume of bilateral ventral anterior cingulate cortices was significantly decreased among TGA patients on brain MRI obtained during the acute stage. This finding suggests that TGA patients have structural changes in the ventral anterior cingulate

**Table 2.** Brain regions displaying reductions in gray matter volumes by voxel-based morphometry in patients with transient global amnesia compared with normal controls

Region	Stereotactic coordinates			Z score	p-value (family-wise error corrected)
	x	y	z		
Right anterior cingulate cortex	0	32	-2	5.39	0.003
Left anterior cingulate cortex	0	24	-6	5.20	0.006



**Fig. 2.** The result of voxel-based morphometry analysis at a statistically significant level,  $p < 0.05$  (family-wise error corrected). (A) Sagittal image, (B) Axial image corresponding to the upper blue line in panel (A), (C) Axial image corresponding to the lower blue line in panel (A). Color bar displays the  $t$ -value.

cortex even prior to a TGA attack and that these changes could be associated with TGA pathogenesis. A previous study using diffusion tensor imaging (DTI) showed that cingulum fiber integrity was significantly decreased in TGA patients compared to healthy controls.<sup>7</sup> Although another study of 26 patients with TGA demonstrated decreased volume in the cingulum as well as in the hippocampus and cerebellum,<sup>8</sup> it is unclear whether the results of that study reflect a pre-existing change in the brain structure among TGA patients or a subsequent result of TGA attack because the timing of brain imaging was not specified. In addition, this previous study analyzed only a small number of patients. Here, we identified that the decreased volume of the ventral anterior cingulate cortex was a pre-existing structural change rather than the result of a TGA attack because our study limited the timing of brain MRI to the acute stage of TGA, unlike previous studies.<sup>7,8</sup>

The cingulate cortex lies in the medial wall of each hemisphere, adjacent to the corpus callosum. The cingulate cortex has anatomical connections with many brain areas, such as the orbitofrontal cortex, basal ganglia, insula, and many other limbic areas, comprising the hippocampal-diencephalic-cingulate network.<sup>9,10</sup> Previous cytoarchitectural studies have suggested that the cingulate cortex could be subdivided into four parts (anterior, middle, posterior, and retrosplenial cortex).<sup>11,13</sup> Although the anterior cingulate cortex is less connected with the parahippocampal regions than the retrosplenial cingulate cortex, the former also has interconnections with anterior thalamic nuclei and parahippocampal regions.<sup>10,14</sup> Functional studies of both normal subjects and patients with psychiatric disorders have established that the anterior cingulate cortex plays important roles in cognition, attention, and emotion.<sup>15</sup> In particular, the anterior cingulate cortex is necessary for normal object memory consolidation and retrieval in animals.<sup>16,17</sup> The ventral division of the anterior cingulate cortex has connections with the amygdala and hippocampal subiculum<sup>18</sup>, and it mediates cognitive influences on emotion, emotion-related learning, and regulation of emotional responses.<sup>15,19</sup> Given these roles of the anterior cingulate cortex, it can be assumed that pre-existing abnormalities in that region might be relevant to TGA attacks. The exact role of decreased anterior cingulate cortex volume needs further investigation.

This study has a potential limitation as it did not use any additional imaging modalities, such as DTI. Further analysis with additional imaging techniques, such as DTI, would be helpful to understand the exact pathophysiology of TGA.

## SUPPLEMENTARY MATERIAL

### Supplementary Table 1

Demographic findings of the included and excluded patients

## REFERENCES

1. Bartsch T, Deuschl G. Transient global amnesia: functional anatomy and clinical implications. *Lancet Neurol* 2010;9:205-214. [PUBMED](#) | [CROSSREF](#)
2. Lee HY, Kim JH, Weon YC, Lee JS, Kim SY, Youn SW, et al. Diffusion-weighted imaging in transient global amnesia exposes the CA1 region of the hippocampus. *Neuroradiology* 2007;49:481-487. [PUBMED](#) | [CROSSREF](#)
3. Giorgio A, De Stefano N. Clinical use of brain volumetry. *J Magn Reson Imaging* 2013;37:1-14. [PUBMED](#) | [CROSSREF](#)
4. Hodges JR, Warlow CP. Syndromes of transient amnesia: towards a classification. A study of 153 cases. *J Neurol Neurosurg Psychiatry* 1990;53:834-843. [PUBMED](#) | [CROSSREF](#)
5. Wang MJ, Yi S, Han JY, Park SY, Jang JW, Chun IK, et al. Analysis of cerebrospinal fluid and [11C]PIB PET biomarkers for Alzheimer's disease with updated protocols. *J Alzheimers Dis* 2016;52:1403-1413. [PUBMED](#) | [CROSSREF](#)
6. Kim J, Kwon Y, Yang Y, Jang IM, Chang Y, Park YH, et al. Clinical experience of modified diffusion-weighted imaging protocol for lesion detection in transient global amnesia: an 8-year large-scale clinical study. *J Neuroimaging* 2014;24:331-337. [PUBMED](#) | [CROSSREF](#)
7. Moon Y, Oh J, Kwon KJ, Han SH. Transient global amnesia: only in already disrupted neuronal integrity of memory network? *J Neurol Sci* 2016;368:187-190. [PUBMED](#) | [CROSSREF](#)
8. Park KM, Han YH, Kim TH, Mun CW, Shin KJ, Ha SY, et al. Pre-existing structural abnormalities of the limbic system in transient global amnesia. *J Clin Neurosci* 2015;22:843-847. [PUBMED](#) | [CROSSREF](#)
9. Hayden BY, Platt ML. Cingulate cortex. In: Squire LR, editor. *Encyclopedia of Neuroscience*. Oxford: Academic Press, 2009;887-892.
10. Bubb EJ, Kinnavane L, Aggleton JP. Hippocampal - diencephalic - cingulate networks for memory and emotion: an anatomical guide. *Brain Neurosci Adv* 2017;1:2398212817723443. [PUBMED](#) | [CROSSREF](#)
11. Vogt BA, Nimchinsky EA, Vogt LJ, Hof PR. Human cingulate cortex: surface features, flat maps, and cytoarchitecture. *J Comp Neurol* 1995;359:490-506. [PUBMED](#) | [CROSSREF](#)
12. Vogt BA, Laureys S. Posterior cingulate, precuneal and retrosplenial cortices: cytology and components of the neural network correlates of consciousness. *Prog Brain Res* 2005;150:205-217. [PUBMED](#) | [CROSSREF](#)
13. Choo IH, Lee DY, Oh JS, Lee JS, Lee DS, Song IC, et al. Posterior cingulate cortex atrophy and regional cingulum disruption in mild cognitive impairment and Alzheimer's disease. *Neurobiol Aging* 2010;31:772-779. [PUBMED](#) | [CROSSREF](#)
14. Jones BF, Witter MP. Cingulate cortex projections to the parahippocampal region and hippocampal formation in the rat. *Hippocampus* 2007;17:957-976. [PUBMED](#) | [CROSSREF](#)
15. Stevens FL, Hurley RA, Taber KH. Anterior cingulate cortex: unique role in cognition and emotion. *J Neuropsychiatry Clin Neurosci* 2011;23:121-125. [PUBMED](#) | [CROSSREF](#)
16. Weible AP, Rowland DC, Monaghan CK, Wolfgang NT, Kentros CG. Neural correlates of long-term object memory in the mouse anterior cingulate cortex. *J Neurosci* 2012;32:5598-5608. [PUBMED](#) | [CROSSREF](#)
17. Pezze MA, Marshall HJ, Fone KC, Cassaday HJ. Role of the anterior cingulate cortex in the retrieval of novel object recognition memory after a long delay. *Learn Mem* 2017;24:310-317. [PUBMED](#) | [CROSSREF](#)
18. Drevets WC, Savitz J, Trimble M. The subgenual anterior cingulate cortex in mood disorders. *CNS Spectr* 2008;13:663-681. [PUBMED](#) | [CROSSREF](#)
19. Bush G, Luu P, Posner MI. Cognitive and emotional influences in anterior cingulate cortex. *Trends Cogn Sci* 2000;4:215-222. [PUBMED](#) | [CROSSREF](#)