

# Experiencing cardiac arrest during surgical exploration in hemodynamically stable patients with multiple stab wounds, including lower extremity in Korea: a case report

Jung Rae Cho, MD<sup>1</sup> , Dae Sung Ma, MD<sup>2</sup> 

<sup>1</sup>Department of Surgery, Trauma Center, Dankook University Hospital, Cheonan, Korea

<sup>2</sup>Department of Thoracic and Cardiovascular Surgery, Trauma Center, Dankook University Hospital, Cheonan, Korea

Received: April 24, 2024

Revised: May 24, 2024

Accepted: May 31, 2024

### Correspondence to

Dae Sung Ma, MD

Department of Thoracic and  
Cardiovascular Surgery, Trauma Center,  
Dankook University Hospital, 201  
Manghyang-ro, Dongnam-gu,  
Cheonan 31116, Korea  
Tel: +82-41-550-6868  
Email: pegamu@dkuh.co.kr

Stab wounds, particularly those affecting multiple body regions, present considerable challenges in trauma care. This report describes a case of sustained self-inflicted stab injuries to the abdomen and thighs of a 23-year-old male patient. Although the patient's vital signs were stable and bleeding was minimal from thigh wounds without overt signs of vascular injury, the patient experienced a sudden, profound hemorrhage from the right thigh, leading to cardiac arrest. Successful resuscitation was followed by surgical repair of a right superficial femoral arterial injury accompanying a resuscitative endovascular balloon of the aorta. Subsequent lower extremity computed tomography angiography revealed no additional vascular abnormalities. The patient was discharged in stable condition on the 12th postoperative day. This case underscores the unpredictability of stab wound trajectories and the potential for hidden vascular injuries, even in the absence of immediate life-threatening signs. It also emphasizes the critical role of advanced imaging modalities, such as computed tomography angiography, in identifying concealed injuries, and the importance of strategic intraoperative techniques, including resuscitative endovascular balloon occlusion of the aorta, in achieving favorable patient outcomes.

**Keywords:** Stab wounds; Vascular system injuries; Balloon occlusion; Case reports

## INTRODUCTION

Stab wounds caused by pointed instruments often create internal tracks deeper than the external length of the skin. Their management requires a thorough and interdisciplinary strategy, particularly when multiple body areas are involved.

This report presents the case of a 23-year-old male patient hospitalized due to multiple self-inflicted stab wounds to the abdo-

men and both thighs. Despite initially stable vital signs and the absence of life-threatening signs, excessive bleeding from the right thigh during surgery led to cardiac arrest.

## CASE REPORT

A 23-year-old male patient arrived at Dankook University Hospital (Cheonan, Korea) with multiple self-inflicted stab wounds on

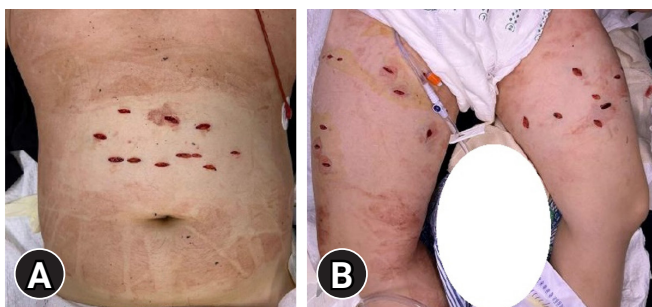
his abdomen and both thighs (Fig. 1). He exhibited stable vital signs, including a systolic blood pressure of 138 mmHg and respiratory rate of 22 breaths/min, with minimal bleeding from the thigh wounds and no hard signs of vascular injury. An abdominopelvic computed tomography (CT) scan was performed to detect potential intraperitoneal injuries. Concerned about the potential peritoneal injuries indicated by the CT scans, we opted for laparoscopy to investigate any concealed intra-abdominal organ damage. Laparoscopy revealed a hematoma in the abdominal cavity but no definitive internal organ damage, indicating limited injury to the abdominal wall.

Following laparoscopy, multiple thigh lacerations were explored before repair in the operating room. However, during irrigation of the right lower extremity wound in preparation for suturing, sudden and profound bleeding ensued from the wound on the right thigh. As the bleeding could not be controlled by direct wound compression alone, additional manual compression of the proximal femoral artery was needed. The wound was extended for better visualization. During this procedure, the patient experienced cardiac arrest but was successfully resuscitated following 3 minutes of cardiopulmonary resuscitation. To control the femoral artery bleeding, we initially performed an ipsilateral cutdown procedure on the proximal femoral artery due to the insufficient space for a tourniquet. However, this approach was time-consuming due to the patient's obesity (body mass index, 29.57 kg/m<sup>2</sup>). Therefore, as an alternative, an 8F angiocatheter sheath was inserted on the contralateral side for resuscitative endovascular balloon occlusion of the aorta (REBOA) (Fig. 2). Following inflation with 8 mL of saline in the zone 3 REBOA, bleeding from the right superficial femoral artery was observed (Fig. 3). The damaged artery was repaired using a prolene 6-0 suture. Upon deflation of REBOA, the absence of bleeding and the intact arterial pulsation confirmed the procedure's success. The estimated blood loss during the operation was 1,500 mL, and the patient received a total of 8 units of packed red blood cells.

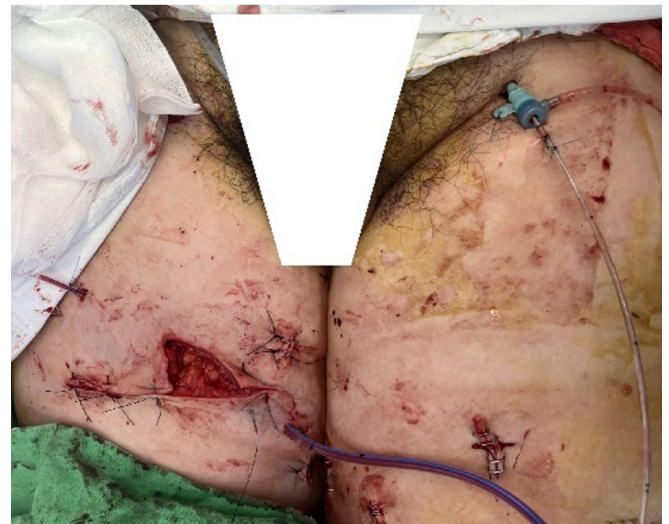The patient underwent a lower extremity CT angiography postoperatively, confirming no further vascular abnormalities, and was discharged home in a stable condition on the 12th postoperative day.

**Ethics statement**

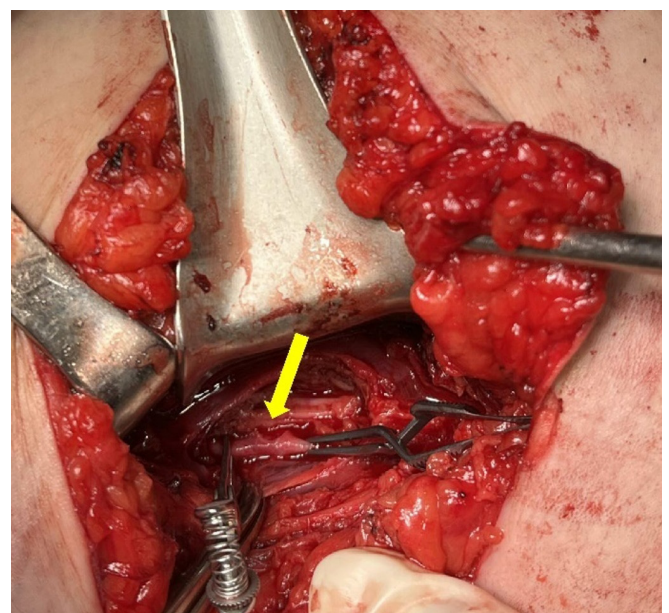
This study was approved by the Institutional Review Board of Dankook University Hospital (No. DKUH 2024-04-005). While the requirement for informed consent was waived due to the ret-



**Fig. 1.** Images of the patient upon arrival. (A) Abdominal multiple stab injuries. (B) Multiple stab injuries in both thighs.



**Fig. 2.** Intraoperative insertion of resuscitative endovascular balloon occlusion of the aorta into the left femoral artery.



**Fig. 3.** Laceration observed in the right superficial femoral artery (arrow).

rospective nature of the study, written informed consent for publication of the research details and clinical images was obtained from the patient.

## DISCUSSION

Management of lower extremity arterial injuries focuses on two primary objectives: preserving the patient's life and saving the limb. Lower limb arterial injury carries a mortality rate of up to 7.7% and an amputation rate of up to 11.3% [1–6]. Moreover, it can lead to systemic complications (pulmonary embolism or rhabdomyolysis), limb complications (deep vein thrombosis, infection, or nerve dysfunction), or arterial complications (thrombosis, stenosis, pseudoaneurysm, or arteriovenous fistula) [7]. Accurate decision-making necessitates assessing vascular integrity, soft tissues, skeletal structure, and neurological function of the limb. An emergency exploration is indicated by clinical hard signs of vascular injury: absent distal pulses, limb ischemia, active hemorrhage, expanding or pulsatile hematoma, bruit or thrill in the area of injury, compartment syndrome, or shock unresponsive to initial fluid resuscitation. In contrast, an imaging workup is necessary in case of clinical soft signs: venous oozing, nonexpanding or nonpulsatile hematoma, diminished distal pulses, or an abnormal ankle-brachial index or brachial-brachial index [8,9]. Although catheter-based angiography has been the gold standard for vascular imaging, the emergence of multidetector CT has revolutionized the initial evaluation of patients with trauma using rapid and noninvasive techniques [9–11].

In this case, while the lower extremity injury did not present hard signs necessitating immediate surgical intervention, the accompanying abdominal stab injury required surgery due to concerns about peritoneal penetration. Therefore, we decided to proceed with abdominal exploration in the operating room following laparoscopic evaluation, without additional imaging workup for the extremity. Unexpectedly, significant bleeding from the superficial femoral artery was observed during wound irrigation after laparoscopy, resulting in cardiac arrest. The complexity of controlling such bleeding, particularly insufficient with proximal arterial compression alone, highlights the unforeseen nature of this type of intraoperative event. Due to the patient's obesity, delayed proximal artery clamping with a cutdown procedure on the ipsilateral side led to the deployment of REBOA on the contralateral side. Familiarity with REBOA at our center facilitated its successful intraoperative utilization with zone 3 inflation, effectively mitigating bleeding and enabling arteriorrhaphy of the damaged vessel. Despite cuff compression being considered an alternative,

the awkward positioning of the injured artery renders this option impractical.

This case underscores the importance of suspecting vascular injury in hemodynamically stable patients with stab injuries to the extremities, given the inherent difficulty in assessing the depth of such wounds, even in the absence of overt clinical signs or symptoms.

## ARTICLE INFORMATION

### Author contributions

Conceptualization: all authors; Writing—original draft: JRC; Writing—review & editing: all authors. All authors read and approved the final manuscript.

### Conflicts of interest

The authors have no conflicts of interest to declare.

### Funding

The authors received no financial support for this study.

### Data availability

Data sharing is not applicable as no new data were created or analyzed in this study.

## REFERENCES

1. Derbel B, Mazzaccaro D, Krarti N, et al. Penetrating vascular injuries of the lower limbs after stab wounds: predictive factors of limb loss and mortality. *J Clin Med* 2023;12:3476.
2. Alarhayem AQ, Cohn SM, Cantu-Nunez O, Eastridge BJ, Rasmussen TE. Impact of time to repair on outcomes in patients with lower extremity arterial injuries. *J Vasc Surg* 2019;69:1519–23.
3. Liang NL, Alarcon LH, Jeyabalan G, Avgerinos ED, Makaroun MS, Chaer RA. Contemporary outcomes of civilian lower extremity arterial trauma. *J Vasc Surg* 2016;64:731–6.
4. Tan TW, Joglar FL, Hamburg NM, et al. Limb outcome and mortality in lower and upper extremity arterial injury: a comparison using the National Trauma Data Bank. *Vasc Endovascular Surg* 2011;45:592–7.
5. Topal AE, Eren MN, Celik Y. Lower extremity arterial injuries over a six-year period: outcomes, risk factors, and management. *Vasc Health Risk Manag* 2010;6:1103–10.
6. Kauvar DS, Sarfati MR, Kraiss LW. National trauma databank analysis of mortality and limb loss in isolated lower extremity

- vascular trauma. *J Vasc Surg* 2011;53:1598–603.
7. O'Shea AE, Lee C, Kauvar DS. Analysis of concomitant and isolated venous injury in military lower extremity trauma. *Ann Vasc Surg* 2022;87:147–54.
  8. Franz RW, Shah KJ, Halaharvi D, Franz ET, Hartman JF, Wright ML. A 5-year review of management of lower extremity arterial injuries at an urban level I trauma center. *J Vasc Surg* 2011;53:1604–10.
  9. Inaba K, Branco BC, Reddy S, et al. Prospective evaluation of multidetector computed tomography for extremity vascular trauma. *J Trauma* 2011;70:808–15.
  10. Chen Zhou ZH, Martinez Chamorro E, Ibanez Sanz L, Sanz De Lucas R, Chico Fernandez M, Borrueal Nacenta S. Traumatic arterial injuries in upper and lower limbs: what every radiologist should know. *Emerg Radiol* 2022;29:781–90.
  11. Adibi A, Krishnam MS, Dissanayake S, et al. Computed tomography angiography of lower extremities in the emergency room for evaluation of patients with gunshot wounds. *Eur Radiol* 2014;24:1586–93.