

Pyogenic granuloma of the hard palate leading to alveolar cleft: a case report

Woo Jin Song, Hyun Beom Choi, Min Sung Tak

Department of Plastic and Reconstructive Surgery, Soonchunhyang University Seoul Hospital, Soonchunhyang University College of Medicine, Seoul, Korea

This case report describes a rare occurrence of pyogenic granuloma (PG) in the hard palate deviating from its typical gingival location that led to the formation of an alveolar cleft. The aggressive growth pattern of the lesion, with atypical progression from a pedunculated nodule to an alveolar cleft, raised concern. The diagnosis was based on magnetic resonance imaging and computed tomography findings, which revealed a tadpole-shaped lesion originating from the midline hard palate. The differential diagnosis included a minor salivary gland tumor. Surgical excision was performed under general anesthesia and resulted in a mucosal defect without nasolabial fistula formation or bone exposure. The palatal defect was packed with oxidized regenerated cellulose and closed with Vicryl Rapide sutures, both of which contributed to the patient's successful outcomes. Our comprehensive approach, extending across the stages of surgical planning, execution, and postoperative care, demonstrated the advantages of a multidisciplinary strategy for the accurate diagnosis and effective treatment of palatal PGs. This report makes a meaningful contribution to the existing literature on common oral lesions by emphasizing the importance of a broad differential diagnosis and a systematic approach to oral pathologies. It also raises clinical awareness of PGs with atypical presentations and the diagnostic challenge that they pose.

Abbreviations: CT, computed tomography; MRI, magnetic resonance imaging; PG, pyogenic granuloma

Keywords: Case reports / Granuloma / Orofacial cleft / Orthodontics / Pyogenic

INTRODUCTION

Pyogenic granulomas (PGs) are mostly benign vascular lesions that can occur at cutaneous or mucosal sites; mucosal PGs predominantly occur in the oral cavity, with approximately 75% of cases presenting in a gingival location. The etiology of PG is multifactorial and includes hormonal changes, chronic irritation, drug reactions, vascular abnormalities, and angiogenic

imbalances. PGs are reactive oral pathologies, the development of which involves an inflammatory response to a stimulus, along with vascular and tissue remodeling [1]. The female-to-male ratio for PGs is approximately 1.5:1, with hormones such as progesterone and estrogen significantly influencing the development of these lesions [2]. The vascular effects of female sex hormones are likely responsible for their higher prevalence in young women, particularly in their second decade of life.

PGs occurring in the hard palate are rare and necessitate a comprehensive differential diagnosis to exclude conditions such as minor salivary gland tumors, peripheral ossifying fibroma, peripheral giant cell granuloma, parulis, gingival squamous cell carcinoma, angiosarcoma, Kaposi sarcoma, and granular cell tumor [3,4]. The accurate diagnosis of PG relies on both clinical examination and imaging techniques, specifically computed tomography (CT) and magnetic resonance imaging

Correspondence: Min Sung Tak

Department of Plastic and Reconstructive Surgery, Soonchunhyang University Seoul Hospital, Soonchunhyang University College of Medicine, 59 Daesagwan-ro, Yongsan-gu, Seoul 04401, Korea
E-mail: tarkms@naver.com

How to cite this article:

Song WJ, Choi HB, Tak MS. Pyogenic granuloma of the hard palate leading to alveolar cleft: a case report. Arch Craniofac Surg 2024;25(3):150-154. <https://doi.org/10.7181/acfs.2024.00080>

Received February 11, 2024 / Revised March 22, 2024 / Accepted June 18, 2024

(MRI). These imaging modalities play a crucial role in assessing the extent of the lesion and the involvement of adjacent structures [5-7]. Typically, the symptomatic presentation of PGs facilitates early intervention, thereby minimizing the risk of significant lesion growth. However, when extensive growth does occur, it can lead to complications such as cleft palate or alveolar cleft, which affect speech and facial aesthetics. In such cases, patients will require alveolar cleft repair to achieve functional rehabilitation and aesthetic restoration [8].

This case report describes the management of a large PG in the hard palate of a 22-year-old woman that resulted in the formation of an alveolar cleft. The lesion was unusual not only in terms of its location, but also its size and progression. We discuss the clinical presentation, diagnosis, treatment, and histopathological findings, emphasizing the critical role of surgical excision in minimizing the risk of recurrence. Additionally, the report highlights the importance of recognizing atypical presentations of PGs and the value of comprehensive evaluations in managing these oral pathologies.

CASE REPORT

A 22-year-old woman with a documented history of cerebral aneurysm and myasthenia gravis presented with a persistent, palpable mass in the hard palate, which she had first noticed 9 months earlier. The initial assessment at a dental practice suggested that the mass was a stress-related inflammatory lesion. However, the patient experienced intermittent periods of improvement and worsening, culminating in significant deterioration 2 months before her presentation at our hospital. The clinical manifestations included sporadic bleeding and notable changes in articulation, although the mass remained non-tender upon palpation.

An intraoral examination revealed a protruding, fungating, soft mass originating from the anterior hard palate between the central incisors (Fig. 1). The lesion was approximately 2 × 1 cm in size and exhibited characteristics that raised concerns about potential malignancy. Consequently, further diagnostic imaging was conducted. MRI identified a 1.9 × 1.6 × 1.0 cm tadpole-shaped lesion with high T2 signal intensity and enhancement, originating from the midline of the hard palate and extending

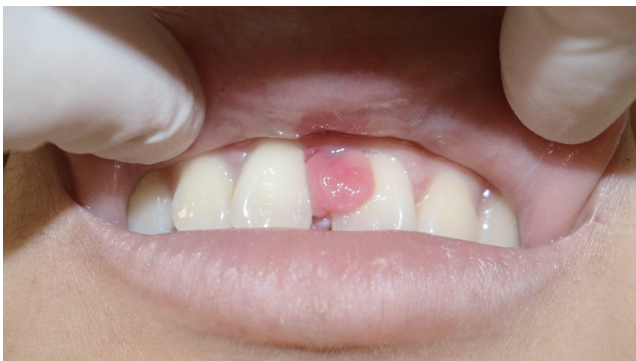

Fig. 1. A 22-year-old woman with a non-tender palpable mass on the hard palate, leading to sporadic bleeding and noticeable changes in articulation. A preoperative frontal view showing a protruding, fungating mass located in the anterior hard palate between the central incisors.

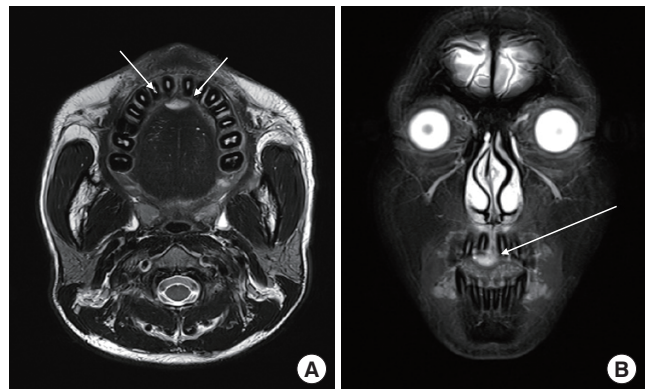


Fig. 2. Magnetic resonance imaging reveals a 1.9 × 1.6 × 1.0 cm tadpole-shaped (arrows), T2-high-signal-intensity lesion in the midline hard palate, suggestive of a minor salivary gland tumor. (A) Axial view. (B) Coronal view.

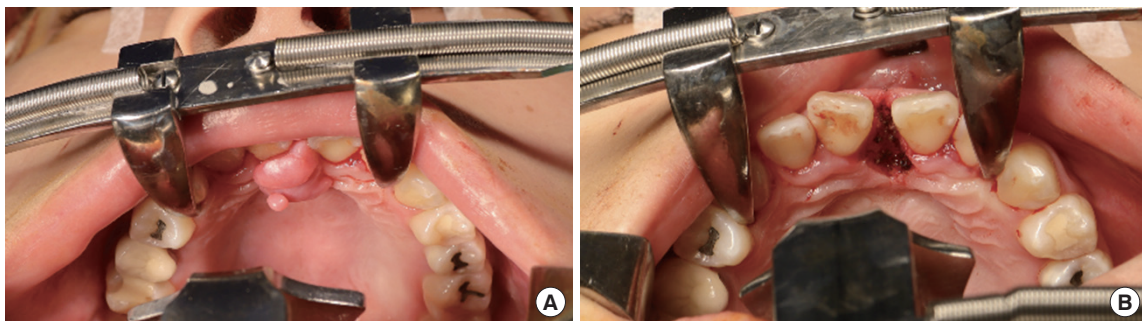


Fig. 3. Intraoperative photographs: (A) palatal view and (B) after complete excision.

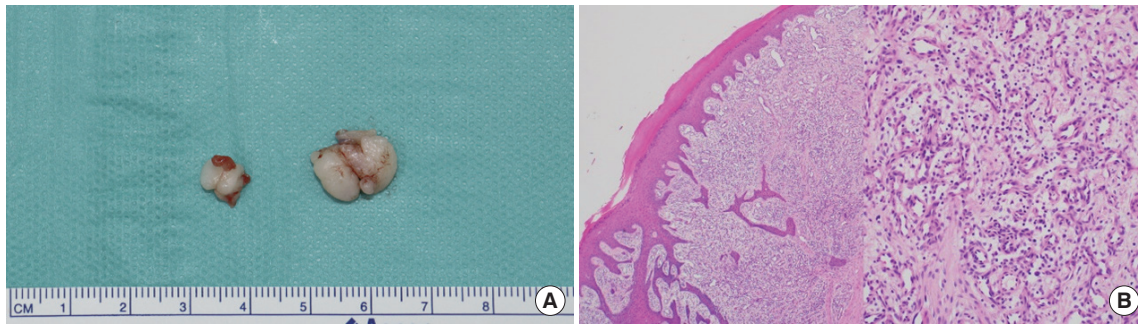


Fig. 4. Pathological examinations. (A) Excised specimen. (B) Photomicrograph (hematoxylin and eosin, $\times 40$, $\times 100$).

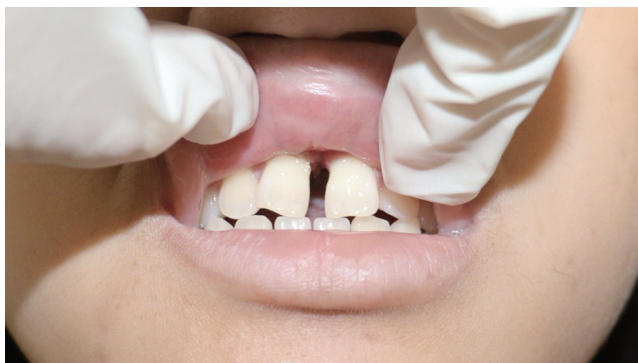

Fig. 5. Postoperative photograph: 1 week after complete excision.

into the incisor area (Fig. 2). An enhanced CT scan confirmed these findings. Based on both imaging modalities, the differential diagnosis included a minor salivary gland tumor. Notably, approximately 8 mm of bone loss was seen in the alveolar ridge between the incisors, suggesting an alveolar cleft caused by the mass.

An incisional biopsy confirmed a diagnosis of PG. Despite the lesion's benign nature, a complete excision was planned to address both functional and aesthetic concerns and to definitively rule out malignancy. The surgery, performed under general anesthesia, revealed a 1×0.5 cm mucosal defect without any nasolabial fistula or bone exposure (Fig. 3). Postoperative care involved packing the palatal defect with oxidized regenerated cellulose, specifically SurgiGuard (Samyang Biopharmaceuticals Corp.). The surgical site was secured using 4/0 Vicryl Rapide sutures (Ethicon, Inc.). Macroscopically, the mass presented a lobulated, whitish-brown appearance with focal hemorrhage on the surface; microscopically, it showed a compact proliferation of capillary-sized blood vessels, indicative of PG (Fig. 4). The patient's recovery proceeded without complications, and she was subsequently scheduled for orthodontic treatment to address dental alignment issues caused by the PG (Fig. 5).

DISCUSSION

This case report presents a patient with a PG in the hard palate that led to an alveolar cleft. The location of the lesion was rare, notably contrasting with the usual gingival location of mucosal PGs, particularly in the anterior maxilla [9]. Oral PGs account for approximately 3.8% to 7% of oral biopsy diagnoses and are often associated with mild trauma or hormonal changes, particularly during pregnancy. They usually appear as red, soft, pedunculated nodules, averaging 1.3 cm in size. In this case, the lesion's progression to the extent of causing an alveolar cleft suggests atypical and aggressive growth. The recurrence rate of PG is around 15%, with higher rates observed in gingival locations. However, recurrence following the surgical removal of an extralingival PG is rare [10]. Although PGs have occasionally been linked to medication use, with cyclosporine and carbamazepine implicated in some instances, no such association was found in our patient [11].

The diagnosis was complicated by the lesion's unusual presentation and the necessity to differentiate it from more serious conditions such as salivary gland tumors or malignancy [1]. An incisional biopsy facilitated early assessment, while MRI and CT scans were crucial in evaluating the lesion, revealing its size, characteristics, potential bone destruction, and the presence of foreign bodies. This comprehensive approach enabled a targeted surgical strategy and helped to exclude malignancy. In this instance, the mass was situated between the patient's central incisors and was visible from the front, displaying characteristics typical of PG. The lesion, approximately 2 cm in size and adhering to the hard palate, was expected to result in a significant palatal defect upon excision. The lesion was relatively hard, which is consistent with the tendency for younger lesions to be soft but become increasingly rubbery as they mature. Additionally, the development of an alveolar cleft had already presented functional challenges for the patient.

Surgical excision is the recommended treatment for PGs, with a suggested excision margin of 2 mm and a depth extending to

the periosteum. Alternative treatment methods, including cryosurgery, laser-assisted removal, and sclerotherapy, have generally demonstrated high success rates and infrequent recurrence [12]. In the present case, both the surgical procedure and the postoperative care regimen were planned and executed with the goal of optimizing outcomes. Oxidized regenerated cellulose, used to induce secondary intention healing in mucosal defects remaining after surgery, promotes clotting and reduces inflammation, making it suitable for controlling hemorrhage and treating small-to-moderate-sized clefts of the palate [13]. The success of the surgery, coupled with the absence of postoperative complications, demonstrates the effectiveness of our management strategy. Furthermore, the postsurgical implementation of corrective orthodontics will address dental misalignment and thus alleviate the patient's long-term functional and aesthetic concerns. Generally, an alveolar cleft requires interventions such as gingivoperiosteoplasty or bone grafting [14]. None of these procedures were necessary for our patient, as there were no complications such as nasolabial fistula or bone exposure. However, the possibility of these interventions should be considered prior to surgery [8].

In conclusion, the case presented herein underscores the necessity for a comprehensive and systematic approach in treating PGs, especially those with atypical presentations, and emphasizes the importance of an accurate diagnosis. It also highlights the critical need for careful preoperative planning, precise and accurate surgical execution, and attentive postoperative care when managing complex oral pathologies. Therefore, our case report adds significant value to the existing medical literature on common oral lesions.

NOTES

Conflict of interest

No potential conflict of interest relevant to this article was reported.

Funding

This work was supported by the Soonchunhyang University Research Fund.

Ethical approval

The report was approved by the Institutional Review Board of Soonchunhyang University Hospital (IRB No. 2023-12-019).

Patient consent

The patient provided written informed consent for the publication and use of her images.

ORCID

Woo Jin Song <https://orcid.org/0000-0002-8957-3950>
Hyun Beom Choi <https://orcid.org/0009-0008-0359-9174>
Min Sung Tak <https://orcid.org/0000-0003-4919-5171>

Author contributions

Writing - original draft: Woo Jin Song. Writing - review & editing: Min Sung Tak. Investigation: Hyun Beom Choi. Supervision: Min Sung Tak. Approval of final manuscript: all authors.

REFERENCES

1. Lomeli Martinez SM, Carrillo Contreras NG, Gomez Sandoval JR, Zepeda Nuno JS, Gomez Mireles JC, Varela Hernandez JJ, et al. Oral pyogenic granuloma: a narrative review. *Int J Mol Sci* 2023;24:16885.
2. Davies MG, Barton SP, Atai F, Marks R. The abnormal dermis in pyogenic granuloma: histochemical and ultrastructural observations. *J Am Acad Dermatol* 1980;2:132-42.
3. Kumar M, Koshal N, Mittal S, Vinayak V, Sharma A. Pyogenic granuloma of hard palate: a rare case report. *Int J Contemp Surg* 2013;1:30-2.
4. Skoglund LA, Holst E. Granular cell tumor on the alveolar ridge in an adult patient. Report of a case. *Int J Oral Surg* 1983;12:60-3.
5. Sills ES, Zegarelli DJ, Hoschander MM, Strider WE. Clinical diagnosis and management of hormonally responsive oral pregnancy tumor (pyogenic granuloma). *J Reprod Med* 1996; 41:467-70.
6. Sooriyamoorthy M, Gower DB. Hormonal influences on gingival tissue: relationship to periodontal disease. *J Clin Periodontol* 1989;16:201-8.
7. Mahabob N, Kumar S, Raja S. Palatal pyogenic granuloma. *J Pharm Bioallied Sci* 2013;5(Suppl 2):S179-81.
8. Kyung H, Kang N. Management of alveolar cleft. *Arch Craniofac Surg* 2015;16:49-52.
9. Koo MG, Lee SH, Han SE. Pyogenic granuloma: a retrospective analysis of cases treated over a 10-year. *Arch Craniofac Surg* 2017; 18:16-20.
10. Frumkin N, Nashef R, Shapira L, Wilensky A. Nonsurgical treatment of recurrent gingival pyogenic granuloma: a case report. *Quintessence Int* 2015;46:539-44.
11. Ghalayani P, Hajisadeghi S, Babadi F. Extragingival pyogenic granuloma associated with medication: report of an unusual case. *Dent Res J (Isfahan)* 2014;11:400-4.
12. Gadea Rosa C, Cartagena Lay A, Caceres La Torre A. Oral pyogenic granuloma diagnosis and treatment: a series of cases. *Revista Odontológica Mexicana* 2017;21:253-61.

13. Patarapongsanti A, Bandhaya P, Sirinirund B, Khongkhunthian S, Khongkhunthian P. Comparison of platelet-rich fibrin and cellulose in palatal wounds after graft harvesting. *J Investig Clin Dent* 2019;10:e12467.
14. Kim J, Jeong W. Secondary bone grafting for alveolar clefts: surgical timing, graft materials, and evaluation methods. *Arch Craniofac Surg* 2022;23:53-8.