



Summary of Key Points of the Response Assessment in Neuro-Oncology (RANO) 2.0

Sang Eun Won^{1*}, Chong Hyun Suh^{2*}, Sinae Kim¹, Hyo Jung Park², Kyung Won Kim²

¹Asan Image Metrics, Clinical Trial Center, Asan Medical Center, University of Ulsan College of Medicine, Seoul, Republic of Korea

²Department of Radiology and Research Institute of Radiology, Asan Medical Center, University of Ulsan College of Medicine, Seoul, Republic of Korea

Keywords: RANO 2.0; Imaging response assessment; Gliomas

The Response Assessment in Neuro-Oncology (RANO) working group has introduced various response assessment criteria for the use of imaging in reliably identifying effective treatment methods for gliomas, the most common malignant primary brain tumors (Fig. 1). The Macdonald criteria, published in 1990, were used to evaluate the response to primary treatment of glioblastomas. RANO high-grade glioma (HGG) [1] and RANO low-grade glioma (LGG) [2] were introduced in 2010 and 2011, respectively. With the emergence of various treatments, such as radiochemotherapy and immunotherapy, modified RANO (mRANO) [3] and immunotherapy RANO (iRANO) [4] were implemented. However, using these multiple criteria, the need for a comprehensive tumor response assessment that can integrate all types of lesions was highlighted. In response, the RANO working group updated the evaluation criteria to RANO 2.0, applicable to glioblastomas, all grades of isocitrate dehydrogenase (IDH)-mutated gliomas, and other gliomas [5]. This article aims to briefly explain the updated RANO 2.0, in

comparison with existing evaluation methods.

First, RANO 2.0 recommends the use of the standardized brain tumor imaging protocol (BTIP), which was initially proposed in 2015 and then updated in 2020 by consensus meetings led by the US FDA, National Cancer Institute, and academic groups in various fields [6,7]. Contrast-enhanced MRI is the most sensitive and reproducible imaging method for capturing brain tumors [8]. When evaluating brain tumors, it is crucial to use the same imaging protocol as much as possible for both baseline and follow-up images to ensure that changes in tumor size or morphology are not influenced by the imaging parameters. Therefore, it is essential to use a standardized BTIP. If there is a desire to include other specific sequences, they can be added to the standardized BTIP.

Second, RANO 2.0 broadened the tumor measurement methods. Similar to RANO-HGG, for contrast-enhanced tumor lesions, the lesion size is determined using the product of the maximum cross-sectional diameter on contrast-enhanced T1-weighted images. As with RANO-LGG, for non-contrast-enhanced tumor lesions (not related to peritumoral edema), size is determined using the product of the maximum cross-sectional diameter on T2/fluid attenuation inversion recovery (FLAIR). Typically, a two-dimensional tumor measurement is performed, but RANO 2.0 allows for the use of volumetric measurements depending on the situation. To maintain consistency, measurement methods should be pre-specified before the start of the study.

Measurable lesions are defined as contrast-enhanced or non-contrast-enhanced lesions with clear margins on MRI and perpendicular diameters of at least 10 mm. Two-dimensional tumor measurements can be made in the axial, coronal, or sagittal plane by choosing the plane where the lesion appears the largest. In three dimensions, measurable

Received: January 5, 2024 **Revised:** February 5, 2024

Accepted: February 13, 2024

*These authors contributed equally to this work.

Corresponding author: Kyung Won Kim, MD, PhD, Department of Radiology and Research Institute of Radiology, University of Ulsan College of Medicine, Asan Medical Center, 88 Olympic-ro 43-gil, Songpa-gu, Seoul 05505, Republic of Korea

• E-mail: medimash@gmail.com

This is an Open Access article distributed under the terms of the Creative Commons Attribution Non-Commercial License (<https://creativecommons.org/licenses/by-nc/4.0>) which permits unrestricted non-commercial use, distribution, and reproduction in any medium, provided the original work is properly cited.

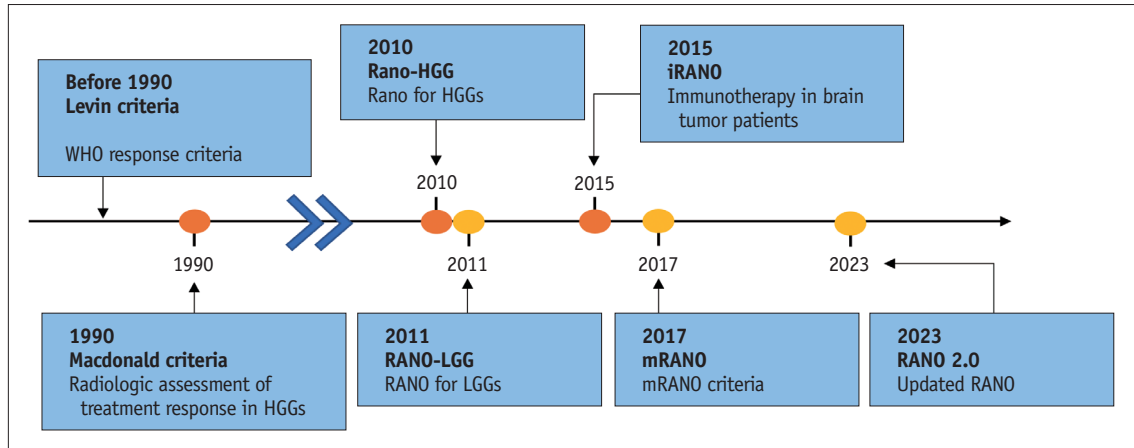


Fig. 1. Evolution of imaging response assessment for gliomas. HGG = high-grade glioma, RANO = Response Assessment in Neuro-Oncology, LGG = low-grade glioma, iRANO = immunotherapy RANO, mRANO = modified RANO

lesions for volumetric measurement are defined as those with a minimum diameter of 10 mm in all three orthogonal directions. Non-measurable lesions are defined as lesions that are unidimensional, have indistinct margins, or have a maximum perpendicular diameter of less than 10 mm. Lesions without nodular components with a vertical diameter of less than 10 mm around the surgical sites are generally considered non-measurable, and cystic lesions or cavities affected by surgery cannot be measured. In cases where multiple measurable lesions exist, a study evaluating contrast-enhanced or non-contrast-enhanced tumors can include a minimum of two to a maximum of three lesions as target lesions. In studies evaluating both lesions, a maximum of two measurable enhancing and two measurable non-enhancing lesions can be designated as target lesions. The sum of the products of the perpendicular diameters of these lesions determines the response. When selecting target lesions, emphasis is generally placed on reproducible and repeatedly measurable lesions, or the largest lesion. In the presence of any growth among multiple measurable lesions, a lesion that is increasing in size is chosen as the target lesion regardless of its relative size, while the remaining lesions are recorded as non-target lesions.

Third, RANO 2.0 specified the timing of baseline MRI and the progression confirmation process. RANO-HGG, iRANO, and mRANO use different schemes that significantly hamper the reliability of tumor measurement data in brain tumor clinical trials. We believe that the updates for baseline MRI and progression formation are the most crucial parts of RANO 2.0. For patients with newly diagnosed gliomas who have undergone radiation therapy, similar to mRANO [3], MRI performed approximately 4 weeks (21–35 days)

after the completion of radiation treatment is used as the baseline (Table 1, Fig. 2). This differs from RANO-HGG [1] and iRANO [4], which use postoperative MRI before radiation as the baseline. For newly diagnosed patients who have received surgery and have not received radiation therapy, RANO 2.0 considers MRI performed after surgery and before standard chemotherapy or a new treatment as the baseline. For patients with recurrent gliomas, MRI performed before treatment is also used as the baseline. This aligns with the baseline setting of the previous evaluation criteria.

Response evaluation is determined by comparing the measurements of tumors identified at baseline. Partial response is defined when, for a minimum of 4 weeks, the sum of the product of perpendicular diameters of all measurable target lesions decreases by 50% or more compared to baseline, with the corticosteroid doses maintained or decreased, or when the volume decreases by 65% or more. Progressive disease (PD) is defined as an increase of 25% or more in the sum of the product of the perpendicular diameters of all measurable target lesions, or a volume increase of 40% or more compared to the smallest tumor measurements at baseline or after the start of treatment. The discovery of new measurable lesions is also considered PD. In this case, they are added to the sum of the existing target lesions, and if the area increases by 25% or more or the volume increases by 40% or more in subsequent repeat images, PD can be confirmed. Additionally, if non-measurable lesions increase by a minimum of 5 × 5 mm or become measurable ($\geq 10 \times 10$ mm) and if non-target lesions increase by 25% in area or 40% in volume, it can also be defined as clear PD. In this case, they are added to the sum of existing target lesions, and if the total sum of the product

Table 1. Comparison of imaging response assessment for gliomas among different criteria

	RANO-HGG	RANO-LGG	mRANO	iRANO	RANO 2.0
Baseline MRI	Pre-radiation	Pre-radiation	Post-radiation	Pre-radiation	Radiotherapy+: Post-radiation Radiotherapy-: Post-surgical (before any other treatments)
Recurrent	Pre-treatment	Pre-treatment	Pre-treatment	Pre-treatment	Pre-treatment
T1 postcontrast evaluation	Required	Required	Required	Required	Required
FLAIR evaluation	Required	Required	Omitted	Omitted	Omitted Can be considered with agents that significantly affect vascular permeability
Confirmation Scans	Optional	Optional	Mandatory	Recommended within 6 months from initiation of immunotherapy	Mandatory*
Measurement	2D	2D or volumetric	2D or volumetric	2D	2D or volumetric
Evaluation glioma	HGG	LGG	HGG (GBM)	HGG (GBM)	All gliomas

*Confirmation scans are required in the first 12 weeks of completion of radiation, but it is optional beyond 12 weeks of radiation. But at that time confirmation scans can be considered with therapies associated with high rates of pseudo-progression.

RANO = Response Assessment in Neuro-Oncology, HGG = high-grade glioma, LGG = low-grade glioma, mRANO = modified RANO, iRANO = immunotherapy RANO, FLAIR = fluid attenuation inversion recovery, GBM = glioblastoma

of the perpendicular diameters in the target lesions exceeds 25% in area or 40% in volume compared to the previous measurement, it is considered PD-confirmed. This analysis is performed to distinguish between pseudo-progression and true PD. If PD is confirmed on subsequent images, the PD date is retroactively set to the point at which initial tumor progression was recorded.

In IDH-mutated gliomas and other gliomas, pseudo-progression can occur well beyond 3 months. In IDH wild-type glioblastomas, pseudo-progression is most commonly observed in the first 12 weeks after the completion of radiochemotherapy [9]. If PD is initially identified but the patient remains clinically stable, repeat MRIs should be performed to confirm PD before considering discontinuation of the study. Generally, pseudo-progression is closely associated with changes in contrast enhancement; therefore, confirmation of PD is typically based on the criteria for contrast-enhanced tumors and is unnecessary when evaluating non-contrast-enhanced tumors.

The RANO-HGG criteria were developed to address the challenges posed by treatments that reduce vascular permeability, including bevacizumab. Such decreases in vascular permeability can lead to pseudo-responses and the progression of non-contrast-enhanced tumors [1]. To address non-contrast-enhanced progression issues, RANO-HGG incorporated the evaluation of T2/FLAIR changes into the response criteria. Specifically, in patients receiving anti-angiogenic agents, if contrast enhancement remains stable or decreases but progression is observed in T2/FLAIR, PD is considered. Up to 40% of patients treated with bevacizumab experience non-contrast-enhanced progression, leading to a shorter progression-free survival (PFS) in evaluation outcomes [10]; however, most patients show contrast-enhanced progression within 1–2 months after non-contrast-enhanced progression, and the correlation between PFS and survival remains unchanged [11]. Moreover, distinguishing non-contrast-enhanced progression from other causes of T2/FLAIR signal increases, such as changes due to radiation or surgery, edema, or corticosteroid dosage, can be challenging. Additionally, some treatments, such as immunotherapy or intratumoral therapy, can lead to increased peritumoral edema or changes in the T2/FLAIR signal, independent of tumor progression. Furthermore, evaluation of non-contrast-enhanced progression based on contrast enhancement in glioblastomas is limited. Therefore, in RANO 2.0, the criteria for non-contrast-enhanced progression were removed from the criteria for determining the progression of enhancing

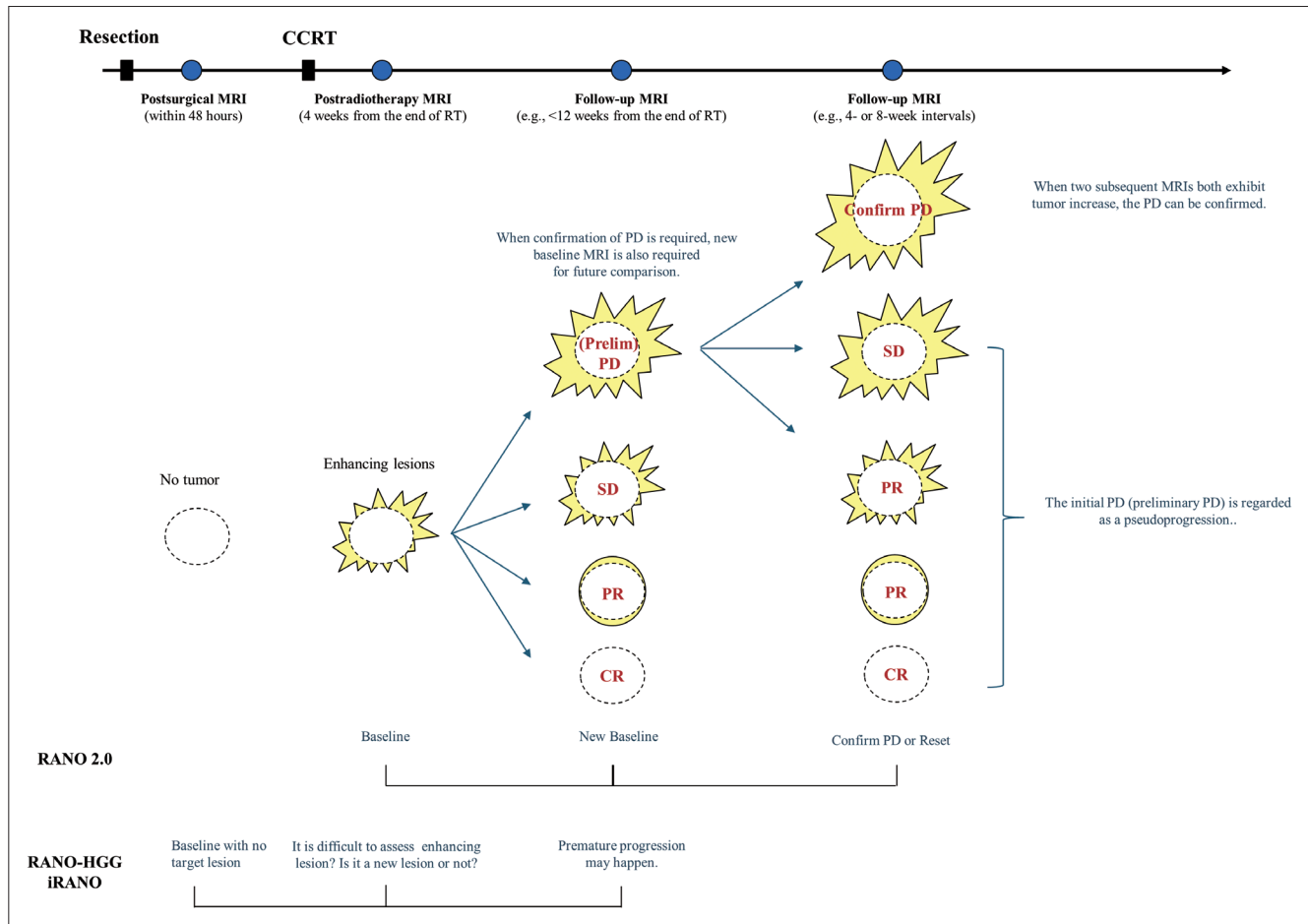


Fig. 2. Response assessment scheme. CCRT = concomitant chemoradiotherapy, RT = radiation therapy, PD = progression disease, SD = stable disease, PR = partial response, CR = complete response, RANO = Response Assessment in Neuro-Oncology, RANO-HGG = RANO for high-grade glioma, iRANO = immunotherapy RANO

glioblastomas. For tumors with a mix of contrast-enhanced and non-contrast-enhanced components, both types of lesions can be assessed. However, when determining PD, measuring only contrast-enhanced lesions is also allowed. The evaluation of T2/FLAIR changes remains valuable for the evaluation of IDH-mutated gliomas with a non-enhancing component and in trials evaluating agents anticipated to significantly affect vascular permeability.

In conclusion, using RANO 2.0, response evaluation for all types of gliomas and treatments is possible, and both 2D and volumetric measurements can be used to assess the response. For newly diagnosed gliomas, when radiation therapy is performed, the MRI obtained approximately 4 weeks after the completion of radiation therapy is used as the baseline. Through various studies, because of the somewhat ambiguous progression evaluation of T2/FLAIR, the criteria for non-contrast-enhanced imaging were removed from the progression determination criteria for enhancing glioblastoma.

As a result, RANO 2.0 is better suited for evaluating neuro-oncology responses, providing substantial assistance in identifying effective treatment strategies in the future.

Conflicts of Interest

Chong Hyun Suh, who hold respective positions on the Assistants to the Editor of the *Korean Journal of Radiology*, were not involved in the editorial evaluation or decision to publish this article. The remaining author has declared no conflicts of interest.

Author Contributions

Conceptualization: all authors. Project administration: Kyung Won Kim. Supervision: Kyung Won Kim. Writing—original draft: Sang Eun Won, Chong Hyun Suh, Sinae Kim, Hyo Jung Park. Writing—review & editing: Kyung Won Kim.

ORCID IDs

Sang Eun Won

<https://orcid.org/0000-0001-8611-1059>

Chong Hyun Suh

<https://orcid.org/0000-0002-4737-0530>

Sinae Kim

<https://orcid.org/0000-0002-2533-4141>

Hyo Jung Park

<https://orcid.org/0000-0002-2364-9940>

Kyung Won Kim

<https://orcid.org/0000-0002-1532-5970>

Funding Statement

This research was supported by a grant of the Korea Health Technology R&D Project through the Korea Health Industry Development Institute (KHIDI), funded by the Ministry of Health & Welfare, Republic of Korea (grant number: HR18C0016).

REFERENCES

1. Wen PY, Macdonald DR, Reardon DA, Cloughesy TF, Sorensen AG, Galanis E, et al. Updated response assessment criteria for high-grade gliomas: response assessment in neuro-oncology working group. *J Clin Oncol* 2010;28:1963-1972
2. van den Bent MJ, Wefel JS, Schiff D, Taphoorn MJ, Jaeckle K, Junck L, et al. Response assessment in neuro-oncology (a report of the RANO group): assessment of outcome in trials of diffuse low-grade gliomas. *Lancet Oncol* 2011;12:583-593
3. Ellingson BM, Wen PY, Cloughesy TF. Modified criteria for radiographic response assessment in glioblastoma clinical trials. *Neurotherapeutics* 2017;14:307-320
4. Okada H, Weller M, Huang R, Finocchiaro G, Gilbert MR, Wick W, et al. Immunotherapy response assessment in neuro-oncology: a report of the RANO working group. *Lancet Oncol* 2015;16:e534-e542
5. Wen PY, van den Bent M, Youssef G, Cloughesy TF, Ellingson BM, Weller M, et al. RANO 2.0: update to the response assessment in neuro-oncology criteria for high- and low-grade gliomas in adults. *J Clin Oncol* 2023;41:5187-5199
6. Ellingson BM, Bendszus M, Boxerman J, Barboriak D, Erickson BJ, Smits M, et al. Consensus recommendations for a standardized brain tumor imaging protocol in clinical trials. *Neuro Oncol* 2015;17:1188-1198
7. Kaufmann TJ, Smits M, Boxerman J, Huang R, Barboriak DP, Weller M, et al. Consensus recommendations for a standardized brain tumor imaging protocol for clinical trials in brain metastases. *Neuro Oncol* 2020;22:757-772
8. Ellingson BM, Wen PY, Cloughesy TF. Evidence and context of use for contrast enhancement as a surrogate of disease burden and treatment response in malignant glioma. *Neuro Oncol* 2018;20:457-471
9. Youssef G, Rahman R, Bay C, Wang W, Lim-Fat MJ, Arnaout O, et al. Evaluation of standard response assessment in neuro-oncology, modified response assessment in neuro-oncology, and immunotherapy response assessment in neuro-oncology in newly diagnosed and recurrent glioblastoma. *J Clin Oncol* 2023;41:3160-3171
10. Nowosielski M, Wiestler B, Goebel G, Hutterer M, Schlemmer HP, Stockhammer G, et al. Progression types after antiangiogenic therapy are related to outcome in recurrent glioblastoma. *Neurology* 2014;82:1684-1692
11. Nowosielski M, Ellingson BM, Chinot OL, Garcia J, Revil C, Radbruch A, et al. Radiologic progression of glioblastoma under therapy-an exploratory analysis of AVAglio. *Neuro Oncol* 2018;20:557-566