



2024 Consensus Statement on Coronary Stenosis and Plaque Evaluation in CT Angiography From the Asian Society of Cardiovascular Imaging-Practical Tutorial (ASCI-PT)

Cherry Kim^{1*}, Chul Hwan Park^{2*}, Bae Young Lee³, Chan Ho Park⁴, Eun-Ju Kang⁵, Hyun Jung Koo⁶, Kakuya Kitagawa⁷, Min Jae Cha⁸, Rungroj Krittayaphong⁹, Sang Il Choi¹⁰, Hwan Seok Yong¹¹, Sung Min Ko¹², Sung Mok Kim¹³, Sung Ho Hwang¹⁴, Nguyen Ngoc Trang¹⁵, Whal Lee¹⁶, Young Jin Kim¹⁷, Jongmin Lee¹⁸, Dong Hyun Yang⁶

¹Department of Radiology, Korea University Ansan Hospital, Ansan, Republic of Korea

²Department of Radiology and Research Institute of Radiological Science, Gangnam Severance Hospital, Yonsei University College of Medicine, Seoul, Republic of Korea

³Department of Radiology, Eunpyeong St. Mary's Hospital, College of Medicine, The Catholic University of Korea, Seoul, Republic of Korea

⁴Department of Radiology, Soonchunhyang University Cheonan Hospital, Cheonan, Republic of Korea

⁵Department of Radiology, College of Medicine, Dong-A University, Busan, Republic of Korea

⁶Department of Radiology and Research Institute of Radiology, Cardiac Imaging Center, Asan Medical Center, University of Ulsan College of Medicine, Seoul, Republic of Korea

⁷Department of Radiology, Mie University Graduate School of Medicine, Tsu, Japan

⁸Department of Radiology, Chung-Ang University Hospital, Seoul, Republic of Korea

⁹Division of Cardiology, Department of Medicine, Siriraj Hospital, Mahidol University, Bangkok, Thailand

¹⁰Department of Radiology, Seoul University Bundang Hospital, Seongnam, Republic of Korea

¹¹Department of Radiology, Korea University Guro Hospital, Seoul, Republic of Korea

¹²Department of Radiology, Yonsei University Wonju College of Medicine, Wonju Severance Christian Hospital, Wonju, Republic of Korea

¹³Department of Radiology, Samsung Medical Center, Sungkyunkwan University School of Medicine, Seoul, Republic of Korea

¹⁴Department of Radiology, Korea University Anam Hospital, Seoul, Republic of Korea

¹⁵Center of Radiology, Bachmai University Hospital, Hanoi, Vietnam

¹⁶Department of Radiology, Seoul National University Hospital, Seoul, Republic of Korea

¹⁷Department of Radiology and Research Institute of Radiological Science, Severance Hospital, Yonsei University College of Medicine, Seoul, Republic of Korea

¹⁸Department of Radiology, Kyungpook National University Hospital, Daegu, Republic of Korea

The Asian Society of Cardiovascular Imaging-Practical Tutorial (ASCI-PT) is an instructional initiative of the ASCI School designed to enhance educational standards. In 2021, the ASCI-PT was convened with the goal of formulating a consensus statement on the assessment of coronary stenosis and coronary plaque using coronary CT angiography (CCTA). Nineteen experts from four countries conducted thorough reviews of current guidelines and deliberated on eight key issues to refine the process and improve the clarity of reporting CCTA findings. The experts engaged in both online and on-site sessions to establish a unified agreement. This document presents a summary of the ASCI-PT 2021 deliberations and offers a comprehensive consensus statement on the evaluation of coronary stenosis and coronary plaque in CCTA.

Keywords: Coronary CT angiography; Coronary artery stenosis; Coronary artery plaque; Consensus development

Received: January 30, 2024 **Accepted:** January 31, 2024

This article is being published jointly in the *Korean Journal of Radiology* and *Cardiovascular Imaging Asia*.

*These authors contributed equally to this work.

Corresponding author: Dong Hyun Yang, MD, Department of Radiology and Research Institute of Radiology, Cardiac Imaging Center, Asan Medical Center, University of Ulsan College of Medicine, 88 Olympic-ro 43-gil, Songpa-gu, Seoul 05505, Republic of Korea

• E-mail: donghyun.yang@gmail.com

This is an Open Access article distributed under the terms of the Creative Commons Attribution Non-Commercial License (<https://creativecommons.org/licenses/by-nc/4.0>) which permits unrestricted non-commercial use, distribution, and reproduction in any medium, provided the original work is properly cited.

INTRODUCTION

Coronary CT angiography (CCTA) has emerged as a prominent non-invasive cardiac imaging technique and has rapidly gained widespread acceptance [1,2]. The 2021 American Heart Association guidelines for chest pain management now recognize CCTA as a primary diagnostic tool, solidifying its critical role in evaluating potential coronary artery disease (CAD) [3]. Consequently, its use is anticipated to rise among patients with suspected CAD [3-5]. Interpretation of CCTA has largely been guided by the Society of Cardiovascular Computed Tomography (SCCT) guidelines [6,7], and the Coronary Artery Disease Reporting and Data System (CAD-RADS) also offers a detailed framework for interpretation [8-10]. However, ambiguities in applying and interpreting these guidelines in real-world CCTA assessments can lead to reader variability and communication challenges in conveying the radiological findings. In 2019, the Asian Society of Cardiovascular Imaging Practical Tutorial (ASCI-PT) convened for the first time, and in 2020, it published a consensus statement addressing contentious issues in cardiac magnetic resonance (CMR) imaging interpretations [11,12]. This initiative resulted in improved interobserver reliability and agreement in semi-quantitative scoring of late gadolinium enhancement in the left ventricle for patients with ischemic cardiomyopathy [12]. Given the frequent clinical use and importance of grading coronary stenosis and characterizing plaque in CCTA, the ASCI-PT discussions and consensus formation in 2021 regarding these subjects are crucial.

This document aims to present the proceedings as follows. We began by clarifying the aspects of the pre-meeting survey that was conducted to pinpoint the contentious topics for the CCTA interpretation consensus session. The results of this survey informed the identification of the primary issues for discussion. Subsequently, we elaborate on the process of achieving consensus through the deliberations of the expert panel and document the consensus outcomes.

Pre-Meeting Surveys, Panels, and Consensus Methods

In preparation for the ASCI-PT consensus session, 19 experts from four countries were enlisted. Due to the coronavirus disease pandemic, 16 experts from South Korea were able to attend in person, while three panelists from Japan, Thailand, and Vietnam participated online

(Supplementary Table 1). To gauge the panelists' experiences and practice patterns and to identify key discussion points for the consensus session, two online pre-meeting surveys were executed. The panel selection, pre-meeting survey preparation, and analysis of results were overseen by the ASCI-PT's director, Dong Hyun Yang, alongside two co-directors, Chul Hwan Park and Cherry Kim.

The first survey sought details on the panelists' clinical experience, CCTA imaging reconstruction protocols, interpretation methodologies, and reporting protocols (Supplementary Table 2). To accurately reflect current practices, radiological report samples from each participating hospital were collected. The subsequent survey posed queries regarding issues that, despite being partially addressed in existing guidelines, could lead to uncertainties in practical interpretation. This survey comprised 34 questions that spanned several core topics, including the assignment of coronary segments, assessment of high-risk plaque (HRP) morphologies, and the evaluation of plaque length, composition, and stenosis degree (Supplementary Tables 3-6).

Analysis of the initial survey revealed that the experts, on average, possessed 15.1 ± 5.9 years of experience post-board certification. Among the respondents, 4 (21.1%) interpreted in excess of 500 CCTA scans monthly, 6 (31.6%) between 200–500, and 5 (26.3%) between 100–200 scans, and 4 (21.1%) less than 100 scans. It was noted that 73.7% of the panelists evaluated coronary stenosis using imaging workstations. Examination of the hospital reports showed universal mention of plaque composition, yet only 31.6% specifically identified HRP, and 31.6% reported routinely employing the CAD-RADS.

The findings from the second survey were initially processed by the director and co-directors and disclosed at the in-person conference. The two-day meeting's schedule is detailed in Supplementary Table 7. Day one involved panelists assessing the results of the pre-meeting surveys, performing literature reviews pertinent to each topic under discussion, and collectively examining cases pertaining to these topics using the available imaging workstations. Following this, eight topics identified as clinically pertinent and exhibiting variability among panel opinions were selected for the final consensus discussion, as listed in Table 1.

During the second day, online panelists joined to review the outcomes of the pre-meeting surveys and the preliminary consensus draft. Each point was deliberated in the morning session, with both online and on-site panelists contributing to the voting process. Consensus was defined by the level

Table 1. Eight issues regarding CCTA semi-quantitative evaluation

Issue 1	Distal margin of the left main artery
Issue 2	Proximal vs. mid-left anterior descending artery
Issue 3	Ramus intermedius vs. first obtuse marginal artery
Issue 4	Categorization of coronary plaque
Issue 5	High-risk plaque morphology
Issue 6	Diameter vs. area stenosis and grading system
Issue 7	Determining reference vessels for calculation of percent stenosis
Issue 8	Determining diameter on a cross-sectional image of CCTA

CCTA = coronary CT angiography

of agreement; items achieving over 75% concordance were classified as having strong agreement, while those with 50%–74% concordance were considered to have moderate agreement.

Eight Issues Regarding CCTA Semi-Quantitative Evaluation

Clarification/Consensus on 18-Segment Coronary Artery Model from the SCCT Guidelines

The ASCI-PT consensus panel endorses and utilizes the 18-segment model of the coronary artery as delineated by the SCCT guidelines for daily interpretations [6], but certain issues have been identified that can cause confusion. To address these ambiguities, the panel has sought to clarify or reach consensus on the following issues through a structured voting process:

Issue 1. Distal Margin of the Left Main Artery (LM)

Issue: Pinpointing the precise termination point of the left main artery (LM) where it bifurcates into the left anterior descending artery (LAD) and left circumflex artery (LCX), which can occasionally be ambiguous.

Clarification/consensus: According to the SCCT guideline, the LM artery extends from its ostium to the bifurcation of the LAD and LCX [6]. Lesions occurring within the bifurcation toward the LAD or LCX should be categorized as part of the LM (Fig. 1). This interpretation was met with unanimous consent (strong agreement, 100%).

Issue 2. Proximal vs. Mid-Left Anterior Descending Artery (Proximal LAD vs. Mid-LAD)

Issue: When a significant first diagonal artery (D1), greater than 1.5 mm in diameter, originates in close proximity to the LAD ostium, prompting the question of how to classify a very short segment from the LAD ostium to D1

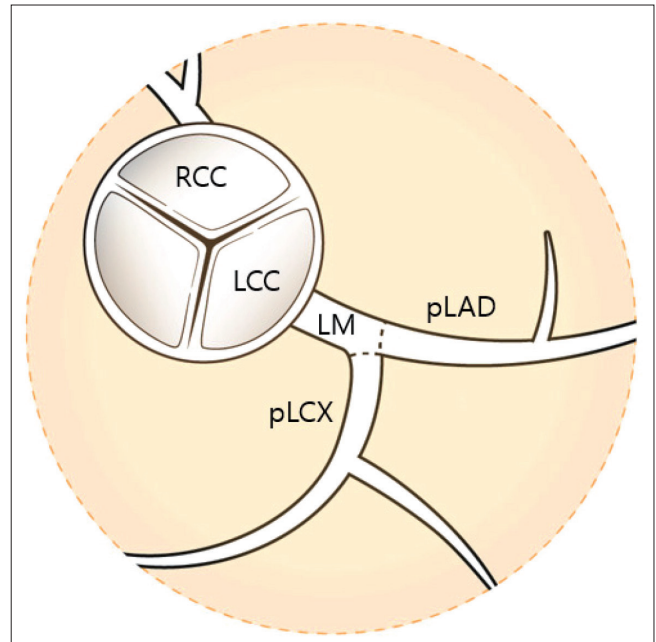
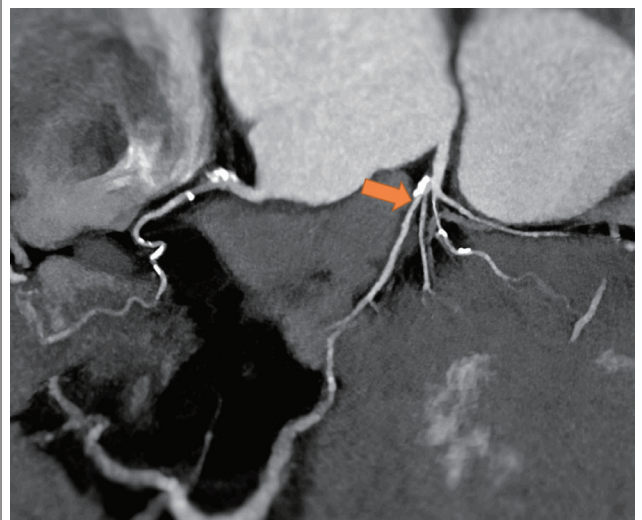


Fig. 1. Definition of left main branch. LM is defined as ‘Ostium of LM to bifurcation of LAD and LCX,’ and lesions in the bifurcation towards LAD or LCX should be classified under LM. LM = left main artery, LAD = left anterior descending artery, LCX = left circumflex artery, RCC = right coronary cusp, LCC = left coronary cusp, pLAD = proximal LAD, pLCX = proximal LCX

Pre-meeting questionnaire item: Which structure is this arrow pointing to (diameter of D1 is 1.6 mm)?



Pre-meeting responses

- 1) Proximal LAD: 63.2%
- 2) Mid LAD: 36.8%

Voting results after discussion

- 1) Proximal LAD: 35.3%
- 2) Mid LAD: 64.7%

Fig. 2. Pre-meeting questionnaire item and responses regarding Issue 2. D1 = the first diagonal artery, LAD = left anterior descending artery

as proximal LAD (pLAD) (Fig. 2).

Clarification/consensus: The SCCT guideline specifies pLAD as the segment from the end of the LM to the first large septal or D1, whichever is most proximal, with the D1 being greater than 1.5 mm in size [6]. Adhering strictly to the SCCT definition, the distal segment near a sizable D1 would be considered mid-LAD (mLAD), which achieved moderate agreement (64.7%).

Discussion: A strict interpretation of the SCCT guideline phrase ‘whichever is most proximal’ would undoubtedly classify the segment indicated in Figure 2 as mLAD. Despite 63.2% of panelists initially favoring pLAD in the pre-meeting survey, there was concern that a very short pLAD segment does not align well with findings from invasive angiography. Proponents of rigorous guideline adherence noted that the presence of a sizable D1 would diminish blood flow in the distal portion, underscoring the need to consider myocardial blood flow when differentiating between pLAD and mLAD. Following thorough deliberations, the final vote favored mLAD (64.7%), a shift from the 36.8% in the pre-meeting survey.

Issue 3. Ramus Intermedius (RI) vs. First Obtuse Marginal Artery (OM1)

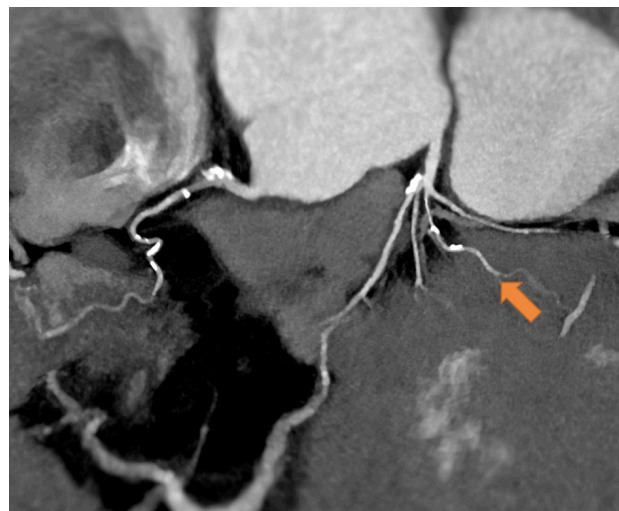
Issue: The classification dilemma arises when determining a significant branch of the LCX (> 1.5 mm) that branches off near the LM bifurcation (Fig. 3).

Clarification/consensus: The SCCT guideline characterizes the RI as a vessel that arises from the LM between the LAD and LCX in scenarios involving a trifurcation [6]. When interpreting this definition strictly, any LCX branch larger than 1.5 mm that originates near the LM bifurcation and does not result in a trifurcation should be designated as first obtuse marginal artery (OM1) (strong agreement, 76.4%).

Discussion: In cases where an LCX branch surfaces very close to the LM bifurcation, 52.6% of the panelists initially identified it as ramus intermedius (RI) in the pre-meeting survey, adhering to the SCCT’s definition of RI in the context of a trifurcation [6]. Subsequent discussions among committee members concluded that a stringent interpretation of the definition, particularly concerning trifurcation, would likely decrease interobserver variability. This led to a post-discussion consensus where 76.4% agreed to classify such a branch as OM1.

The consensus panel acknowledges that while the SCCT’s 18-segment model serves as a solid guideline, detailed discussions and ensuing clarifications are essential for ensuring uniform and precise interpretations among various

Pre-meeting questionnaire item: Which structure is this arrow pointing to (diameter of D1 is 1.6 mm)?



Pre-meeting responses

- 1) Ramus intermedius: 52.6%
- 2) Obtuse marginal branch: 47.4%

Voting results after discussion

- 1) Ramus intermedius: 23.5%
- 2) Obtuse marginal branch: 76.4%

Fig. 3. Pre-meeting questionnaire item and responses regarding Issue 3. D1 = the first diagonal artery

practitioners.

Coronary Plaque Characterization

Issue 4. Categorization of Coronary Plaque

Issue: The capability of CCTA to assess both coronary stenosis grading and coronary plaque composition is well-established. However, the terminology for classifying coronary plaques—such as calcified, partially calcified, and noncalcified—varies among different studies and across guideline editions. The SCCT 2009 guidelines delineated plaques as calcified, mixed, or noncalcified [13], while the 2011 guidelines introduced the term “partially calcified” [14]. The term, “partially calcified plaque,” is somewhat ambiguous as it encompasses a wide range of plaques without considering the proportion of calcified to noncalcified components. The pre-meeting survey underscored the varying opinions on plaque classification, which could contribute to interobserver variability in CCTA interpretations (Fig. 4).

Clarification/consensus: The SCCT 2014 guidelines refined the classification, introducing “predominant noncalcified” and “predominant calcified” as descriptors for plaques [6]. The ASCI-PT endorses the SCCT 2014 guidelines [6] and concurs with the distinction between





Pre-meeting questionnaire item: Noncalcified? Partially calcified? Or calcified plaque?	Pre-meeting responses
	1) Noncalcified: 57.9% 2) Partially calcified: 42.1% 3) Calcified: 0%
	1) Noncalcified: 31.6% 2) Partially calcified: 68.4% 3) Calcified: 0%
	1) Noncalcified: 0% 2) Partially calcified: 94.7% 3) Calcified: 5.3%
	1) Noncalcified: 0% 2) Partially calcified: 10.5% 3) Calcified: 89.5%

Fig. 4. Pre-meeting questionnaire item and responses regarding Issue 4.

“partially calcified” plaques, advocating the use of a 50% threshold to differentiate between “predominant calcified” and “predominant noncalcified” plaques (strong agreement, 82.3%) (Fig. 5).

Discussion: The introduction of more precise terms such as “predominant noncalcified” and “predominant calcified” in the SCCT 2014 guidelines is seen as an effort to reduce confusion [6]. A notable challenge is establishing a definitive boundary between “predominant calcified” and “predominant noncalcified” plaques. The application of the 50% rule presents a potential resolution, offering a uniform standard for plaque classification.

Issue 5. High-Risk Plaque (HRP) Morphology

Issue: The issue revolves around the identification of HRP features, such as spotty calcification, positive remodeling, low attenuation plaque, and the napkin ring sign, which clinical studies have consistently linked with patient outcomes [15-20]. Both the SCCT guidelines and the CAD-







SCCT 2011 guideline		SCCT 2014 guideline
Noncalcified		Noncalcified
Partially calcified		Predominantly noncalcified
Partially calcified		Predominantly noncalcified
Partially calcified		Predominantly calcified
Partially calcified		Predominantly calcified
Calcified		Calcified

Fig. 5. Differences in plaque characterization according to the SCCT 2011 and 2014 guidelines. Plaques with calcification of different ratios are all labeled as partially calcified, according to the SCCT 2011 guidelines [14]. SCCT = Society of Cardiovascular Computed Tomography

RADS system underscore the importance of reporting these features [3]. However, concerns arise due to the relatively high prevalence of HRP found in studies, which may affect the positive predictive value for prognosis [21]. To address this, the CAD-RADS 2022 recommends designating an “HRP” modifier only when there are at least two clear HRP features present [7,10]. In the pre-meeting survey, 94.7% of the ASCI-PT panel recognized the importance of HRPs but exhibited differing opinions regarding the clinical significance of each HRP characteristic. According to the survey, 84.2% considered low attenuation plaque and the napkin ring sign crucial, whereas only 36.8% saw spotty calcification as significant, possibly due to its vague definition and frequent appearance in plaques. The definitions of positive remodeling and low attenuation plaque also vary across studies, with differing criteria for the reference diameter and the size of the region of interest (ROI) or pixel count (Table 2).

Clarification/consensus: The ASCI-PT has established definitions for positive remodeling and low attenuation plaque as follows:

- 1) Positive remodeling should be reported using multiplanar reformatted images in long-axis and short-axis views. The reference diameter is the average of the normal proximal and distal segments’ diameters, with a remodeling index (RI) greater than 1.1 indicating positive remodeling (strong agreement, 100%).
- 2) Low attenuation plaque is characterized by a central area within the plaque that shows low CT attenuation, defined as at least one voxel with an attenuation value below 30 Hounsfield units (HU), although a threshold of 30 HU is acceptable when the tube voltage is between 100 kVp to 120 kVp (strong agreement, 100%).

Discussion: The disparity in panelists’ views on the importance of different HRP features reflects the need for standardized reporting practices. The frequent occurrence and vague definition of spotty calcification add to the complexity. Inconsistent definitions of positive remodeling and variations in identifying low attenuation plaque based on ROI size or pixel count lead to discrepancies in reporting. The ASCI-PT’s consensus, which aligns with the 2022 CAD-RADS guidelines [10], aims to standardize the reporting of these critical HRP features, enhancing clarity and consistency in CCTA interpretations.

Coronary Stenosis Evaluation

Achieving uniformity in documenting coronary stenosis, whether in clinical practice or research, remains challenging due to the variation in reference standards, such as quantitative CCTA and invasive intravascular ultrasound (IVUS). Differences exist in methods for determining area vs. diameter stenosis, identifying reference vessel points, and measuring luminal diameter in CCTA cross-sections across studies. In response, after reviewing the SCCT 2014 guidelines and previous CT research on stenosis measurement [6], the ASCI-PT has developed a recommendation or clarification to unify these practices.

Issue 6. Diameter vs. Area Stenosis and Grading System

Issue: Determining whether to adopt diameter stenosis or area stenosis as the standard for measurement. According to the pre-meeting survey, a majority of 73.7% favored diameter stenosis, while the remainder, 26.3%, applied area stenosis. Moreover, categorization of coronary stenosis into grades such as mild or moderate varies among research studies, with mild stenosis sometimes defined as less than

Table 2. Examples of different definitions for high-risk plaques

	Reference
Definitions of positive remodeling	
The diameter at the plaque site is at least 10% larger than the reference segment. The reference segment is proximal to the lesion in a normal-appearing vessel segment	[28]
Outer vessel diameter which is $\geq 10\%$ greater than the mean of the diameter of the normal adjoining segments also labeled as the remodeling index > 1.1	[9]
Definitions of low attenuation plaque	
If low CT attenuation is visually noted in a noncalcified plaque, readers placed 3 random region-of-interest measurements (approximately 0.5 to 1.0 mm ²) in the noncalcified low CT attenuation portion of the plaque. Low HU plaque is defined as the mean CT number within these 3 regions of interest < 30 HU	[15]
Presence of a central focal area within the plaque, which has a low CT attenuation, which is usually defined as at least 1 voxel with < 30 HU	[10]

HU = Hounsfield unit

Table 3. Various grading systems of coronary stenosis

	Grading system			
	SCCT guideline, 2014 [6]	SCCT guideline, 2009 [13]	Min et al., 2007 [22]	Hadamitzky et al., 2013 [29]
Normal	No stenosis	No stenosis	No stenosis	
Minimal	< 25%		< 30% (very mild)	
Mild	25%–49%	< 39%	30%–49%	1%–49%
Moderate	50%–69%	40%–69%	50%–69%	50%–69%
Severe	70%–99%	70%–99%	≥ 70%	≥ 70%
Occluded	Occluded	Occluded		

SCCT = Society of Cardiovascular Computed Tomography

40% and minimal stenosis as less than 30% (Table 3).

Clarification/consensus: The SCCT 2014 guidelines advocate for using the maximal percentage of diameter stenosis [6]. The ASCI-PT agrees with the SCCT 2014 guidelines and suggests reporting maximal diameter stenosis (strong agreement, 100%). The ASCI-PT recommends classifying based on the most recent CAD-RADS system as follows: normal 0%; minimal 1%–24%; mild 25%–49%; moderate 50%–69%; severe 70%–99%; occlusion 100%; and non-diagnostic study (strong agreement, 100%).

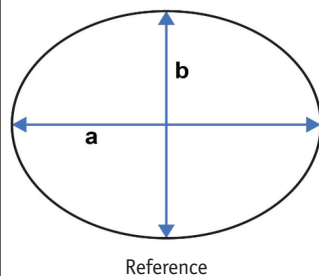
Issue 7. Determining Reference Vessels for Calculation of Percent Stenosis

Issue: Identifying a consistent and accurate reference vessel is essential for reporting percent stenosis. Various methods are cited in the literature, such as using the proximal reference vessel, averaging the dimensions of proximal and distal references, or selecting an interpolated reference point.

Clarification/consensus: The ASCI-PT recognizes that the selection of a reference vessel may differ according to the reporting objective of percent stenosis. The following recommendations are put forward for typical clinical scenarios, with alternative methods (marked as ‘optional’) suggested for specific purposes (strong agreement, 100%):

1. Choose the most normal-looking site immediately before the plaque [22,23].
2. If the proximal segment is not appropriate (e.g., ostial lesion) the closest distal reference should be chosen [23].
3. (Optional) Similar to IVUS studies, select the most normal cross-section within 10 mm of the lesion, provided there is no side branch in between [24].
4. (Optional) Average the proximal and distal reference diameters or areas, following prior IVUS or quantitative CCTA studies, particularly if there is a significant side branch near the plaque [25,26].
5. (Optional) For comparisons with quantitative

Pre-meeting questionnaire item: When you measure the diameter of reference (either proximal or distal), which diameter do you apply for the calculation of diameter stenosis or remodeling index?

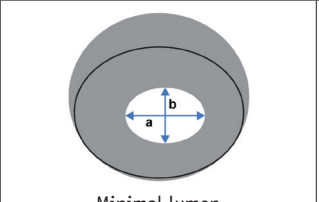


Pre-meeting responses

- 1) a (max. diameter): 26.3%
- 2) b (min. diameter): 15.8%
- 3) Average of a and b: 26.3%
- 4) Area driven diameter: 31.6%
- 5) Perimeter driven diameter: 0%

Fig. 6. Pre-meeting questionnaire item and responses regarding Issue 8.

Pre-meeting questionnaire item: When you measure the diameter of the minimal lumen section, which diameter do you apply for the calculation of diameter stenosis or remodeling index?



Pre-meeting responses

- 1) a (max. diameter): 5.3%
- 2) b (min. diameter): 36.8%
- 3) Average of a and b: 26.3%
- 4) Area driven diameter: 31.6%
- 5) Perimeter driven diameter: 0%

Fig. 7. Pre-meeting questionnaire item and responses regarding Issue 8.

angiography, employ an interpolated reference diameter (area) using specialized analysis software [27].

Issue 8. Determining Diameter on a Cross-Sectional Image of CCTA

Issue: In cases of elliptical lumens, whether in reference vessels or stenosed segments, practitioners must decide between several measurement options: maximal diameter, minimal diameter, the average of both, or methods based on area or perimeter (Figs. 6, 7).

Clarification/consensus: Diameter stenosis traditionally measures the narrowing within a vessel along a single specified direction, utilizing longitudinally reconstructed

Table 4. Consensus statements of the ASCI-PT on the evaluation of stenosis grading and plaque characteristics of CCTA

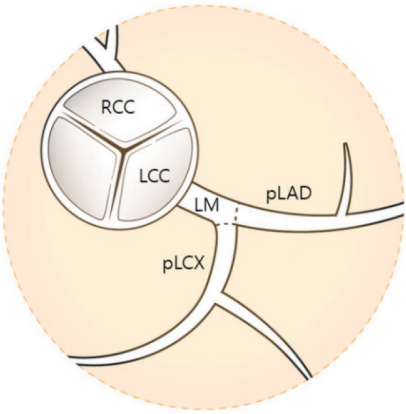
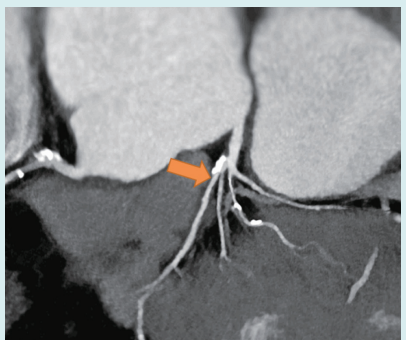
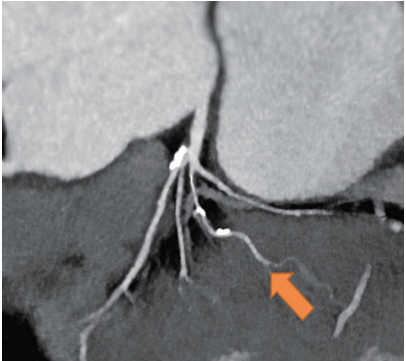












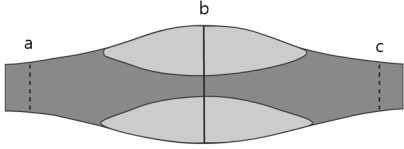
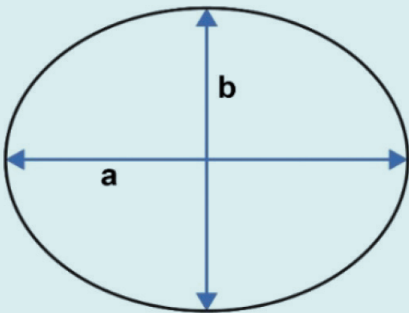
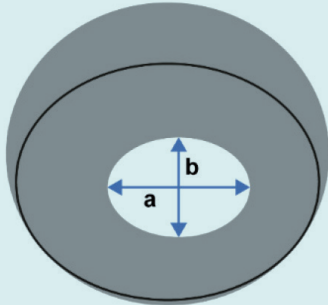
Issues	Degree of agreement	Consensus								
1. Distal margin of LM	100% (17/17)	<p>LM is defined as: 'Ostium of LM to bifurcation of LAD and LCX'</p> <p>Lesions in the bifurcation towards LAD or LCX should be classified under LM</p> 								
2. Proximal vs. mid LAD	64.7% (11/17)	<p>Proximal LAD is defined as: 'End of LM to the first large septal of D1 (D1 > 1.5-mm in size) whichever is most proximal, even though proximal LAD is extremely short'</p>  <p>Arrow should be mid-LAD (if, D1 > 1.5-mm)</p>								
3. RI vs. OM1	76.4% (13/17)	<p>RI is defined as: 'Vessel originating from the LM between the LAD and LCX in case of a trifurcation'</p>  <p>Arrow should be OM1</p>								
4. Categorization of coronary plaque	82.3% (14/17)	<table border="0"> <tr> <td>Noncalcified</td> <td>Predominantly noncalcified</td> <td>Predominantly calcified</td> <td>Calcified</td> </tr> <tr> <td></td> <td></td> <td></td> <td></td> </tr> </table>	Noncalcified	Predominantly noncalcified	Predominantly calcified	Calcified				
Noncalcified	Predominantly noncalcified	Predominantly calcified	Calcified							
										

Table 4. Consensus statements of the ASCI-PT on the evaluation of stenosis grading and plaque characteristics of CCTA (continued)

Issues	Degree of agreement	Consensus															
5. HRP morphology	100% (17/17)	2-FPP: Positive remodeling and low attenuation plaque															
		<p>Positive remodeling Outer vessel diameter (b) which is $\geq 10\%$ greater than the mean of the diameter of the normal proximal and distal segments ($[a + c]/2$)</p> 	<p>Low attenuation plaque Presence of a central focal area within the plaque which has a low CT attenuation, which is usually defined as at least 1 voxel with < 30 HU</p> <p>Addendum: 30 HU could be used when tube voltage is 100 kVp – 120 kVp</p>														
6. Coronary stenosis evaluation	100% (17/17)	<p>The maximal (percent diameter) stenosis is recommended in line with the SCCT 2014 interpretation guideline</p> <p>Minimal lumen area or percent area stenosis may be additive but is not required</p>	<table border="1"> <thead> <tr> <th>Grade</th> <th>Stenosis degree</th> </tr> </thead> <tbody> <tr> <td>Normal</td> <td>No stenosis</td> </tr> <tr> <td>Minimal</td> <td>$< 25\%$</td> </tr> <tr> <td>Mild</td> <td>$25\% - 49\%$</td> </tr> <tr> <td>Moderate</td> <td>$50\% - 69\%$</td> </tr> <tr> <td>Severe</td> <td>$70\% - 99\%$</td> </tr> <tr> <td>Occluded</td> <td>Occluded</td> </tr> </tbody> </table>	Grade	Stenosis degree	Normal	No stenosis	Minimal	$< 25\%$	Mild	$25\% - 49\%$	Moderate	$50\% - 69\%$	Severe	$70\% - 99\%$	Occluded	Occluded
Grade	Stenosis degree																
Normal	No stenosis																
Minimal	$< 25\%$																
Mild	$25\% - 49\%$																
Moderate	$50\% - 69\%$																
Severe	$70\% - 99\%$																
Occluded	Occluded																
7. Determining reference vessel for calculation of percent stenosis	100% (17/17)	<p>Recommendations</p> <ol style="list-style-type: none"> The most normal-appearing site immediately proximal to the plaque should be chosen If the proximal segment is not appropriate (e.g., ostial lesion) the closest distal reference should be chosen <p>Options</p> <ol style="list-style-type: none"> Similar to IVUS studies, the most normal-looking cross-section within 10 mm of the lesion without an intervening side branch should be chosen Averaging proximal and distal reference diameter or area could be applied similarly to previous IVUS or quantitative CCTA studies (if there is a significant intervening branch at the area with plaque) For comparison to quantitative angiography, an interpolated reference diameter (area) should be chosen using dedicated analysis software 															
8. Determining diameter on a cross sectional image of CCTA	66.7% (10/15)	<p>Reference diameter</p>  <p>Reference Average of a and b</p>	<p>Lesion diameter</p>  <p>Minimal lumen Average of a and b</p>														

ASCI-PT = Asian Society of Cardiovascular Imaging-Practical Tutorial, CCTA = coronary CT angiography, LM = left main artery, LAD = left anterior descending artery, LCX = left circumflex artery, RCC = right coronary cusp, LCC = left coronary cusp, pLAD = proximal LAD, pLCX = proximal LCX, D1 = the first diagonal artery, RI = ramus intermedius, OM1 = first obtuse marginal artery, HRP = high-risk plaque, 2-FPP = 2-feature-positive plaques, HU = Hounsfield unit, SCCT = Society of Cardiovascular Computed Tomography, IVUS = intravascular ultrasonography

images. Yet, in routine clinical practice, cross-sectional images are frequently evaluated, and for elliptical lesions, the task of selecting a particular diameter for measurement presents a challenge. Prior guidelines have not provided explicit direction for this situation. Following thorough discussion and examination of the output from commercial workstations, the ASCI-PT advises that the average of the maximal and minimal diameters should be used for assessing the coronary lumen in cross-sectional images. This recommendation received moderate agreement from the panelists, with a consensus rate of 66.7%.

CONCLUSION

In this consensus session, the ASCI-PT sought to resolve ambiguities in CCTA interpretations by leveraging the expertise of specialists (Table 4). Although consensus was reached on most key issues, some topics still presented challenges, resulting in only moderate agreement after panel discussions. The results of this consensus process are expected to enhance the consistency of CCTA readings and facilitate better communication between radiologists and clinicians reviewing radiological reports.

Supplement

The Supplement is available with this article at <https://doi.org/10.3348/kjr.2024.0112>.

Availability of Data and Material

All data generated or analyzed during the study are included in this published article (and its supplementary information files).

Conflicts of Interest

Bae Young Lee, Kakuya Kitagawa, and Dong Hyun Yang, who hold respective positions on the Editorial Board Members and Section Editor of the *Korean Journal of Radiology*, were not involved in the editorial evaluation or decision to publish this article. The remaining author has declared no conflicts of interest.

Author Contributions

Conceptualization: Cherry Kim, Chul Hwan Park, Dong Hyun Yang. Data curation: Cherry Kim, Chul Hwan Park, Bae Young Lee, Chan Ho Park, Eun-Ju Kang, Hyun Jung Koo, Min Jae Cha, Sang Il Choi, Hwan Seok Yong, Sung Min Ko, Sung Mok

Kim, Sung Ho Hwang, Whal Lee, Young Jin Kim, Jongmin Lee. Formal analysis: Cherry Kim, Chul Hwan Park, Dong Hyun Yang. Funding acquisition: Dong Hyun Yang, Jongmin Lee. Investigation: Cherry Kim, Chul Hwan Park, Bae Young Lee, Chan Ho Park, Eun-Ju Kang, Hyun Jung Koo, Min Jae Cha, Sang Il Choi, Hwan Seok Yong, Sung Min Ko, Sung Mok Kim, Sung Ho Hwang, Whal Lee, Young Jin Kim, Jongmin Lee, Kakuya Kitagawa, Rungroj Kittayaphong, Nguyen Ngoc Trang. Methodology: Cherry Kim, Chul Hwan Park, Bae Young Lee, Chan Ho Park, Eun-Ju Kang, Hyun Jung Koo, Min Jae Cha, Sang Il Choi, Hwan Seok Yong, Sung Min Ko, Sung Mok Kim, Sung Ho Hwang, Whal Lee, Young Jin Kim, Jongmin Lee. Project administration: Cherry Kim, Chul Hwan Park, Dong Hyun Yang. Resources: Cherry Kim, Chul Hwan Park, Bae Young Lee, Chan Ho Park, Eun-Ju Kang, Hyun Jung Koo, Min Jae Cha, Sang Il Choi, Hwan Seok Yong, Sung Min Ko, Sung Mok Kim, Sung Ho Hwang, Whal Lee, Young Jin Kim, Jongmin Lee. Software: Cherry Kim, Chul Hwan Park, Dong Hyun Yang. Supervision: Dong Hyun Yang, Jongmin Lee. Validation: Dong Hyun Yang. Visualization: Cherry Kim, Chul Hwan Park, Dong Hyun Yang. Writing—original draft: Cherry Kim, Chul Hwan Park, Dong Hyun Yang. Writing—review & editing: Cherry Kim, Chul Hwan Park, Bae Young Lee, Chan Ho Park, Eun-Ju Kang, Hyun Jung Koo, Min Jae Cha, Sang Il Choi, Hwan Seok Yong, Sung Min Ko, Sung Mok Kim, Sung Ho Hwang, Whal Lee, Young Jin Kim, Jongmin Lee, Kakuya Kitagawa, Rungroj Kittayaphong, Nguyen Ngoc Trang.

ORCID IDs

Cherry Kim

<https://orcid.org/0000-0002-3361-5496>

Chul Hwan Park

<https://orcid.org/0000-0002-0004-9475>

Bae Young Lee

<https://orcid.org/0000-0002-3426-9660>

Chan Ho Park

<https://orcid.org/0000-0002-0653-4666>

Eun-Ju Kang

<https://orcid.org/0000-0003-0937-3607>

Hyun Jung Koo

<https://orcid.org/0000-0001-5640-3835>

Kakuya Kitagawa

<https://orcid.org/0000-0003-4402-6846>

Min Jae Cha

<https://orcid.org/0000-0001-6358-8081>

Rungroj Kittayaphong

<https://orcid.org/0000-0001-8684-2361>

Sang Il Choi

<https://orcid.org/0000-0002-1323-2279>

Hwan Seok Yong

<https://orcid.org/0000-0003-0247-8932>

Sung Min Ko

<https://orcid.org/0000-0002-7420-6269>

Sung Mok Kim

<https://orcid.org/0000-0001-5190-2328>

Sung Ho Hwang

<https://orcid.org/0000-0003-1850-0751>

Nguyen Ngoc Trang

<https://orcid.org/0000-0002-5965-5381>

Whal Lee

<https://orcid.org/0000-0003-1285-5033>

Young Jin Kim

<https://orcid.org/0000-0002-6235-6550>

Jongmin Lee

<https://orcid.org/0000-0002-4163-913X>

Dong Hyun Yang

<https://orcid.org/0000-0001-5477-558X>

Funding Statement

None

Acknowledgments

ASCI-PT 2021 was supported by Dongkook Pharmaceutical Co., Ltd. and TeraRecon, Inc. financially. We thank them for their support and funds. We appreciate the Medical Illustration & Design (MID) team, a member of Medical Research Support Services of Yonsei University College of Medicine, for their excellent support with medical illustration.

REFERENCES

- Kim YJ, Yong HS, Kim SM, Kim JA, Yang DH, Hong YJ. Korean guidelines for the appropriate use of cardiac CT. *Korean J Radiol* 2015;16:251-285
- Kim JY, Hong YJ, Han K, Lee S, Kim YJ, Choi BW, et al. Evaluation of the ostium in anomalous origin of the right coronary artery with an interarterial course using dynamic cardiac CT and implications of ostial findings. *Korean J Radiol* 2022;23:172-179
- Gulati M, Levy PD, Mukherjee D, Amsterdam E, Bhatt DL, Birtcher KK, et al. 2021 AHA/ACC/ASE/CHEST/SAEM/SCCT/SCMR guideline for the evaluation and diagnosis of chest pain: a report of the American College of Cardiology/American Heart Association Joint Committee on clinical practice guidelines. *J Cardiovasc Comput Tomogr* 2022;16:54-122
- Yang DH. Application of artificial intelligence to cardiovascular computed tomography. *Korean J Radiol* 2021;22:1597-1608
- Beck KS, Kim JA, Choe YH, Hian SK, Hoe J, Hong YJ, et al. 2017 multimodality appropriate use criteria for noninvasive cardiac imaging: expert consensus of the Asian Society of Cardiovascular Imaging. *Korean J Radiol* 2017;18:871-880
- Leipsic J, Abbara S, Achenbach S, Cury R, Earls JP, Mancini GJ, et al. SCCT guidelines for the interpretation and reporting of coronary CT angiography: a report of the Society of Cardiovascular Computed Tomography guidelines committee. *J Cardiovasc Comput Tomogr* 2014;8:342-358
- Narula J, Chandrasekhar Y, Ahmadi A, Abbara S, Berman DS, Blankstein R, et al. SCCT 2021 expert consensus document on coronary computed tomographic angiography: a report of the Society of Cardiovascular Computed Tomography. *J Cardiovasc Comput Tomogr* 2021;15:192-217
- Cury RC, Abbara S, Achenbach S, Agatston A, Berman DS, Budoff MJ, et al. Coronary artery disease - reporting and data system (CAD-RADS): an expert consensus document of SCCT, ACR and NASCI: endorsed by the ACC. *JACC Cardiovasc Imaging* 2016;9:1099-1113
- Cury RC, Abbara S, Achenbach S, Agatston A, Berman DS, Budoff MJ, et al. CAD-RADS™ coronary artery disease - reporting and data system. An expert consensus document of the Society of Cardiovascular Computed Tomography (SCCT), the American College of Radiology (ACR) and the North American Society for Cardiovascular Imaging (NASCI). Endorsed by the American College of Cardiology. *J Cardiovasc Comput Tomogr* 2016;10:269-281
- Cury RC, Leipsic J, Abbara S, Achenbach S, Berman D, Bittencourt M, et al. CAD-RADS™ 2.0 - 2022 coronary artery disease-reporting and data system: an expert consensus document of the Society of Cardiovascular Computed Tomography (SCCT), the American College of Cardiology (ACC), the American College of Radiology (ACR), and the North America Society of Cardiovascular Imaging (NASCI). *JACC Cardiovasc Imaging* 2022;15:1974-2001
- Park CH, Kim C, Lee BY, Park CH, Kang EJ, Koo HJ, et al. Semi-quantitative scoring of late gadolinium enhancement of the left ventricle in patients with ischemic cardiomyopathy: consensus statement from the Asian Society of Cardiovascular Imaging-Practical Tutorial (ASCI-PT) 2020. *Cardiovasc Imaging Asia* 2021;5:26-36
- Kim C, Park CH, Kim DY, Cha J, Lee BY, Park CH, et al. Semi-quantitative scoring of late gadolinium enhancement of the left ventricle in patients with ischemic cardiomyopathy: improving interobserver reliability and agreement using consensus guidance from the Asian Society of Cardiovascular Imaging-Practical Tutorial (ASCI-PT) 2020. *Korean J Radiol* 2022;23:298-307
- Raff GL, Abidov A, Achenbach S, Berman DS, Boxt LM, Budoff MJ, et al. SCCT guidelines for the interpretation and reporting of coronary computed tomographic angiography. *J Cardiovasc Comput Tomogr* 2009;3:122-136
- Weigold WG, Abbara S, Achenbach S, Arbab-Zadeh A, Berman

- D, Carr JJ, et al. Standardized medical terminology for cardiac computed tomography: a report of the Society of Cardiovascular Computed Tomography. *J Cardiovasc Comput Tomogr* 2011;5:136-144
15. Puchner SB, Liu T, Mayrhofer T, Truong QA, Lee H, Fleg JL, et al. High-risk plaque detected on coronary CT angiography predicts acute coronary syndromes independent of significant stenosis in acute chest pain: results from the ROMICAT-II trial. *J Am Coll Cardiol* 2014;64:684-692
 16. Braunwald E. Progress in the noninvasive detection of high-risk coronary plaques. *J Am Coll Cardiol* 2015;66:347-349
 17. Lee SE, Sung JM, Andreini D, Al-Mallah MH, Budoff MJ, Cademartiri F, et al. Differences in progression to obstructive lesions per high-risk plaque features and plaque volumes with CCTA. *JACC Cardiovasc Imaging* 2020;13:1409-1417
 18. Motoyama S, Ito H, Sarai M, Kondo T, Kawai H, Nagahara Y, et al. Plaque characterization by coronary computed tomography angiography and the likelihood of acute coronary events in mid-term follow-up. *J Am Coll Cardiol* 2015;66:337-346
 19. Kolossváry M, Szilveszter B, Merkely B, Maurovich-Horvat P. Plaque imaging with CT—a comprehensive review on coronary CT angiography based risk assessment. *Cardiovasc Diagn Ther* 2017;7:489-506
 20. Bom MJ, van der Heijden DJ, Kedhi E, van der Heyden J, Meuwissen M, Knaapen P, et al. Early detection and treatment of the vulnerable coronary plaque: can we prevent acute coronary syndromes? *Circ Cardiovasc Imaging* 2017;10:e005973
 21. Shaw LJ, Blankstein R, Bax JJ, Ferencik M, Bittencourt MS, Min JK, et al. Society of Cardiovascular Computed Tomography/North American Society of Cardiovascular Imaging - expert consensus document on coronary CT imaging of atherosclerotic plaque. *J Cardiovasc Comput Tomogr* 2021;15:93-109
 22. Min JK, Shaw LJ, Devereux RB, Okin PM, Weinsaft JW, Russo DJ, et al. Prognostic value of multidetector coronary computed tomographic angiography for prediction of all-cause mortality. *J Am Coll Cardiol* 2007;50:1161-1170
 23. Plank F, Burghard P, Friedrich G, Dichtl W, Mayr A, Klauser A, et al. Quantitative coronary CT angiography: absolute lumen sizing rather than %stenosis predicts hemodynamically relevant stenosis. *Eur Radiol* 2016;26:3781-3789
 24. Koo BK, Yang HM, Doh JH, Choe H, Lee SY, Yoon CH, et al. Optimal intravascular ultrasound criteria and their accuracy for defining the functional significance of intermediate coronary stenoses of different locations. *JACC Cardiovasc Interv* 2011;4:803-811
 25. Kang SJ, Ahn JM, Song H, Kim WJ, Lee JY, Park DW, et al. Usefulness of minimal luminal coronary area determined by intravascular ultrasound to predict functional significance in stable and unstable angina pectoris. *Am J Cardiol* 2012;109:947-953
 26. Kristensen TS, Engstrøm T, Kelbæk H, von der Recke P, Nielsen MB, Kofoed KF. Correlation between coronary computed tomographic angiography and fractional flow reserve. *Int J Cardiol* 2010;144:200-205
 27. Boogers MJ, Schuijf JD, Kitslaar PH, van Werkhoven JM, de Graaf FR, Boersma E, et al. Automated quantification of stenosis severity on 64-slice CT: a comparison with quantitative coronary angiography. *JACC Cardiovasc Imaging* 2010;3:699-709
 28. Motoyama S, Kondo T, Sarai M, Sugiura A, Harigaya H, Sato T, et al. Multislice computed tomographic characteristics of coronary lesions in acute coronary syndromes. *J Am Coll Cardiol* 2007;50:319-326
 29. Hadamitzky M, Achenbach S, Al-Mallah M, Berman D, Budoff M, Cademartiri F, et al. Optimized prognostic score for coronary computed tomographic angiography: results from the CONFIRM registry (coronary CT angiography evaluation for clinical outcomes: an international multicenter registry). *J Am Coll Cardiol* 2013;62:468-476