



# Acupuncture-Induced Abscess in the Retroperitoneal Cavity and Thigh Muscle: A Case Report

침술로 인한 후복막강 및 허벅지 근육의 농양: 증례 보고

Duk Ju Kim, MD, In Chul Nam, MD\*, Doo Ri Kim, MD,  
Jeong Sub Lee, MD, Kyung Ryeol Lee, MD,  
Bong Soo Kim, MD, Guk Myung Choi, MD

Department of Radiology, Jeju National University Hospital, Jeju National University School of Medicine, Jeju, Korea

Received June 7, 2023  
Revised July 14, 2023  
Accepted August 10, 2023

\*Corresponding author

In Chul Nam, MD  
Department of Radiology,  
Jeju National University Hospital,  
Jeju National University  
School of Medicine,  
15 Aran 13 gil, Jeju 63241, Korea.

Tel 82-64-717-1382  
Fax 82-64-717-1371  
E-mail sky\_hall@naver.com

This is an Open Access article distributed under the terms of the Creative Commons Attribution Non-Commercial License (<https://creativecommons.org/licenses/by-nc/4.0>) which permits unrestricted non-commercial use, distribution, and reproduction in any medium, provided the original work is properly cited.

Acupuncture is increasingly being used in Asian countries and is generally considered a relatively safe procedure. However, adverse events have been reported consistently. Therefore, clinicians should be aware of the possibility of acupuncture-related complications and should actively treat serious cases. We report a case of an acupuncture-induced large abscess in the retroperitoneal cavity and thigh muscles treated with percutaneous catheter drainage, surgical incision, and drainage.

**Index terms** Acupuncture; Abscess; Catheter; Indwelling

## INTRODUCTION

Acupuncture is a field of Oriental medicine in which solid needles are inserted at specific points in the body to treat diseases and symptoms (1). It is increasingly being used, particularly in Asian countries, and is generally considered a relatively safe procedure. A systematic review of acupuncture-related infections in the Korean literature up to 2015 revealed that essential information for judging causality and appropriateness of acupuncture practice was not adequately reported (2). Nonetheless, the incidence of complications may be lower in international cases. The incidence of mild or transient complications ranges from 6.7% to 15%, and serious adverse events are rare (1, 3). However, adverse events, including infectious cases such as suppurative arthritis, erysipelas, necrotizing fasciitis, and paravertebral abscesses, as well as serious cases such as hepatitis, intra-abdominal abscess, and hematoma with active bleeding have

been reported consistently (4-7). Therefore, clinicians should be aware of the possibility of acupuncture-related complications and actively treat serious cases. Herein, we report a case of a serious infectious complication caused by acupuncture that was treated with percutaneous catheter drainage (PCD), surgical incision, and drainage.

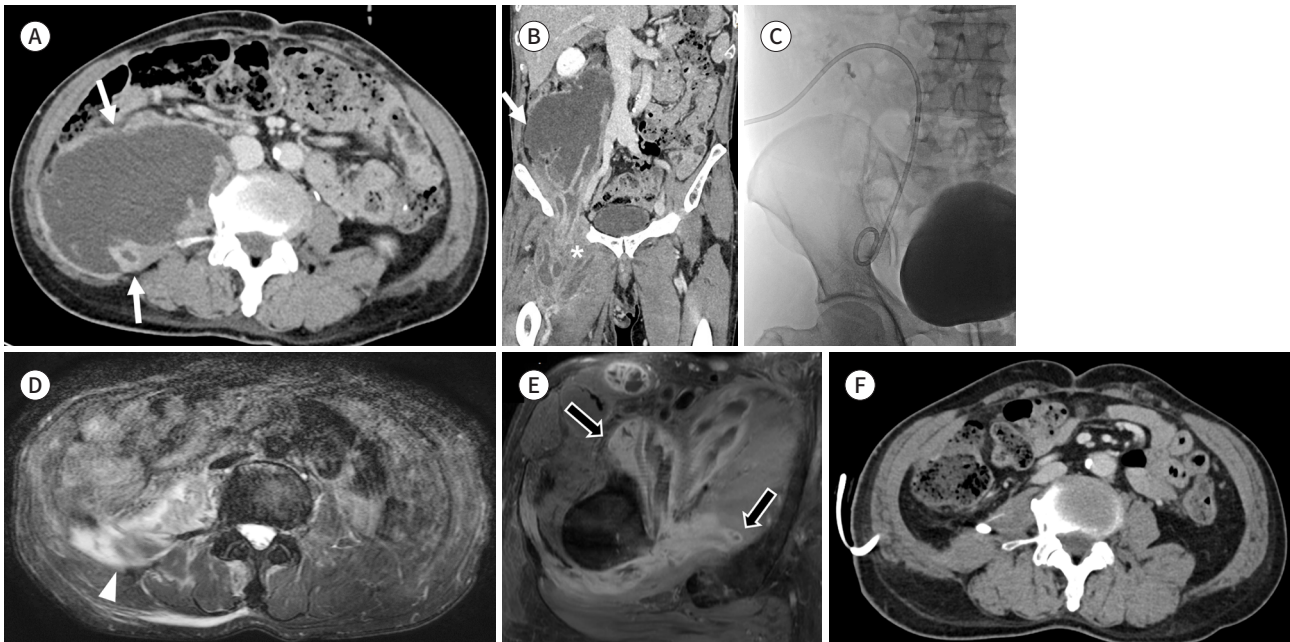
## CASE REPORT

A healthy 63-year-old male patient visited our emergency department and presented with right leg swelling and pain four days after symptom onset. He also experienced a fever with a high body temperature of 39.4°C. His heart rate, respiratory rate, and blood pressure were 114 beats/min, 20 breaths/min, and 133/76 mmHg, respectively. He denied any underlying medical conditions, including history of trauma, diabetes, or medication use at the time of admission. However, he had a history of adenocarcinoma in the rectosigmoid colon and had undergone low anterior resection three years previously. Laboratory tests revealed a C-reactive protein (CRP) level of 29.49 mg/dL, white blood cell (WBC) of  $19.6 \times 10^3/\mu\text{L}$ , and procalcitonin level of 0.420 ng/mL, indicating an infection. Axial CT revealed a large abscess, approximately 13 cm in size, in the right retroperitoneum and right thigh muscle without active bleeding (Fig. 1A, B). As the blood culture was not identified, clinicians empirically administered third generation cephalosporins, ceftriaxone, and clindamycin. The patient was transferred to the intervention room for treatment, which included 10.2-Fr PCD, a biliary drainage catheter with multiple side holes (Vasflex, Yeongcheon, Republic of Korea) of the abscess (Fig. 1C). Because the cause of the abscess had not yet been identified, we conducted further evaluations, which revealed a history of acupuncture. He reported undergoing acupuncture for pain in his right leg and several more times because of the right leg swelling after the first acupuncture. Bacterial cultures of the pus specimens revealed *Eikenella corrodens* (*E. corrodens*). Hence, the clinicians adjusted the antibiotic regimen and removed clindamycin while continuing ceftriaxone. The size of the retroperitoneal abscess significantly decreased on the lumbar spine MRI eight days after PCD (Fig. 1D). The patient's body temperature was 36.7°C, and the CRP level and WBC were 11.05 mg/dL and  $10.2 \times 10^3/\mu\text{L}$ , respectively. The patient reported no abnormalities other than pain at the procedural site. However, in the thigh MRI performed four days later, the size of the abscess did not decrease further and extended into the pectineus, adductor brevis, obturator externus, quadratus femoris, adductor magnus, sartorius muscle, and superficial fascia of the long-head biceps femoris muscle. It also extended to the deep fascia of the adductor magnus, semitendinosus, and the long head of the biceps femoris muscle (Fig. 1E). Therefore, incision and drainage surgeries were performed. Although no signs of active pus were observed, pus-like fluid was drained based on the surgical findings. The bacterial culture of the pus specimen indicated no bacterial growth. Antibiotics were adequately adjusted according to the identified bacteria through appropriate drainage and examination of the specimens obtained from the drainage, which reduced the CRP level to  $< 0.3$  mg/dL and improved the symptoms. An axial CT scan taken one month later revealed a resolved abscess cavity (Fig. 1F). The patient was discharged after drainage tube removal one month after admission.

This study was approved by our institutional review board (IRB No. JEJUNUH 2023-05-010).

**Fig. 1.** A 63-year-old male presents a huge abscess in the retroperitoneum and thigh.

- A.** Axial contrast-enhanced CT demonstrates a large space-occupying retroperitoneal abscess with a thick wall (arrows).  
**B.** Coronal reformatted contrast-enhanced CT demonstrates an abscess (arrow) extending to the right upper thigh (asterisk).  
**C.** Percutaneous drainage catheter is inserted.  
**D.** Lumbar spine MRI performed for back pain and T2-weighted fat-suppressed axial image demonstrate the decreased size of the retroperitoneal abscess with remaining irregular high signal intensity lesions in the right psoas muscle (arrowhead).  
**E.** Contrast-enhanced fat-suppressed axial MRI of the right thigh demonstrates prominent enhancement of the peripheral portion of the abscess (arrows) in the right pectineus, adductor brevis, obturator externus, quadratus femoris, adductor magnus, and sartorius muscles.  
**F.** Axial contrast-enhanced CT performed one month later demonstrates a nearly resolved abscess in the right psoas muscle and retroperitoneum. Note the insertion state of the percutaneous drainage catheter.



The requirement for informed consent was waived owing to the retrospective nature of the study.

## DISCUSSION

After searching the PubMed database using the keywords “acupuncture” and “adverse effect” for articles published in the last 30 and five years, we identified 4975 and 2330 cases, respectively. In addition, after searching the PubMed database using the keywords “acupuncture” and “abscess” for articles published in the last 30 years, we identified 103 cases. The number of reports of acupuncture complications, including serious adverse events, has increased. Acupuncture involves puncturing the body with a solid needle, and pneumothorax is the most common complication (5). Other complications, such as hemorrhage, infection, and abscesses, have also been reported. However, patients may not associate their symptoms with acupuncture and only visit the emergency department when their condition progresses. Additionally, if the clinician does not inquire regarding a patient’s history of acupuncture, the cause may remain unidentified. In our case, the patient visited the emergency department four days after symptom onset, and his acupuncture history was obtained only in the intervention room. Therefore, during history-taking, the possibility of acupuncture as the cause

should be considered, and if a serious case is suspected, imaging studies, such as contrast-enhanced CT, should be performed. Contrast-enhanced CT is an important modality for diagnosing active bleeding and should be prioritized over other imaging modalities.

Serious cases in patients undergoing acupuncture are often characterized by long intervals between acupuncture and emergency department visits (2). Patients may not suspect acupuncture as the cause and may delay seeking treatment. In our case, the patient did not initially associate pain or fever with acupuncture and continued to receive additional acupuncture treatment before visiting the emergency department. Consequently, the patient experienced serious complications and required antibiotic treatment, percutaneous drainage, and incision and drainage for improvement.

Gram-positive cocci are the most common pathogens causing skin and soft tissue infections. Microorganisms that cause adverse infectious events after acupuncture include *Staphylococcus*, *Streptococcus*, *Mycobacterium*, and *Klebsiella* (2). However, our patient reported the presence of *E. corrodens* after acupuncture, which has not been previously reported. *E. corrodens* is a Gram-negative, rod-shaped bacterium, generally susceptible to penicillin, ampicillin, amoxicillin, second and third generation cephalosporins, ureidopenicillins, tetracyclines, and fluoroquinolones. Clindamycin, macrolides, metronidazole, and aminoglycosides are all ineffective. *E. corrodens* is part of the normal human mucosal flora and can cause infectious diseases, such as endocarditis, brain abscesses, perirenal abscesses, head and neck infections, liver abscesses, and hip arthritis (8-10).

In conclusion, clinicians should be aware of the complications associated with acupuncture and perform accurate history-taking and appropriate imaging studies when acupuncture is suspected as the cause. Immediate intervention may be necessary in cases of serious adverse events.

### Author Contributions

Conceptualization, N.I.C.; data curation, K.D.J.; investigation, K.D.J.; supervision, N.I.C.; writing—original draft, K.D.J., N.I.C.; and writing—review & editing, N.I.C., K.D.R., L.J.S., L.K.R., K.B.S., C.G.M.

### Conflicts of Interest

The authors have no potential conflicts of interest to disclose.

### ORCID iDs

Duk Ju Kim  <https://orcid.org/0000-0003-1773-4230>  
In Chul Nam  <https://orcid.org/0000-0001-8406-6645>  
Doo Ri Kim  <https://orcid.org/0000-0001-5263-7693>  
Jeong Sub Lee  <https://orcid.org/0000-0002-4120-8655>  
Kyung Ryeol Lee  <https://orcid.org/0000-0002-9368-9825>  
Bong Soo Kim  <https://orcid.org/0000-0002-8148-9041>  
Guk Myung Choi  <https://orcid.org/0000-0003-0370-484X>

### Funding

None

### REFERENCES

1. Cho Y, Steven SH, Choi L. Percutaneous drainage control of an intraabdominal abscess caused by acu-

- puncture. *Med Case Stud Case Rep* 2016;5:101-105
2. Kim TH, Kang JW, Park WS. The reporting quality of acupuncture-related infections in Korean literature: a systematic review of case studies. *Evid Based Complement Alternat Med* 2015;2015:273409
  3. Melchart D, Weidenhammer W, Streng A, Reitmayr S, Hoppe A, Ernst E, et al. Prospective investigation of adverse effects of acupuncture in 97 733 patients. *Arch Intern Med* 2004;164:104-105
  4. MacPherson H, Thomas K, Walters S, Fitter M. The York acupuncture safety study: prospective survey of 34000 treatments by traditional acupuncturists. *BMJ* 2001;323:486-487
  5. Cho YP, Jang HJ, Kim JS, Kim YH, Han MS, Lee SG. Retroperitoneal abscess complicated by acupuncture: case report. *J Korean Med Sci* 2003;18:756-757
  6. Xu S, Wang L, Cooper E, Zhang M, Manheimer E, Berman B, et al. Adverse events of acupuncture: a systematic review of case reports. *Evid Based Complement Alternat Med* 2013;2013:581203
  7. Xiao L, Zhou T, Chen J, Hu Y, Zheng Y. Paravertebral abscess and bloodstream infection caused by *Burkholderia pseudomallei* after acupuncture: a case report. *BMC Complement Med Ther* 2022;22:95
  8. Gowda AL, Mease SJ, Dhar Y. *Eikenella corrodens* septic hip arthritis in a healthy adult treated with arthroscopic irrigation and debridement. *Am J Orthop (Belle Mead NJ)* 2014;43:419-421
  9. Nordholm AC, Vøgg ROB, Permin H, Katzenstein T. *Eikenella corrodens* endocarditis and liver abscess in a previously healthy male, a case report. *BMC Infect Dis* 2015;18:35
  10. Penton M 3rd, Oraa SS, Abdelhemid A, Otto C, Hammerschlag MR. Head and neck infections in children due to *Eikenella corrodens*: report of three cases and review of literature. *Int J Pediatr Otorhinolaryngol* 2020;138:110287

## 침술로 인한 후복막강 및 허벅지 근육의 농양: 증례 보고

김덕주 · 남인출\* · 김두리 · 이정섭 · 이경렬 · 김봉수 · 최국명

침술은 아시아 문화권에서 빈번하게 시행되고 있으며 비교적 안전한 시술로 알려져 있다. 그러나 침술과 관련된 부작용은 지속적으로 보고되고 있다. 따라서, 의료진은 침술과 관련된 합병증의 가능성을 인식하고, 심각한 경우에는 적극적으로 치료해야 한다. 우리는 침술로 인해 발생한 후복막강과 대퇴부 근육의 큰 농양과 이를 경피적 카테터 배액술 및 수술적 절개와 배농술로 치료한 사례를 보고한다.

제주대학교 의과대학 제주대학교병원 영상의학과