



# Transcholecystic Duodenal Drainage as an Alternative Decompression Method for Afferent Loop Syndrome: Two Case Reports

들장관증후군의 대체 감압 치료로서 경담낭 십이지장 배액술: 두 건의 증례 보고

Jihoon Hong, MD<sup>1</sup>, Gab Chul Kim, MD<sup>1\*</sup>, Jung Guen Cha, MD<sup>1</sup>,  
Jongmin Park, MD<sup>1</sup>, Byungeon Park, MD<sup>1</sup>,  
Seo Young Park, MD<sup>1</sup>, Sang Un Kim, MD<sup>2</sup>

<sup>1</sup>Department of Radiology, School of Medicine, Kyungpook National University, Daegu, Korea

<sup>2</sup>Department of Internal Medicine, Kyungpook National University Hospital, Daegu, Korea

Afferent loop syndrome (ALS) is a rare complication of gastrectomies and gastrointestinal reconstruction. This can predispose patients to fatal conditions, such as cholangitis, pancreatitis, and duodenal perforation with peritonitis. Therefore, emergency decompression is necessary to prevent these complications. Herein, we report two cases in which transcholecystic duodenal drainage, an alternative decompression treatment, was performed in ALS patients without bile duct dilatation. Two patients who underwent distal gastrectomy with Billroth II anastomosis sought consultation in an emergency department for epigastric pain and vomiting. On CT, ALS with acute pancreatitis was diagnosed. However, biliary access could not be achieved because of the absence of bile duct dilatation. To overcome this problem, a duodenal drainage catheter was placed to decompress the afferent loop after traversing the cystic duct via a transcholecystic approach. The patients were discharged without additional surgical treatment 2 weeks and 1 month after drainage.

**Index terms** Afferent Loop Syndrome; Drainage; Decompression

## INTRODUCTION

Afferent loop syndrome (ALS) is a rare complication of gastrectomy with Billroth II or Roux-en-Y reconstruction, characterized by the distal obstruction of the afferent

Received September 15, 2023

Revised October 18, 2023

Accepted November 5, 2023

Published Online February 15, 2024

\*Corresponding author

Gab Chul Kim, MD

Department of Radiology,  
School of Medicine,  
Kyungpook National University,  
680 Gukchaebosang-ro, Jung-gu,  
Daegu 41944, Korea.

Tel 82-53-200-3376

Fax 82-53-200-3349

E-mail [kingcrad@gmail.com](mailto:kingcrad@gmail.com)

This is an Open Access article distributed under the terms of the Creative Commons Attribution Non-Commercial License (<https://creativecommons.org/licenses/by-nc/4.0>) which permits unrestricted non-commercial use, distribution, and reproduction in any medium, provided the original work is properly cited.

loop, which results in cholangitis, pancreatitis, duodenal perforation, and peritonitis (1). Surgical bypass has been recommended as a treatment of choice (2). However, due to advanced malignant disease or poor general condition, many patients are poor surgical candidates (3). Emergency decompression may be required in many cases. Percutaneous transhepatic biliary drainage (PTBD) is a well-established procedure with a technical success rate of 98.7% (4). It can be easily converted into percutaneous transhepatic duodenal drainage (PTDD), which has also proven efficacious in afferent loop decompression (3, 5). However, obtaining biliary access can be technically challenging and is associated with a longer fluoroscopy time and a higher incidence of major bleeding if the intrahepatic bile duct (IHD) is not dilated (6). Unfortunately, some ALS patients do not exhibit IHD dilatation (3, 7). Under these circumstances, the gallbladder can be used as a simple and safe route for percutaneous entry into the biliary system, subsequent to the afferent loop. After Billroth II and Roux-en-Y reconstruction, the gallbladder often remains intact. Technically, especially cystic duct cannulation, previous studies reported relatively high success rates (90.4%–100%) of transcholecystic removal of the common bile duct (CBD) stone or CBD stricture stenting as an alternative for transhepatic approach (6, 8). Herein, we report two cases in which transcholecystic duodenal drainage was successfully performed for decompression of the afferent loop in patients with ALS presenting with acute pancreatitis without IHD dilatation.

## CASE REPORTS

### CASE 1

A 78-year-old female patient visited the emergency room with a chief complaint of periumbilical abdominal pain associated with nausea and vomiting that had started 7 hours earlier. She had undergone distal gastrectomy with Billroth II anastomosis and D2 lymphadenectomy for advanced gastric cancer six months prior. She received adjuvant chemotherapy once; however, further sessions were delayed because of poor clinical condition. Upon admission, the patient's vital signs were stable. The laboratory test revealed leukocytosis (12980/ $\mu$ L) and pancreatic enzyme elevation (amylase, 1685 U/L; lipase, 2985 U/L); however, the total and direct bilirubin levels were within the normal range. Contrast-enhanced CT revealed diffuse dilatation of the afferent loop and no clear enhancing wall thickening or mass lesions at the anastomosis site (Fig. 1A). Additionally, diffuse pancreatic swelling with peripancreatic fat infiltration was noted, suggesting acute pancreatitis. Decompression via an L-tube was attempted while continuing antibiotic medication; however, no significant effect was noted for 2 days, and afferent loop decompression through PTBD was requested. Because preprocedural CT revealed no IHD dilatation and the mild distension of the gallbladder, transcholecystic duodenal drainage was planned. The gallbladder was approached through the transhepatic route using a 21-G Chiba needle and a transitional sheath under conscious sedation. Thereafter, a 5-Fr angiographic catheter (Kumpe; Cook Medical, Bloomington, IN, USA) and a 0.035-in hydrophilic guidewire (Radifocus Guide Wire M; Terumo, Tokyo, Japan) were used to cannulate the cystic duct with gentle catheter torque and wiring (Fig. 1B). After advancement to the CBD and duodenum, the guidewire was replaced with a stiff-type wire (Radifocus Guide Wire M; Terumo), and an 8.5-Fr drainage catheter with multiple side holes (Biliary

drainage catheter; Cook Medical) was advanced to locate its tip in the duodenal 3rd portion of the afferent loop (Fig. 1C). Bile-stained serous fluid was evacuated through the catheter. The following day, laboratory tests for pancreatitis revealed gradual improvement: amylase (205 U/L) and lipase (84 U/L). Esophagogastroduodenoscopy (EGD) revealed a patent lumen of the afferent and efferent loops with proper decompression, and only edematous hyperemic mucosa on the afferent loop side of the anastomosis (Fig. 1D). Lesional biopsy was performed. After

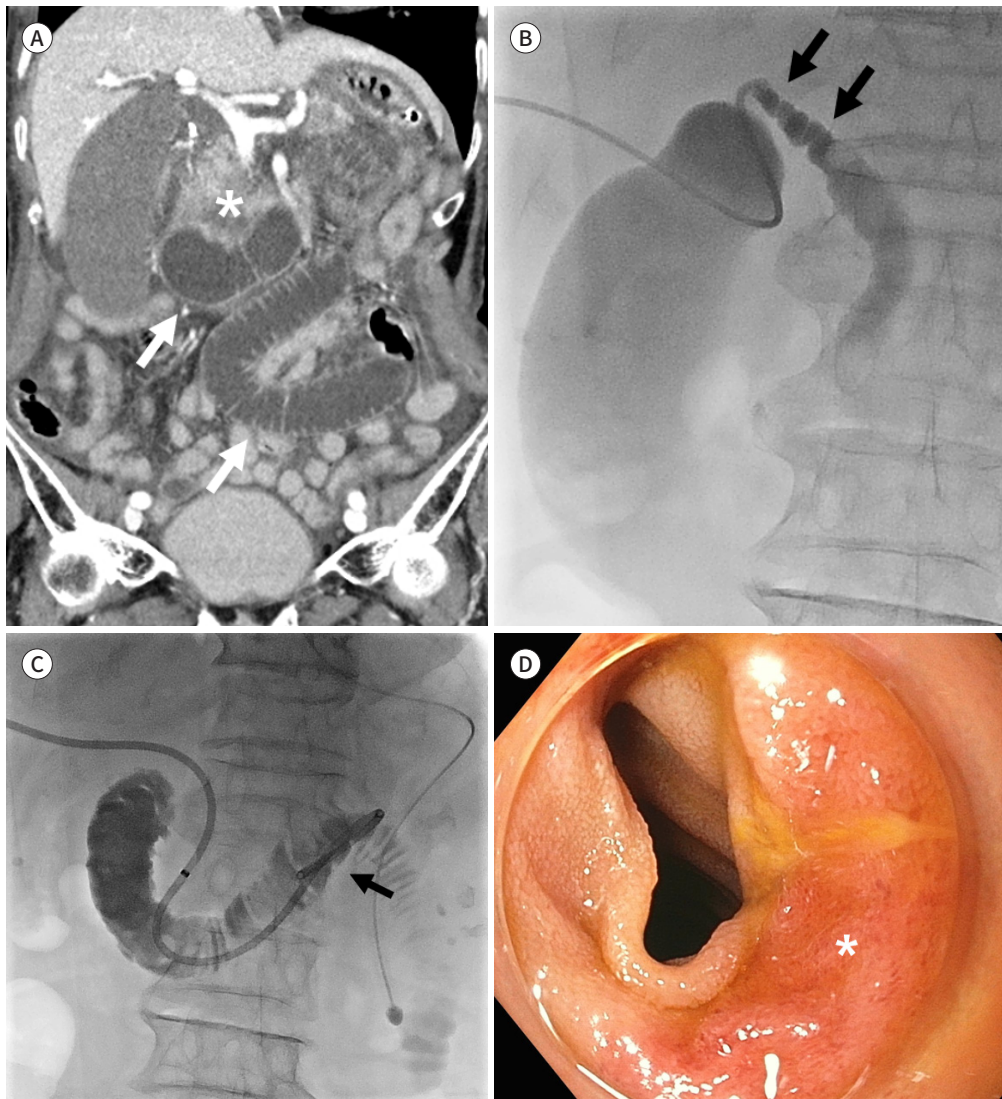
**Fig. 1.** A 78-year-old female who had undergone distal gastrectomy with Billroth II anastomosis for advanced gastric cancer 6 months prior.

**A.** Coronally reformatted CT reveals a markedly dilated afferent loop (arrows) suggesting afferent loop syndrome. Moreover, pancreatic head edema with heterogeneous enhancement is shown (\*).

**B.** A spot fluoroscopic image acquired after cholecystography shows a 5-Fr catheter inserted into a cork-screw-shaped cystic duct (arrows).

**C.** A 8.5-Fr biliary drainage catheter is placed across the gallbladder, cystic duct, common bile duct, and duodenum on fluoroscopy image. The catheter tip (arrow) is located in the fourth portion of the duodenum.

**D.** Endoscopic image demonstrates edematous hyperemic mucosa (\*) at the anastomosis site on the afferent loop side.



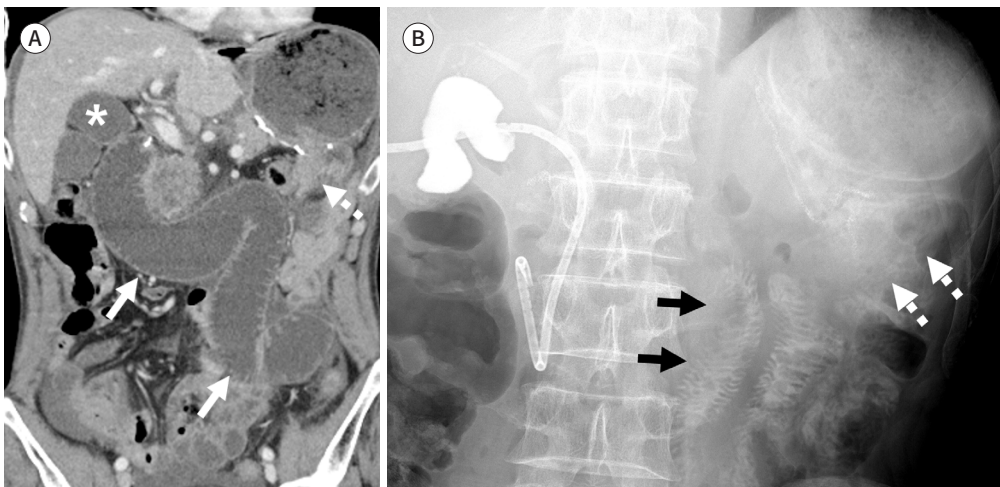
3 days, PET-CT revealed no sign of gastric cancer recurrence including the anastomosis site and other abdominal organs. Moreover, prior biopsy results showed only jejunitis. On the same day, the amount of external catheter drainage was markedly reduced, and afferent loop patency was confirmed on subsequent tubography. Laboratory test results returned to normal 2 weeks after duodenal drainage, and the drainage catheter was removed 3 days after clamping. On a 7-month follow-up CT scan, the patient exhibited no recurrence at the anastomotic site or new-onset ALS.

## CASE 2

A 62-year-old male patient visited the emergency room complaining of epigastric pain with tenderness that had started 7 hours earlier. He had undergone distal gastrectomy with Billroth II anastomosis and D2 lymphadenectomy for advanced gastric cancer 12 days before presentation. During admission, he had stable vital signs, and subsequent laboratory test demonstrated elevated C-reactive protein (2.93 mg/dL) and pancreatic enzymes (amylase, 714 U/L; lipase, 711 U/L) but normal total and direct bilirubin levels. CT revealed diffuse afferent loop dilatation and a residual stomach. Enhancing wall thickening or mass lesion at the anastomosis was not observed (Fig. 2A). Focal swelling of the pancreatic head with fat infiltration was observed, suggesting acute pancreatitis. Subsequently, afferent loop decompression was requested through the PTBD. However, IHD dilatation was not observed; thus, a transcholecystic approach was used. An 8.5-Fr transcholecystic duodenal drainage catheter was inserted, as described in Case 1. The next day, the patient's symptoms resolved, and subsequent EGD revealed swelling of the afferent loop and efferent loop anastomosis; no lumen was secured during air inflation. Pancreatic enzyme levels were within normal limits 2 days after duodenal drainage, and the diet was administered. Discharge was considered; however,

**Fig. 2.** A 62-year-old male who had undergone distal gastrectomy with Billroth II anastomosis for advanced gastric cancer 12 days prior.

- A.** Coronally reformatted CT reveals a markedly dilated afferent loop (arrows) and no definite wall thickening or mass at the anastomosis site (dotted arrow). The gallbladder is slightly distended (\*).
- B.** Thirteen days after transcholecystic duodenal drainage, follow-up tubography via gastrografin reveals a well-decompressed afferent loop (arrows) and contrast passage to the efferent loop (dotted arrows).





7 days postoperatively, fever (39.5°C) developed, and amylase and lipase levels increased again to 188 and 152 U/L, respectively. Malfunction of the duodenal drainage catheter was confirmed, and over-the-wire exchange was performed using a 10.2-Fr catheter. Thirteen days after the first procedure, tubography confirmed passage of the contrast medium into the efferent loop (Fig. 2B). To ensure his safety, the patient was readmitted 1 month after discharge and the catheter was removed. The patient underwent scheduled adjuvant chemotherapy and demonstrated no recurrent ALS or tumor recurrence during clinical and follow-up imaging at 1 year and 6 months.

## DISCUSSION

In previous studies, surgical revision procedures were successfully performed in 75% of patients with jaundice caused by afferent loop obstruction (9). However, several patients are poor candidates for a second surgery owing to a debilitated state, associated peritoneal adhesion, or disseminated tumors. Furthermore, pancreatitis or cholangitis resulting from afferent loop obstruction may necessitate emergency palliative procedures. Meanwhile, patients in 17 of 23 reported cases showed inflammatory edema of the mucosa or even inflammatory stenosis of the gastrojejunal anastomosis, and four revealed no obvious findings in a recent study describing the endoscopic appearance of ALS (10). That study reported that clinical success had been attained with initial decompression treatment using an endoscopic nasogastric tube in all patients, and delayed operative treatment was required in only two patients. Similarly, in our study, edematous hyperemic mucosa and afferent loop anastomosis swelling were observed on EGD, and the catheter was removed without additional surgery after treatment for acute pancreatitis and afferent loop drainage for 2 weeks and 1 month, respectively. These results highlight the importance of decompression as a bridge procedure that determines whether surgical treatment is warranted.

Percutaneous decompression options, such as PTBD and PTDD, have traditionally been used (3, 5). However, technical difficulty may occur with nondilated IHD, and even if successful, complications related to bleeding may increase (6). Additionally, there have been case reports of direct loop drainage as an alternative approach. However, this procedure may lead to peritonitis secondary to spillage and frequent catheter dislodgement caused by bowel peristalsis (9). Moreover, not all cases had appropriate puncture localization, whether under ultrasound or CT guidance. A recent study reported on the efficacy of nasogastric tube insertion via endoscopy (10). However, alterations in postsurgical anatomy can present remarkable challenges for endoscopic access to the afferent small bowel loop, especially for anastomotic angulation or long segmental strictures (2).

The proposed transcholecystic approach has several advantages. First, the percutaneous approach to the gallbladder is a safety-proven procedure for biliary intervention. If an appropriate transhepatic approach is used, the risk of catheter dislodgement or peritoneal spillage can be reduced (8). Second, it can provide an alternative route for patients who develop pancreatitis, but do not manifest jaundice secondary to bile duct dilatation. Third, although additional research is essential, additional palliative procedures such as duodenal stenting are possible through this route. However, this technique has some disadvantages. Bile duct dilata-

tion and bacterial implantation may occur with catheter occlusion or dislodgement, inducing ascending cholangitis (10). This can be prevented by frequently evaluating the drainage volume and the catheter function. Failure of cystic duct cannulation is also a contributing factor and has been reported to have a relatively high failure rate of 9.6% (6). Furthermore, this can be even higher if the cystic duct has a small diameter or tortuous course, is invaded by a malignancy, or is occluded by a stone (8). Lastly, it was limited to patients who had undergone Whipple surgery or previous cholecystectomy and had no remaining gallbladder.

In conclusion, we have reported two cases of successful transcholecystic duodenal drainage in ALS patients with acute pancreatitis. In ALS patients without bile duct dilatation, the gallbladder may be a safe alternative to decompression treatment.








### Author Contributions

Conceptualization, K.G.C., P.S.Y.; data curation, P.B., C.J.G.; resources, P.J., K.S.U.; supervision, K.G.C.; writing—original draft, H.J.; and writing—review & editing, H.J.

### Conflicts of Interest

The authors have no potential conflicts of interest to disclose.

### ORCID iDs

Jihoon Hong  <https://orcid.org/0000-0003-3389-244X>  
 Gab Chul Kim  <https://orcid.org/0000-0001-7963-7538>  
 Jung Guen Cha  <https://orcid.org/0000-0002-2519-2120>  
 Jongmin Park  <https://orcid.org/0000-0001-9240-4181>  
 Byunggeon Park  <https://orcid.org/0000-0002-5807-9271>  
 Seo Young Park  <https://orcid.org/0000-0002-4626-4285>  
 Sang Un Kim  <https://orcid.org/0000-0003-0530-1665>

### Funding

None

## REFERENCES

1. Grotewiel RK, Cindass R. *Afferent loop syndrome*. Treasure Island, FL: StatPearls, 2023
2. Blouhos K, Boulas KA, Tsalis K, Hatzigeorgiadis A. Management of afferent loop obstruction: reoperation or endoscopic and percutaneous interventions? *World J Gastrointest Surg* 2015;7:190-195
3. Lee KD, Liu TW, Wu CW, Tiu CM, Liu JM, Chung TR, et al. Non-surgical treatment for afferent loop syndrome in recurrent gastric cancer complicated by peritoneal carcinomatosis: percutaneous transhepatic duodenal drainage followed by 24-hour infusion of high-dose fluorouracil and leucovorin. *Ann Oncol* 2002;13:1151-1155
4. Uberoi R, Das N, Moss J, Robertson I. British Society of Interventional Radiology: biliary drainage and stenting registry (BDSR). *Cardiovasc Intervent Radiol* 2012;35:127-138
5. Yao NS, Wu CW, Tiu CM, Liu JM, Whang-Peng J, Chen LT. Percutaneous transhepatic duodenal drainage as an alternative approach in afferent loop obstruction with secondary obstructive jaundice in recurrent gastric cancer. *Cardiovasc Intervent Radiol* 1998;21:350-353
6. Jung GS, Kim YJ, Yun JH, Park JG, Yun BC, Han BH, et al. Percutaneous transcholecystic removal of common bile duct stones: case series in 114 patients. *Radiology* 2019;290:238-243
7. Kim KY, Han YM, Jung EH, Jin GY, Chae KJ, Lee KJ. Percutaneous transabdominal metallic stent placement for palliation of afferent loop syndrome: a case report. *J Korean Soc Radiol* 2019;80:333-338
8. Hatzidakis A, Venetucci P, Krokidis M, Iaccarino V. Percutaneous biliary interventions through the gallbladder and the cystic duct: what radiologists need to know. *Clin Radiol* 2014;69:1304-1311
9. Kim YH, Han JK, Lee KH, Kim TK, Kim KW, Choi BI. Palliative percutaneous tube enterostomy in afferent-

loop syndrome presenting as jaundice: clinical effectiveness. *J Vasc Interv Radiol* 2002;13:845-849

10. Cao Y, Kong X, Yang D, Li S. Endoscopic nasogastric tube insertion for treatment of benign afferent loop obstruction after radical gastrectomy for gastric cancer: a 16-year retrospective single-center study. *Medicine (Baltimore)* 2019;98:e16475

## 들장관증후군의 대체 감압 치료로서 경담낭 십이지장 배액술: 두 건의 증례 보고

홍지훈<sup>1</sup> · 김갑철<sup>1\*</sup> · 차중근<sup>1</sup> · 박종민<sup>1</sup> · 박병건<sup>1</sup> · 박서영<sup>1</sup> · 김상운<sup>2</sup>

들장관증후군은 위장 재건술을 동반한 위절제술 후 발생하는 드문 합병증이다. 이 질환은 담관염, 췌장염, 복막염을 동반한 십이지장 천공과 같은 치명적인 상태에 이를 수 있어서, 즉각적인 감압 치료가 필요하다. 담관 확장이 없는 들장관증후군 환자를 위한 대체 감압 치료법으로 경담낭 십이지장 배액술을 시행한 두 건의 증례를 보고하고자 한다. Billroth II 문합술과 위위위절제술을 시행한 2명의 환자가 상복부 통증과 구토를 주소로 응급실에 내원하였다. 컴퓨터단층촬영에서 급성 췌장염을 동반한 들장관증후군으로 진단되었다. 담관 확장이 없어 담도를 통한 접근이 어려워, 경담낭 접근을 통해 담낭관을 통과한 후 들장관을 감압하기 위한 십이지장 배액 카테터를 설치하였다. 환자들은 배액술 시행 후 각각 2주와 1개월째에 추가적인 수술적 치료 없이 퇴원하였다.

<sup>1</sup>경북대학교 의과대학 영상의학교실,

<sup>2</sup>경북대학교병원 내과