



# Pulmonary Artery Periadventitial Hematoma in a Patient with Aortic Intramural Hematoma: A Case Report

대동맥벽내 혈종 환자에서의 폐동맥 외막주위 혈종:  
증례 보고

Hoon Kwon, MD<sup>1</sup>, Yeon Joo Jeong, MD<sup>2</sup>, Geewon Lee, MD<sup>1</sup>,  
Minhee Hwang, MD<sup>1</sup>, Jin You Kim, MD<sup>1</sup>, Nam Kyung Lee, MD<sup>1</sup>, Ji Won Lee, MD<sup>1\*</sup>

<sup>1</sup>Department of Radiology, Pusan National University School of Medicine and  
Medical Research Institute, Pusan National University Hospital, Busan, Korea

<sup>2</sup>Department of Radiology, Pusan National University School of Medicine and  
Medical Research Institute, Pusan National University Yangsan Hospital, Yangsan, Korea

A pulmonary artery periadventitial hematoma is a rare complication of a Stanford type A intramural hematoma. As the proximal ascending aorta and pulmonary artery share a common adventitial layer, extravasated blood from the intramural hematoma in the ascending thoracic aorta may extend to beneath the adventitia of the pulmonary artery. The authors describe a case involving a 66-year-old male with acute chest pain who presented with a pulmonary artery periadventitial hematoma associated with a Stanford type A intramural hematoma.

**Index terms** Pulmonary Artery Periadventitial Hematoma; Aortic Intramural Hematoma;  
Acute Aortic Syndrome; Tomography, X-Ray Computed

## INTRODUCTION

Pulmonary artery periadventitial hematoma (PAPH) is a potential complication of acute aortic syndrome (1). The condition is, in large part, associated with Stanford type A dissections, and its incidence is approximately 9% in patients who undergo aortic dissections (2-5) Herein, we present a case of PAPH associated with a Stanford type A intramural hematoma (IMH), accompanied by a series of follow-up images

Received July 27, 2023  
Revised February 14, 2024  
Accepted March 5, 2024  
Published Online May 14, 2024

**\*Corresponding author**

Ji Won Lee, MD  
Department of Radiology,  
Pusan National University  
School of Medicine and  
Medical Research Institute,  
Pusan National University Hospital,  
179 Gudeok-ro, Seo-gu,  
Busan 49241, Korea.

Tel 82-51-240-7354

Fax 82-51-244-7534

E-mail monophobia00@hanmail.net

This is an Open Access article  
distributed under the terms of the  
Creative Commons Attribution  
Non-Commercial License  
([https://creativecommons.org/  
licenses/by-nc/4.0](https://creativecommons.org/licenses/by-nc/4.0)) which permits  
unrestricted non-commercial use,  
distribution, and reproduction in  
any medium, provided the original  
work is properly cited.

illustrating its natural course.

## CASE REPORT

A 66-year-old male with a history of hypertension and cerebral infarction presented to the emergency department with a sudden onset of severe chest and abdominal pains. His blood pressure was 80/40 mmHg, with a body temperature of 36.2°C. Electrocardiography was unremarkable and chest radiography revealed a widened mediastinum and prominent bronchovascular marking in both lungs. Laboratory findings revealed an elevated C-reactive protein level (0.63 mg/dL [normal, 0–0.5 mg/dL]), high-sensitivity troponin I (159.7 ng/mL [normal, 0–17.8 pg/mL]), and liver enzymes, including alanine transaminase (72 U/L [normal, 0–40 U/L]) and alkaline phosphatase (72 U/L [normal, 0–40 U/L]). Echocardiography revealed dilatation and wall thickening of the ascending thoracic aorta without definite evidence of an intimal flap. Mild to moderate aortic regurgitation was also observed.

Acute aortic syndrome was suspected, and CT was performed. Non-contrast CT revealed

**Fig. 1.** A 66-year-old male presented with PAPH and aortic IMH.

**A.** Axial non-contrast CT demonstrates crescent-shape hyperattenuation (arrows) in the ascending and descending thoracic aorta. Hemopericardium is also shown.

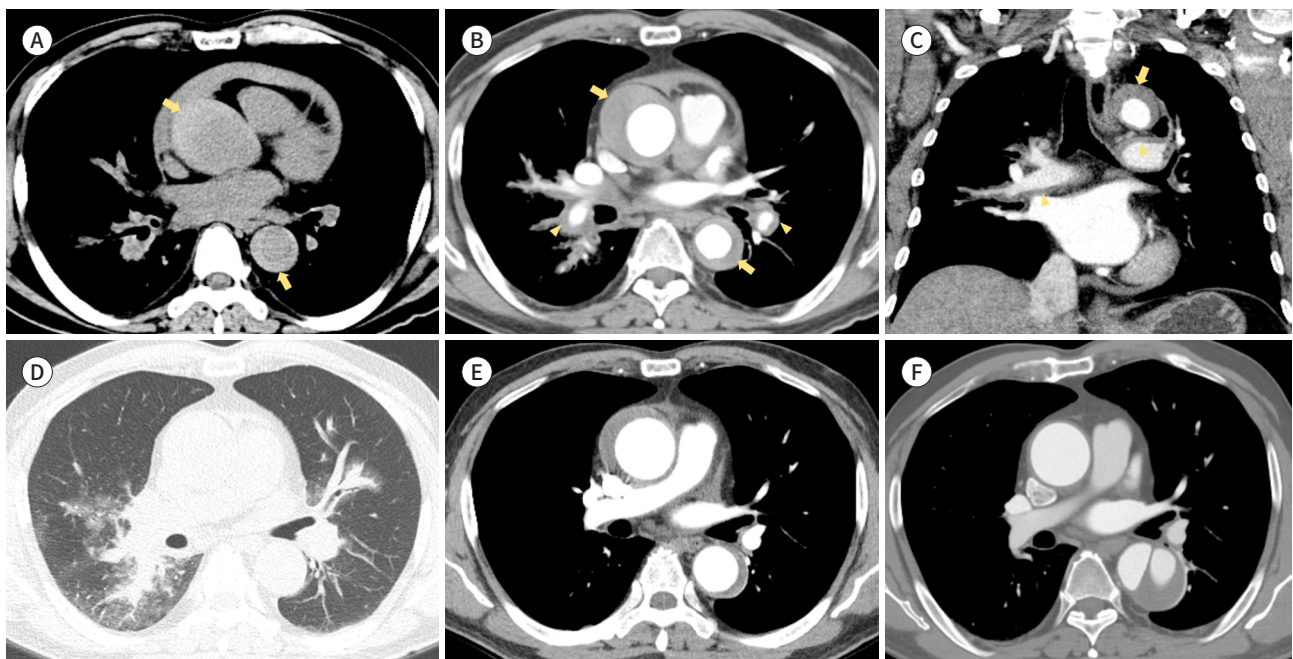
**B, C.** Axial (**B**) and coronal (**C**) contrast-enhanced CT reveal wall thickening of the thoracic aorta (arrows), suggesting Stanford type A IMH. In addition, circular wall thickening along both pulmonary arteries is evident (arrowheads). Although a definite high-dense lesion is not detected on the thickened pulmonary arterial wall, circular wall thickening without significant enhancement in the patient with aortic IMH suggests the possibility of PAPH.

**D.** Axial CT with a lung window demonstrates ground-glass opacities around the pulmonary artery in both lungs, indicating pulmonary hemorrhage.

**E.** Follow-up CT after 3 weeks reveals resorption of the PAPH and pulmonary hemorrhage. Furthermore, the extent of the aortic IMH decreases.

**F.** Follow-up CT performed after 2 years demonstrates resolution of the IMH of the ascending thoracic aorta; however, aortic dissection of the descending to infrarenal abdominal aorta (not shown) developed.

IMH = intramural hematoma, PAPH = pulmonary artery periadventitial hematoma



crescent-shape hyperattenuation in the ascending to the infrarenal abdominal aorta. A hemo-pericardium was also observed (Fig. 1A). Contrast-enhanced CT revealed wall thickening of the aorta, suggesting Stanford type A IMH and a hematoma along the pulmonary artery. A dissection flap in the aorta was not observed (Fig. 1B, C). Ground-glass opacities around the pulmonary artery on axial CT with a lung window indicated pulmonary hemorrhage (Fig. 1D). The treatment strategy for Stanford type A IMH is primarily surgery (6, 7); however, this patient did not undergo surgery because of his underlying health condition and increased operative risk. He received medical treatment including blood pressure control with intensive blood pressure monitoring and imaging follow-up. CT performed 3 weeks later revealed re-sorption of the PAPH and pulmonary hemorrhage. Furthermore, the extent of aortic IMH had decreased (Fig. 1E). Two years later, IMH of the ascending thoracic aorta was resolved; however, aortic dissection of the descending to infrarenal abdominal aorta developed (Fig. 1F).

This study was approved by the Institutional Review Board of our institution. Informed consent was waived due to the retrospective nature of the study (IRB No. 2023-0398).

## DISCUSSION

PAPH is rare complication of IMH (1, 4, 5). It occurs because the proximal ascending aorta and the pulmonary artery share a common adventitial layer, allowing extravasated blood from the ascending thoracic aorta to extend beneath the adventitia of the pulmonary artery (4). CT findings of PAPH include crescent-shape or circumferential thickening with increased density of the pulmonary arterial wall. There was no evidence of enhancement within the area on contrast-enhanced CT (2, 4).

High pressure within the blood-filled pulmonary adventitia causes its rupture, and the blood can enter the pulmonary interstitium and/or alveoli (8). Perivascular ground-glass opacities or consolidation on CT indicate pulmonary hemorrhage (3). To date, the clinical significance of PAPH remains unclear; however, Sueyoshi et al. (4) demonstrated that PAPH combined with an alveolar hemorrhage was an independent and significant risk factor for death in patients with aortic dissection. Furthermore, there is growing evidence in reports suggesting that PAPH results in acute narrowing of the pulmonary artery lumen. It simulates the effects of pulmonary hypertension and vasculitis, possibly even mimicking the clinical presentation of a pulmonary embolism by increasing the right ventricular afterload (9).

IMH is defined as the presence of blood within the media of the aortic wall without an overt intimal tear or patent false lumen (6, 7). Among patients with acute aortic syndrome, it has been reported that 5% to 25% exhibit IMH (7). CT has revealed the presence of a circular or crescent-shape thickening of the aortic wall, thicker than 5 mm, without detectable blood flow (6, 7). IMH can lead to the development of aortic dissection in 16% to 47% of patients but resolves in only < 10% (7). Stanford type A IMH is conventionally managed similarly to classical aortic dissection, especially in the West. However, findings among the Asian population have presented an alternative viewpoint, demonstrating favorable survival results with the medical-first approach. This highlights the significance of medical treatment in patients with uncomplicated Stanford type A IMH. A recent meta-analysis has examined the comparative advantages of immediate surgery versus the medical-first approach and suggested that medi-

cal treatment of type A IMH in an acute setting may be safe in selective patients. It is reported that, among the patients initially managed with medical treatment, 36% experienced resolution of IMH solely through blood pressure control (10).

In summary, we have described a rare case of PAPH, combined with a pulmonary hemorrhage, in a patient with Stanford type A IMH. We have also presented serial follow-up images and described an example of the natural course of these diseases. PAPH is a rare complication of IMH following blood extravasation from a ruptured aorta into the common aortopulmonary adventitia. Radiologists should be aware of its pathophysiology and imaging findings associated with acute aortic syndrome to enable a prompt diagnosis in affected patients.








### Author Contributions

Conceptualization, L.J.W.; data curation, K.H., K.J.Y., L.J.W.; formal analysis, K.J.Y.; investigation, K.H., L.J.W.; methodology, J.Y.J., L.J.W.; resources, L.N.K.; supervision, L.G., L.J.W.; visualization, H.M.; writing—original draft, K.H., L.J.W.; and writing—review & editing, J.Y.J., L.G., H.M., K.J.Y., L.N.K., L.J.W.

### Conflicts of Interest

The authors have no potential conflicts of interest to disclose.

### ORCID iDs

Hoon Kwon  <https://orcid.org/0000-0003-4055-5863>  
 Yeon Joo Jeong  <https://orcid.org/0000-0002-1741-9604>  
 Geewon Lee  <https://orcid.org/0000-0002-8278-0500>  
 Minhee Hwang  <https://orcid.org/0000-0003-2603-616X>  
 Jin You Kim  <https://orcid.org/0000-0002-9631-501X>  
 Nam Kyung Lee  <https://orcid.org/0000-0003-1972-2719>  
 Ji Won Lee  <https://orcid.org/0000-0003-1800-8548>

### Funding

This work was supported by a clinical research grant from the Pusan National University Hospital in 2021.

## REFERENCES

- Hodges WM, Jia L, White SF, Patel S, Keshavamurthy J. Aortic intramural hematoma with unique involvement of pulmonary arteries. *J Cardiovasc Comput Tomogr* 2020;14:e15-e17
- Gros-Gean J, Lebecque O, Nchimi A, Vlad MM. Case series: pulmonary artery intramural hematoma in Stanford type A acute aortic dissection. *J Belg Soc Radiol* 2021;105:34
- Guilmette J, Semionov A, Dennie C, Gahide G, Pressacco J, Fraser R, et al. Hemorrhagic infiltration of the aortopulmonary adventitia: a complication of acute aortic dissection. *Eur J Radiol* 2016;85:239-247
- Sueyoshi E, Matsuoka Y, Sakamoto I, Uetani M. CT and clinical features of hemorrhage extending along the pulmonary artery due to ruptured aortic dissection. *Eur Radiol* 2009;19:1166-1174
- Jinno A, Hirotsawa T. Aortic intramural haematoma associated with pulmonary artery periadventitial haematoma. *BMJ Case Rep* 2018;2018:bcr2018224853
- Murillo H, Molvin L, Chin AS, Fleischmann D. Aortic dissection and other acute aortic syndromes: diagnostic imaging findings from acute to chronic longitudinal progression. *Radiographics* 2021;41:425-446
- Writing Committee Members; Isselbacher EM, Preventza O, Hamilton Black Iii J, Augoustides JG, Beck AW, Bolen MA, et al. 2022 ACC/AHA guideline for the diagnosis and management of aortic disease: a report of the American Heart Association/American College of Cardiology Joint Committee on clinical practice guidelines. *J Am Coll Cardiol* 2022;80:e223-e393
- Milne EN, Cyrllak D. Interstitial pulmonary hemorrhage from mediastinal hematoma secondary to aortic

rupture. *Radiology* 1987;164:286-287

9. Plack DL, Rehfeldt KH, Nelson JA, Kauss ML. Pulmonary artery sheath hematoma. *Ann Card Anaesth* 2021; 24:232-233
10. Chow SCY, Wong RHL, Lakhani I, Wong MV, Tse G, Yu PSY, et al. Management of acute type A intramural hematoma: upfront surgery or individualized approach? A retrospective analysis and meta-analysis. *J Thorac Dis* 2020;12:680-689

## 대동맥벽내 혈종 환자에서의 폐동맥 외막주위 혈종: 증례 보고

권 훈<sup>1</sup> · 정연주<sup>2</sup> · 이지원<sup>1</sup> · 황민희<sup>1</sup> · 김진유<sup>1</sup> · 이남경<sup>1</sup> · 이지원<sup>1\*</sup>

폐동맥 외막주위 혈종은 Stanford A형 대동맥벽내 혈종의 드문 합병증이다. 근위부 상행 대동맥과 폐동맥은 공통된 혈관외막을 공유하고 있기 때문에 대동맥벽내 혈종의 혈액은 폐동맥으로 확산될 수 있다. 저자들은 급성 흉통을 호소하는 66세 남성에게서 보인 Stanford A형 대동맥벽내 혈종과 연관된 폐동맥 외막주위 혈종의 증례를 보고하고자 한다.

<sup>1</sup>부산대학교 의과대학 부산대학교병원 영상의학과,

<sup>2</sup>부산대학교 의과대학 양산부산대학교병원 영상의학과