



Feasibility and Safety of a Technique Intended to Place the Catheter Tip in the Right Atrium without Abutment Against the Cardiac Wall during Implantation of the Totally Implantable Venous Access Port

완전이식형 정맥 접근 포트 삽입 시 카테터 팁을 심벽에 닿지 않고 우심방 내 위치시키는 방법의 타당성과 안전성

Hyejin Park, MD , Tae-Seok Seo, MD* ,
Myung Gyu Song, MD , Woo Jin Yang, MD

Department of Radiology, Korea University Guro Hospital, Korea University College of Medicine, Seoul, Korea

ORCID iDs

Hyejin Park <https://orcid.org/0009-0003-3435-5483>
Tae-Seok Seo <https://orcid.org/0000-0002-4427-0198>
Myung Gyu Song <https://orcid.org/0000-0002-9861-2886>
Woo Jin Yang <https://orcid.org/0000-0003-2392-2174>

Purpose To assess the safety and feasibility of intentionally positioning the catheter tip in the right atrium (RA) without an abutment during implantation of a totally implantable venous access port (TIVAP).

Materials and Methods We enrolled 330 patients who had undergone TIVAP implantation between January and December 2016 and postoperative chest CT. The TIVAP was placed using the single-incision technique to access the axillary vein directly from the incision line. To position the catheter tip in the RA without abutment, blood return was checked before cutting. Catheter length and complications were evaluated by retrospectively reviewing medical images and records.

Results All patients achieved successful catheter tip positioning without abutment or dysfunction. The median tip position was 15.3 mm distal to the cavoatrial junction (CAJ) on fluoroscopy and 6 mm

Received May 24, 2023
Revised June 30, 2023
Accepted July 26, 2023

*Corresponding author

Tae-Seok Seo, MD
Department of Radiology,
Korea University Guro Hospital,
Korea University
College of Medicine,
148 Gurodong-ro, Guro-gu,
Seoul 08308, Korea.

Tel 82-2-2626-1354
Fax 82-2-2626-1379
E-mail g1q1papa@korea.ac.kr

This is an Open Access article distributed under the terms of the Creative Commons Attribution Non-Commercial License (<https://creativecommons.org/licenses/by-nc/4.0>) which permits unrestricted non-commercial use, distribution, and reproduction in any medium, provided the original work is properly cited.

distal to the CAJ on CT. Catheter tips migrated a median of 10.4 mm cephalically on CT compared to fluoroscopy. Thromboses were detected in the RA and superior vena cava in one patient each.

Conclusion Intentional catheter tip positioning in the RA without abutment is a safe and feasible technique with a low incidence of thrombosis and no observed dysfunction.

Index terms Catheter Tip; Catheter Abutment; Implantable Access Port

INTRODUCTION

Thrombosis and dysfunction are the most common complications associated with using totally implantable venous access ports (TIVAPs) and the major causes of explantation (1). The catheter tip position is a predisposing factor for catheter-related thrombosis and predictive factor for dysfunction (1, 2). When the catheter tip abuts the vascular wall, it irritates the endothelium, leading to denudation, which is considered the primary initiating event of thrombosis (3). Contact with the vascular wall and thrombosis around the catheter tip may cause dysfunction (1). Therefore, the catheter tip position is critical. However, no consensus has been reached regarding the optimal position, ranging from the superior vena cava (SVC) to the right atrium (RA) (4-10). The Quality Improvement Guidelines for Central Venous Access define successful catheter placement as the introduction of a catheter with the tip at the desired location and function for its intended use (11).

Techniques used for placing the catheter tip in the desired position vary with the specific situation and operator's preference (7, 12-16). Radiological landmarks, such as the carina, right tracheobronchial angle, and contour of the RA, have been used under fluoroscopic guidance to place the catheter tip at the intended position (13, 17-20). Various techniques, including those involving a guidewire or catheter, have been used to determine the length of the catheter to reach the intended position (7, 15, 21). The safe zone for placing the catheter tip is within 2 cm above and below the cavoatrial junction (CAJ) because of the low complication rate caused by catheter tip movement (4, 8, 9, 15, 22). In daily practice, we intentionally position the catheter tip in the central or cephalic portion of the RA without abutting the cardiac wall, accounting for both the anatomy and function of the catheter before determining the appropriate catheter length. The aim of the present study was to assess the feasibility and safety of this technique for positioning the tip in the RA without abutment during implantation.

MATERIALS AND METHODS

The Institutional Review Board of our hospital approved this retrospective study and waived the requirement for obtaining written informed consent (IRB No. 2018GR0319). We included 330 patients who had undergone TIVAP implantation between January and December 2016 and postoperative chest CT. Our sample comprised 158 male and 172 female with a mean age of 61.1 years (range: 24–95 years). Table 1 shows patient demographics. TIVAPs were implanted for chemotherapy to treat the underlying malignancies in all patients.

Preoperatively, all patients provided written informed consent. All procedures were per-

Table 1. Demographics and Clinical Characteristics from Medical Records

	Numbers/Days	%
Sex	330	
Male	158	47.9
Female	172	52.1
Mean age, years	61.1 (24–95)	
Access sites		
Right axillary vein	287	87.0
Left axillary vein	43	13.0
Median fluoroscopic time for TIVAP implantation, minute	0.3 (0.41, 0.1–2.8)	
Median time interval between a procedure and the first CT, days	41 (46.5, 0–182)	
CT follow-up during catheter indwelling periods, times		
Median number, times	5 (6.0, 1–26)	
Median period, days	362 (415.8, 0–1061)	

Data are presented as mean (range).

TIVAP = totally implantable venous access port

formed using an interventional radiology suite. A TIVAP (Celsite Discreet[®]; B. Braun Medical, Boulogne Cedex, France) with a 6.5-F single-lumen catheter made of silicon was placed using the single-incision technique to access the axillary vein without forming a subcutaneous tunnel (21). The axillary vein was punctured at the cephalic end of an oblique vertical incision in the right ($n = 287$) and left ($n = 43$) infraclavicular areas under ultrasound guidance. Under fluoroscopic guidance, the catheter was advanced through the peel-away sheath to the intended tip position in the central or cephalic portion of the RA contour. The tip abutment was checked by aspiration with a 10-mL syringe connected to the flushing hub of the catheter. If blood return was achieved without resistance, the catheter length and tip position were finalized. In the event of no blood return, the tip position was adjusted toward the cephalic direction by pulling it back until blood return was achieved without resistance. The catheter was cut at the final distance after pulling it out of the skin to a length of approximately 3 cm. This was performed to secure the working length for attaching the proximal end of the catheter to the reservoir and prevent migration into the tract or vein after cutting. The catheter was pushed into the tract, and the reservoir was placed in a subcutaneous pocket after attachment. In female, the ipsilateral breast was immobilized in a sitting position using a previously reported method to reduce catheter tip migration caused by positional changes (23).

Follow-up chest CT was performed using a 256-detector-row (Aquilion One; Toshiba Medical Systems, Tokyo, Japan) or a 128-detector-row (Somatom Definition Edge; Siemens Healthineers, Erlangen, Germany) CT scanner. CT scans were obtained to assess treatment responses and lung metastases during the scheduled follow-up, and axial CT scans with 3-mm thickness/increment were reconstructed.

Spot fluoroscopy was used to evaluate the catheter tip position immediately after placing the reservoir in the subcutaneous pocket. The first chest CT scans were reviewed using a picture archiving and communication system (PACS). To evaluate the position on the spot fluoroscopy image, the catheter length between an imaginary point indicating the CAJ and the tip was measured. The CAJ was considered as two vertebral body units below the carina (20),

and the catheter tips positioned at the cephalic and caudal portions of the CAJ were assigned negative and positive values, respectively. The first chest CT scan obtained after TIVAP insertion was used to evaluate the tip position to reduce the bias resulting from changes in the cardiac position due to variations in the diaphragm level or lung atelectasis during the follow-up period. The time interval between TIVAP insertion and the first CT scan was also calculated. The catheter tip position was defined as the position of the CAJ if the tip was noted on the same axial image as the crista terminalis, which is the caudal margin of the SVC (18). For each axial scan, the distance between the CAJ and the catheter tip was calculated at 3-mm intervals. The catheter tips remaining in the SVC and RA on the first CT scan were assigned negative and positive values, respectively (-3 mm, -6 mm in the SVC and +3 mm and +6 mm in the RA).

Axial, coronal, and sagittal CT scans obtained in the catheter indwelling period were reviewed to evaluate catheter-related complications, such as stenosis of the SVC, tip migration above the SVC, and thrombosis. The tip abutment against the cardiac wall was also evaluated in cases in which the catheter tip was in the RA on the CT scans. The migration distance of the catheter tip on the first CT scan was calculated and compared to that observed on the spot fluoroscopy image. Statistically significant differences in the migration distance according to the sex of the patient or access site were evaluated using the student's *t*-test. The total number of CT scans obtained in the catheter indwelling period and interval between the procedure and the last CT scan were calculated. The last CT scan was defined as a CT scan performed immediately before explantation in cases of TIVAP explantation or a recently performed CT scan in cases of death, transfer to another hospital, or lack of follow-up without explantation. For patients who were alive and had TIVAP, CT scans obtained up to December 31, 2018, were used for data acquisition. Electronic medical records were retrospectively reviewed. In the procedural report, the fluoroscopic time for TIVAP implantation and incidence of catheter migration during catheter cutting and reservoir attachment were reviewed.

RESULTS

Positioning the catheter tip without abutting the cardiac wall was successful in all patients. The catheter tips were positioned at median distances of 15.3 and 6 mm distal to the CAJ, according to spot fluoroscopy and first CT scans, respectively (Table 2). The catheter tips were positioned within 2 cm above or below the CAJ in 220 (66.7%) and 237 (71.8%) patients according to spot fluoroscopy and the first CT scans, respectively (Table 3). The tips were positioned in the RA in 313 (94.8%) and 225 (68.2%) patients according to spot fluoroscopy and the first CT scans, respectively. In all patients with a tip in the RA, the tip abutment against the cardiac wall was not detected on any of the follow-up CT scans. The median migration of the catheter tips towards the cephalic direction was 10.4 mm as observed on the first CT scan, compared to their position on the spot fluoroscopy image (Table 2). The median migration distances toward the cephalic direction were 11.9 and 8.4 mm in male and female, respectively. When accessing the right and left axillary veins, the median migration distances were 10.2 and 15.3 mm, respectively. The differences between the subgroups were not significant ($p = 0.184$ and $p = 0.154$, respectively; Table 2). The median interval between the proce-

Table 2. Length from the Cavoatrial Junction to the Catheter Tip on the Spot Fluoroscopy Scan at the Time of Placement and on the First CT Scan: Subgroup Comparison of the Positions

Position of the Catheter Tip (mm)	Variates				Total
	Male (n = 158)	Female (n = 172)	Right (n = 287)	Left (n = 43)	
Position on a spot fluoroscopy*					
Median	11.1	17.9	14.6	18.5	15.3
Mean ± SD	12.13 ± 10.62	17.42 ± 10.59	14.34 ± 10.90	18.58 ± 10.43	14.89 ± 10.93
Range	-14.4–39.1	-9.4–39.9	-14.4–39.9	-2.7–39.9	-14.4–39.9
Position on the 1st CT*					
Median	0	9	6	6	6
Mean ± SD	1.6 ± 17.1	9.3 ± 15.1	5.6 ± 17.0	6.0 ± 12.9	5.6 ± 16.9
Range	-42–54	-36–54	-42–54	-24–27	-42–54
Catheter tip migration†					
Median	-11.9	-8.4	-9.5	-15.7	-10.4
Mean ± SD	-10.53 ± 16.82	-8.15 ± 15.52	-8.80 ± 16.49	-12.58 ± 13.66	-9.29 ± 16.20
Range	-45.3–39.1	-48.4–39.5	-48.4–39.5	-41.4–22.0	-48.4–39.5
Statistical significance (p)	0.184		0.154		

*Negative value: tip in the superior vena cava; positive value: tip in the right atrium.

† Negative value: cephalic migration; positive value: caudal migration.

SD = standard deviation

Table 3. Catheter Tip Position on the Spot Fluoroscopy Image at the Time of Placement and on the First CT Scan

CT	Radiography						Total (%)
	-20.0 to -10.1	-10.0 to -0.1	0 to 10	10.1 to 20.0	20.1 to 30.0	30.1 to 40.0	
-50.0 to -40.1	1						1 (0.3)
-40.0 to -30.1		1	1	1			3 (0.9)
-30.0 to -20.1		3	11	6	1		21 (6.4)
-20.0 to -10.1	1	1	12	6	5		25 (7.6)
-10.0 to -0.1	1	2	21	18	11	2	55 (16.7)
0 to 10	1	2	26	35	29	7	100 (30.3)
10.1 to 20.0		3	16	16	14	8	57 (17.3)
20.1 to 30.0		1	6	19	15	11	52 (15.8)
30.1 to 40.0			2	4	3	2	11 (3.3)
40.1 to 50.0			1	1		1	3 (0.9)
50.1 to 60.0				1		1	2 (0.6)
Total (%)	4 (1.2)	13 (3.9)	96 (29.1)	107 (32.4)	78 (23.6)	32 (9.7)	330

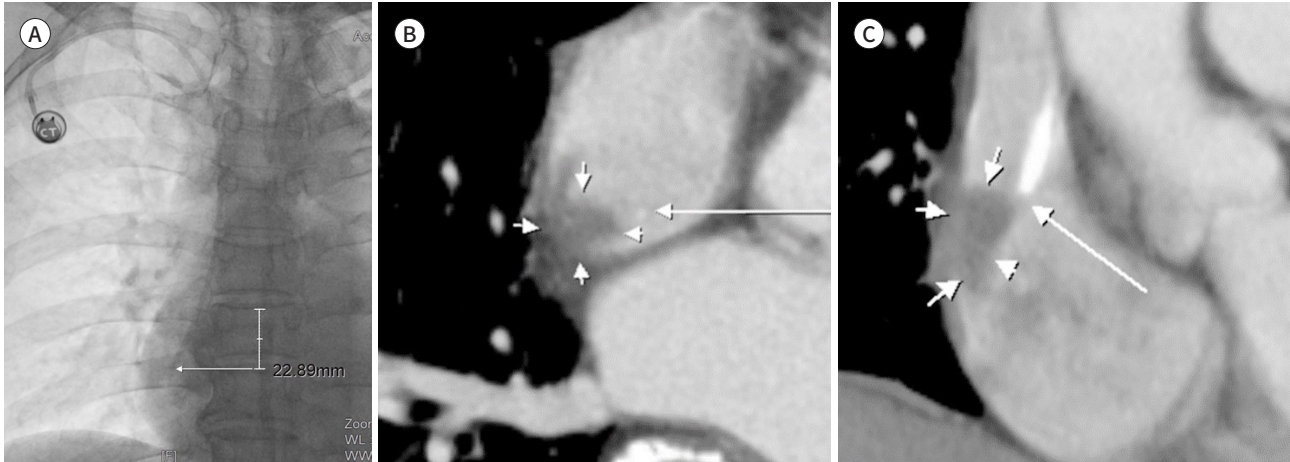
ture and the first CT scan was 41 days (range: 0–182 days).

Follow-up chest CT scans were performed a median of five times over a median of 362.5 days (Table 1). Thrombosis was the only complication observed in this study, occurring in the RA in one patient and SVC in another, and the catheter tip positions were the RA and CAJ on the first CT scan, respectively (two [0.6%] patients). No other catheter-related complications, such as stenosis of the SVC or tip migration above the SVC, were observed. The patient with a thrombus in the RA was a female with stomach cancer and nonvalvular atrial fibrillation

Fig. 1. Thrombosis in the right atrium of a 64-year-old female.

A. The spot fluoroscopy image shows the catheter tip position 22.9 mm distal to the cavoatrial junction, which is located two vertebral body units below the carina.

B, C. Axial (**B**) and coronal (**C**) reformatted images show the catheter tip in the right atrium without abutment against the wall (long arrows). A low-attenuation thrombus (short arrows) is observed on the wall of the right atrium around the catheter tip.



who was administered amiodarone and clopidogrel. The thrombus was diagnosed 46 days after implantation through the right axillary vein and was noted on the 117th day of follow-up. The patient died on the 128th day of follow-up. The lengths of the catheter beyond the CAJ were 23.2 mm and 30 mm, according to the spot fluoroscopy and first CT images, respectively (Fig. 1). The patient with thrombus in the SVC was a female with right breast cancer, and the thrombosis was asymptomatic. The patient was diagnosed 386 days after implantation through the left axillary vein and died on the 514th follow-up day. The lengths of the catheter beyond the CAJ were 19.8 mm and 0 mm according to spot fluoroscopy and the first CT scans, respectively. The median fluoroscopy duration of the entire procedure was 0.3 minutes (Table 1). There were no instances of catheter migration during attachment to the reservoir in any of the patients. TIVAPs were explanted in 95 patients, none of whom had catheter tip-associated complications such as thrombosis, dysfunction, or arrhythmia.

DISCUSSION

The lower one-third of the SVC and the cephalic portion of the RA are considered safe zones for positioning catheter tips (4, 9, 22). However, positioning the tip at a high level of the SVC may increase complications, such as catheter malfunction, thrombosis, and vessel perforation in the mediastinum (2, 6, 7, 22). Although rare, cardiac perforation and tamponade are serious complications that may occur when the tip is positioned in the RA (5, 22, 24, 25). Additionally, thrombosis or arrhythmia may develop. The risk of arrhythmia may increase if the tip is positioned too low; however, this risk is rarely serious (5, 26, 27). In the present study, the catheter tips were positioned in the RA in 313 (94.8%) patients and in a deep portion of the RA beyond 2 cm from the CAJ in 110 (33.3%) patients, according to spot fluoroscopy. Among the 313 patients in whom the catheter tip was placed in the RA, intra-atrial thrombosis developed in only 1 patient (0.3%) who had underlying atrial fibrillation. In addition,

the two patients who developed thrombosis were asymptomatic, and explantation was not performed.

Under fluoroscopic guidance, an anatomical landmark is required for TIVAP placement. However, the cardiac silhouette cannot accurately indicate the CAJ due to the intrapericardial portion of the SVC (1, 18, 19, 28). The carina is generally used as an anatomical landmark for fluoroscopic guidance because the CAJ is located two vertebral body units below the carina (20). The catheter length is indirectly measured from the venotomy site to the intended position with a guidewire when implanting a TIVAP under fluoroscopic guidance (15). Another method to determine the catheter length is to advance the catheter tip intravenously to the intended position under fluoroscopic guidance and then cut it at the proximal end (14, 21). This method allows for greater accuracy in determining the catheter length and placing the tip at the intended position. The single-incision technique used in this study involved advancing the catheter through the tract and attaching it to a reservoir. This technique allows the position, function, and abutment of the catheter tip against the cardiac wall to be checked before determining the catheter length. Therefore, this technique enhanced the safety and reproducibility of the procedure. The rates of the catheter tip in the SVC on fluoroscopic imaging and CT were 5.2% and 31.8%, respectively, although the intended position was in the RA. When positioning the catheter tip during the procedure, we did not consider an imaginary CAJ, which is two vertebral body units below the carina, used to retrospectively assess the catheter tip position on fluoroscopic imaging. Had this been considered during the procedure, the number of cases may have been lower. The higher incidence of the catheter tip in the SVC on CT than on fluoroscopy may be due to various factors influencing the position observed on CT. In female, the ipsilateral breast is immobilized during the procedure but not when CT is performed (23). During CT without immobilization, the position of the port chamber shifted, followed by movement of the catheter tip. Another factor affecting the tip position was that fluoroscopy was performed with the arm down, while CT was performed with the arm up. In addition, fluoroscopy was performed without breathing, whereas CT was performed with deep inspiration, resulting in different relative positions of the two images. Various factors can affect the catheter tip position as seen on the image and actual movement of the position after its initial placement, including the catheter type, access site, patient's body habitus and posture, angle of the brachiocephalic vein, respiration, arm elevation, head and chin positions, and high-flow infusion (5, 7, 12, 14, 17, 22, 23, 29-32). The catheter tip can move up and down by 2–3 cm with changes in posture from supine to erect and by 1–3 cm with arm movements. Moreover, overweight female have a significantly higher risk of catheter migration compared to normal-weight female and male. Therefore, verifying the catheter function by confirming blood return before cutting and placing the catheter tip at the intended position is a valuable technique. This method helps select a wider area without an abutment against the cardiac wall within a short period under fluoroscopic guidance compared to the previously reported method of placing the catheter tip at the exact position without checking the catheter function.

In the present study, the median fluoroscopic duration was short (0.3 min). This short duration was observed during catheter positioning and throughout the procedure. Previous studies have suggested that access sites are associated with complications, such as thrombo-

sis, dysfunction, and vein perforation (6, 22, 33). Additionally, left-sided access increases the risk of complications. This increased risk is also associated with tip placement in a high SVC; however, left-sided placement with the tip below the carina is satisfactory (13). In this study, one case of SVC thrombosis developed after placement via the left axillary vein access; however, the access site did not demonstrate a statistically significant difference in tip migration between the right and left axillary veins.

The present study has some limitations. First, data were collected retrospectively. Moreover, the interval between the procedure and the first CT scan was inconsistent among patients, as follow-up CT scans were obtained to evaluate disease progression, response to treatment, and lung metastases. The first CT scan was obtained at a median of 41 days after the procedure, and the longest interval was 182 days. This long interval may not accurately reflect mediastinal anatomy at the time of placement. Second, arrhythmias triggered by the catheter tip were not evaluated as catheter-related cardiac complications, although no cases of serious arrhythmias required TIVAP removal. Finally, the catheter used in this study was a 6.5-F catheter made of silicon. Further studies using catheters of different materials and diameters are required.

In conclusion, confirming the abutment of the catheter tip against the cardiac wall by checking blood return before determining the length and cutting of the catheter is a feasible technique. In addition, intentional positioning of the catheter tip in the RA without abutment appears to be a feasible and safe technique, with a low incidence of thrombosis and no incidence of catheter dysfunction or cardiac perforation.

Author Contributions

Conceptualization, S.T.; data curation, S.T.; formal analysis, S.M.G.; methodology, Y.W.J.; supervision, S.M.G.; validation, Y.W.J.; writing—original draft, P.H.; and writing—review & editing, P.H.

Conflicts of Interest

The authors have no potential conflicts of interest to disclose.

Funding

None

REFERENCES

1. Caers J, Fontaine C, Vinh-Hung V, De Mey J, Ponnet G, Oost C, et al. Catheter tip position as a risk factor for thrombosis associated with the use of subcutaneous infusion ports. *Support Care Cancer* 2005;13:325-331
2. Petersen J, Delaney JH, Brakstad MT, Rowbotham RK, Bagley CM Jr. Silicone venous access devices positioned with their tips high in the superior vena cava are more likely to malfunction. *Am J Surg* 1999;178:38-41
3. Xiang DZ, Verbeken EK, Van Lommel AT, Stas M, De Wever I. Composition and formation of the sleeve enveloping a central venous catheter. *J Vasc Surg* 1998;28:260-271
4. Fletcher SJ, Bodenham AR. Safe placement of central venous catheters: where should the tip of the catheter lie? *Br J Anaesth* 2000;85:188-191
5. Vesely TM. Central venous catheter tip position: a continuing controversy. *J Vasc Interv Radiol* 2003;14:527-534
6. Tesselaar ME, Ouwerkerk J, Nooy MA, Rosendaal FR, Osanto S. Risk factors for catheter-related thrombosis in cancer patients. *Eur J Cancer* 2004;40:2253-2259
7. Schutz JC, Patel AA, Clark TW, Solomon JA, Freiman DB, Tuite CM, et al. Relationship between chest port catheter tip position and port malfunction after interventional radiologic placement. *J Vasc Interv Radiol* 2004;15:581-587

8. Pittiruti M, Hamilton H, Biffi R, MacFie J, Pertkiewicz M. ESPEN guidelines on parenteral nutrition: central venous catheters (access, care, diagnosis and therapy of complications). *Clin Nutr* 2009;28:365-377
9. Bodenham Chair A, Babu S, Bennett J, Binks R, Fee P, Fox B, et al. Association of anaesthetists of Great Britain and Ireland: safe vascular access 2016. *Anaesthesia* 2016;71:573-585
10. Hade AD, Beckmann LA, Basappa BK. A checklist to improve the quality of central venous catheter tip positioning. *Anaesthesia* 2019;74:896-903
11. Dariushnia SR, Wallace MJ, Siddiqi NH, Towbin RB, Wojak JC, Kundu S, et al. Quality improvement guidelines for central venous access. *J Vasc Interv Radiol* 2010;21:976-981
12. Kowalski CM, Kaufman JA, Rivitz SM, Geller SC, Waltman AC. Migration of central venous catheters: implications for initial catheter tip positioning. *J Vasc Interv Radiol* 1997;8:443-447
13. Stonelake PA, Bodenham AR. The carina as a radiological landmark for central venous catheter tip position. *Br J Anaesth* 2006;96:335-340
14. Wallace JA, Afonso E, Yu H, Birchard K, Isaacson A. Factors that predict increased catheter tip movement in left internal jugular vein implantable venous access ports upon standing. *J Vasc Access* 2014;16:223-226
15. Samman M, Mujo T, Harris JJ, Coldwell DM, Hite-Potts M, Vyleta M. Subcutaneous port malfunction: a retrospective comparison between internal jugular and subclavian vein access. *J Assoc Vasc Access* 2015;20:229-234
16. Schummer W, Herrmann S, Schummer C, Funke F, Steenbeck J, Fuchs J, et al. Intra-atrial ECG is not a reliable method for positioning left internal jugular vein catheters. *Br J Anaesth* 2003;91:481-486
17. Nazarian GK, Bjarnason H, Dietz CA Jr, Bernadas CA, Hunter DW. Changes in tunneled catheter tip position when a patient is upright. *J Vasc Interv Radiol* 1997;8:437-441
18. Aslamy Z, Dewald CL, Heffner JE. MRI of central venous anatomy: implications for central venous catheter insertion. *Chest* 1998;114:820-826
19. Schuster M, Nave H, Piepenbrock S, Pabst R, Panning B. The carina as a landmark in central venous catheter placement. *Br J Anaesth* 2000;85:192-194
20. Baskin KM, Jimenez RM, Cahill AM, Jawad AF, Towbin RB. Cavoatrial junction and central venous anatomy: implications for central venous access tip position. *J Vasc Interv Radiol* 2008;19:359-365
21. Seo TS, Song MG, Kang EY, Lee CH, Yong HS, Doo K. A single-incision technique for placement of implantable venous access ports via the axillary vein. *J Vasc Interv Radiol* 2014;25:1439-1446
22. Pittiruti M, Lamperti M. Late cardiac tamponade in adults secondary to tip position in the right atrium: an urban legend? A systematic review of the literature. *J Cardiothorac Vasc Anesth* 2015;29:491-495
23. Song MG, Seo TS, Kim YH, Cho SB, Jung E, Chung HH, et al. Effectiveness of breast fixation to reduce migration of the tip of a totally implantable venous access port in women. *J Vasc Access* 2016;17:348-352
24. Chabanier A, Dany F, Brutus P, Vergnoux H. Iatrogenic cardiac tamponade after central venous catheter. *Clin Cardiol* 1988;11:91-99
25. Aldridge HE, Jay AW. Central venous catheters and heart perforation. *CMAJ* 1986;135:1082-1084
26. Korones DN, Buzzard CJ, Asselin BL, Harris JP. Right atrial thrombi in children with cancer and indwelling catheters. *J Pediatr* 1996;128:841-846
27. Bivins MH, Callahan MJ. Position-dependent ventricular tachycardia related to a peripherally inserted central catheter. *Mayo Clin Proc* 2000;75:414-416
28. Lewis CA, Allen TE, Burke DR, Cardella JF, Citron SJ, Cole PE, et al. Quality improvement guidelines for central venous access. *J Vasc Interv Radiol* 2003;14(9 Pt 2):S231-S235
29. Kalso E, Rosenberg PH, Vuorialho M, Pietilä K. How much do arm movements displace cubital central venous catheters? *Acta Anaesthesiol Scand* 1982;26:354-356
30. Wyschkon S, Löschmann JP, Scheurig-Münkler C, Nagel S, Hamm B, Elgeti T. Apparent migration of implantable port devices: normal variations in consideration of BMI. *J Vasc Access* 2016;17:155-161
31. Behrendt FF, Wingen M, Katoh M, Guenther RW, Buecker A. Evaluation of catheter loops in central venous port systems. *Invest Radiol* 2006;41:777-780
32. Caruso LJ, Gravenstein N, Layon AJ, Peters K, Gabrielli A. A better landmark for positioning a central venous catheter. *J Clin Monit Comput* 2002;17:331-334
33. Puel V, Caudry M, Le Métayer P, Baste JC, Midy D, Marsault C, et al. Superior vena cava thrombosis related to catheter malposition in cancer chemotherapy given through implanted ports. *Cancer* 1993;72:2248-2252

완전이식형 정맥 접근 포트 삽입 시 카테터 팁을 심벽에 닿지 않고 우심방 내 위치시키는 방법의 타당성과 안전성

박혜진 · 서태석* · 송명규 · 양우진

목적 완전이식형 정맥 접근 포트 이식 시 카테터 팁을 심벽에 닿지 않으면서 우심방 내 위치시키는 기술의 타당성과 안전성에 대하여 평가하였다.

대상과 방법 2016년 1월부터 12월까지 완전이식형 정맥 접근 포트를 삽입하고 추적관찰 CT를 시행한 환자 총 330명이 연구에 포함되었다. 정맥 접근 포트는 절개선에서 직접 액와정맥으로 접근하는 단일절개법을 적용하여 이식하였다. 카테터 팁을 자르기 전 정맥 환류를 확인하여 우심방 내벽에 닿지 않도록 위치를 확인하였다. 카테터의 길이 및 연관된 합병증은 의료영상 그리고 의료기록을 통해 후향적으로 평가하였다.

결과 모든 환자에서 카테터 팁은 심벽과의 닿음과 기능장애 없이 성공적으로 위치 조정되었다. 카테터 팁의 위치는 cavoatrial junction 기준으로 fluoroscopy에서 15.3 mm, 첫 번째 CT에서 6 mm 원위부에 있었다(중앙값). 카테터 팁은 fluoroscopy 대비 첫 번째 CT에서 10.4 mm 머리 방향으로 이동하였다(중앙값). 추적 CT에서 우심방과 상대정맥에서 각각 1건씩의 혈전증이 발견되었다.

결론 카테터 팁을 심벽에 닿지 않으면서 우심방 내 의도적으로 위치시키는 것은 혈전증 발생률이 낮고 기능장애가 없는 기술적으로 가능하고 안전한 방법이다.

고려대학교 의과대학 고려대학교 구로병원 영상의학과