



Primary tooth aspiration during conscious sedation with N₂O: foreign body removal with rigid bronchoscopy

Yeeun Jo, Kyungmin Rim, Dohyun Kwon, Jaemyung Ahn, Jun-Young Paeng

Department of Oral & Maxillofacial Surgery, Samsung Medical Center, Seoul, Republic of Korea

A 7-year-old girl visited the Samsung Medical Center emergency room for primary tooth aspiration during primary tooth extraction under conscious sedation with N₂O. The patient showed no signs of respiratory complications. Chest radiography and CT revealed a tooth in the right bronchi. Foreign body removal using rigid bronchoscopy was performed on the day of aspiration. With close monitoring of the airway in the pediatric ICU, extubation was performed the next day, and the patient was discharged the same day. The primary objective of this case report was to highlight the potential risk of aspiration associated with the use of N₂O gas for conscious sedation.

Keywords: Aspiration; Conscious Sedation; Foreign Bodies; Removal.



This is an Open Access article distributed under the terms of the Creative Commons Attribution Non-Commercial License (<http://creativecommons.org/licenses/by-nc/4.0/>) which permits unrestricted non-commercial use, distribution, and reproduction in any medium, provided the original work is properly cited.



INTRODUCTION

An effective approach for managing anxiety and stress during dental procedures involves the intravenous administration of sedatives, such as midazolam or propofol, or inhalation of gases, such as N₂O or sevoflurane [1]. Among these, nitrous oxide gas is frequently employed because of its perceived safety profile and minimal associated risks [2]. In the Republic of Korea, the prevalence of conscious sedation in dental clinics has increased, and 87% of sedation procedures were performed with N₂O between January 2007 and September 2019 [3]. In Korean pediatric dental practice, a typical mixture consists of 50% N₂O and 50% O₂, with the maximum N₂O concentration not exceeding 50%. This gas mixture poses a minimal inhalation risk during dental procedures when maintained within a concentration range of 20–65% [4].

However, an experimental investigation revealed that nitrous oxide diminishes the gag reflex at a concentration of 50% N₂O [5]. It is important to note that its use may increase the risk of aspiration, as the protective mechanisms of swallowing and gag reflex are attenuated by its sedative effects [6]. Consequently, although N₂O gas is considered safe from aspiration hazards, clinicians should be vigilant about the heightened risk of foreign body aspiration during conscious sedation with N₂O.

The spectrum of symptoms associated with foreign body aspiration ranges from mild manifestations, such as coughing, to severe complications, including airway obstruction leading to hypoxemia or pulmonary hemorrhage, which are associated with high mortality rates.

Bronchoscopy is an established procedure for removing foreign bodies. Rigid bronchoscopy is warranted in patients presenting with compelling indications, including definitive evidence indicating the presence of a foreign

Received: April 16, 2024 • Revised: May 21, 2024 • Accepted: May 23, 2024

Corresponding Author: Jun-Young Paeng, Department of Oral & Maxillofacial Surgery, Samsung Medical Center, 81, Irwon-ro, Gangnam-gu, Seoul 06351, Republic of Korea

E-mail: jypaeng@gmail.com

Copyright© 2024 Journal of Dental Anesthesia and Pain Medicine

body and concurrent respiratory distress, such as asphyxiation, identification of a radiopaque foreign body on chest radiography, diminished breath sounds, and obstructive emphysema [7].

This case report describes an incident of foreign body aspiration during the extraction of a deciduous tooth under conscious sedation with nitrous oxide, followed by removal via rigid bronchoscopy.

CASE REPORT

A 7-year-old girl without any underlying disease presented to the Emergency Medicine Department at Samsung Medical Center with aspiration of a deciduous tooth. Aspiration occurred during the extraction of tooth #54 under sedation with a mixture of 50% N₂O and 50% O₂ gas at a private local dental clinic. At such concentrations, anxiety was well-controlled and obeyed by the doctor without problems. However, the extracted tooth was inhaled immediately after falling into the oral cavity. Upon arrival at the emergency room, the patient exhibited no signs of respiratory distress, including

wheezing, stridor, altered respiratory muscle function, or cyanosis. Additionally, vital signs, such as SpO₂, respiratory rate, blood pressure, and heart rate, were all within normal limits. Owing to the absence of symptoms, further diagnostic examinations were warranted to differentiate between aspiration and ingestion. The

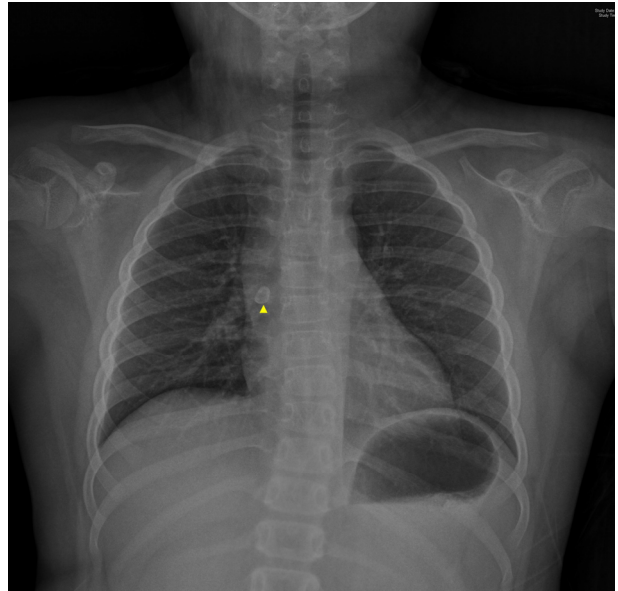


Fig. 1. Chest X-ray demonstrating the presence of the tooth lodged in the right bronchus. No effusion or structural abnormalities are observed. (Yellow triangle: aspirated tooth)

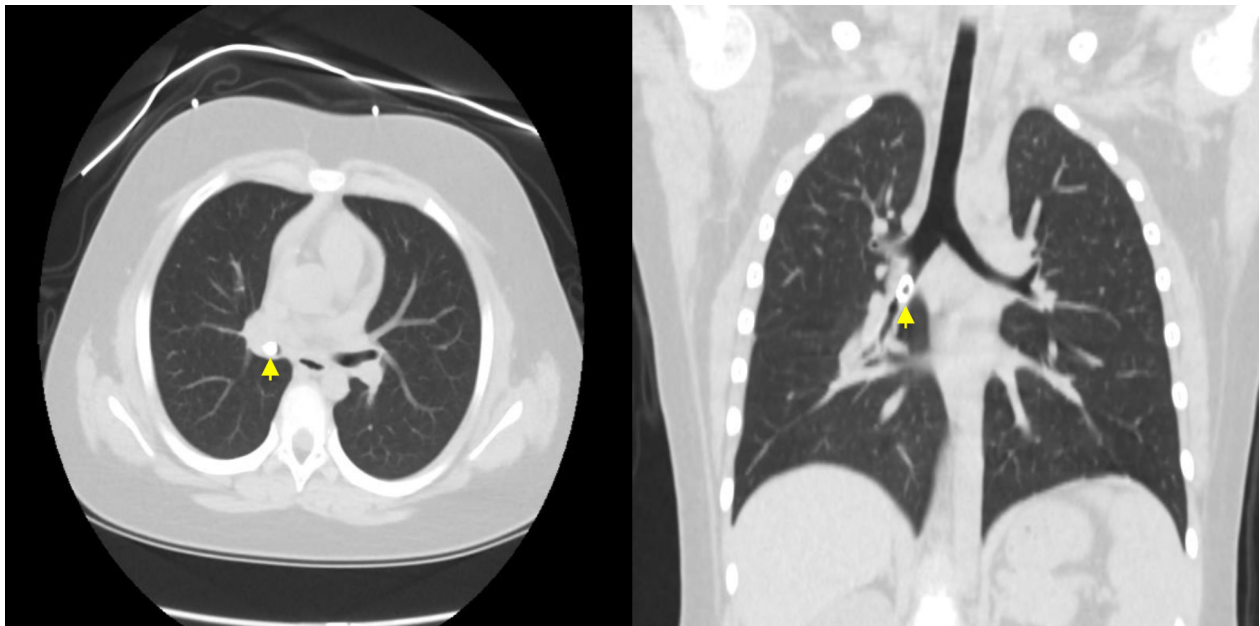


Fig. 2. Chest computed tomography (CT) scan revealed a 1 cm-sized tooth located in the right bronchus intermedium, with no evidence of atelectasis or pneumonitis. (Yellow triangle: aspirated tooth)

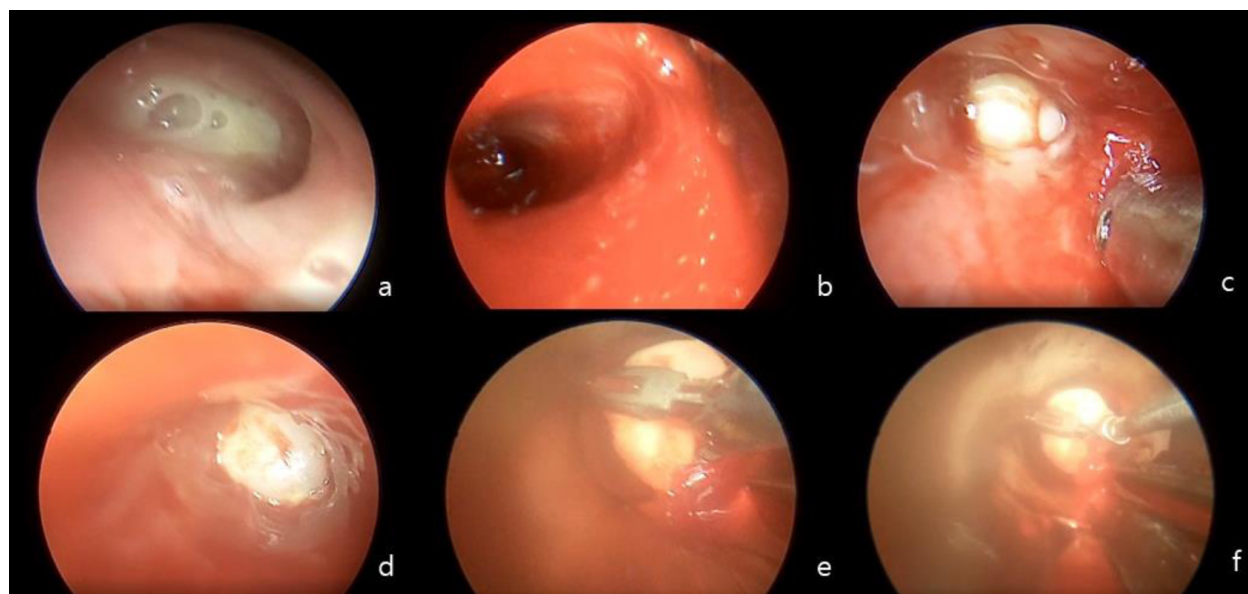


Fig. 3. (a) Obscured field of vision resulting from secretion within the bronchus. (b) Exploration following suction to clear the field. (c) Identification of the tooth. (d) Mild swelling observed around the tooth. (e) Tooth extraction performed using forceps. (f) The diameter of the bronchoscope was smaller than that of tooth #54. The otolaryngologist utilized forceps to grasp and extract the tooth via the bronchoscope itself.

attending emergency physician conducted a series of investigations, including chest and abdomen X-rays (Fig. 1), as well as a chest CT scan (Fig. 2), revealing the presence of the tooth lodged in the right main bronchus. The emergency physician promptly referred the patient to an otolaryngologist for removal of the foreign body through ventilating bronchoscopy. Additionally, an otolaryngologist recommended that the patient undergo extraction of the other mobile teeth to mitigate the risk of further aspiration during subsequent intubation or bronchoscopy procedures.

The subsequent procedural steps are delineated below:

1. The procedure was performed in the operating room under general anesthesia. General anesthesia was administered and orotracheal intubation was performed by the attending anesthesiologist. For induction, thiopental 200 mg, 8% Sevoflurane, and Rocuronium 25 mg were used, and continuous intravenous infusion of Remifentanyl and Propofol was used to maintain deep sedation.
2. The attending dentist conducted the extraction of mobile teeth #64, 74, and 84 from the oral cavity.
3. Prior to extubation, oxygenation was ensured.
4. Extubation was performed by an otolaryngologist

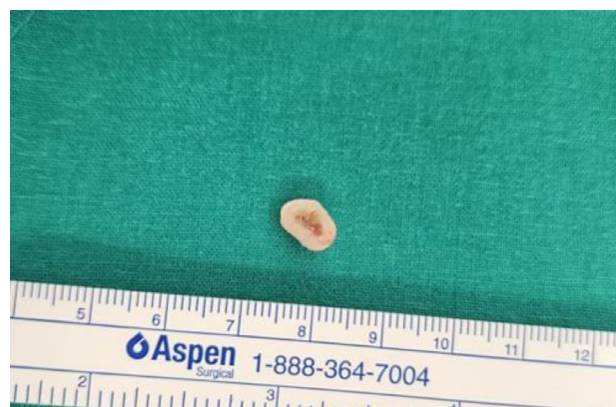

Fig. 4. Extracted tooth from the right bronchus of the patient.

concomitantly with the insertion of a bronchoscope (Richard Wolf, Lumina). Upon ensuring appropriate positioning of the scope within the trachea, the ventilation circuit was connected to the bronchoscope to facilitate ventilation during exploration. The otolaryngologist explored the trachea and bronchi, while the anesthesiologist closely monitored the vital signs. In instances of detected desaturation, exploration was promptly halted and re-oxygenation was conducted via the bronchoscope (Fig. 3).

5. The otolaryngologist successfully extracted the tooth from the right bronchus (Fig. 4).

6. Subsequently, the bronchoscope was removed, and the endotracheal tube was reintubated by an otolaryngologist. Delayed extubation was planned because of slight airway swelling observed during the procedure.

7. The patient was transferred to the pediatric ICU under sedation.

In pediatric ICU, postoperative care focuses on ensuring proper sedation and airway evaluation before extubation. Sedation was aimed at an Richmond agitation sedation scale (RASS) score of 0 to -1 and was maintained with continuous intravenous infusion of remifentanyl. To manage mild agitation immediately after the operation, serial intravenous injections of fentanyl (40 µg), ketamine (40 mg), and midazolam (4 mg) were administered at 20-minute and 40-minute intervals. The secretions exhibited high viscosity, but the quantity was moderate. Ambroxol (15 mg) was administered to reduce the sputum. At the time of extubation, the secretion quality was deemed appropriate and postoperative chest radiography did not reveal airway edema. After a thorough airway evaluation, extubation was performed 11 h after the operation. The patient was discharged on the same day of extubation, without any complications.

DISCUSSION

According to statistics, 87% of conscious sedation cases are performed using N₂O [3]. Several agents are typically used in dental clinics for sedation, including chloral hydrate, hydroxyzine, midazolam, propofol, dexmedetomidine, and sevoflurane.

Chloral hydrate: It is used for pediatric sedation. Although easy to administer, the prevalence of sedation with chloral hydrate has decreased. This is because its texture and taste irritate children, and its safety has not been proven [3].

- Hydroxyzine: Although its sedative effect is not as strong as that of other agents, it is usually administered in combination with another sedative agent because of

its synergistic effect.

Midazolam: Midazolam acts within 5 min and lasts approximately 30 min with an anterograde amnesia effect. It has several side effects such as respiratory depression, seizures, and agitation.

Propofol: The incidence of nausea, vomiting, derangement, and sleeping tendency after sedation was much lower than that with other agents. It also had a minimal analgesic effect.

- Dexmedetomidine: Dexmedetomidine has minimal influence on respiratory function and is safe for pediatric patients. It also has an analgesic effect [8].

- Sevoflurane: It acts and recovers rapidly, and the dose can be controlled based on the respiratory rate [9]. Its effect on the respiratory and cardiovascular systems was not significantly different from that of N₂O; however, patients felt more comfortable with sevoflurane than N₂O [10].

One of the purposes of sedation in dental clinics is to control the excessive gag reflex. In other words, it decreased the protective gag reflex. Therefore, it is difficult to conclude that all the agents mentioned above can alter N₂O levels in terms of aspiration risk. Therefore, it is clinically efficient to focus on the prevention and management of foreign body aspiration rather than altering sedative agents.

For foreign body aspiration that occurs in dental clinics, the following protocol can be suggested for dentists: prevention of aspiration, evaluation of the degree of emergency symptoms after aspiration, first-aid treatment for airway protection, and consultation for foreign body removal.

1. Prevention of aspiration

The basic strategy for preventing foreign body aspiration is the use of rubber dams. However, the risk escalates notably in scenarios where isolation from a rubber dam is not possible, such as during extraction [11]. In instances where rubber dam isolation is impracticable, placement of a 4 × 4 gauze distal to the treatment area may serve as an alternative approach [12].

2. Evaluation of the emergency degree of symptom after aspiration

Symptoms of foreign body aspiration can range from an asymptomatic state to coughing and, in severe cases, life-threatening cyanosis and respiratory arrest, depending on the location and site of the foreign body [13,14]. Foreign bodies lodged in the trachea may precipitate acute airway obstruction, whereas those in the lower airways can predispose the patient to pneumonia and secondary lung complications [15]. Dentists must vigilantly monitor the breathing and vital signs of the patient, including SpO₂ levels.

Foreign body aspiration is most pronounced among children under 3 years old, with 90% of cases being diagnosed within a month [13]. However, owing to the limited ability of children under three years old to effectively articulate symptoms and recognize signs of foreign body aspiration when the symptoms are subtle, some cases are not diagnosed until more than a month after aspiration. Furthermore, diagnostic delays may occur because of misinterpretation by physicians and parental neglect. An incorrect diagnosis is often rectified only after the persistence of chronic symptoms associated with airway foreign bodies, such as choking, fever, dyspnea, and stridor, despite antibiotic treatment [16-18]. It is crucial for physicians to recognize that while chest X-rays are commonly used in diagnosis, they are not infallible, with reported sensitivities and specificities of 82% and 74%, respectively [19], and not all aspirated objects are radiopaque [13]. Despite the various challenges hindering the prompt diagnosis of foreign body aspiration, the time elapsed between aspiration and diagnosis is pivotal.

Prolonged retention of a foreign body in the airway for > 4 weeks can lead to complications such as pneumonia, bronchiectasis, and bronchoesophageal fistula, and delayed diagnosis is correlated with a higher incidence of complications [19]. In conclusion, physicians must endeavor to obtain comprehensive patient histories and accurately assess symptoms to facilitate prompt and

precise diagnosis.

3. First aid treatment for airway protection

Foreign bodies in the oropharynx can be removed directly or using the Heimlich maneuver. But for the foreign body located in more complicated areas in which such management is unavailable, urgent bronchoscopy has been validated as an efficient method for removing foreign bodies from the airway, with several studies recommending its use as a first-line intervention [6,11, 20]. Thus, dentists should evaluate the respiration of the patient and protect the airway until the foreign body is expelled using a rigid bronchoscope.

Huh JY proposed a management protocol for foreign body aspiration during dental treatment, advocating initial measures, such as encouraging coughing and manual removal [21]. If expulsion fails, the dentist should select the next procedure depending on the signs of hypoxemia. In cases with signs of hypoxemia, techniques such as backblows and the Heimlich maneuver are recommended until a successful resolution is achieved. If these interventions prove ineffective and the patient becomes unresponsive, cardiopulmonary resuscitation is warranted. Although certain studies have advocated the use of the Heimlich maneuver as first aid for airway obstruction [14, 21], dentists should exercise caution when relying solely on this method because of its inherent limitations. The Heimlich maneuver is effective primarily for supraglottic foreign bodies, ineffective when obstruction occurs after exhalation, and may increase the risk of foreign body impaction in the subglottic region [19]. Such maneuvers can exacerbate the situation, as distal foreign bodies are more challenging to dislodge [22]. Consequently, dentists might need to explore alternative interventions after repeated attempts. Training paramedics in the use of a laryngoscope and Magill forceps is imperative because they allow for precise foreign body removal with a clear field of view, proving to be the most efficacious method [19]. Additionally, cricothyroidectomy and positive ventilation are also recommended [14].

In conclusion, if a patient exhibits stable vital signs

and symptoms that do not impede proper breathing, no intervention may be necessary. However, when respiratory distress and signs of asphyxia become pronounced, various interventions should be initiated, such as encouraging coughing, performing the Heimlich maneuver and back blows, and if warranted, implementing cricothyrotomy and intubation [6,14,19, 23].

4. Consultation for foreign body removal

If a foreign body is located inside the subglottis, which is difficult to reach, a bronchoscopy should be performed. The aforementioned guidelines suggest additional imaging and bronchoscopy only in the absence of hypoxia-related symptoms, such as tachypnea or cyanosis [21]. In cases of foreign body aspiration during dental procedures, the responsibilities of the dentist include immediate consultation with an emergency physician or otolaryngologist for the removal of the foreign body using rigid bronchoscopy, along with the provision of life support until transfer.

N₂O gas is a widely favored method for conscious sedation during dental procedures owing to its safety and efficacy. Nonetheless, the risk of foreign body inhalation is elevated under sedation, manifesting as symptoms ranging from mild coughing and choking to potentially life-threatening hypoxemia or respiratory arrest. In the event of foreign body aspiration in a dental clinic setting, it is imperative for dentists to evaluate the emergence of symptoms and protect the airway. If it is impossible to withdraw a foreign body from the airway with the direct method or Heimlich maneuver, rigid bronchoscopy remains the established standard for the removal of foreign bodies. In such cases, dentists should promptly refer the patient to a rigid bronchoscope and provide appropriate support until transfer.

Although this study has a limitation in that it does not suggest an alternative sedative agent with a lower aspiration risk than the traditional method, it provides information about elevated aspiration risk during conscious sedation and protocols for management after

foreign body aspiration. This finding is meaningful because the prevalence of conscious sedation is on the rise.

Ethical approval was granted by the Institutional Review Board (IRB) of the Samsung Medical Center (IRB number: SMC 2024-04-094-001). The patient provided informed consent for the publication of this article.

AUTHOR ORCIDs

Yeeun Jo: <https://orcid.org/0009-0005-9466-1348>
Kyungmin Rim: <https://orcid.org/0009-0006-1243-9821>
Jun-Young Paeng: <https://orcid.org/0000-0002-0104-9338>
Jaemyung Ahn: <https://orcid.org/0000-0002-1803-460X>
Dohyun Kwon: <https://orcid.org/0000-0001-8450-5513>

AUTHOR CONTRIBUTIONS

Yeeun Jo: Conceptualization, Writing - original draft, Writing - review & editing
Kyungmin Rim: Data curation
Jun-Young Paeng: Writing - review & editing
Jaemyung Ahn: Writing - review & editing
Dohyun Kwon: Writing - review & editing

DECLARATIONS OF INTEREST: The authors declare that they have no conflicts of interest.

REFERENCES

1. Kunta S, Arora RV, Jain R, Rawat P. The effect of anxiety and stress on acceptance of dental procedure before and after inhalation sedation in pediatric patients: an in vivo study. *Int J Clin Pediatr Dent* 2023; 16: 302-7.
2. Hallonsten AL, Koch G, Schröder U. Nitrous oxide-oxygen sedation in dental care. *Community Dent Oral Epidemiol* 1983; 11: 347-55.
3. Kim H, Ryoo SH, Karm MH, Seo KS, Kim HJ. Analysis of changes and trends in the use of sedatives in dental sedation using data from the National Health Insurance in Korea. *J Dent Anesth Pain Med* 2022; 22: 49-60.
4. Roberts GJ, Wignall BK. Efficacy of the laryngeal reflex

- during oxygen-nitrous oxide sedation (relative analgesia). *Br J Anaesth* 1982; 54: 1277-81.
5. Kaufman E, Weinstein P, Sommers EE, Soltero DJ. An experimental study of the control of the gag reflex with nitrous oxide. *Anesth Prog* 1988; 35: 155-7.
 6. Cossellu G, Farronato G, Carrassi A, Angiero F. Accidental aspiration of foreign bodies in dental practice: clinical management and prevention. *Gerodontology* 2015; 32: 229-33.
 7. Martinot A, Closset M, Marquette CH, Hue V, Deschildre A, Ramon P, et al. Indications for flexible versus rigid bronchoscopy in children with suspected foreign-body aspiration. *Am J Respir Crit Care Med* 1997; 155: 1676-9.
 8. Mohite V, Baliga S, Thosar N, Rathi N. Role of dexmedetomidine in pediatric dental sedation. *J Dent Anesth Pain Med* 2019; 19: 83-90.
 9. Kim K, Kim S. Application of sevoflurane inhalation sedation in dental treatment: a mini review. *J Dent Anesth Pain Med* 2021; 21: 321-7.
 10. Haraguchi N, Furusawa H, Takezaki R, Oi K. Inhalation sedation with sevoflurane: a comparative study with nitrous oxide. *J Oral Maxillofac Surg* 1995; 53: 24-6; discussion 6-7.
 11. R M, Prasad V, Menon PA. A case of accidental aspiration of an endodontic instrument by a child treated under conscious sedation. *Eur J Dent* 2013; 7: 225-8.
 12. Cameron SM, Whitlock WL, Tabor MS. Foreign body aspiration in dentistry: a review. *J Am Dent Assoc* 1996; 127: 1224-9.
 13. Ding G, Wu B, Vinturache A, Cai C, Lu M, Gu H. Tracheobronchial foreign body aspiration in children: a retrospective single-center cross-sectional study. *Medicine (Baltimore)* 2020; 99: e20480.
 14. Zur KB, Litman RS. Pediatric airway foreign body retrieval: surgical and anesthetic perspectives. *Paediatr Anaesth* 2009; 19: 109-17.
 15. Johnson K, Linnaus M, Notrica D. Airway foreign bodies in pediatric patients: anatomic location of foreign body affects complications and outcomes. *Pediatr Surg Int* 2017; 33: 59-64.
 16. Holan G, Ram D. Aspiration of an avulsed primary incisor: a case report. *Int J Paediatr Dent* 2000; 10: 150-2.
 17. Leith R, Fleming P, Redahan S, Doherty P. Aspiration of an avulsed primary incisor: a case report. *Dent Traumatol* 2008; 24: e24-6.
 18. Saquib Mallick M, Rauf Khan A, Al-Bassam A. Late presentation of tracheobronchial foreign body aspiration in children. *J Trop Pediatr* 2005; 51: 145-8.
 19. Inglis AF Jr, Wagner DV. Lower complication rates associated with bronchial foreign bodies over the last 20 years. *Ann Otol Rhinol Laryngol* 1992; 101: 61-6.
 20. Abusamaan M, Giannobile WV, Jhawar P, Gunaratnam NT. Swallowed and aspirated dental prostheses and instruments in clinical dental practice: a report of five cases and a proposed management algorithm. *J Am Dent Assoc* 2014; 145: 459-63.
 21. Huh JY. Foreign body aspirations in dental clinics: a narrative review. *J Dent Anesth Pain Med* 2022; 22: 161-74.
 22. Farrell PT. Rigid bronchoscopy for foreign body removal: anaesthesia and ventilation. *Paediatr Anaesth* 2004; 14: 84-9.
 23. Altuntas B, Aydın Y, Eroglu A. Foreign bodies in trachea: a 25-years of experience. *Eurasian J Med* 2016; 48: 119-23.