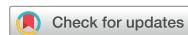

Research Article



Prevalence of apical periodontitis and quality of root canal treatment in an adult Kuwaiti sub-population: a cross-sectional study

Abdulrahman A. Alhailaa ,^{1,2} Saad A Al-Nazhan ,^{3,*} Mazen A Aldosimani ⁴

¹Department of Restorative Dentistry, College of Medicine and Dentistry, Riyadh Elm University, Riyadh, Saudi Arabia

²Farwania Dental Department, Ministry of Health, Kuwait City, Kuwait

³Department of Restorative Dentistry – Endodontics, College of Medicine and Dentistry, Riyadh Elm University, Riyadh, Saudi Arabia

⁴Department of Oral Medicine and Diagnostic Sciences, College of Dentistry, King Saud University, Riyadh, Saudi Arabia

OPEN ACCESS

Received: Jan 13, 2024

Revised: Jan 26, 2024

Accepted: Feb 13, 2024

Published online: Mar 22, 2024

Citation

Alhailaa AA, Al-Nazhan SA, Aldosimani MA. Prevalence of apical periodontitis and quality of root canal treatment in an adult Kuwaiti sub-population: a cross-sectional study. Restor Dent Endod 2024;49(2):e16.

*Correspondence to

Saad A Al-Nazhan, BDS, MSD

Department of Restorative Dentistry – Endodontics, College of Medicine and Dentistry, Riyadh Elm University, P.O. Box 84891, Riyadh 11545, Saudi Arabia. Email: saad.alnazhan@riyadh.edu.sa

Copyright © 2024. The Korean Academy of Conservative Dentistry

This is an Open Access article distributed under the terms of the Creative Commons Attribution Non-Commercial License (<https://creativecommons.org/licenses/by-nc/4.0/>) which permits unrestricted non-commercial use, distribution, and reproduction in any medium, provided the original work is properly cited.

Conflict of Interest

No potential conflict of interest relevant to this article was reported.

Author Contributions

Data curation: Al-Nazhan SA; Formal analysis: Al-Nazhan SA; Investigation: Al-Nazhan SA,

ABSTRACT

Objectives: This cross-sectional study evaluated the prevalence of apical periodontitis (AP) and the technical quality of root canal fillings in an adult Kuwaiti subpopulation using cone-beam computed tomography (CBCT) images.

Materials and Methods: Two experienced examiners analyzed 250 CBCT images obtained from Kuwaiti patients aged 15–65 years who attended government dental specialist clinics between January 2019 and September 2020. The assessment followed the radiographic scoring criteria proposed by De Moor for periapical status and the technical quality of root canal filling. Chi-square and Fisher's exact tests were used for statistical analysis, with significance level set at $p < 0.05$.

Results: Among the 2,762 examined teeth, 191 (6.91%) exhibited radiographic signs of AP, and 176 (6.37%) had undergone root canal filling. AP prevalence in root canal-treated teeth was 32.38%, with a significant difference between males and females. Most of the endodontically treated teeth exhibited adequate root canal filling (71.5%).

Conclusions: The study demonstrated a comparable prevalence of AP and satisfactory execution of root canal treatment compared to similar studies in different countries.




Keywords: Apical periodontitis; Cone-beam computed tomography; Endodontic outcome; Epidemiology; Root canal treatment

INTRODUCTION

Apical periodontitis (AP) is an inflammatory reaction of the periapical tissue, induced by the infiltration of bacteria and their toxins from the root canal system into the periradicular area [1,2]. It is typically asymptomatic and necessitates radiographic detection [3]. Epidemiological studies have identified AP as a prevalent condition across various populations. A recent systematic review and meta-analysis involving 11,114 studies, including 34,668 individuals and 639,357 teeth, indicated a prevalence of 52% at the individual level and 5% at the tooth level [4]. The frequencies of AP in root-filled and untreated teeth are 39% and 3%, respectively.

Alhailaa AA, Aldosimani MA; Methodology: Al-Nazhan SA; Project administration: Al-Nazhan SA; Supervision: Al-Nazhan SA; Validation: Al-Nazhan SA, Aldosimani MA; Visualization: Al-Nazhan SA, Alhailaa AA; Writing - original draft: Al-Nazhan SA; Writing - review & editing: Al-Nazhan SA.

ORCID iDs

Abdulrahman A. Alhailaa 
<https://orcid.org/0009-0009-8197-8468>
Saad A Al-Nazhan 
<https://orcid.org/0000-0002-5997-0330>
Mazen A Aldosimani 
<https://orcid.org/0000-0002-4105-2283>

Moreover, the rate is significantly higher in samples from dental care services and hospitals and in individuals with systemic diseases compared to healthy individuals [4]. Seppänen *et al.* [5] reported that AP accounts for infections in > 90% of the patients who require hospital treatment for a developing odontogenic maxillofacial infection, highlighting the public health risk posed by root canal infections and other persistent oral infections.

There are 2 primary treatment options for AP: extraction of the affected tooth and tooth-saving therapy, including root canal treatment (RCT). RCT aims to eliminate infected necrotic tissue from the root canal system and prevent re-infection by facilitating periapical tissue repair through the use of a biocompatible material. However, the success of RCT may be influenced by several individual, tooth-related, and treatment-related prognostic variables [6]. Most previous studies have suggested that achieving optimal-length root fillings positively impacts RCT outcomes [7,8].

The predominant contemporary method for assessing the periapical area and RCT in everyday clinical practice is conventional or digital periapical radiography [9,10]. However, this technique is limited to detecting periapical lesions due to factors such as bone characteristics, lesion location, morphologic variation, surrounding bone density, X-ray angulations, and radiographic contrast [9,11]. Recently, cone-beam computed tomography (CBCT) has emerged as an effective tool in endodontics, offering 3-dimensional (3D) reconstructions of anatomical structures and improved detection of small or occult periradicular lesions compared to conventional radiography [12].

While few studies have explored the periapical status of teeth and the quality of endodontic treatment in Kuwait, Zaatar *et al.* [13] assessed 846 endodontically treated teeth and reported the mandibular first molar as the most frequently treated tooth. However, the study did not assess the quality of RCT or the status of periapical tissue. Maslamani *et al.* [14,15] examined 4,841 teeth using conventional radiography and reported a 2.7% rate of root canal filling. The quality of root fillings was poor and significantly associated with a high prevalence of AP. The study concluded that inadequate coronal filling, rather than the quality of root filling, resulted in a higher prevalence of periapical lesions [15]. Based on the limitations of conventional periapical radiography, the present study assessed the prevalence of AP and the technical quality of root canal fillings in an adult Kuwaiti subpopulation using CBCT images.

MATERIALS AND METHODS

The study was approved by the Research and Innovation Center of Riyadh Elm University, Riyadh, Saudi Arabia, and the Institutional Review Board (registration number: FPGRP/2021/596/530/508). It was conducted in accordance with the World Medical Association Declaration of Helsinki.

Data collection

Background information, including age, sex, and self-reported systemic diseases, was obtained from patient documents. Patient age was recorded in years and categorized into groups with 15-year intervals.

Study samples

Between January 2019 and September 2020, 250 CBCT images were obtained from the archives of the radiology departments of various governmental specialized dental centers in Kuwait. These images were for patients who had undergone CBCT examinations for various diagnostic purposes; none of them had specifically undergone CBCT for this study. Patient identities remained confidential, with only sex and age information collected. Teeth were selected based on the predetermined criteria.

The images were obtained using a 3D X CBCT Creanex machine (SOREDEX Manufacturing Corp., Helsinki, Finland), with image capture parameters set at 90 kV and 5–10 mA, and an exposure time of 6.5 seconds. The voxel size was 0.1 mm, and the slice thickness was 1.0 mm. The inclusion criteria were Kuwaiti citizenship, age of 16–65 years, presence of > 10 mature permanent teeth, and good-quality CBCT images showing the periapical status of the teeth. The exclusion criteria were patients aged < 15 years, poor-quality CBCT images, retained roots, teeth with open apices, and impacted teeth or third molars.

CBCT evaluation

The CBCT datasets were converted into Digital Imaging and Communications in Medicine (DICOM) format and imported into 3D image reformatting software. The scans were analyzed using OnDemand3D software (Cybermed, Seoul, Korea) by 2 experienced examiners: an endodontist and an oral and maxillofacial radiologist. Axial, coronal, and sagittal sections were presented on a 32-inch monitor (hp LCD) with an aspect ratio of 16:10, a calculated pixel size of 0.282 mm, color resolution of 32-bit, luminance of 250 Cd/m², and a contrast ratio (static) of 1,000:1. Images were read in a dark room, with adjustments made for magnification and contrast to ensure optimal visualization and thorough examination.

Data reliability was previously established and assessed through interexaminer calibration, based on the anatomic diagnosis of the CBCT images. Each CBCT image was evaluated for the total number of teeth present, the number of non-root-filled teeth with periapical lesions, and the number of root-filled teeth with or without periapical lesions. Interexaminer agreement between the endodontist and oral and maxillofacial radiologist was determined based on Cohen's kappa for AP status, achieving a kappa value of 0.8, indicating very good agreement across teeth scores [16].

Evaluation criteria

This study utilized the radiographic scoring criteria for root canal filling quality and periapical status proposed by De Moor *et al.* [17].

Root canal filling quality

The quality of root canal filling was classified as adequate if the filling was 0–2 mm short of the radiographic apex, and as inadequate if it was > 2 mm short of the radiographic apex, or limited to the pulp chamber as a pulpotomy.

Periapical status

The periapical status of each tooth was evaluated based on the following criteria: healthy periodontal ligament (intact periodontal ligament devoid of any signs of periapical pathosis), and AP (either widening of the periodontal ligament [the apical part of the periodontal ligament not exceeding twice the width of the lateral periodontal ligament space]) or the presence of periapical radiolucency (radiolucency associated with the apical part of the

root exceeding at least twice the width of the lateral part of the periodontal ligament). Each tooth root was individually assessed by obtaining transverse cross-sectional images through the mesiodistal thickness and parasagittal images parallel to the long axis of the root (buccolingual). The thinnest possible CBCT slice thickness was used for assessment.

Statistical analysis

Data were analyzed using the Statistical Package for Social Sciences (SPSS version 25, IBM Corp., Armonk, NY, USA). Frequency distributions and percentages were calculated for the categorical variables. The χ^2 , Fisher's exact, and sample proportion tests were applied to the data. The chi-square test was used to determine the relationships of sex with the quality of RCT and the AP status. A p -value < 0.05 was considered significant.

RESULTS

In total, 2,762 teeth (male: 2498; female: 264) were assessed in 106 patients, yielding an AP prevalence of 6.91%. Among these, 176 teeth had undergone RCT, with an AP prevalence of 32.38%. Only 21 out of 93 well-treated teeth had AP. The number of root canal-treated teeth was significantly higher in males than females (**Table 1**).

Age

The comparison of AP among age groups showed statistically significant differences ($p < 0.001$), being more common in the age groups of 36–45 and > 55 years in both males and females.

Maxillary teeth

The total number of RCT maxillary teeth with AP was significantly higher in males than in females (**Table 2**). AP was detected in 10 of the 36 maxillary premolars treated with RCT in males, compared to 2 out of 3 in females. Similarly, 14 of the 30 maxillary molars with RCT in males had AP, while none were affected in females.

Mandibular teeth

There were 17 RCT mandibular teeth with AP in males and 2 in females. While there were no significant differences in mandibular premolars, with 4 teeth affected in males and 1 in females, there was a significantly greater number of mandibular molars with AP in males than in females (**Table 2**).

RCT quality

Among the 176 treated teeth, 130 were evaluated for RCT quality, excluding 46 teeth due to poor image quality in the radicular region. Adequate root filling was observed in 71.5% of the cases, compared to 22.3% with inadequate and 0.6% with extruded fillings (**Table 3**). Among

Table 1. Distribution of assessed teeth, root canal treated teeth and teeth with apical periodontitis (AP) by sex

Sex	No. of assessed teeth	Teeth with AP	No. of RCT Teeth	RCT Teeth with AP
Male	2,498	172 (6.88)	160 (6.48)	51 (31.87)
Female	264	19 (7.19)	16 (5.30)	6 (37.50)
Total	2,762	191 (6.91)	176 (6.37)	57 (32.38)
p value	< 0.001	< 0.001	< 0.001	< 0.001

Values are presented as number (%).
RCT, root canal treatment.

Table 2. Frequency of apical periodontitis (AP) for teeth with root canal treatment (RCT) according to tooth type and sex

Tooth type	Teeth with RCT						Prop. test p value*
	Male			Female			
	Total No. of teeth	With AP	%	Total No. of teeth	With AP	%	
Maxillary							
Maxillary incisors	33	9	27.27	2	2	100	0.065
Maxillary canines	10	1	10	2	0	0.00	-
Maxillary premolars	36	10	27.78	3	2	66.67	0.039
Maxillary molars	30	14	46.67	2	0	0.00	-
Total	109	34	31.20	9	4	44.45	< 0.001
Mandibular							
Mandibular incisors	0	0	0	0	0	0	-
Mandibular canines	2	1	50	0	0	0	-
Mandibular premolars	10	4	40	6	1	16.67	0.375
Mandibular molars	39	12	30.77	1	1	100	0.003
Total	51	17	33.33	7	2	28.57	0.001
Grand total	160	51	31.88	16	6	37.50	< 0.001

*The p value for comparing sex with AP and with RCT teeth for tooth type and overall.

Table 3. Quality of root canal treatment (RCT) among males and females according to tooth type (n = 130)*

Tooth type	Sex	Adequate	Inadequate (< 2 mm; short)	Quality of RCT		Total	p value for RCT quality
				Extruded	RCT in pulp chamber		
Maxillary							
Maxillary incisors	Male	18 (75)	3 (12.5)	3 (12.5)	0	24	< 0.001
	Female	2 (100)	0	0	0	2	-
	p value	< 0.001	-	-	-	< 0.001	-
Maxillary canines	Male	7 (87.5)	0	1 (12.5)	0	8	0.070
	Female	1 (100)	0	0	0	1	-
	p value	0.07	-	-	-	0.039	-
Maxillary premolars	Male	22 (71)	7 (23)	2 (6)	0	31	< 0.001
	Female	2 (100)	0	0	0	2	-
	p value	< 0.001	-	-	-	< 0.001	-
Maxillary molars	Male	16 (66.7)	7 (29.2)	1 (4.2)	0	24	0.001
	Female	1 (50)	1 (50)	0	0	2	1.000
	p value	< 0.001	0.001	-	-	< 0.001	-
Total	Male	63 (72.4)	17 (19.5)	7 (8)	0	87	< 0.001
	Female	6 (85.7)	1 (14.3)	0	0	7	0.289
	p value	< 0.001	0.001	-	-	< 0.001	-
Mandibular							
Mandibular incisors	Male	0	0	0	0	0	-
	Female	0	0	0	0	0	-
	p value	-	-	-	-	-	-
Mandibular canines	Male	0	1 (100)	0	0	1	-
	Female	0	0	0	0	0	-
	p value	-	-	-	-	-	-
Mandibular premolars	Male	3 (60)	1 (20)	1 (20)	0	5	0.449
	Female	0	0	0	0	0	-
	p value	-	-	-	-	-	-
Mandibular molars	Male	20 (69)	9 (31)	0	0	29	0.063
	Female	1 (100)	0	0	0	1	-
	p value	< 0.001	-	-	-	< 0.001	-
Total	Male	23 (65.7)	11 (31.4)	1 (3)	0	35	< 0.001
	Female	1 (100)	0	0	0	1	-
	p value	< 0.001	-	-	-	< 0.001	-
Overall total	Male	86 (70.5)	28 (23)	8 (7)	0	122	< 0.001
	Female	7 (87.5)	1 (12.5)	0	0	8	0.180
	p value	< 0.001	< 0.001	-	-	< 0.001	-

Values are presented as numbers (%).

*Forty-six teeth were excluded due to poor image of root canal filling in the radicular region.

males, 86 (70.5%) RCTs demonstrated adequate fillings, while a statistically significant difference was noted compared to females. Among female patients, there were 7 (87.50%) cases of adequate fillings and 1 (12.50%) case of inadequate filling. Moreover, the overall RCT quality between males and females differed significantly for molars.

DISCUSSION

This cross-sectional study assessed AP prevalence and the technical quality of root canal fillings in an adult Kuwaiti subpopulation using CBCT images. We utilized the De Moor *et al.* [19] criteria for periapical radiolucency, a widely recognized and reliable technique for evaluating periapical diseases, as evidenced by its successful use in previous studies [10,18,19]. For simplicity, all CBCT images depicting periapical radiolucencies associated with the apical part of the root were considered indicative of AP. This approach aimed to minimize false negatives and improve observer reliability compared to conventional and panoramic radiographs [20].

The high interexaminer agreement in this study was attributed to the previous calibration by an expert radiologist for CBCT interpretation and the strict criteria applied for image analysis. High interobserver agreements have also previously been reported in studies that have used similar techniques [10,18,21].

This cross-sectional study included 2,762 teeth, constituting a representative sample of the adult Kuwaiti population. A greater number of males than females were included, demonstrating a significant difference in the number of assessed teeth between the sexes. This is in contrast to previous studies, which included more female participants, possibly reflecting sex-related disparities in seeking dental care [18,22,23].

Given the lack of previous studies on AP prevalence and RCT quality in the Kuwaiti population, our findings were compared to those from neighboring countries. It was observed that 6.37% of the teeth had undergone RCT, slightly exceeding figures reported among Saudi populations but falling within the broader range of comparable studies (2.0%–22.8%) [10,21,24,25].

Previous epidemiological studies have reported a higher prevalence of AP in endodontically treated teeth. In the present study, 32.38% of the root-filled teeth exhibited AP, a prevalence within the previously reported range (16.8%–64.5%) [10,22,23,26]. Studies of Belarusian (12%), Greek (13.6%), and Palestinian (15.1%) populations have reported a lower overall prevalence of AP than our study [19,25,27]. This disparity could be attributable to the smaller sample size and male predominance of our study. In addition, we identified more filled root canals and cases of AP in maxillary than in mandibular teeth, in agreement with previous studies [18,25,27].

We identified a significant association between AP and root canal-filled maxillary and mandibular molars, followed by premolars. This reflects the intricate canal anatomy of these teeth and elucidates the challenges in achieving successful RCT. However, the presence of AP in a tooth that has undergone RCT does not always signify treatment failure; it may indicate the healing process of the apical lesion [28]. Consequently, caution is warranted when relying solely on radiographs to determine the success or failure of endodontic therapy,

as the diagnostic utility of this approach is limited without additional clinical information. Conversely, the prevalence of AP may be underestimated, as radiographic changes are often not evident when apical lesions involve up to a 30% loss of the mineral component of bone. In essence, changes in cortical bone are necessary for a visible radiographic change to occur. It is important to note that the outcomes of our study could have been influenced by the dynamic nature of periapical lesions, whether they were evolving or healing [25]. The actual progression or regression of periapical lesions cannot be definitively determined. However, Petersson *et al.* [29] reported that, over a 10-year period, the number of RCT teeth with healed periapical lesions was comparable to the number of teeth that developed lesions during the same period.

The Ministry of Health National Oral and Dental Health Program in Kuwait categorizes individuals enrolled in the program based on their ages. The age group of 6–16 years is covered by school programs for oral and dental health, and was not included in the current study [30]. The majority of the evaluated patients in our study were in middle-aged, specifically in the age groups of 36–45 years and 46–55 years, in agreement with previous studies [23,26]. By contrast, Al-Nazhan *et al.* [10] reported that the majority of their study participants were young patients aged 16–25 years. This disparity could be attributable to differences in the total number of samples assessed, with a lower representation of young subjects in our study.

RCT success depends on 3 fundamental principles: mechanical instrumentation, disinfection, and complete filling of the prepared root canals with a biocompatible material [31]. Of these, only the latter can be assessed through radiographic evaluation [32]. We found a lower prevalence of poor root canal filling compared to previous studies [17,18,21,25]. This may be attributable to the data being derived from specialized dental centers, where consultants and specialists in endodontics performed the endodontic treatments.

Mukhaimer *et al.* [25] evaluated the technical quality of RCTs in the Palestinian population and found that 25.5% of the root fillings were of adequate length, while 7.3% of the RCT teeth were associated with AP. A higher incidence of AP was associated with inadequate root canal fillings (> 2 mm away from the radiographic apex). Inadequate root canal fillings are associated with an increased risk for AP due to infected pulp remnants in the apical portion of the root canal. Sjögren *et al.* [33] reported that, compared to root canal fillings restricted to the pulp chamber or extruding from the radiographic apex, adequate fillings (\leq 2 mm from the radiographic apex) are associated with a reduced incidence of AP and a higher success rate. Moreover, fillings extruding beyond the radiographic apex are correlated with an increased incidence of apical pathology and a poorer prognosis [34]. This may be because root canal overfilling can induce tissue damage and inflammation due to the extrusion of infected debris into the apical area. In addition, root canal filling materials may trigger a foreign body reaction, contributing to the development of apical lesions, even in the absence of bacterial involvement [35].

In the current study, the quality of RCT exhibited significant differences between mandibular and maxillary teeth in males. Maxillary teeth were significantly better than mandibular. However, no significant relationship was observed between the RCT quality of mandibular and maxillary teeth of females. Sjögren *et al.* [33] reported that the technical quality of endodontic therapy is a crucial factor in healing and preventing apical pathosis, and it is generally inadequate in failed cases.

A critical parameter associated with endodontic treatment failure is the coronal seal quality [36,37]. A few studies have suggested that the technical quality of the coronal restoration may be even more significant for periapical health than the root canal filling quality [38]. Inadequate root filling and coronal restorations have been associated with an increased risk for AP [39]. Our findings are consistent with those of previous studies, highlighting a significant relationship between the technical quality of RCT and apical health [17,18,21,39].

Generally, we observed slightly higher RCT quality compared to previous studies, where a greater number of RCT teeth developed AP [10,15]. This improvement could be attributable to the use of high-resolution CBCT images, allowing a more comprehensive assessment of factors that could have been obscured in 2-dimensional radiographic images, such as panoramic and periapical radiographs.

The outcome of RCT may have been influenced by the clinical experience, practices, and skills of the endodontists providing care at government dental centers. In addition, the CBCT images analyzed in our study did not represent a statistically significant sample of the Kuwaiti adult population because of the small sample size and a significant data imbalance between males and females. Nevertheless, the results offer insights into the quality of endodontic treatment and AP prevalence among patients seeking dental care at specialist dental care facilities.

In Kuwait, the government operates a primarily publicly financed healthcare system, where dentists in district dental clinics provide basic dental treatment, and patients are referred to specialty centers for advanced treatment, including endodontics [13]. The economic impact of RCT is substantial, and the health benefits derived from this therapy should be acknowledged and enhanced using advanced diagnostic methods, including CBCT. A greater knowledge of the prognosis of RCT in various clinical settings in Kuwait could help dentists make optimal treatment decisions, thus avoiding unfavorable health, social, and economic consequences. Furthermore, a comprehensive understanding of the impact of endodontic treatment on AP may lead to improvements in the quality of routine RCTs.

This was the first epidemiological study of the Kuwaiti population that utilized CBCT images to evaluate AP and RCT quality. Previous data similar to our study relied on conventional radiographs of patients seeking dental care at various dental centers in Kuwait, with a majority of cases being non-Kuwaitis [13-15]. However, caution must be exercised in generalizing our findings because CBCT images did not represent a random sample of Kuwaiti patients. The absence of clinical data was a major limitation of this study, but its impact on the results is likely to be modest, as previous reports have indicated no significant differences in RCT outcomes when clinical and radiographic findings were compared to radiographic findings alone [40]. Retrieving systemic health information from patient files and assessing its influence on RCT was beyond the scope of this investigation. Our results emphasize the need for early dental examination, diagnosis, and monitoring of lesions, particularly in non-endodontically treated teeth, along with strict post-treatment endodontic evaluation protocols to enhance the overall quality of care.

CONCLUSIONS

We noted a prevalence of AP comparable to similar studies from other countries and a satisfactory quality of the RCTs performed.

REFERENCES

1. Kakehashi S, Stanley HR, Fitzgerald RJ. The effects of surgical exposures of dental pulps in germ-free and conventional laboratory rats. *Oral Surg Oral Med Oral Pathol* 1965;20:340-349. [PUBMED](#) | [CROSSREF](#)
2. Sundqvist G, Figdor D, Persson S, Sjögren U. Microbiologic analysis of teeth with failed endodontic treatment and the outcome of conservative re-treatment. *Oral Surg Oral Med Oral Pathol Oral Radiol Endod* 1998;85:86-93. [PUBMED](#) | [CROSSREF](#)
3. Abbott PV. Classification, diagnosis and clinical manifestations of apical periodontitis. *Endod Topics* 2004;8:36-54. [CROSSREF](#)
4. Tibúrcio-Machado CS, Michelon C, Zanatta FB, Gomes MS, Marin JA, Bier CA. The global prevalence of apical periodontitis: a systematic review and meta-analysis. *Int Endod J* 2021;54:712-735. [PUBMED](#) | [CROSSREF](#)
5. Seppänen L, Lemberg KK, Lauhio A, Lindqvist C, Rautemaa R. Is dental treatment of an infected tooth a risk factor for locally invasive spread of infection? *J Oral Maxillofac Surg* 2011;69:986-993. [PUBMED](#) | [CROSSREF](#)
6. Ørstavik D, Qvist V, Stoltze K. A multivariate analysis of the outcome of endodontic treatment. *Eur J Oral Sci* 2004;112:224-230. [PUBMED](#) | [CROSSREF](#)
7. Kojima K, Inamoto K, Nagamatsu K, Hara A, Nakata K, Morita I, et al. Success rate of endodontic treatment of teeth with vital and nonvital pulps. A meta-analysis. *Oral Surg Oral Med Oral Pathol Oral Radiol Endod* 2004;97:95-99. [PUBMED](#) | [CROSSREF](#)
8. Ng YL, Mann V, Rahbaran S, Lewsey J, Gulabivala K. Outcome of primary root canal treatment: systematic review of the literature -- part 2. influence of clinical factors. *Int Endod J* 2008;41:6-31. [PUBMED](#) | [CROSSREF](#)
9. Estrela C, Bueno MR, Leles CR, Azevedo B, Azevedo JR. Accuracy of cone beam computed tomography and panoramic and periapical radiography for detection of apical periodontitis. *J Endod* 2008;34:273-279. [PUBMED](#) | [CROSSREF](#)
10. Al-Nazhan SA, Alsaeed SA, Al-Attas HA, Dohaithem AJ, Al-Serhan MS, Al-Maflehi NS. Prevalence of apical periodontitis and quality of root canal treatment in an adult Saudi population. *Saudi Med J* 2017;38:413-421. [PUBMED](#) | [CROSSREF](#)
11. Halse A, Molven O, Fristad I. Diagnosing periapical lesions--disagreement and borderline cases. *Int Endod J* 2002;35:703-709. [PUBMED](#) | [CROSSREF](#)
12. Nair MK, Nair UP. Digital and advanced imaging in endodontics: a review. *J Endod* 2007;33:1-6. [PUBMED](#) | [CROSSREF](#)
13. Zaatar EI, al-Kandari AM, Alhomaidah S, al-Yasin IM. Frequency of endodontic treatment in Kuwait: radiographic evaluation of 846 endodontically treated teeth. *J Endod* 1997;23:453-456. [PUBMED](#) | [CROSSREF](#)
14. Maslamani M, Behbahani J, Mitra AK. Radiographic evaluation and predictors of periapical lesions in patients with root-filled and nonroot-filled teeth in Kuwait. *Indian J Dent Sci* 2017a;9:237-240. [CROSSREF](#)
15. Maslamani M, Khalaf M, Mitra AK. Association of quality of coronal filling with the outcome of endodontic treatment: a follow-up study. *Dent J (Basel)* 2017;5:5. [PUBMED](#) | [CROSSREF](#)
16. McHugh ML. Interrater reliability: the kappa statistic. *Biochem Med (Zagreb)* 2012;22:276-282. [PUBMED](#) | [CROSSREF](#)
17. De Moor RJ, Hommez GM, De Boever JG, Delmé KI, Martens GE. Periapical health related to the quality of root canal treatment in a Belgian population. *Int Endod J* 2000;33:113-120. [PUBMED](#) | [CROSSREF](#)
18. Lupi-Pegurier L, Bertrand MF, Muller-Bolla M, Rocca JP, Bolla M. Periapical status, prevalence and quality of endodontic treatment in an adult French population. *Int Endod J* 2002;35:690-697. [PUBMED](#) | [CROSSREF](#)
19. Kabak Y, Abbott PV. Prevalence of apical periodontitis and the quality of endodontic treatment in an adult Belarusian population. *Int Endod J* 2005;38:238-245. [PUBMED](#) | [CROSSREF](#)
20. Estrela C, Bueno MR, Azevedo BC, Azevedo JR, Pécora JD. A new periapical index based on cone beam computed tomography. *J Endod* 2008;34:1325-1331. [PUBMED](#) | [CROSSREF](#)
21. Loftus JJ, Keating AP, McCartan BE. Periapical status and quality of endodontic treatment in an adult Irish population. *Int Endod J* 2005;38:81-86. [PUBMED](#) | [CROSSREF](#)
22. Jiménez-Pinzón A, Segura-Egea JJ, Poyato-Ferrera M, Velasco-Ortega E, Ríos-Santos JV. Prevalence of apical periodontitis and frequency of root-filled teeth in an adult Spanish population. *Int Endod J* 2004;37:167-173. [PUBMED](#) | [CROSSREF](#)
23. Alfouzan K, Baskaradoss JK, Geevarghese A, Alzahrani M, Alhezaimi K. Radiographic diagnosis of periapical status and quality of root canal fillings in a Saudi Arabian subpopulation. *Oral Health Prev Dent* 2016;14:241-248. [PUBMED](#) | [CROSSREF](#)

24. Petersson K, Lewin B, Hakansson J, Olsson B, Wennberg A. Endodontic status and suggested treatment in a population requiring substantial dental care. *Endod Dent Traumatol* 1989;5:153-158. [PUBMED](#) | [CROSSREF](#)
25. Mukhaimer R, Hussein E, Orafi I. Prevalence of apical periodontitis and quality of root canal treatment in an adult Palestinian sub-population. *Saudi Dent J* 2012;24:149-155. [PUBMED](#) | [CROSSREF](#)
26. Alrahabi M, Younes HB. A cross-sectional study of the quality of root canal treatment in Al-Madinah Al-Munawwarah. *Saudi Endod J* 2016;6:31-35. [CROSSREF](#)
27. Georgopoulou MK, Spanaki-Voreadi AP, Pantazis N, Kontakiotis EG. Frequency and distribution of root filled teeth and apical periodontitis in a Greek population. *Int Endod J* 2005;38:105-111. [PUBMED](#) | [CROSSREF](#)
28. Ørstavik D. Time-course and risk analyses of the development and healing of chronic apical periodontitis in man. *Int Endod J* 1996;29:150-155. [PUBMED](#) | [CROSSREF](#)
29. Petersson K, Håkansson R, Håkansson J, Olsson B, Wennberg A. Follow-up study of endodontic status in an adult Swedish population. *Endod Dent Traumatol* 1991;7:221-225. [PUBMED](#) | [CROSSREF](#)
30. Ariga J, Al-Mutawa S, Nazar H. School oral health program in Kuwait. *Med Princ Pract* 2014;23 Supplement 1:43-46. [PUBMED](#) | [CROSSREF](#)
31. Kerekes K, Tronstad L. Long-term results of endodontic treatment performed with a standardized technique. *J Endod* 1979;5:83-90. [PUBMED](#) | [CROSSREF](#)
32. Weiger R, Hitzler S, Hermle G, Löst C. Periapical status, quality of root canal fillings and estimated endodontic treatment needs in an urban German population. *Endod Dent Traumatol* 1997;13:69-74. [PUBMED](#) | [CROSSREF](#)
33. Sjögren U, Hagglund B, Sundqvist G, Wing K. Factors affecting the long-term results of endodontic treatment. *J Endod* 1990;16:498-504. [PUBMED](#) | [CROSSREF](#)
34. Schaeffer MA, White RR, Walton RE. Determining the optimal obturation length: a meta-analysis of literature. *J Endod* 2005;31:271-274. [PUBMED](#) | [CROSSREF](#)
35. Nair PN, Sjögren U, Krey G, Sundqvist G. Therapy-resistant foreign body giant cell granuloma at the periapex of a root-filled human tooth. *J Endod* 1990;16:589-595. [PUBMED](#) | [CROSSREF](#)
36. Sidaravicius B, Aleksejuniene J, Eriksen HM. Endodontic treatment and prevalence of apical periodontitis in an adult population of Vilnius, Lithuania. *Endod Dent Traumatol* 1999;15:210-215. [PUBMED](#) | [CROSSREF](#)
37. Tronstad L, Asbjørnsen K, Døving L, Pedersen I, Eriksen HM. Influence of coronal restorations on the periapical health of endodontically treated teeth. *Endod Dent Traumatol* 2000;16:218-221. [PUBMED](#) | [CROSSREF](#)
38. Ray HA, Trope M. Periapical status of endodontically treated teeth in relation to the technical quality of the root filling and the coronal restoration. *Int Endod J* 1995;28:12-18. [PUBMED](#) | [CROSSREF](#)
39. Segura-Egea JJ, Jiménez-Pinzón A, Poyato-Ferrera M, Velasco-Ortega E, Ríos-Santos JV. Periapical status and quality of root fillings and coronal restorations in an adult Spanish population. *Int Endod J* 2004;37:525-530. [PUBMED](#) | [CROSSREF](#)
40. Hoskinson SE, Ng YL, Hoskinson AE, Moles DR, Gulabivala K. A retrospective comparison of outcome of root canal treatment using two different protocols. *Oral Surg Oral Med Oral Pathol Oral Radiol Endod* 2002;93:705-715. [PUBMED](#) | [CROSSREF](#)