

## Case Report

Clin Shoulder Elbow 2024;27(1):126-130  
<https://doi.org/10.5397/cise.2023.00234>

eISSN 2288-8721

# Anterior capsular reconstruction with acellular dermal allograft for subscapularis deficiency: a report of two cases

Raffy Mirzayan<sup>1</sup>, Shane Korber<sup>2</sup>

<sup>1</sup>Department of Orthopedic Surgery, Kaiser Permanente Southern California, Baldwin Park, CA, USA

<sup>2</sup>Department of Orthopedic Surgery, University of Southern California, Los Angeles, CA, USA

Anterior glenohumeral instability with an irreparable subscapularis tear is a challenging problem for the orthopedic shoulder surgeon. Current techniques, including tendon transfers, yield inconsistent results with high rates of recurrent instability. Acellular dermal allografting has been used in young patients with massive superior rotator cuff tears with early success, but acellular dermal allografting is comparatively unstudied in anterior deficiency. We present two cases of anterior capsular reconstruction with an acellular dermal allograft in patients ages 66 and 58 years with irreparable subscapularis tendon tears. Follow-up for both patients exceeded 4 years, with forward flexion >140°, external rotation exceeding 60°, a Single Assessment Numeric Evaluation score >90 points, a visual analog scale score of 0 points, and an American Shoulder and Elbow Score of 98 points. In conclusion, acellular dermal allografting can be used to reconstruct the anterior capsule in patients with massive irreparable subscapularis tears, similar to its use in superior capsular reconstruction in patients with massive posterosuperior rotator cuff tears.

**Keywords:** Acellular dermal allograft; Chronic subscapularis tear; Chronic subscapularis deficiency; Rotator cuff; Shoulder

Anterior glenohumeral instability in the setting of irreparable subscapularis deficiency remains a challenging problem for orthopedic surgeons. It is well known that subscapularis integrity is important for glenohumeral biomechanics and stability because the anterior capsule blends with the subscapularis. When the subscapularis is torn and retracted medially, the anterior capsule is retracted with it [1]. Various techniques have been described to restore glenohumeral mechanics. Tendon transfers including those of the pectoralis major, latissimus, teres major, and trapezius have been described, with the pectoralis major being the most common [2]. Results of pectoralis major tendon transfer have been inconsistent, with a notable risk of musculocutaneous nerve injury [1-3]. Latissimus and trapezius transfer results have been suggested to improve the line of pull, but results have been

poor [2,4]. Anterior capsular graft reconstructions for the treatment of failed thermal capsulorrhaphy have included the iliotibial band, tibialis anterior, and hamstrings [5]. However, the results of this kind of procedure have been mixed, with high rates of recurrent instability [5].

Superior capsular reconstruction (SCR) with a tensor fasciae latae or acellular dermal allograft (ADM) has led to encouraging results in the early- to mid-term in middle-aged patients with massive irreparable superior rotator cuff tears [6,7]. Several studies documented improvements in range of motion (ROM), pain, and patient-reported outcome measures [6,7]. Given the early success of SCR with ADM, similar techniques have been described for the anterior capsule [8]. However, although results from recent biomechanical studies of anterior capsule recon-

Received: March 30, 2023    Revised: July 17, 2023    Accepted: July 17, 2023

Correspondence to: Raffy Mirzayan

Department of Orthopedic Surgery, Kaiser Permanente Southern California, 1011 Baldwin Park Blvd. Baldwin Park, CA 91706, USA

Tel: +1-626-851-101, E-mail: [lakersdoc@gmail.com](mailto:lakersdoc@gmail.com), ORCID: <https://orcid.org/0000-0001-7008-2484>

© 2024 Korean Shoulder and Elbow Society.

This is an Open Access article distributed under the terms of the Creative Commons Attribution Non-Commercial License (<http://creativecommons.org/licenses/by-nc/4.0/>) which permits unrestricted non-commercial use, distribution, and reproduction in any medium, provided the original work is properly cited.

struction with ADM have been promising [8,9], clinical data are lacking [10].

Here, we demonstrate that ADM was successful in reconstructing the anterior capsule in two patients at 4 years of follow-up. These patients included an active individual with an irreparable subscapularis tear without significant glenohumeral arthritis who preferred to avoid a reverse shoulder arthroplasty.

## CASE REPORT

This case report was exempt from institutional review board (IRB) review because the activity does not meet the regulatory definition of research, as defined by 45 CFR 46.102(l), and informed consent was waived.

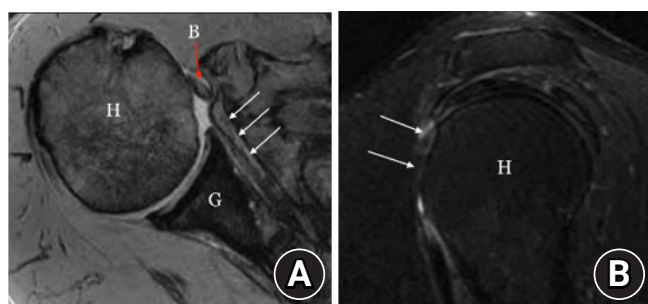
### Case 1

A 66-year-old male laborer with right-hand dominance dislocated his right shoulder again while pulling on a garage door, requiring reduction in the emergency room. His initial dislocation had occurred approximately 40 years prior while waterskiing. He never sought medical attention and experienced recurrent dislocations every few years. He had no apparent muscle atrophy and full active ROM with a positive belly press and lift-off as well as positive apprehension and relocation signs. He underwent magnetic resonance imaging (MRI), which revealed a chronic Hill-Sachs lesion, posterior inferior labral tear, and full-thickness Goutallier IV supraspinatus and subscapularis tears with medial subluxation of the biceps tendon (Fig. 1). The procedure was performed in the lateral decubitus position. Upon diagnostic arthroscopy, the subscapularis tendon was absent and unable to visualized. The supraspinatus was torn and retracted from the greater tuberosity. The remaining rotator cuff was intact, but the

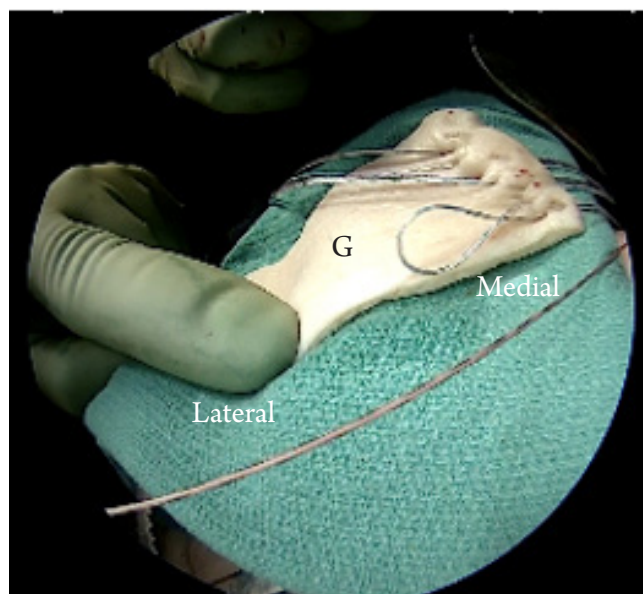
biceps was frayed and anteromedially displaced. The supraspinatus was arthroscopically repaired primarily.

A mini-open anterior incision approximately 4–5 cm long was created, and the deltopectoral approach was used. Despite clearing adhesions 360° around the subscapularis, it would not mobilize and remained at the level of the anterior glenoid rim. The decision was made to reconstruct the anterior capsule with ADM. Three knotless SutureTak anchors (Arthrex) were placed into the anterior glenoid (5-mm medial from the joint line). The repair stitch was passed in mattress fashion through the medial edge of a 3-mm-thick ArthroFlex (LifeNet Health) dermal allograft (Fig. 2). The repair stitch was then looped back into its own anchor, locking it in and reducing and fixing the graft to the anterior glenoid neck (Fig. 3A). Next, a three of 4.75-mm BioComposite SwiveLock anchors loaded with FiberTape (Arthrex) was placed in the medial row of the lesser tuberosity, just off the articular margin (Fig. 3B). The sutures were passed through the dermal graft approximately 15 mm from the lateral edge, brought over the graft, and secured with 4.75-mm anchors (Fig. 3C). The arm was fixed at 45° of abduction and neutral rotation. The long head of the biceps tendon was tenodesed to the short head of the biceps.

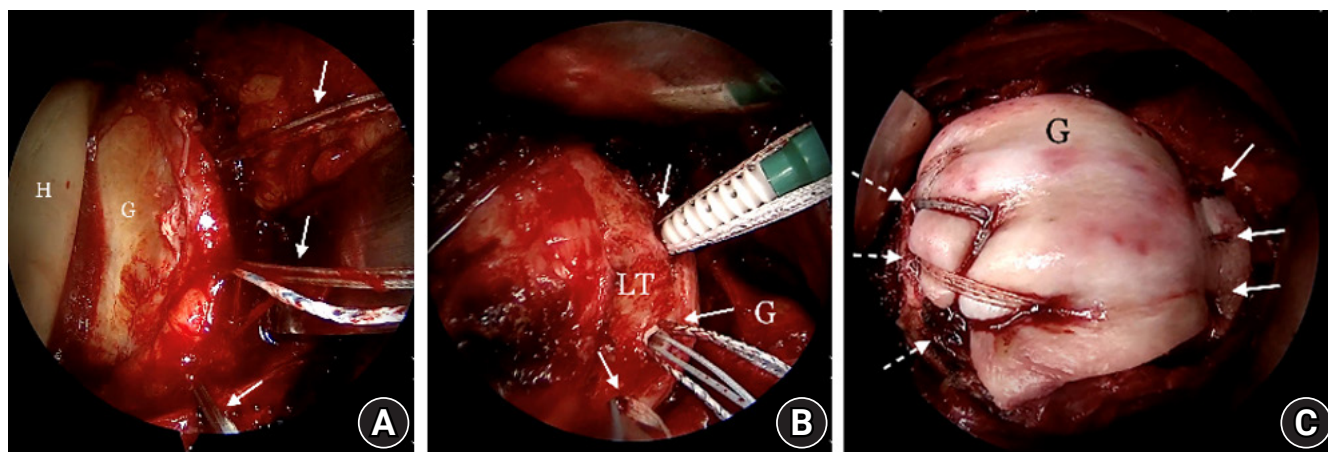
Postoperatively, the patient was kept in a sling for 3 weeks. Then, once the sling was removed, active and active-assisted ROM movement was initiated. Attempting external rotation beyond 45° was limited for the first 6 weeks. Strengthening was then initiated at 6 weeks. The patient was last seen 58 months af-



**Fig. 1.** Preoperative (A) axial and (B) sagittal magnetic resonance imaging scans of the right shoulder. B: long head of the biceps tendon, H: humeral head, G: glenoid. Note the medial subluxation of the long head of the biceps tendon out of the groove (red arrow) as well as the full-thickness, attenuated subscapularis tear (white arrows).



**Fig. 2.** Intraoperative photograph of the acellular dermal allograft. Sutures are in place along the medial side of the graft, which will be anchored in the glenoid. G: graft.



**Fig. 3.** Intraoperative photographs. (A) Three knotless SutureTak anchors (Arthrex; white arrows) were placed into the glenoid. H: humeral head, G: glenoid. (B) BioComposite medial-row SwiveLock Anchors with FiberTape (Arthrex; white arrows) were placed in the lesser tuberosity. LT: lesser tuberosity, G: glenoid. (C) Transosseous-equivalent (Expanded SpeedBridge) fixation across the lesser tuberosity (dashed arrows), along with glenoid fixation (solid arrows). G: acellular dermal allograft.

ter surgery with no pain, full forward flexion, active external rotation to 70° with the arm at the side and to 90° with the arm abducted. He also had 5/5 strength per Jobe's test and 4/5 strength with internal rotation as well as a persistent belly press and lift-off sign, but the apprehension and relocation signs were eliminated. He denied symptoms of instability. At 58 months, he had a Single Assessment Numeric Evaluation (SANE) score of 90 points, a visual analog scale score of 0 points, and an American Shoulder and Elbow Score (ASES) of 98 points. A postoperative axillary radiograph revealed no evidence of anterior translation—the same as on preoperative radiograph. Postoperative MRI at 3 months revealed a well-fixed, intact reconstruction as well as a healed supraspinatus repair (Fig. 4).

### Case 2

A 58-year-old male heavy laborer with left-hand dominance injured his right shoulder at work moving a heavy pallet. He experienced significant pain, stiffness, and weakness for the subsequent 5 months and no relief with physical therapy, non-steroidal anti-inflammatory drugs, or cortisone injections. MRI revealed a grade 3 subscapularis tear and a long head of the biceps tear. Given his persistent symptoms, he elected to undergo surgery. Upon diagnostic arthroscopy, the subscapularis was torn and retracted. The remaining rotator cuff tendons were intact. Anterior capsular reconstruction was performed in a similar manner to case 1, except a three of knotless FiberTak anchors (Arthrex) instead of SutureTak anchors was placed on the anterior glenoid.

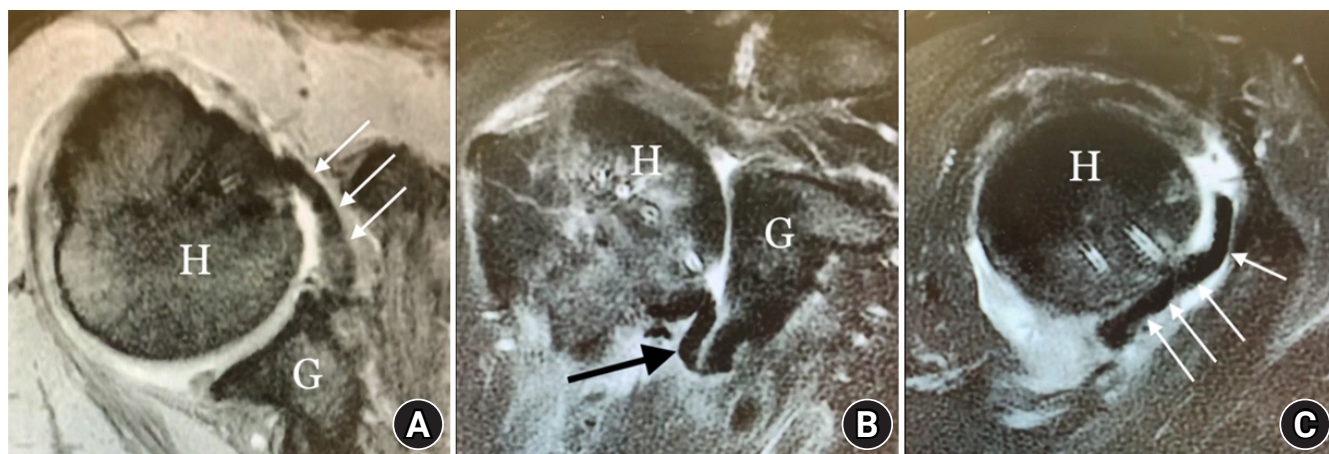
The patient underwent the same rehabilitation protocol as the patient in case 1. At 50 months of follow-up, he had forward flexion and external rotation to 60° as well as 4/5 strength with inter-

nal rotation without instability. His SANE score was 100 points, his visual analog scale score was 0 points, and his ASES was 98 points. A postoperative axillary radiograph revealed no evidence of anterior translation—the same as on preoperative radiograph.

## DISCUSSION

Irreparable subscapularis tears in the young, active patient are a challenge to manage. The subscapularis is a critical player in the force-couple balancing of the glenohumeral joint, keeping the humeral head concentric throughout the ROM. Though the ADM is not a dynamic structure, it does restore anterior stability, allowing the surrounding structures to work in concert and restore kinematics [1]. In a biomechanical study, Omid et al. [4] demonstrated that anterior capsule reconstruction (ACR) restored rotational ROM and reduced anteroinferior glenohumeral translation more effectively than pectoralis major transfer alone. In their study, Mirzayan et al. [8] demonstrated that even a failed dermal allograft can improve pain and function by restoring biomechanics.

Since it is a static structure, the position of the arm at the time of fixation is a critical factor in the patient's ROM. In our study, we fixed the arm at 45° of abduction and neutral rotation to achieve a balanced ROM in both internal and external rotation. Pectoralis major transfer has traditionally been used for severe subscapularis insufficiency. In a systematic review of 195 shoulders with irreparable subscapularis tears, Shin et al. [1] noted a statistically significant improvement in Constant scores from 37.8 to 61.3 points ( $P < 0.0001$ ). However, this improvement was less consistent in patients with preoperative glenohumeral anteri-



**Fig. 4.** Postoperative (A) axial, (B) coronal, and (C) sagittal magnetic resonance imaging scans of the right shoulder. Acellular dermal allograft was secure and intact (white arrows and black arrow). H: humeral head, G: glenoid.

or subluxation or prior arthroplasty. This subset of patients also had higher rates of reoperation [1]. In Komperda et al.'s cadaveric study [2], they found that pectoralis major tendon transfer in isolation failed to restore normal glenohumeral biomechanics due to the indirect line of pull of the pectoralis major. They concluded that pectoralis major tendon transfer should not be performed in isolation with patients with recurrent glenohumeral instability [2]. Elhassan et al. [3] described 29 patients who underwent pectoralis major transfer. They found a consistent improvement in Constant score and pain relief after treatment. However, the pain relief and patient-reported outcome measures were not significantly improved if the patient had a prior arthroplasty or preoperative anterior subluxation of the humeral head. They concluded that there is a high risk of failure with pectoralis major transfer if there is preoperative anterior instability [3].

Other options for irreparable subscapularis tears include latissimus dorsi, trapezius, or teres major tendon transfers. However, these options suffer from many of the same downsides as pectoralis major transfer, including altered biomechanics and high re-tear rates [3,4]. The axillary nerve is also at risk in latissimus and teres major transfers [1,4]. For latissimus transfers, a high number of patients report discomfort and pain at the donor site [4].

ACR addresses some of the disadvantages of tendon transfers. Like SCR, ACR provides a static check rein against glenohumeral translation, improving glenohumeral stability [6,7]. Since ACR provides greater anterior stability in patients with preoperative glenohumeral translation compared to tendon transfers, ACR may be preferable to tendon transfers in patients with anterior humeral subluxation. In addition, ACR avoids donor site morbidity and the risk of nerve damage that can occur with tendon transfers [9,10].

Long-term clinical results of ACR have yet to be published. A single case report by Myers et al. [10] details a 51-year-old patient with an irreparable subscapularis tear after total shoulder arthroplasty, reporting improvements in function, ROM, internal rotation strength, and patient-reported outcomes at 2 years after the procedure. They also reported no recurrent anterior instability.

In conclusion, our study adds to the sparse literature concerning the use of ACR with ADM for irreparable subscapularis tear in the native shoulder. Our two cases of ACR demonstrate satisfactory functional and patient-reported outcomes in the short- to mid-term. This technique is promising when indicated for the right patient population and may provide an alternative to tendon transfer. Future studies are warranted to investigate long-term clinical outcomes.

## NOTES

### ORCID

Raffy Mirzayan <https://orcid.org/0000-0001-7008-2484>

### Author contributions

Conceptualization: RM. Data curation: RM. Formal Analysis: SK. Investigation: SK. Methodology: RM. Project administration: RM. Supervision: RM. Writing – original draft: SK. Writing – review & editing: RM.

### Conflict of interest

None.

### Funding

None.

### Data availability

None.

### Acknowledgments

None.

## REFERENCES

1. Shin JJ, Saccomanno MF, Cole BJ, Romeo AA, Nicholson GP, Verma NN. Pectoralis major transfer for treatment of irreparable subscapularis tear: a systematic review. *Knee Surg Sports Traumatol Arthrosc* 2016;24:1951–60.
2. Komperda KW, Adamson GJ, Itami Y, et al. Anterior capsule reconstruction versus pectoralis major transfer for irreparable subscapularis tears involving the anterior capsule: a comparative biomechanical cadaveric study. *Arthroscopy* 2019;35:3002–8.
3. Elhassan B, Ozbaydar M, Massimini D, Diller D, Higgins L, Warner JJ. Transfer of pectoralis major for the treatment of irreparable tears of subscapularis: does it work. *J Bone Joint Surg Br* 2008;90:1059–65.
4. Omid R, Stone MA, Lin CC, et al. Biomechanical analysis of anterior capsule reconstruction and latissimus dorsi transfer for irreparable subscapularis tears. *J Shoulder Elbow Surg* 2020;29:374–80.
5. Dewing CB, Horan MP, Millett PJ. Two-year outcomes of open shoulder anterior capsular reconstruction for instability from severe capsular deficiency. *Arthroscopy* 2012;28:43–51.
6. Tokish JM, Beicker C. Superior capsule reconstruction technique using an acellular dermal allograft. *Arthrosc Tech* 2015;4:e833–9.
7. Denard PJ, Brady PC, Adams CR, Tokish JM, Burkhart SS. Preliminary results of arthroscopic superior capsule reconstruction with dermal allograft. *Arthroscopy* 2018;34:93–9.
8. Mirzayan R, Stone MA, Batech M, Acevedo DC, Singh A. Failed dermal allograft procedures for irreparable rotator cuff tears can still improve pain and function: the "biologic tubero-plasty effect". *Orthop J Sports Med* 2019;7:2325967119863432.
9. Kwapisz A, Tokish JM. Anterior capsule reconstruction technique with an acellular dermal allograft. *Arthrosc Tech* 2017;6:e1945–52.
10. Myers D, Triplet JJ, Johnson DB, Strakowski JA, Wiseman SP, Long NK. Anterior capsular reconstruction using a dermal allograft for an irreparable subscapularis tear after shoulder arthroplasty: a case report. *JBSJ Case Connect* 2020;10:e0468.