

Pyrocarbon hemiarthroplasty and the shoulder: biomechanical and clinical results of an emerging treatment option

Mohamad Y. Fares, Jaspal Singh, Peter Boufadel, Matthew R. Cohn, Joseph A. Abboud

Division of Shoulder and Elbow Surgery, Rothman Orthopedic Institute, Philadelphia, PA, USA

While shoulder hemiarthroplasty is still used to treat young patients with shoulder pathology, the use of this procedure has substantially declined in recent years due to its significant complication profile. Glenoid wear with arthrosis is one of the major postoperative complications following shoulder hemiarthroplasty, and efforts to prevent this complication led many scientists to explore alternative weight-bearing surfaces on arthroplasty implants to decrease joint wear and improve patient outcomes. Pyrolytic carbon, or pyrocarbon, is a material that has better biocompatibility, survivorship, strength, and wear resistance compared to the materials used in traditional shoulder hemiarthroplasty. Pyrocarbon implants have been used in orthopedics for over 50 years; recently, their utility in shoulder hemiarthroplasty has garnered much interest. The purpose behind the use of pyrocarbon in shoulder hemiarthroplasty is to decrease the risk of progressive glenoid wear, especially in young active patients in whom joint preservation is important. Promising survivorship and outcomes have been demonstrated by recent studies, including limited glenoid wear following pyrocarbon hemiarthroplasty. Nevertheless, these clinical studies have been limited to relatively small case series with limited long-term follow-up. Accordingly, additional research and comparative studies need to be conducted in order to properly assess the therapeutic efficacy and value of pyrocarbon hemiarthroplasty.

Keywords: Pyrolytic carbon; Osteoarthritis; Partial shoulder replacement; Glenoid arthrosis; Avascular necrosis

INTRODUCTION

Shoulder arthroplasty has become increasingly common over the past two decades [1]. While the number of primary reverse total shoulder arthroplasty (rTSA) and primary anatomic total shoulder arthroplasty (aTSA) procedures has increased in recent years, hemiarthroplasty has become less common and its surgical indications have narrowed [2,3]. The procedure remains an important treatment option in a specific subset of patients, primarily young, physically-active individuals with glenohumeral osteoarthritis (GHOA) or avascular necrosis (AVN) of the humeral head [2,4-6]. Compared to other replacement procedures, hemiarthroplasty better preserves glenoid bone stock and typically requires

a shorter surgical time [2,4-6].

Despite the advantages of shoulder hemiarthroplasty, there exists a number of potential complications that may compromise outcomes and lead to higher revision rates [7,8]. Joint overload, anterosuperior escape, and glenoid arthrosis are all potential complications [9-13]. The articulation of the metal resurfaced humeral head with the native glenoid can often generate pain, bone erosion, and potential medialization of the joint line [9]. Different studies have explored techniques to minimize the impact of the resurfaced humeral head on the native glenoid with limited success [14,15].

In order to solve this challenge, pyrolytic carbon (pyrocarbon) in the form of pyrocarbon-coated implants or interpositional

Received: January 11, 2023 Revised: January 31, 2023 Accepted: February 4, 2023

Correspondence to: Joseph A. Abboud

Division of Shoulder and Elbow Surgery, Rothman Orthopedic Institute, 925 Chestnut St, Philadelphia, PA 19107, USA

Tel: +1-610-547-8351, E-mail: abboudj@gmail.com, ORCID: <https://orcid.org/0000-0002-3845-7220>

© 2024 Korean Shoulder and Elbow Society.

This is an Open Access article distributed under the terms of the Creative Commons Attribution Non-Commercial License (<http://creativecommons.org/licenses/by-nc/4.0/>) which permits unrestricted non-commercial use, distribution, and reproduction in any medium, provided the original work is properly cited.

prosthetic components was introduced as an alternative weight-bearing surface that can decrease glenoid erosion in hemiarthroplasty procedures [16-18]. Early *in vitro* studies showed promising results, with reduced wear rates compared to other materials [19-21]. Understanding the biomechanical principles and clinical outcomes of pyrocarbon humeral heads is critical to determine its role in the increasingly diverse landscape of shoulder arthroplasty implants. As such, the aim of this review is to evaluate the current use of shoulder hemiarthroplasty, describe the properties of the pyrocarbon material, explore the previous use of pyrocarbon in the surgical setting, and evaluate the utility of this novel technology in shoulder surgery.

SHOULDER HEMIARTHROPLASTY

While aTSA has been shown to provide more consistently successful clinical outcomes for elderly patients with primary GHOA [8,22], the ideal treatment for young, physically-active patients who are at elevated risk of late glenoid component loosening remains unclear. Hemiarthroplasty with or without concentric glenoid reaming (“ream and run”) provides durable clinical improvements without risk of complications related to the glenoid component [15,23-26]. In patients with inadequate bone stock to support a glenoid component, hemiarthroplasty may be preferred [15,23-26]. Patients with AVN without glenoid involvement achieve the most positive outcomes with hemiarthroplasty, whereas relatively poor results are seen with proximal humerus fractures or cuff tear arthropathy [27].

However, higher complication rates are seen with hemiarthroplasty compared to aTSA. Fonte et al. [2] found that the hemiarthroplasty for GHOA had a complication rate of 21.7%, compared to 19.4% among both rTSA and aTSA patients. Hackett et al. [28] reviewed the causes for revision among 359 hemiarthroplasty patients who had indications that included proximal humerus fracture, GHOA, capsulorrhaphy arthropathy, cuff tear arthropathy, and AVN. The most common characteristics of revised hemiarthroplasties were rotator cuff failure, fracture sequelae, and severe glenoid erosion violating the subchondral bone [28]. Severe erosion was present in 35% of cases, with erosion beyond the coracoid base in 4%. While a trend toward rTSA for proximal humerus fractures and those with at-risk rotator cuffs has likely reduced the rates of revision due to cuff failure and fracture sequelae, glenoid wear remains a concern.

Herschel et al. [29] retrospectively reviewed 118 shoulders treated with hemiarthroplasty to explore the rate of postoperative glenoid erosion and arthrosis and to identify possible risk factors. The authors showed that nearly one-third of patients who under-

went hemiarthroplasty of the shoulder developed severe glenoid erosion within a mean postoperative time of 2.5 years [29]. The authors also found that osteoarthritis and bone cysts, fatty infiltration of the rotator cuff, and inclination of the prosthetic head were risk factors for glenoid arthrosis in these patients [29]. Specifically, overly horizontal positioning of the prosthetic implant was considered a predictor for erosion as it increases the friction between the implant and the glenoid [29]. Parsons et al. [30] recorded progressive glenoid cartilage wear in eight patients followed for a mean of 43 months, noting a 68% decrease in glenohumeral joint space. The authors also noted lower patient reported outcome scores in those with residual joint spaces smaller than 1 mm compared to those in patients with joint spaces larger than 1 mm [30]. These studies support the potential of glenoid wear following shoulder hemiarthroplasty and the resulting limitations placed on the use of this procedure.

PYROCARBON HISTORY AND COMPOSITION

Pyrocarbon was originally developed in the late 1960s as a strong, durable, and wear-resistant coating for nuclear fuel particles [31]. Pyrocarbon is a form of pure elemental carbon similar to graphite and exists in a disordered crystalline structure composed of randomly oriented continuous crystalline array regions with a sheet layer spacing of approximately 0.348 nm [32]. Due to the small size of these arrays and their random orientation in space, bulk pyrocarbon has isotropic mechanical and physical characteristics. Disorder between adjacent sheets increases the strength of pyrocarbon compared to the more organized crystalline structure of graphite [33,34].

After its initial development, pyrocarbon was modified at the University of Wisconsin to have increased biocompatibility and survivorship in the biological environment for use in long-term cardiovascular implants [31]. Since then, pyrocarbon has been used for over 35 years in various applications for upper extremity orthopedic prosthetics composed of a graphite core with a pyrolytic carbon coating up to 1 mm thick (Fig. 1) [33]. The graphite core defines both the size and the shape of the implant, while the outer pyrocarbon coating provides strength, longevity, and resistance to wear and fatigue [33,35,36]. Tungsten is mixed into the graphite portion to impart radiopacity, while the pyrocarbon layer is radiolucent. This results in a radiolucent halo around the bright white radiopaque core on radiographs [32,37]. Different types of pyrocarbon implants exist, especially in the shoulder; and several clinical reports describe their use for treatment of challenging shoulder pathologies in young patients (Figs. 2 and

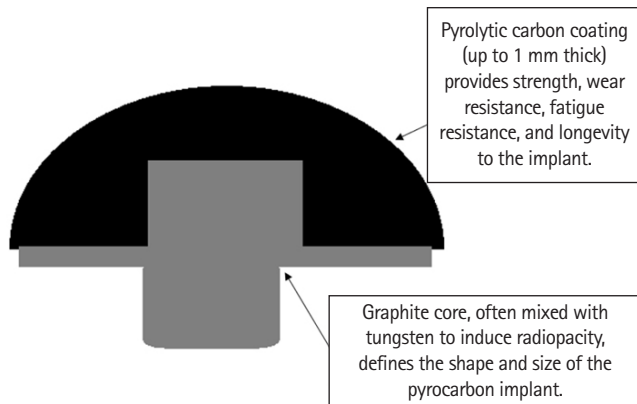


Fig. 1. Pyrolytic carbon implant showing the graphite core that defines the implant shape and size and the pyrolytic carbon coating that adds strength and longevity.

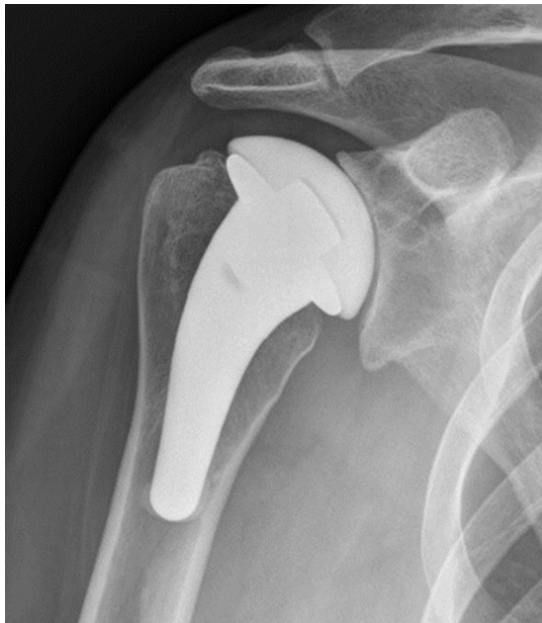

Fig. 2. An X-ray image of a pyrocarbon hemiarthroplasty implant.

3) [17,18].

The material is made by heating hydrocarbons to temperatures above 1,200 °C in the absence of oxygen, the product of which is then deposited onto a graphite core by chemical vapor deposition [33,38,39]. Most carbon-based materials are compatible with the biologic environment, and the same applies for pyrocarbon. However, the crystallographic structure formed by this production process imparts mechanical and tensile strength not demonstrated in all carbon materials. This provides pyrocarbon with prominent fatigue and crack resistance, a beneficial trait for use in long-term implants [40,41].

Pyrocarbon has both a similar density and Young's modulus to bone, which allows implants to be biomechanically compatible

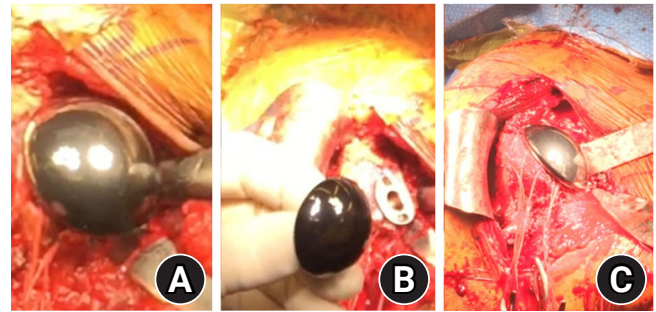


Fig. 3. (A-C) Operative implantation of a pyrocarbon hemiarthroplasty implant.

and for minimal stress shielding at the bone-prosthesis interface. Alongside the strength provided by its crystalline structure, this structure also allows pyrocarbon implants to have good durability and wear resistance [42,43]. In the clinical setting, research analyzing fatigue failure has shown promising results over 30 years of use. For example, the use of pyrocarbon in heart valve prostheses has eliminated wear as a mode of failure [44-46].

PYROCARBON AND OTHER MATERIALS

As more patients undergo shoulder arthroplasty at younger ages, there is a need for durable and biocompatible implants to reduce the risk of long-term complications such as component loosening, osteolysis, and polyethylene wear [21,47-49]. In the hemiarthroplasty setting, the articulating surface of the implant is in contact with the native joint surface or a reamed surface in the case of ream and run. Glenoid wear occurs over time through abrasion, adhesion, fatigue, third body wear, and corrosion [21,50].

Several laboratory studies have indicated that pyrocarbon is less damaging to cartilage compared to traditional implant materials. Animal studies using pyrocarbon for joint prostheses in comparison to cobalt-chromium (CoCr) and titanium alloy have shown better tolerance and significantly less cartilage wear [51]. Although the reason remains uncertain, this preservation of cartilage reduced the amount of joint space narrowing and pain caused by long-term use [51]. Pyrocarbon may also have a role in increased production of type II collagen, leading to formation of a cartilaginous matrix at the articulating surface; however, there are limited data on the clinical benefit [21,52]. Over time, when pyrocarbon was brought into contact with the bony surface of the native joint, less damage than with traditional metal alloys was observed [32,53]. Bone volume loss seen in lab testing from CoCr alloys was approximately 100 times greater than that seen

with pyrocarbon, indicating that joint preservation is more likely with a pyrocarbon humeral head implant [32].

In an *in vitro* study by Klawitter et al. [54], pyrocarbon showed more favorable wear characteristics than CoCr. Using a simulator applying 756 N of applied load to mimic demand conditions of a shoulder hemiarthroplasty patient, damage to the articular surface was observed after 320,000 cycles with CoCr, compared to over 5 million cycles with pyrocarbon [54]. Pyrocarbon also demonstrated 30 times lower linearized bone penetration, bone loss volume rate, and changes to surface roughness compared to CoCr, suggesting that pyrocarbon may be a durable treatment option in the younger patient population [54,55]. In addition, lower production of wear-related particles can potentially reduce risk of osteolysis and aseptic loosening, which occurs in approximately 4% of hemiarthroplasty cases requiring revision [28,32,37]. Considering the biocompatibility and less caustic relationship with cartilage and bone, pyrocarbon is a promising alternative for hemiarthroplasty implants that require long lifespans [32].

PYROCARBON HEMIARTHROPLASTY OF THE SHOULDER

The earliest clinical use of pyrocarbon implants in orthopedics was in 1968 to treat thumb carpometacarpal arthritis, and the utility of pyrocarbon implants was expanded to treat other small joint conditions of the hand and other areas in the body [56]. Positive outcomes from pyrocarbon hemiarthroplasty emerged for different conditions affecting small joints in the hand and were evident through reports of prominent improvements in pain, function, and grip strength [57,58]. Nevertheless, some reports highlighted concerns for procedure-related complications, including postoperative arthritis, component loosening and dislocation, and nerve impingement [59]. As such, wide adoption of pyrocarbon implants has been limited to hand surgery, possibly due to its complication profile and higher costs [60,61]. Pyrocarbon implants have also been used in the lower limb, as reported by Bernasek et al. [62], who conducted a pilot study of pyrocarbon hemiarthroplasty on two groups of patients diagnosed with either hip fracture or femoral head osteonecrosis. The authors reported a significantly higher rate of revision in the osteonecrosis group compared to the fracture group, mainly due to acetabular wear and groin pain, indicating mixed results and equivocal benefit of the pyrocarbon implant [62]. As such, application of pyrocarbon in different joints, while promising, did not lead to a convincing integration into standard arthroplasty practice.

In the setting of shoulder hemiarthroplasty, pyrocarbon-coated implants and pyrocarbon inter-positional humeral head prosthe-

ses have been developed, and early clinical results have been reported. Cointat et al. [16] reported the survivorship and short-term outcomes of 64 consecutive patients who underwent pyrocarbon hemiarthroplasty for GHOA, with an average follow-up of 33 months. Survival rate of the prosthesis was 92%, with five patients undergoing revision conversion to total shoulder arthroplasty: one patient was converted to aTSA due to painful glenoid erosion, and four patients were converted to rTSA due to postoperative rotator cuff deficiency [16]. The authors also reported that approximately 91% of the patients returned to work and 88% of the patients returned to sports [16]. Similarly, a study by Tsitlakidis et al. [63] explored the survival rates and clinical outcomes of 16 patients ranging from 29 to 65 years in age, with an average follow-up of 24 months. The patients had undergone a pyrocarbon hemiarthroplasty of the shoulder due to GHOA, rheumatoid arthritis, or AVN [64]. At follow-up, the authors reported an arthroplasty survival rate of 94%, and significant improvements in Constant scores and pain scores were reported. Only one revision surgery was necessary due to a periprosthetic fracture [63]. Another prospective study by Garret et al. [64] followed 65 patients who underwent pyrocarbon hemiarthroplasty of the shoulder for GHOA, AVN, or rheumatoid arthritis. At a mean follow-up of approximately 26 months, the authors reported improvement in mean Constant score from 31 preoperatively to 74 and Single Assessment Numeric Evaluation scores from 32 to 78 at most recent follow-up [64]. The authors also conducted radiographic analyses at 2-year follow-up and reported no glenoid erosion in 86% of the patients; however, six patients showed progressive glenoid erosion and 3 showed thinning of tuberosities [64].

While early clinical outcomes are promising, there are limited mid- and long-term data available. A study by Hudek et al. [65] examined the use of a free pyrocarbon-coated interposition arthroplasty in the shoulders of 10 patients for treatment of advanced collapse of the humeral head following AVN. At a mean follow-up of 3.6 years, the authors reported excellent improvements in quality of life and function as demonstrated by significant improvements in clinical outcome scores that are comparable to those of aTSA. These improvements comprised a 63-point increase in Constant scores and 47-point increase in Disabilities of the Arm, Shoulder and Hand (DASH) scores [65]. On radiographic analyses, the authors reported 1.4 mm mean glenoid erosion, -0.8 mm thinning of tuberosities, and 2 mm superior displacement of implant [65]. Another study by McBride et al. [66] used a national joint replacement registry to explore the outcomes of patients younger than 55 years who underwent primary shoulder arthroplasty for GHOA. The au-

thors compared the outcomes of 163 patients who underwent pyrocarbon humeral resurfacing hemiarthroplasty to those of 163 patients who underwent CoCr humeral resurfacing and 67 patients who underwent metal stemmed hemiarthroplasty [66]. At a mean follow-up of 6 years, revision rates were 17.1% for metal hemi-resurfacing, 17.5% for metal stemmed hemiarthroplasty, and 8.9% for pyrocarbon hemi-resurfacing, with pain, prosthesis fracture, and infections as the key reasons for revisions [66]. No pyrocarbon hemi-resurfacing cases were revised for glenoid erosion, further supporting the use of this implant for young GHOA patients [66].

Despite promising clinical outcomes, a few studies have high-

lighted concerns regarding relatively high revision rates of the implant [17,67]. Hirakawa et al. [17] reported outcomes of 10 patients who underwent pyrocarbon interposition arthroplasty of the shoulder. Patients included were younger than 60 years with either AVN of the humeral head, GHOA with Walch type B glenoids, or secondary severe osteoarthritis [17]. Of the 10 patients, five required revision surgery to rTSA at a mean follow-up time of 60 months due to poor clinical outcomes based on Constant and Subjective Shoulder Value scores [17]. The remaining five patients had significant improvements in clinical outcome scores, though their follow-up duration was less than 35 months [17]. That study, while limited by a small population, expressed con-

Table 1. Summary of studies reporting on the outcomes of pyrocarbon-coated hemiarthroplasty of the shoulder

Study	Number of patients	Indication	Procedure	Mean follow-up	Prognosis
Garret et al. (2017) [64]	65	GHOA Rheumatoid arthritis AVN	Pyrocarbon hemiarthroplasty of the shoulder	26 mo	Significant improvement in mean Constant scores and mean SANE scores At 2-year follow-up, 86% of patients showed no radiographic evidence of glenoid erosion.
Hudek et al. (2017) [65]	10	AVN	Pyrocarbon interposition arthroplasty of the shoulder	3.6 yr	Significant improvement in mean Constant scores and mean DASH scores Radiographic evidence of mild glenoid erosion, thinning of tuberosities, and superior displacement of implant was noted at follow-up.
Pangaud et al. (2020) [67]	1	GHOA	Pyrocarbon hemi-resurfacing of the shoulder	6 yr	Patient sustained a fracture of the pyrocarbon hemi-resurfacing implant without any history of obvious trauma or dislocation. Patient was revised to a rTSA.
Hirakawa et al. (2021) [17]	10	AVN GHOA with type B glenoids (on Walch classification) Severe secondary GHOA	Pyrocarbon interposition arthroplasty of the shoulder	5 yr	Five patients showed significant improvements in Constant and SSV scores but had a shorter follow up duration (35 mo). Remaining five patients (50%) were revised to an rTSA due to poor Constant and SSV scores.
Tsitlakidis et al. (2021) [63]	16	GHOA Rheumatoid arthritis AVN	Pyrocarbon hemiarthroplasty of the shoulder	24 mo	Prosthesis survival rate was 94%. Significant improvement in mean Constant scores and mean pain scores One patient was revised due to periprosthetic fracture.
Cointat et al. (2022) [16]	64	GHOA	Pyrocarbon hemiarthroplasty of the shoulder	33 mo	Prosthesis survival rate was 92%. Return to work rate was 91% and return to sport rate was 88%. Four patients were converted to rTSA, and one patient was converted to aTSA.
McBride et al. (2022) [66]	393	GHOA	Pyrocarbon hemi-resurfacing of the shoulder (163 patients) Metal hemi-resurfacing of the shoulder (163 patients) Metal stemmed hemiarthroplasty of the shoulder (67 patients)	6 yr	Revision rate was significantly lower for pyrocarbon hemi-resurfacing group (8.9%) when compared to metal hemi-resurfacing (17.1%) and metal stemmed hemiarthroplasty (17.5%). None of the pyrocarbon hemi-resurfacing cases underwent revision for glenoid erosion.

GHOA: glenohumeral osteoarthritis, AVN: avascular necrosis, SANE: Single Assessment Numeric Evaluation, DASH: Disabilities of the Arm, Shoulder and Hand, rTSA: reverse total shoulder arthroplasty, SSV: Subjective Shoulder Value, aTSA: anatomic total shoulder arthroplasty.

cern over the longevity of pyrocarbon implants in the shoulder [17]. Moreover, Pangaud et al. [67] reported a case of a pyrocarbon humeral head resurfacing implant fracture that occurred without any clear trauma or dislocation at 6 years post-implantation. The authors report that the patient presented with pain and pseudoparalysis before imaging studies confirmed fracture of the implant [67]. The report expressed concern regarding the fragility of the implant [67]. A summary of the reported studies is presented in Table 1 [16,17,63-67].

RECOMMENDATIONS

While *in vitro* research provides a strong basis for use of pyrocarbon implants, clinical results are limited. These implants show promise for young, physically active adults with AVN or humeral head arthrosis and a preserved glenoid. Pyrocarbon implants with ream and run may have future clinical use, though literature in this context is currently unavailable.

As such, additional research with longer-term follow-up is needed to assess the safety, durability, and clinical results of this implant. Large comparative studies and clinical trials should be conducted in order to determine the advantages of this treatment option compared to other common procedures for young patients with GHOA including traditional hemiarthroplasty, ream and run, and aTSA.

CONCLUSIONS

The concept behind the use of pyrocarbon in replacement procedures was to create a prosthesis that has better biocompatibility, survivorship, strength, and wear resistance compared to prostheses of other biomaterials. Pyrocarbon heads are made of a graphite core with pyrolytic carbon coating and have been used in orthopedics for over 50 years. While mostly associated with hand and wrist replacement procedures, pyrocarbon prostheses have been recently used in shoulder surgery, specifically shoulder hemiarthroplasty in young patients at risk of progressive glenoid wear.

Biomechanical and early clinical results suggest promising short-term survivorship, clinical outcomes, and limited glenoid wear. However, clinical studies have been limited to relatively small case series, and long-term outcomes are not yet available. As such, additional research on this technology is warranted to establish its role in the growing landscape of shoulder arthroplasty implants.

NOTES

ORCID

Mohamad Y. Fares <https://orcid.org/0000-0001-8228-3953>

Jaspal Singh <https://orcid.org/0000-0002-9662-0575>

Joseph A. Abboud <https://orcid.org/0000-0002-3845-7220>

Author contributions

Conceptualization: MYF, JS, PB, MRC, JAA. Investigation: MYF. Methodology: MYF. Supervision: JAA. Validation: JAA. Project administration: JAA. Writing – original draft: MYF, JS, PB, MRC. Writing – review & editing: MYF, JS, PB, MRC, JAA.

Conflict of interest

JAA would like to disclose the board member/committee appointments for American Shoulder and Elbow Society, Pacira. Additionally, financial support for this article is disclosed in the Funding section below. Apart from the disclosed financial support and the aforementioned board member/committee appointments, no other potential conflicts of interest relevant to this article have been reported.

Funding

JAA would like to disclose royalties from Djo Global, Zimmer-Biomet, Smith And Nephew, Stryker, Globus Medical, Inc.; research support as a PI from Lima Corporation - Italy, Orthofix, Arthrex, Oref; royalties or financial or material support from Wolters Kluwer.

Data availability

None.

Acknowledgments

None.

REFERENCES

1. Farley KX, Wilson JM, Kumar A, et al. Prevalence of shoulder arthroplasty in the United States and the increasing burden of revision shoulder arthroplasty. *JB JS Open Access* 2021;6:e20.00156.
2. Fonte H, Amorim-Barbosa T, Diniz S, Barros L, Ramos J, Claro R. Shoulder arthroplasty options for glenohumeral osteoarthritis in young and active patients (< 60 years old): a systematic review. *J Shoulder Elb Arthroplast* 2022;6:24715492221087014.
3. Best MJ, Aziz KT, Wilckens JH, McFarland EG, Srikumaran U. Increasing incidence of primary reverse and anatomic total

- shoulder arthroplasty in the United States. *J Shoulder Elbow Surg* 2021;30:1159–66.
4. Weber S, Grehn H, Hutter R, Sommer C, Haupt S. Shoulder arthroplasty for proximal humeral fracture treatment: a retrospective functional outcome analysis. *Eur J Orthop Surg Traumatol* 2023;33:1581-9.
 5. Na SS, Kim DH, Choi BC, Cho CH. Outcomes and complications after arthroplasty in patients with osteonecrosis of humeral head- systematic review. *J Orthop Sci* 2023;28:772-7.
 6. Nielsen KP, Amundsen A, Olsen BS, Rasmussen JV. Good long-term patient-reported outcome after shoulder arthroplasty for cuff tear arthropathy. *JSES Int* 2021;6:40–3.
 7. Radnay CS, Setter KJ, Chambers L, Levine WN, Bigliani LU, Ahmad CS. Total shoulder replacement compared with humeral head replacement for the treatment of primary glenohumeral osteoarthritis: a systematic review. *J Shoulder Elbow Surg* 2007;16:396–402.
 8. Bryant D, Litchfield R, Sandow M, Gartsman GM, Guyatt G, Kirkley A. A comparison of pain, strength, range of motion, and functional outcomes after hemiarthroplasty and total shoulder arthroplasty in patients with osteoarthritis of the shoulder: a systematic review and meta-analysis. *J Bone Joint Surg Am* 2005;87:1947–56.
 9. Carroll RM, Izquierdo R, Vazquez M, Blaine TA, Levine WN, Bigliani LU. Conversion of painful hemiarthroplasty to total shoulder arthroplasty: long-term results. *J Shoulder Elbow Surg* 2004;13:599–603.
 10. Leung B, Horodyski M, Struk AM, Wright TW. Functional outcome of hemiarthroplasty compared with reverse total shoulder arthroplasty in the treatment of rotator cuff tear arthropathy. *J Shoulder Elbow Surg* 2012;21:319–23.
 11. Dines JS, Fealy S, Strauss EJ, et al. Outcomes analysis of revision total shoulder replacement. *J Bone Joint Surg Am* 2006; 88:1494–500.
 12. Geervliet PC, Willems JH, Sierevelt IN, Visser CP, van Noort A. Overstuffing in resurfacing hemiarthroplasty is a potential risk for failure. *J Orthop Surg Res* 2019;14:474.
 13. Peker B, Polat AE, Carkci E, Senel A, Soydan C, Tuzuner T. Functional outcomes and complication analysis of plate osteosynthesis versus hemiarthroplasty in three-part and four-part proximal humerus fractures. *J Pak Med Assoc* 2022;72:57–61.
 14. Familiari F, Hochreiter B, Gerber C. Unacceptable failure of osteochondral glenoid allograft for biologic resurfacing of the glenoid. *J Exp Orthop* 2021;8:111.
 15. Sperling JW, Cofield RH, Rowland CM. Minimum fifteen-year follow-up of Neer hemiarthroplasty and total shoulder arthroplasty in patients aged fifty years or younger. *J Shoulder Elbow Surg* 2004;13:604–13.
 16. Cointat C, Raynier JL, Vasseur H, et al. Short-term outcomes and survival of pyrocarbon hemiarthroplasty in the young arthritic shoulder. *J Shoulder Elbow Surg* 2022;31:113–22.
 17. Hirakawa Y, Ode GE, Le Coz P, et al. Poor results after pyrocarbon interpositional shoulder arthroplasty. *J Shoulder Elbow Surg* 2021;30:2361–9.
 18. Campos-Pereira E, Henrique-Barros L, Claro R. Pyrocarbon humeral head in a shoulder hemiarthroplasty: preliminary results at 3 years follow-up and review of the current literature. *Case Rep Orthop* 2021;2021:6633690.
 19. Mehta N, Hall DJ, Pourzal R, Garrigues GE. The biomaterials of total shoulder arthroplasty: their features, function, and effect on outcomes. *JBS Rev* 2020;8:e1900212.
 20. Ramírez-Martínez I, Smith SL, Trail IA, Joyce TJ. Wear behaviour of polyethylene glenoid inserts against PyroCarbon humeral heads in shoulder arthroplasties. *J Mech Behav Biomed Mater* 2020;103:103553.
 21. Stone MA, Noorzad AS, Namdari S, Abboud J. Prosthetic bearing surfaces in anatomic and reverse total shoulder arthroplasty. *J Am Acad Orthop Surg* 2021;29:414–22.
 22. Edwards TB, Kadakia NR, Boulahia A, et al. A comparison of hemiarthroplasty and total shoulder arthroplasty in the treatment of primary glenohumeral osteoarthritis: results of a multicenter study. *J Shoulder Elbow Surg* 2003;12:207–13.
 23. Somerson JS, Neradilek MB, Service BC, Hsu JE, Russ SM, Matsen FA 3rd. Clinical and radiographic outcomes of the ream-and-run procedure for primary glenohumeral arthritis. *J Bone Joint Surg Am* 2017;99:1291–304.
 24. Somerson JS, Matsen FA 3rd. Functional outcomes of the ream-and-run shoulder arthroplasty: a concise follow-up of a previous report. *J Bone Joint Surg Am* 2017;99:1999–2003.
 25. Getz CL, Kearns KA, Padegimas EM, Johnston PS, Lazarus MD, Williams GR Jr. Survivorship of hemiarthroplasty with concentric glenoid reaming for glenohumeral arthritis in young, active patients with a biconcave glenoid. *J Am Acad Orthop Surg* 2017;25:715–23.
 26. Schoch B, Schleck C, Cofield RH, Sperling JW. Shoulder arthroplasty in patients younger than 50 years: minimum 20-year follow-up. *J Shoulder Elbow Surg* 2015;24:705–10.
 27. Gadea F, Alami G, Pape G, Boileau P, Favard L. Shoulder hemiarthroplasty: outcomes and long-term survival analysis according to etiology. *Orthop Traumatol Surg Res* 2012;98:659–65.
 28. Hackett DJ Jr, Hsu JE, Matsen FA 3rd. Primary shoulder hemiarthroplasty: what can be learned from 359 cases that were surgically revised. *Clin Orthop Relat Res* 2018;476:1031–40.
 29. Herschel R, Wieser K, Morrey ME, Ramos CH, Gerber C, Mey-

- er DC. Risk factors for glenoid erosion in patients with shoulder hemiarthroplasty: an analysis of 118 cases. *J Shoulder Elbow Surg* 2017;26:246–52.
30. Parsons IM 4th, Millett PJ, Warner JJ. Glenoid wear after shoulder hemiarthroplasty: quantitative radiographic analysis. *Clin Orthop Relat Res* 2004;(421):120–5.
 31. Hegyeli RJ. Artificial heart program conference: proceedings; Washington, D.C., June 9-13, 1969. National Institutes of Health; 1969.
 32. Stanley J, Klawitter J, More R. Replacing joints with pyrolytic carbon. In: Revell PA, ed. *Joint replacement technology*. Elsevier; 2008. p. 631–56.
 33. Black J, Hastings G. *Handbook of biomaterial properties*. Springer Science & Business Media; 2013.
 34. Bokros JC. Carbon biomedical devices. *Carbon* 1977;15:353–71.
 35. Ely JL, Emken MR, Accuntius JA, et al. Pure pyrolytic carbon: preparation and properties of a new material, On-X carbon for mechanical heart valve prostheses. *J Heart Valve Dis* 1998;7:626–32.
 36. More RB, Haubold AD, Bokros JC. Pyrolytic carbon for long-term medical implants. In: Ratner B, Hoffman A, Schoen F, Lemons J, eds. *Biomaterials science*. Elsevier; 2013. p. 209–22.
 37. Bellemère P. Pyrocarbon implants for the hand and wrist. *Hand Surg Rehabil* 2018;37:129–54.
 38. Bokros JC. Deposition, structure, and properties of pyrolytic carbon. In: Walker PL, ed. *Chemistry and physics of carbon*. Vol. 5. Dekker; 1969. p. 1–118.
 39. Kaae JL. The mechanism of the deposition of pyrolytic carbons. *Carbon* 1985;23:665–73.
 40. Gilpin CB, Haubold AD, Ely JL. Fatigue crack growth and fracture of pyrolytic carbon composites. *Bioceramics* 1993;6:217–23.
 41. Ma L, Sines G. Fatigue behavior of a pyrolytic carbon. *J Biomed Mater Res* 2000;51:61–8.
 42. Haubold AD, More RB, Bokros JC. Carbons. In: Black J, Hastings G, eds. *Handbook of biomaterial properties*. Elsevier; 1998. p. 464–77.
 43. More RB, Sines G, Ma L, Bokros JC. Pyrolytic carbon. In: Wnek GE, Bowlin GL, eds. *Encyclopedia of biomaterials and biomedical engineering*. CRC Press; 2004. p. 1308–19.
 44. Haubold AD. On the durability of pyrolytic carbon in vivo. *Med Prog Technol* 1994;20:201–8.
 45. Bokros JC, Haubold AD, Akins RJ, Campbell LA, Griffin CD, Lane E. The durability of mechanical heart valve replacements: past experience and current trends. In: Bodnar E, Frater R, eds. *Replacement cardiac valves*. Pergamon Press; 1991. p. 21–48.
 46. Schoen FJ. Carbons in heart valve prostheses: foundations and clinical performance. In: Szycher M, ed. *Biocompatible polymers, metals, and composites*. Technomic Publishing Company; 1983. p. 240–61.
 47. Lubowitz JH. Editorial Commentary: Shoulder arthroscopy, shoulder hemiarthroplasty, and total shoulder arthroplasty for glenohumeral osteoarthritis. *Arthroscopy* 2015;31:1167–8.
 48. Pfahler M, Jena F, Neyton L, Sirveaux F, Molé D. Hemiarthroplasty versus total shoulder prosthesis: results of cemented glenoid components. *J Shoulder Elbow Surg* 2006;15:154–63.
 49. Sandow MJ, David H, Bentall SJ. Hemiarthroplasty vs total shoulder replacement for rotator cuff intact osteoarthritis: how do they fare after a decade. *J Shoulder Elbow Surg* 2013;22:877–85.
 50. Nho SJ, Nam D, Ala OL, Craig EV, Warren RF, Wright TM. Observations on retrieved glenoid components from total shoulder arthroplasty. *J Shoulder Elbow Surg* 2009;18:371–8.
 51. Cook SD, Beckenbaugh R, Weinstein AM, Klawitter JJ. Pyrolytic carbon implants in the metacarpophalangeal joint of baboons. *Orthopedics* 1983;6:952–61.
 52. Hannoun A, Ouenzerfi G, Brizuela L, et al. Pyrocarbon versus cobalt-chromium in the context of spherical interposition implants: an in vitro study on cultured chondrocytes. *Eur Cell Mater* 2019;37:1–15.
 53. Hussain N, Couzens G, Gilpin D, Ross M. Pyrocarbon PIPJ and MCPJ hemiarthroplasty. In: *Proceedings of the 9th Congress of the International Federation of Societies for Surgery of the Hand*; 2004 Jun 13-17; Budapest, Hungary. Medimond Publishing; 2004.
 54. Klawitter JJ, Patton J, More R, Peter N, Podnos E, Ross M. In vitro comparison of wear characteristics of PyroCarbon and metal on bone: shoulder hemiarthroplasty. *Shoulder Elbow* 2020; 12(1 Suppl):11–22.
 55. Ross M, Williams D, Couzens G, Klawitter J. Pyrocarbon for joint replacement. In: Revell PA, ed. *Joint replacement technology*. Elsevier; 2021. p. 145–63.
 56. Swanson AB. Silicone rubber implants for replacement of arthritis or destroyed joints in the hand. *Surg Clin North Am* 1968;48:1113–27.
 57. Caudwell M, Bayne G, Page RS. Anatomic pyrocarbon hemiarthroplasty for thumb carpometacarpal osteoarthritis in patients under 65 years: mid term results. *J Hand Surg Asian Pac Vol* 2018;23:469–73.
 58. Pettersson K, Amilon A, Rizzo M. Pyrolytic carbon hemiarthroplasty in the management of proximal interphalangeal joint arthritis. *J Hand Surg Am* 2015;40:462–8.
 59. Vitale MA, Hsu CC, Rizzo M, Moran SL. Pyrolytic carbon arthroplasty versus suspensionplasty for trapezium-metacarpal ar-

- thrititis. *J Wrist Surg* 2017;6:134–43.
60. Smeraglia F, Basso MA, Famiglietti G, Cozzolino A, Balato G, Bernasconi A. Pyrocardan[®] interpositional arthroplasty for trapeziometacarpal osteoarthritis: a minimum four year follow-up. *Int Orthop* 2022;46:1803–10.
 61. Szalay G, Meyer C, Scheufens T, Schnettler R, Christ R, Schleicher I. Pyrocarbon spacer as a trapezium replacement for arthritis of the trapeziometacarpal joint: a follow-up study of 60 cases. *Acta Orthop Belg* 2013;79:648–54.
 62. Bernasek TL, Stahl JL, Pupello D. Pyrolytic carbon endoprosthetic replacement for osteonecrosis and femoral fracture of the hip: a pilot study. *Clin Orthop Relat Res* 2009;467:1826–32.
 63. Tsitlakidis S, Doll J, Westhauser F, et al. Promising results after hemi-shoulder arthroplasty using pyrolytic carbon heads in young and middle-aged patients. *Orthop Traumatol Surg Res* 2021;107:102896.
 64. Garret J, Godeneche A, Boileau P, et al. Pyrocarbon interposition shoulder arthroplasty: preliminary results from a prospective multicenter study at 2 years of follow-up. *J Shoulder Elbow Surg* 2017;26:1143–51.
 65. Hudek R, Werner B, Abdelkawi AF, Gohlke F. Pyrocarbon interposition shoulder arthroplasty in advanced collapse of the humeral head. *Orthopade* 2017;46:1034–44.
 66. McBride AP, Ross M, Hoy G, et al. Mid-term outcomes of pyrolytic carbon humeral resurfacing hemiarthroplasty compared with metal humeral resurfacing and metal stemmed hemiarthroplasty for osteoarthritis in young patients: analysis from the Australian Orthopaedic Association National Joint Replacement Registry. *J Shoulder Elbow Surg* 2022;31:755–62.
 67. Pangaud C, Gonzalez JF, Galvin JW, Gauci MO, Boileau P. Fracture of pyrocarbon humeral head resurfacing implant: a case report. *J Shoulder Elbow Surg* 2020;29:e306–12.