

세포교정영양요법(OCNT)을 이용한 고혈압 및 탈모 개선 사례 연구

김호진 약사

경기도 수원시 영통구 태장로 84 슬림약국

A Case Study on the Improvement in Hypertension and Hair Loss Patient Using Ortho-Cellular Nutrition Therapy (OCNT)

Pharmacist, Hochin Kim

Slim Pharmacy, 84, Taejang-ro, Yeongtong-gu, Suwon-si, Gyeonggi-do, Republic of Korea

ABSTRACT

Objective: A case study on alleviating hypertension-related symptoms and hair loss through Ortho-Cellular Nutrition Therapy (OCNT).

Methods: A 58-year-old male patient, suffering from hypertension and hair loss, was treated with OCNT.

Results: After applying OCNT, a reduction in blood pressure and improved hair loss symptoms were observed.

Conclusion: The application of OCNT can be beneficial in mitigating hypertension and hair loss.

Keywords Ortho-Cellular Nutrition Therapy (OCNT), hypertension, hair loss, hair transplantation

INTRODUCTION

Hypertension is a condition where systolic and diastolic blood pressures exceed 140/90 mmHg, as measured by arterial pressure. In South Korea, it is estimated that over 11 million people suffer from hypertension, with a rapidly increasing prevalence among the elderly.¹

Hypertension has various causes, including smoking, obesity, family history, and lifestyle habits, yet optimal treatment strategies considering these factors have not been fully established.^{2,3}

Androgenetic alopecia, also known as pattern hair loss, is a common cause of non-scarring alopecia affecting over 80% of men across all ethnicities, starting from adolescence. Typically, men exhibit thinning and hair loss primarily at the frontal and vertex areas.

These symptoms can be diagnosed through patient history and trichoscopy⁴ and addressed through medications or hair transplantation. Although hair transplantation is a relatively safe procedure with a low risk of complications, appropriate preoperative consultation and postoperative care tailored to the patient's medical history and conditions are crucial to minimize complications and dissatisfaction.⁵ However, further research is

needed to reduce such complications.

The patient in this case study experienced an improvement in symptoms of hypertension and hair loss following a prescription of OCNT.

CASE STUDY

1. Subject

The case involves a patient suffering from hypertension and hair loss.

- 1) Name: Kim OO (M/58 years old)
- 2) Diagnosis: Hypertension, hair loss
- 3) Onset date: Early 2023.
- 4) Treatment duration: December, 2023 ~ Present.
- 5) Main symptoms: Hair loss, facial redness
- 6) Social history: Prior experience with smoking and drinking.
- 7) Family history: None
- 8) Medications and procedures: Hair transplantation, Momota (Dutasteride 0.5 mg)

2. Methods

From December 2023, the following OCNT was applied according to symptoms:

- OCNT for Hypertension

Cyaplex X (202, twice a day, two capsules per intake)

Eufaplex Alpha (101, twice a day, one sachet per intake)

Hwapyeongwon granule (101, twice a day, one sachet per intake)

Supplements containing minerals and arginine were also administered in addition to the aforementioned OCNT.

*Correspondence: Hochin Kim

E-mail: chiny91@hanmail.net

Received Apr 30, 2024; Accepted Apr 30, 2024; Published Apr 30, 2024

doi: <http://dx.doi.org/10.5667/CellMed.spc.075>

©2024 by CellMed Orthocellular Medicine Pharmaceutical Association

This is an open access article under the CC BY-NC license.

<http://creativecommons.org/licenses/by-nc/3.0/>

† This report has been translated and edited by the CellMed editor-in-chief, Prof. Beom-Jin Lee.

- OCNT for Hair Loss
Oral Application
Morangmorang booster capsule (101, twice a day, one capsule per intake)
- Topical Application
Cyaplex Scalpare Tonic (sprayed twice or third time a day on scalp)
Cyaplex Scalp Revitalizing Shampoo (once a day)

pressure, and to stabilize it, Cyaplex X, Eufaplex Alpha, and Hwapyeongwon granule were prescribed.

The anthocyanin in Cyaplex X is known for its potent antioxidant and anti-inflammatory effects, which also contribute to vascular protection and activation.⁶ Omega-3 fatty acids and alpha-linolenic acid in Eufaplex Alpha are known to inhibit thrombus formation^{7,8}, thereby aiding in blood pressure reduction.

After stabilizing the blood pressure, OCNT for hair loss symptoms was implemented. The patient had been taking Dutasteride following hair transplantation. The prescribed

OCNT included oral intake of Morangmorang booster capsules and topical application of Cyaplex Scalp Revitalizing Shampoo and Cyaplex Scalpare Tonic.

Methylsulfonylmethane (MSM) in Morangmorang booster capsules, shampoo, and tonic strengthens the keratin bonds in hair and nails, making hair thicker and more robust.⁹ Menthol in the shampoo and tonic aids in soothing the skin and enhances the penetration of medicinal ingredients¹⁰, while dexpanthenol is known for its anti-inflammatory and antioxidant properties that protect cells and promote hair growth.¹¹

Dutasteride is widely used for treating male pattern baldness, but it has side effects like decreased libido and erectile dysfunction.¹² Hair transplantation is a common hair loss treatment technique but requires continuous follow-up and postoperative care.¹³ Studies suggest that treatments using natural ingredients generally have a lower risk of side effects¹⁴, indicating that nutrition therapy based on natural ingredients can minimize patient discomfort.

This case study focuses on a single patient and may not universally apply to all patients with hypertension or hair loss. However, the symptoms were effectively improved after OCNT was implemented. Therefore, this case is reported with the patient's consent.

RESULTS

One month after implementing OCNT for hypertension, the patient's blood pressure returned to normal ranges (Fig. 1). Additionally, improvements were noted in the facial redness.

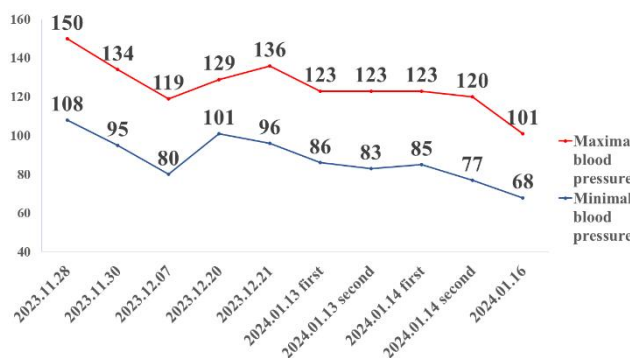


Fig. 1. Changes in patient's blood pressure following OCNT application. It demonstrates blood pressure's return to normal levels after the OCNT application.

Following the prescribed nutrition therapy for hair loss, gradual hair regrowth was observed at the vertex region over monthly evaluations (Fig. 2). Moreover, one month after starting the OCNT, the patient reduced his dosage of Dutasteride from once a day to once weekly.

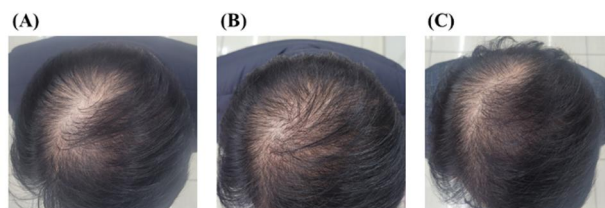

Fig. 2. Hair status at the vertex before and after nutrition therapy implementation: (A) before treatment, (B) one month after, and (C) two months after

DISCUSSION

This case involves a patient concerned with symptoms of hypertension and hair loss for which OCNT was initiated. Initially, the patient sought consultation due to high blood

REFERENCES

1. Jeong J-W, Shin G, Kim DS, et al. Korea hypertension fact sheet 2018. *Clinical Hypertension*. 2018;10/01 2018;24(1):13. doi:10.1186/s40885-018-0098-0
2. Current status and therapeutic considerations of hypertension in the elderly FAU - Lee, Ju-Hee FAU - Kim, Kwang-Il FAU - Cho, Myeong-Chan. *Korean J Intern Med*. 7 2019;34(4):687-695. doi:10.3904/kjim.2019.196
3. Jordan J, Kurschat C, Reuter H. Arterial Hypertension. *Dtsch Arztebl Int*. Aug 20 2018;115(33-34):557-568. doi:10.3238/arztebl.2018.0557

A Case Study on the Improvement in Hypertension and Hair Loss Patient Using Ortho-Cellular Nutrition Therapy (OCNT)

4. Kuczara A, Waškiel-Burnat A, Rakowska A, Olszewska M, Rudnicka L. Trichoscopy of Androgenetic Alopecia: A Systematic Review. *J Clin Med*. Mar 28 2024;13(7)doi:10.3390/jcm13071962
5. Salantri S, Gonçalves AJ, Helene A, Jr., Junqueira Lopes FH. Surgical Complications in Hair Transplantation: A Series of 533 Procedures. *Aesthetic Surgery Journal*. 2009;29(1):72-76. doi:10.1016/j.asj.2008.11.005
6. Jurikova T, Mlcek J, Skrovankova S, et al. Fruits of Black Chokeberry *Aronia melanocarpa* in the Prevention of Chronic Diseases. *Molecules*. Jun 7 2017;22(6)doi:10.3390/molecules22060944
7. Jain A, Aggarwal K, Zhang P. Omega-3 fatty acids and cardiovascular disease. *Eur Rev Med Pharmacol Sci*. 2015;19(3):441-5.
8. Bertoni C, Abodi M, D'Oria V, Milani GP, Agostoni C, Mazzocchi A. Alpha-Linolenic Acid and Cardiovascular Events: A Narrative Review. *International Journal of Molecular Sciences*. 2023;24(18):14319.
9. Muizzuddin N, Benjamin R. Beneficial effects of a sulfur-containing supplement on hair and nail condition. *Nat Med J*. 2019;11
10. Kamatou GP, Vermaak I, Viljoen AM, Lawrence BM. Menthol: a simple monoterpene with remarkable biological properties. *Phytochemistry*. 2013;96:15-25.
11. Kutlu Ö. Dexpanthenol may be a novel treatment for male androgenetic alopecia: Analysis of nine cases. *Dermatologic Therapy*. 2020;33(3):e13381.
12. Hirshburg JM, Kelsey PA, Therrien CA, Gavino AC, Reichenberg JS. Adverse Effects and Safety of 5-alpha Reductase Inhibitors (Finasteride, Dutasteride): A Systematic Review. *J Clin Aesthet Dermatol*. Jul 2016;9(7):56-62.
13. Perez-Meza D, Niedbalski R. Complications in hair restoration surgery. *Oral and maxillofacial surgery clinics of North America*. 2009;21(1):119-148.
14. Lee JY, Jun SA, Hong SS, Ahn YC, Lee DS, Son CG. Systematic review of adverse effects from herbal drugs reported in randomized controlled trials. *Phytotherapy Research*. 2016;30(9):1412-1419.