








Treatment outcome and long-term stability of orthognathic surgery for facial asymmetry: A systematic review and meta-analysis

Yoon-Ji Kim^a 
Moon-Young Kim^b 
Nayansi Jha^a 
Min-Ho Jung^{c,d} 
Yong-Dae Kwon^e 
Ho Gyun Shin^f 
Min Jung Ko^f 
Sang Ho Jun^g 

^aDepartment of Orthodontics, Asan Medical Center, University of Ulsan College of Medicine, Seoul, Korea

^bDepartment of Oral and Maxillofacial Surgery, College of Dentistry, Dankook University, Cheonan, Korea

^cDepartment of Orthodontics, Dental Research Institute and School of Dentistry, Seoul National University, Seoul, Korea

^dPrivate Practice, Seoul, Korea

^eDepartment of Oral and Maxillofacial Surgery, College of Dentistry, Kyung Hee University, Seoul, Korea

^fDivision of Healthcare Technology Assessment Research, National Evidence-based Healthcare Collaborating Agency, Seoul, Korea

^gDepartment of Oral and Maxillofacial Surgery, Korea University Anam Hospital, Seoul, Korea

Objective: This systematic review aimed to provide a comparative analysis of the treatment outcomes, including hard and soft tissues, postoperative stability, temporomandibular disorders (TMD), and quality of life (QoL), in patients with facial asymmetry who underwent orthognathic surgery. **Methods:** The primary objective was to address the question, "How do different factors related to surgery affect the outcomes and stability of orthognathic surgery in the correction of facial asymmetry?" A meta-analysis was conducted on the outcome parameters, such as skeletal, dental, and soft tissue symmetry, TMD, QoL, and relapse, using the Hartung–Knapp–Sidik–Jonkman method for random-effects models. Subgroup analyses were conducted considering surgery-related factors such as surgical techniques (one-jaw vs. two-jaw), use of the surgery-first approach, utilization of computer simulation, and analytical methods employed to evaluate asymmetry (2D vs. 3D). **Results:** Forty-nine articles met the inclusion criteria. The meta-analysis demonstrated a significant improvement in the symmetry of hard and soft tissues. The subgroup analysis indicated that the treatment outcomes showed significant improvement, regardless of the factors related to surgery. Changes in TMD signs and symptoms varied according to the surgical technique used. Quality of life improved in the facial, oral, and social domains. Skeletal relapse was observed during the follow-up. **Conclusions:** Our findings support the positive outcomes of orthognathic surgery in the treatment of facial asymmetry in terms of skeletal and soft tissue improvements, stability, relief of TMD symptoms, and enhancement of QoL. However, most of the included studies showed a low certainty of evidence and high heterogeneity.

Key words: Facial asymmetry, Orthognathic surgery, Temporomandibular joint disorder, Surgical stability

Received September 27, 2023; Revised December 14, 2023; Accepted January 18, 2024.

Corresponding author: Sang Ho Jun.

Clinical Professor, Department of Oral and Maxillofacial Surgery, Korea University Anam Hospital, 73 Goryeodae-ro, Seongbuk-gu, Seoul 02841, Korea.

Tel +82-2-920-6770 e-mail junsang@korea.ac.kr

Corresponding author: Min Jung Ko.

Senior Research Fellow, Division of Healthcare Technology Assessment Research, National Evidence-based Healthcare Collaborating Agency, 400 Neungdong-ro, Gwangjin-gu, Seoul 04933, Korea.

Tel +82-2-2174-2731 e-mail minjung.ko@neca.re.kr

Yoon-Ji Kim and Moon-Young Kim contributed equally to this work (as co-first authors).

How to cite this article: Kim YJ, Kim MY, Jha N, Jung MH, Kwon YD, Shin HG, Ko MJ, Jun SH. Treatment outcome and long-term stability of orthognathic surgery for facial asymmetry: A systematic review and meta-analysis. Korean J Orthod 2024;54(2):89-107. https://doi.org/10.4041/kjod23.194

© 2024 The Korean Association of Orthodontists.

This is an Open Access article distributed under the terms of the Creative Commons Attribution Non-Commercial License (<http://creativecommons.org/licenses/by-nc/4.0>) which permits unrestricted non-commercial use, distribution, and reproduction in any medium, provided the original work is properly cited.

INTRODUCTION

Facial asymmetry is characterized by notable disparities in size, shape, and positioning of features between the right and left sides of the face. The etiology of facial asymmetry is multifactorial, involving genetic, functional, and environmental factors during growth,^{1,2} and the reported prevalence thereof ranges from 11% to 37%,³ with a higher prevalence (21–67%) observed in individuals with malocclusions, particularly Class III.^{4–7}

Most people have some degree of skeletal asymmetry, which is considered normal, and it may be compensated for by soft tissues, dental occlusion, and head posture.⁸ However, a deviation exceeding 3–4 mm in the soft tissue menton region may be perceived by laypeople and elicit psychological implications.^{1,2} Patients with facial asymmetry commonly exhibit concomitant malocclusion, compromised masticatory functions, speech impairments, and temporomandibular joint (TMJ) dysfunction.

Considerable progress in surgical techniques has revolutionized the treatment approach for facial asymmetry, supplanting the previous reliance on orthodontic camouflage with more stable and esthetically pleasing outcomes. Leveraging digital advancements such as computer-aided design and manufacturing technologies enables the utilization of surgical simulations, thereby enhancing the predictability of treatment outcomes and patient satisfaction.

While numerous studies have explored orthognathic terms of diagnosis, surgical technique, and surgical outcome for facial asymmetry, a comprehensive systematic review of the impact of a range of factors on treatment outcomes remains lacking. These factors include surgical techniques (one- vs. two-jaw), surgical protocols (surgery-first approach [SFA] vs. conventional approach), implementation of surgical simulation techniques, and analytical methods (two-dimensional [2D] vs. three-dimensional [3D]). We, therefore, aimed to provide a comparative analysis of treatment outcomes encompassing hard and soft tissues, postoperative stability, temporomandibular disorder (TMD) signs and symptoms, and quality of life (QoL).

MATERIALS AND METHODS

This systematic review adhered to the 2020 Preferred Reporting Items for Systematic Reviews and Meta-Analyses⁹ (Supplementary Table 1). The study was registered in the PROSPERO Registry of Systematic Reviews/Meta-Analyses in Research (registration number: CRD42022384509). The primary objective was to address the question, “How do different factors related to surgery affect the outcomes and stability of orthognathic surgery in the correction of facial asymmetry?” The

research question was structured according to the Population, Intervention, Comparison, Outcomes, Time, and Study type framework (Table 1). The specific outcome parameters are shown in Table 2.

Information sources and search strategy

The search strategy included relevant English databases, including Ovid-Medline, Ovid Embase, and the Cochrane Central Register of Controlled Trials, and Korean databases, such as KoreaMed and KMBase. The search terms were derived from those employed in Ovid-Medline and search functions, including controlled vocabulary (MeSH and Emtree), text words, logical operators, and truncation, were appropriately applied considering the characteristics of each database. The search was limited to the literature published between January 2000 and June 2023 in English and Korean (Supplementary Table 2).

Eligibility criteria, study selection, and data collection

We included original studies published in scientific journals with the full text available. We included studies as follows: those involving patients with facial asymmetry aged 18 years or older, focusing on orthognathic surgery, reporting one or more predefined outcomes, and conforming to a predetermined study design. We excluded non-original articles (reviews, editorials, letters, comments, abstracts, duplicate research); studies addressing the treatment of pathological conditions such as condylar hyperplasia; studies concerning the treatment of congenital facial deformities such as hemifacial microsomia and cleft lip and palate; documents not published in peer-reviewed journals (gray literature, abstracts, etc.); and studies not published in Korean. Two

Table 1. Description of PICOTS framework

PICOTS framework	Details
Population	Facial asymmetry patients
Intervention	Orthognathic surgery
Comparison	Untreated subjects
Outcomes	Skeletal symmetry, midline discrepancies, lip canting, temporomandibular disorders, quality of life, relapse
Time	No limitation
Study type	Randomized clinical study, non-randomized clinical study (cohort study, case-control study, cross-sectional study), patient group study (case-series)

PICOTS, population, intervention, comparison, outcome, time, and study type.

Table 2. Definition of outcome variables

Outcome variables	Definition
Skeletal symmetry	Linear and angular measurements of the anatomic landmarks of the facial skeleton using radiographs for assessment of facial asymmetry
Menton deviation	Distance from the menton of the mandible to the midsagittal reference plane
Maxillary canting	Angle between the maxillary plane and the horizontal reference plane
Frontal ramal inclination*	Angle between the midsagittal reference line and the line connecting the most lateral point of the condylar head and gonion in the frontal plane
Ramus height*	Distance from the condylyon to gonion
Body length*	Distance from the gonion to menton
Midline discrepancies	Deviation of upper and lower dental midline from the midsagittal reference line; midline discrepancy between the upper and the lower dentition
Lip canting	The angle between the line where the upper and lower lips meet and the horizontal reference line
TMD	Signs and symptoms related to TMD
Quality of life	Quality of life related to surgical treatment of facial asymmetry
Relapse	Change of more than 1 mm in the menton deviation after surgery

TMD, temporomandibular disorders.

*Differences between right and left measurements were analyzed.

reviewers (YJK and MYK) independently conducted the literature selection process based on the predetermined inclusion and exclusion criteria. Inter-rater agreement was assessed using Cohen's kappa statistic, which yielded a substantial agreement coefficient of 0.801. In cases of disagreement, a final selection of literature was made through discussions involving the entire research team.

Data extraction

Pilot data extraction was performed in several studies to standardize the process and enhance consistency between reviewers. Subsequently, two independent reviewers extracted data from the selected studies into a standardized form. Disagreements between the two reviewers were resolved by rechecking the data and further discussions with the clinical advisory committee.

The extracted data included (a) study characteristics (authors, year of publication, study design, period, and the number and location of research centers), (b) study population (inclusion/exclusion criteria, number of participants included/dropped out, sex, age, and type of dentoskeletal malocclusion), (c) methods (surgical techniques, use of SFA, computer simulation, analytic methods [2D vs. 3D] to assess asymmetry), (d) values of outcome variables, and (e) follow-up duration.

Risk of bias assessment

The methodological quality rating was determined using the Newcastle-Ottawa Scale (NOS) to assess the quality of non-randomized studies in the meta-analyses. Studies received one or two stars within each NOS cat-

egory. A study with a score of ≥ 7 was considered high quality, those scoring 4–6 were considered moderate quality, and studies scoring < 4 were categorized as low quality. A critical assessment of the studies was conducted by two reviewers, and any discrepancies were resolved by a third.

Certainty of evidence assessment

We used the Grading of Recommendations, Assessment, Development, and Evaluation¹⁰ to evaluate the quality of evidence of the studies in which the meta-analysis was performed. Each outcome was rated based on the quality of evidence as high, moderate, low, or very low within five domains: risk of bias, imprecision, inconsistency, indirectness, and other biases.

Statistical analysis

The meta-analysis was conducted using the Hartung-Knapp-Sidik-Jonkman method, which is a random-effects model. Heterogeneity among the studies was assessed using the I^2 statistic, indicating the proportion of the total variation attributed to heterogeneity rather than chance. Heterogeneity was categorized as low (25–50%), intermediate (50–75%), or high (75–100%).

In cases of high heterogeneity, the effect estimate was reported as the standardized mean difference (SMD) or mean difference. To explore potential sources of heterogeneity, subgroup and sensitivity analyses were performed on studies exhibiting moderate or high heterogeneity. These analyses utilized predefined variables to investigate the factors contributing to heterogeneity.

Subgroup analyses were conducted to improve overall skeletal symmetry, which included all outcomes of skeletal symmetry and menton deviation considering surgery-related factors, such as the surgical techniques (one- vs. two-jaw), the use of SFA, utilization of computer simulation, and the analytical methods employed to evaluate asymmetry (2D vs. 3D). Skeletal relapse was evaluated by examining the SMDs of the overall skeletal symmetry from immediately after surgery to the follow-up periods of < 3, 3–12, and > 12 months. Additionally, relapse of menton deviation was observed for follow-up periods of < 3 months and > 3 months.

Standardized mean differences for the upper and lower dental midlines, midline discrepancies between the upper and lower dentition, and lip canting were assessed. The prevalence of signs and symptoms of TMD before and after surgery were analyzed. Quality of life was examined. Publication bias was assessed using funnel plots and Egger’s test.¹¹ Statistical analyses were performed using R (version 3.6.3, <http://cran.r-project.org/>) and comprehensive meta-analysis (version 3.3.070). Statistical significance was defined as $P < 0.05$.

RESULTS

Study selection

A comprehensive database search yielded 2,928 articles, including 2,694 in English and 234 in Korean. After removing duplicate studies, 2,175 articles remained for further evaluation based on the selection criteria.

Through a rigorous review process, 168 articles were selected based on their titles and abstracts, and a final set of 49 articles were included after a thorough examination of the full texts (Figure 1).

Risk of bias assessment of the included studies

Supplementary Table 3 summarizes the NOS results. Most of the studies were assessed as moderate quality,^{12–48} while a few were assessed as high quality.^{14,49–62} The studies were classified as high quality when the comparability of cohorts was appropriately addressed based on the study design or analysis.

Certainty of evidence assessment

The outcome parameters of the studies included in the meta-analysis were examined. Factors such as risk of bias, indirectness, inconsistency, and imprecision were not serious issues. The certainty of evidence regarding menton deviation is very low, owing to publication bias. However, publication bias did not significantly affect the results of menton deviation analysis. Certainty was low for other outcomes (Supplementary Table 4).

Characteristics of included studies

The meta-analysis included 1,796 participants. The publication timeline revealed 1 article from 2003 and 8 articles from 2019, and a significant proportion (51%) of the studies were published within the last 5 years (2019–2023). The studies originated from various countries: 19 from South Korea, 12 from Taiwan, 9 from Japan, 7

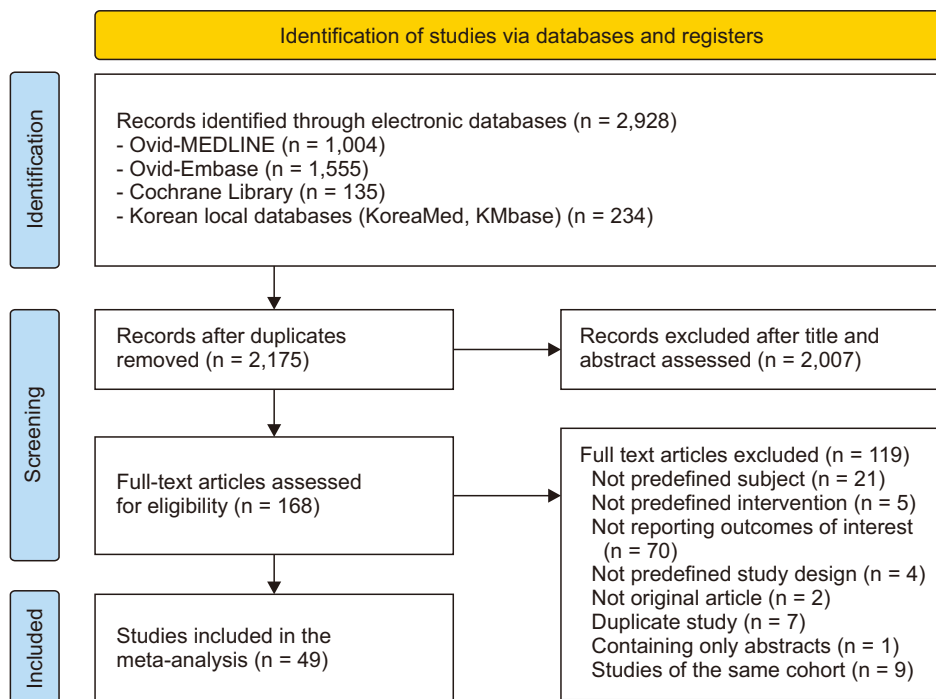


Figure 1. PRISMA flowchart to screen and identify the included studies.

from China, 1 from Hong Kong, and 3 from Europe. The mean number of participants per study was 41 (range: 8–228), with a mean age of 24.6 years. In addition, 33 studies focused on skeletal Class III malocclusion. The follow-up periods varied across studies, ranging from a minimum of 15 days to a maximum of 3 years, with an average follow-up time of 9.7 months.

Evaluation of outcome parameters

Overall skeletal symmetry

In a comprehensive review involving 44 studies,^{12-43,49-60} 77 outcome indicators were analyzed to assess skeletal symmetry before and after orthognathic surgery. The SMDs of skeletal symmetry according to one- and two-jaw surgery are shown in Figure 2, with descriptions of the study groups and outcome variables in Table 3. Significant improvements were observed after surgery for all surgery types. However, a notable heterogeneity was observed among the included studies.

Skeletal symmetry according to distinct factors associated with surgery

Subgroup analyses according to surgery-related factors, such as the use of SFA, computer simulation, and analytical methods employed to evaluate asymmetry (2D vs. 3D), indicated a statistically significant improvement in skeletal symmetry in all subgroups (Supplementary Figures 1-3). However, high heterogeneity was observed among the studies in all subgroups.

Publication bias

Visual examination of the contour-enhanced funnel plot revealed that studies with larger standard errors were predominantly located within statistically significant intervals biased toward the left. This observation was supported by the Egger’s test, which demonstrated a significantly small study effect ($P < 0.01$).

Trim-and-fill analysis was employed to address potential publication bias, resulting in the inclusion of 38 studies. The analysis showed an SMD of -0.67 ($P < 0.01$) for the improvement in skeletal symmetry, indicating

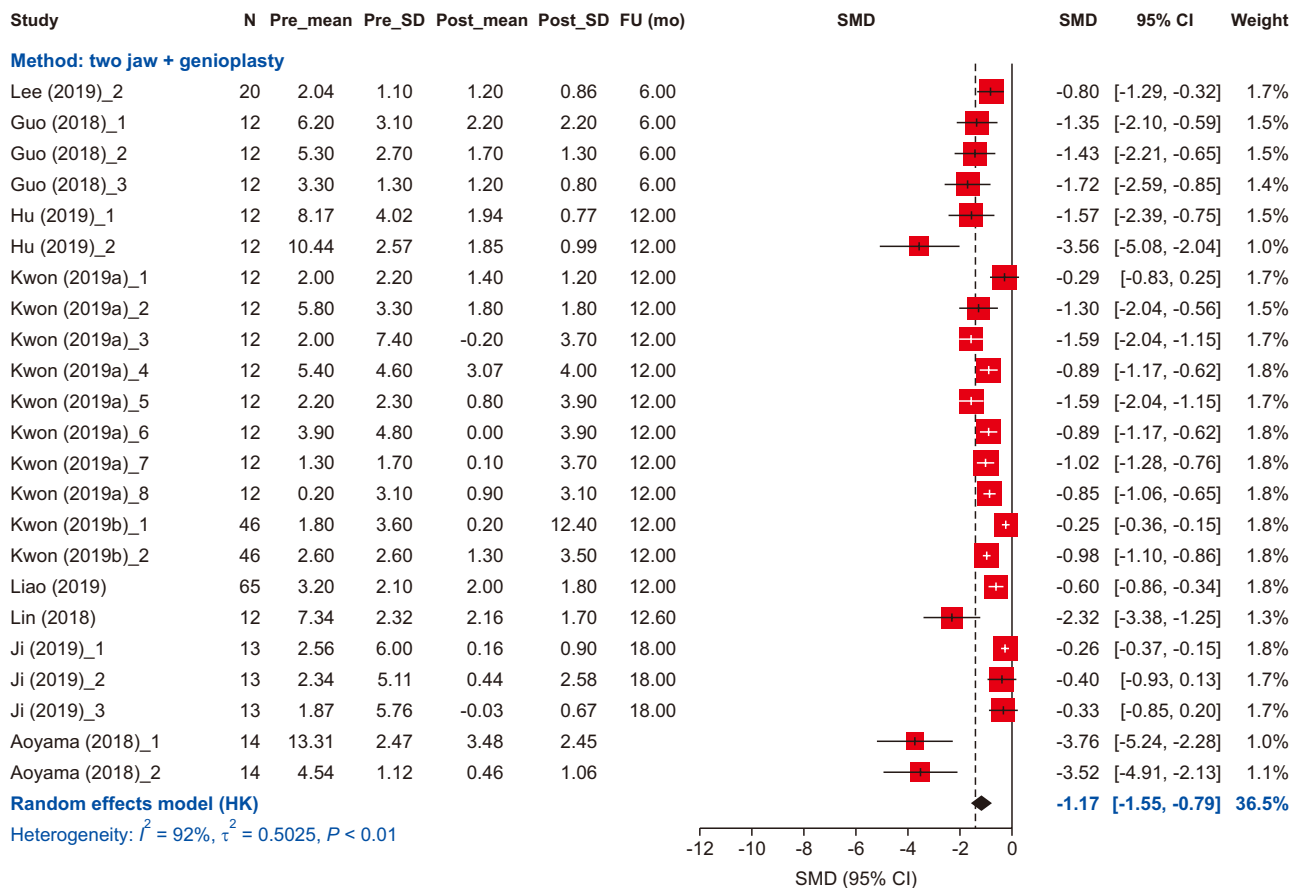


Figure 2. Skeletal symmetry improvement: one-jaw vs. two-jaw (study groups and outcomes are shown in Table 3). SD, standard deviation; FU, follow-up; SMD, standardized mean difference; CI, confidence interval, HK, Hoffman and Kringle.

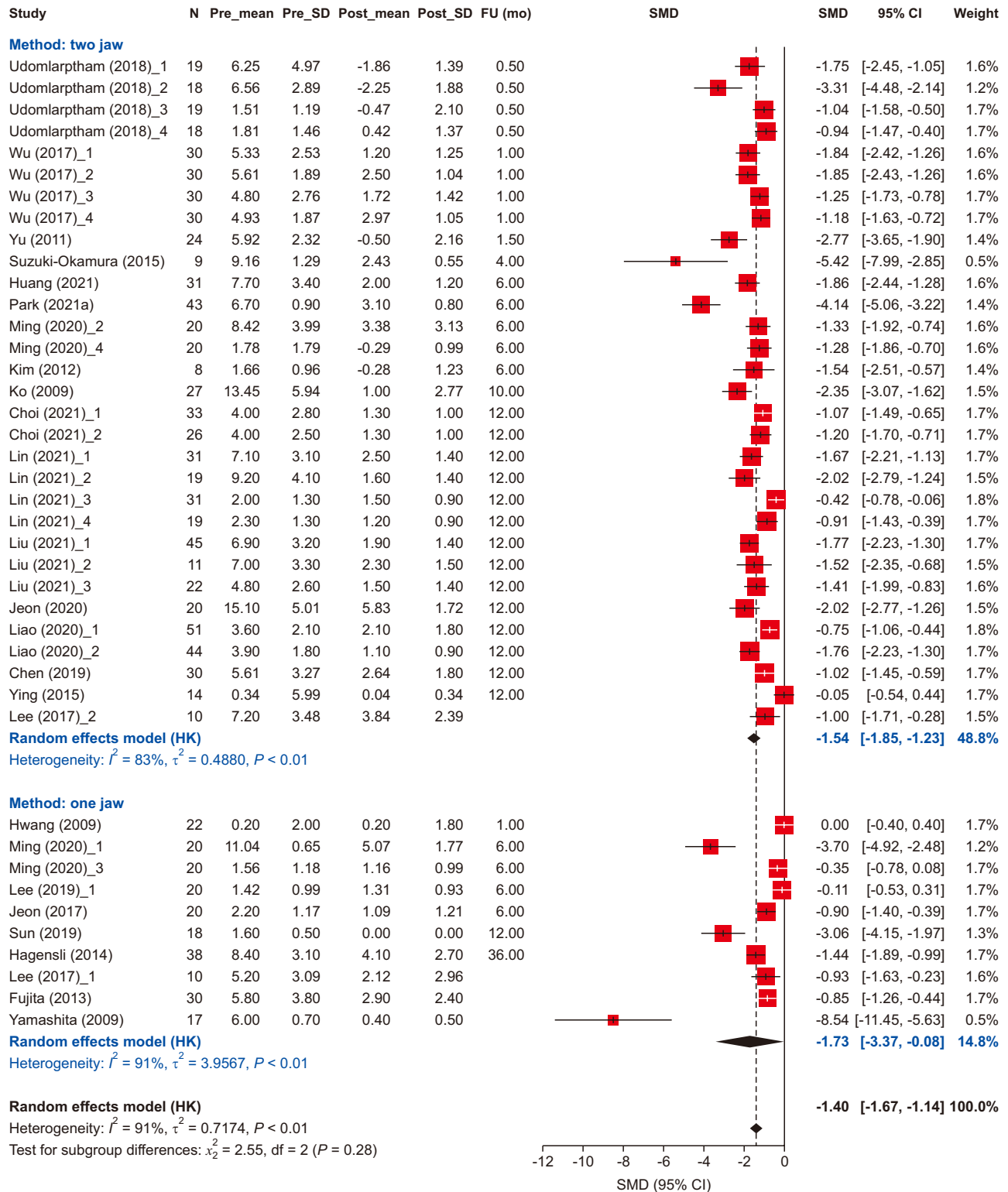


Figure 2. Continued.

that publication bias did not significantly impact the overall outcome of enhanced skeletal symmetry following orthognathic surgery.

Individual skeletal symmetry outcomes

The SMDs of each outcome variable used for skeletal symmetry, such as menton deviation, maxillary canting,

Table 3. Characteristics of included studies and the definitions of the subgroups for the meta-analysis

Study (year)	Outcome	Surgical technique (mandible)	Computer simulation	1-jaw vs. 2-jaw	SFA	Imaging	Subgroup for meta-analysis
Aoyama et al. ⁴² (2018)	Me, MC	SSRO	No	2-jaw + genioplasty	No	2D	1: Me, 2: MC
Chen et al. ⁵¹ (2016)	Me	SSRO	No	1-jaw, 2-jaw	No	3D	1: Group I*, 2: Group II†, 3: Group III*
Chen et al. ³⁶ (2019)	UI, LI, LC, Me	SSRO	No	2-jaw	Yes	3D	
Choi et al. ²⁸ (2021)	Me	SSRO	No	2-jaw	Yes	2D	1: SFA, 2: Conventional approach
Eo et al. ⁵² (2022)	Me	SSRO	No	2-jaw	No	3D	
Freudlsperger et al. ²⁵ (2017)	LC	SSRO	No	2-jaw	No	3D	
Fujita et al. ⁴⁰ (2013)	LC, Me	SSRO, IVRO	No	1-jaw	No	2D	
Guo et al. ²² (2018)	FRI, RH, BL	SSRO	No	2-jaw + genioplasty	Yes	3D	1: FRI, 2: RH, 3: BL
Ha et al. ¹⁸ (2023)	FRI	SSRO	Yes	2-jaw	No	3D	
Hågensli et al. ³⁹ (2014)	UI, LI, Me	SSRO	No	1-jaw	No	2D	
Hu et al. ³¹ (2019)	Me	SSRO	Yes	2-jaw + genioplasty	Yes	3D	1: Group A [§] , 2: Group B
Huang et al. ¹⁹ (2021)	Me	SSRO	No	2-jaw	No	3D	
Hwang et al. ¹³ (2009)	LC, MC	NR	No	1-jaw	No	3D	
Jeon et al. ²³ (2017)	Me, LC	SSRO	No	1-jaw	No	3D	
Jeon et al. ³⁰ (2020)	Me	SSRO	No	2-jaw	No	3D	
Ji et al. ³⁸ (2019)	BL, MC, RH	SSRO	Yes	2-jaw + genioplasty	No	3D	1: BL, 2: MC, 3: RH
Kim et al. ²⁴ (2012)	LC, MC	SSRO	No	2-jaw	No		
Ko et al. ²⁶ (2009)	Me	SSRO	No	2-jaw	No	2D	
Kwon et al. ³² (2019)	Me, FRI, RH, BL	IVRO	No	2-jaw + genioplasty	No	3D	1: Me, contralateral type, 2: Me, ipsilateral type, 3: FRI, contralateral type, 4: FRI, ipsilateral type, 5: RH, contralateral type, 6: RH, ipsilateral type, 7: BL, contralateral type, 8: BL, ipsilateral type
Kwon et al. ³³ (2019)	BL, RH	IVRO	Yes	2-jaw + genioplasty	No	3D	1: RH, 2: BL
Lee et al. ⁶⁰ (2017)	Me, LC	SSRO	Yes	1-jaw, 2-jaw	Yes	3D	1: Me, 1-jaw, 2: Me, 2-jaw, 3: LC, 1-jaw, 4: LC, 2-jaw

Table 3. Continued

Study (year)	Outcome	Surgical technique (mandible)	Computer simulation	1-jaw vs. 2-jaw	SFA	Imaging	Subgroup for meta-analysis
Lee et al. ⁵⁰ (2019)	MC, LC	SSRO	Yes	1-jaw, 2-jaw	Yes	3D	1: MC, 1-jaw, 2: MC, 2-jaw, 3: LC, 1-jaw, 4: LC, 2-jaw
Lee et al. ²⁷ (2022)	Me	SSRO	No	1-jaw, 2-jaw	No	3D	
Liao et al. ⁵⁴ (2020)	Me	SSRO	Yes	2-jaw	Yes	3D	1: Conventional, 2: Computer simulation
Lin et al. ³⁷ (2018)	Me	SSRO	Yes	2-jaw + genioplasty	No	3D	
Lin et al. ²⁹ (2021)	Me, MC, LC	SSRO	No	2-jaw	Yes	3D	1: Me, API [†] , 2: Me, PIE ^{**} , 3: MC, API, 4: MC, PIE, 5: LC, API, 6: LC, PIE
Liu et al. ⁵³ (2022)	Me, LC	SSRO	Yes	2-jaw	Yes	3D	1: Me, Roll-type, 2: Me, Translation-type, 3: Me, Yaw-type, 4: LC, Roll-type, 5: LC, Translation-type, 6: LC, Yaw-type
Liu and Li ⁴⁹ (2022)	BL, RH	SSRO		1-jaw + genioplasty	No	3D	
Ming et al. ²¹ (2020)	Me, MC	SSRO	No	1-jaw, 2-jaw	No	3D	1: Me, 1-jaw, 2: Me, 2-jaw, 3: MC, 1-jaw, 4: MC, 2-jaw
Ohba et al. ⁵⁷ (2016)	Me, L1	SSRO	No	1-jaw, 2-jaw	No	2D	1: Me, Minor asymmetry, 2: Me, Severe asymmetry, 3: L1, Minor asymmetry, 4: L1, Severe asymmetry
Park et al. ⁴⁶ (2021)	FRI	SSRO	No	2-jaw	Yes	3D	
Sun and Lee ⁵⁶ (2019)	MC	SSRO	No	1-jaw	Yes	3D	
Suzuki-Okamura et al. ¹⁷ (2015)	LC, Me	SSRO	No	2-jaw	No	3D	
Udomlarptham et al. ¹² (2018)	Me, MC	SSRO	Yes	2-jaw	No	3D	1: Me (3D), 2: Me (2D), 3: MC (3D), 4: MC (2D)
Verzé et al. ⁴⁴ (2012)	U1-L1 discrepancy	Mixed	No	1-jaw, 2-jaw	No	3D	
Wong et al. ¹⁶ (2014)	Me	SSRO	Yes	1-jaw, 2-jaw	No	3D	1: Conventional, 2: Computer simulation
Wu et al. ¹⁴ (2017)	Me, RH, U1, L1	SSRO	Yes	2-jaw	No		1: Me (3D), 2: Me (2D), 3: RH (3D), 4: RH (2D), 5: L1 (3D), 6: L1 (2D), 7: U1 (3D), 8: U1 (2D)
Xu et al. ⁴³ (2021)	L1	SSRO	No	1-jaw, 2-jaw	No	3D	1: 1-jaw, 2: 2-jaw
Yamashita et al. ⁴¹ (2009)	LC, MC	SSRO	No	1-jaw	No	2D	

Table 3. Continued

Study (year)	Outcome	Surgical technique (mandible)	Computer simulation	1-jaw vs. 2-jaw	SFA	Imaging	Subgroup for meta-analysis
Ying et al. ³⁴ (2015)	MC	SSRO, IVRO	Yes	2-jaw	No	3D	
Yoon et al. ³⁵ (2003)	Me	SSRO	No	1-jaw, 2-jaw	No	2D	
Yu ¹⁵ (2011)	FRI, L1	SSRO	No	2-jaw	No	2D	

SFA, surgery-first approach; Me, menton deviation; MC, maxillary canting; SSRO, sagittal split ramus osteotomy; 2D, two-dimensional; 3D, three-dimensional; U1, upper dental midline deviation; L1, lower dental midline deviation; LC, lip canting; IVRO, intraoral vertical ramus osteotomy; FRI, frontal ramal inclination; RH, ramus height; BL, body length; NR, not reported.

*Menton deviation greater than ramus asymmetry.

†Menton deviation less than ramus asymmetry.

‡Atypical asymmetry of menton deviation to the contralateral side.

§Use of CAD/CAM occlusal splints, drilling guiding templates, and pre-bent plates.

|| Use of CAD/CAM occlusal splints only.

¶Asymmetric posterior impaction on both sides.

**Posterior impaction on one side, and posterior extrusion on the other side.

frontal ramal inclination, ramus height, and body length, were assessed, and all variables showed significant improvement after surgery (Supplementary Figures 4–8).

Midline discrepancy

Following orthognathic surgery, a significant decrease was observed in the dental midline discrepancy of the upper dentition (SMD = -1.09, $P = 0.19$), lower dentition (SMD = -1.44, $P < 0.01$), and in the discrepancy between the upper and lower dentition (SMD = -1.24, $P < 0.01$) (Figure 3).

Lip canting

A significant decrease in lip canting was shown after surgery (SMD = -1.08, $P < 0.01$). However, high heterogeneity was observed among the included studies ($I^2 = 73.0\%$, $P < 0.01$) (Figure 4).

TMDs

The signs and symptoms related to TMD were classified into joint sounds, pain, and limited mouth opening (Table 4). Most studies have reported a decrease in TMD signs and symptoms of TMD after surgery.

QoL

The study conducted by Vongkamolchoon et al.⁴⁸ examined changes in QoL before and after surgery in patients with facial asymmetry. This study included 74 patients with skeletal Class III malocclusion 12 months after surgery. The Orthognathic Quality of Life Questionnaire was used to assess the QoL across different domains. The results showed a significant improvement in QoL in each domain and overall QoL, except for the awareness domain, when compared with the preopera-

tive period.⁴⁸

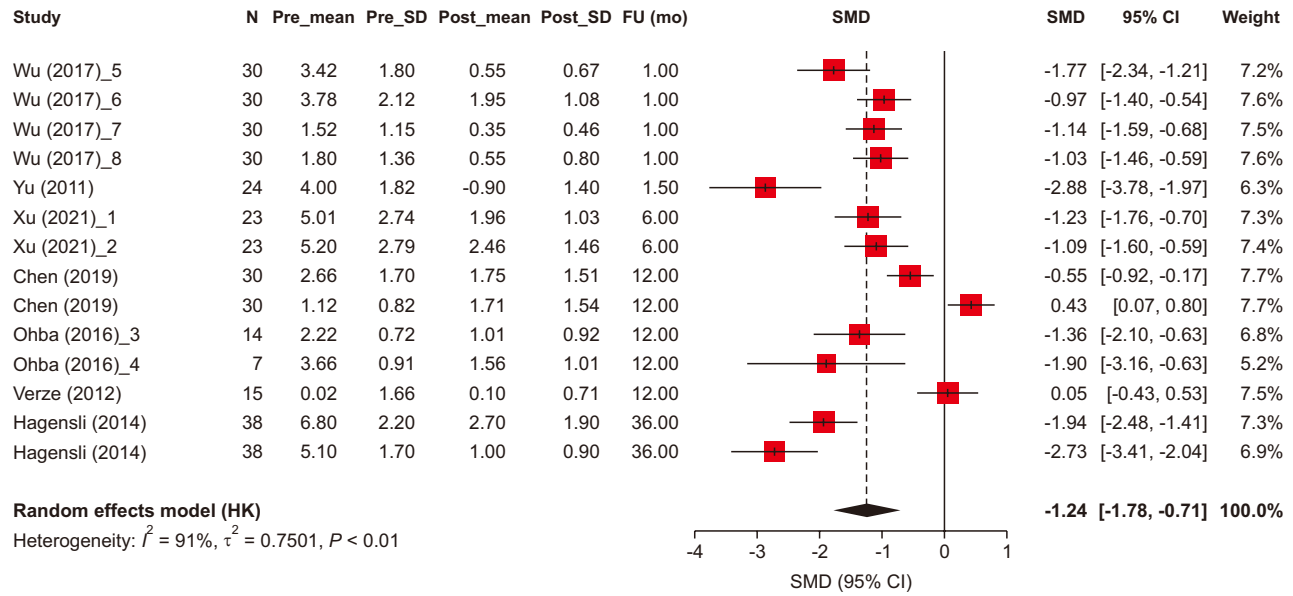
Relapse

In the analysis of skeletal symmetry based on the follow-up period, studies with a follow-up period of < 3 months exhibited the highest SMDs (-1.36, $P < 0.01$), indicating a significant change due to surgery, while studies with a follow-up period of 3–12 months also showed a significant improvement in skeletal symmetry (SMD = -1.34, $P < 0.01$). However, in studies with a follow-up period > 12 months, the SMD was less than that in those with a shorter follow-up period (SMD = -0.60, $P > 0.05$) (Figure 5). The analysis of menton deviation based on the follow-up period showed similar results, with a greater SMD for studies with a follow-up period of < 3 months^{12,14}; studies with a follow-up period > 3 months showed fewer SMDs (Supplementary Figure 9).

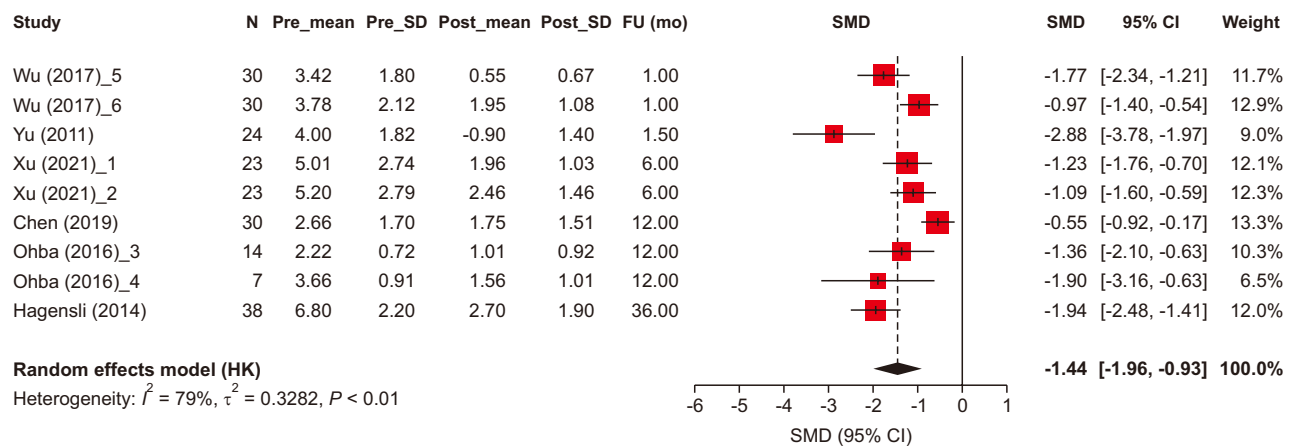
DISCUSSION

We provide comprehensive evidence supporting the effectiveness of orthognathic surgery to correct facial asymmetry, alleviating TMD symptoms, and improving QoL. Analysis of the included studies revealed significant improvements in all the evaluated skeletal parameters following surgery. Among the variables studied, the menton exhibited the highest frequency of use as a measure of facial asymmetry, followed by maxillary canting, frontal ramal inclination, ramus height, body length, and distance from the gonion to the midsagittal reference plane. Our results indicated that there was a significant improvement in skeletal symmetry, regardless of the different surgery-related factors, such as the surgical technique (one- vs. two-jaw), timing of surgery,

A



B



C

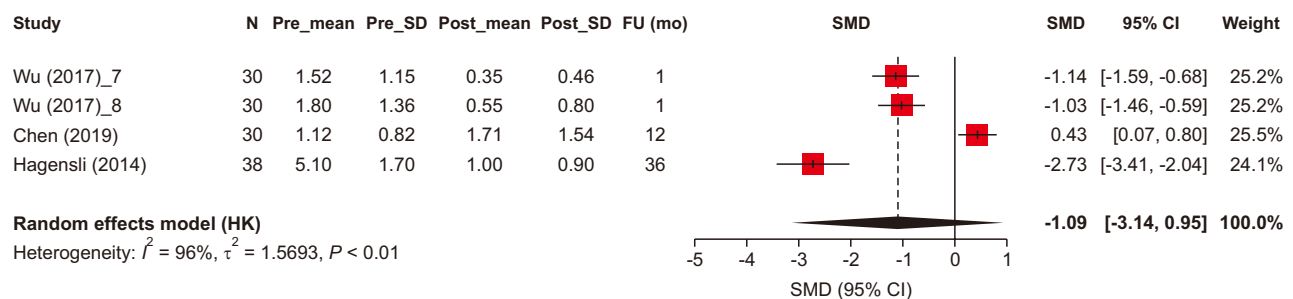


Figure 3. Forest plot for dental midline discrepancies between upper and lower arches (A), lower dental midline discrepancies (B), and upper dental midline discrepancies (C) (study groups and outcomes are shown in Table 3). SD, standard deviation; FU, follow-up; SMD, standardized mean difference; CI, confidence interval, HK, Hoffman and Kringle.

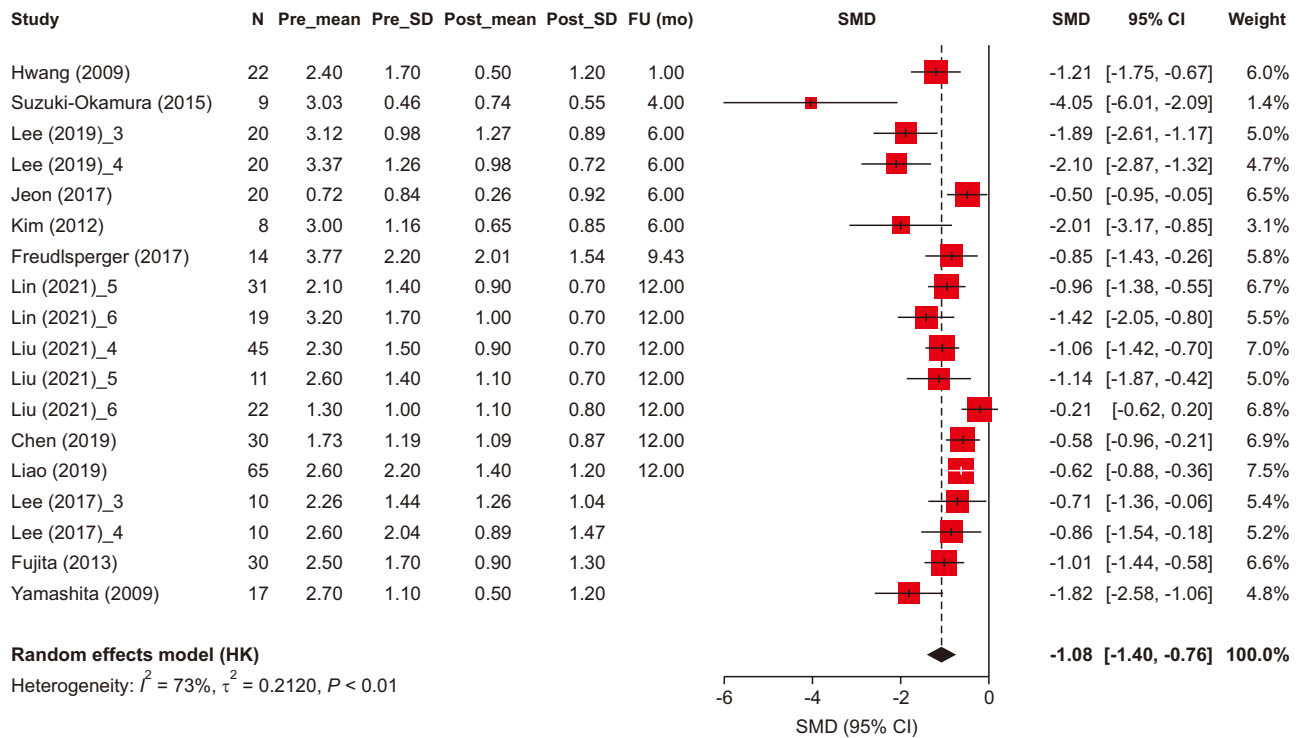


Figure 4. Forest plot for lip canting (study groups and outcomes are shown in Table 3). SD, standard deviation; FU, follow-up; SMD, standardized mean difference; CI, confidence interval, HK, Hoffman and Kringle.

Table 4. Signs and symptoms associated with temporomandibular disorder

Outcome indicator	Studies	Surgical technique	Number of patients (n)	Pre-surgery (%)	Post-surgery (%)
Sound	Fujimura et al. ⁶¹ (2005)	IVSRO	15	86.7	6.7
		IVRO	15	80.0	13.3
	Park et al. ⁴⁶ (2021)	SSRO + IVRO	8	62.5	37.5
		SSRO	10	60.0	50.0
	Kim and Ryu ⁴⁵ (2007)	Not reported	30	66.7	23.3
Toh and Leung ⁶² (2022)	Mixed	64	37.8	17.8	
Pain	Park et al. ⁴⁶ (2021)	SSRO + IVRO	8	12.5	0
		SSRO	10	10.0	0
	Kim and Ryu ⁴⁵ (2007)	Not reported	30	53.5	20.0
	Toh and Leung ⁶² (2022)	Mixed	64	13.3	6.7
Sound and pain	Park et al. ⁴⁶ (2021)	SSRO + IVRO	8	37.5	0
		SSRO	10	20.0	0
	Toh and Leung ⁶² (2022)	Mixed	64	15.6	13.3
Sound, pain, and limitation of condylar movement	Ohba et al. ⁴⁷ (2022)	IVRO	14	17.9	10.7
		SSRO with fixation	11	18.2	40.9
		SSRO with no fixation	37	24.3	5.4

IVSRO, intraoral vertical-sagittal ramus osteotomy; IVRO, intraoral vertical ramus osteotomy; SSRO, sagittal split ramus osteotomy.

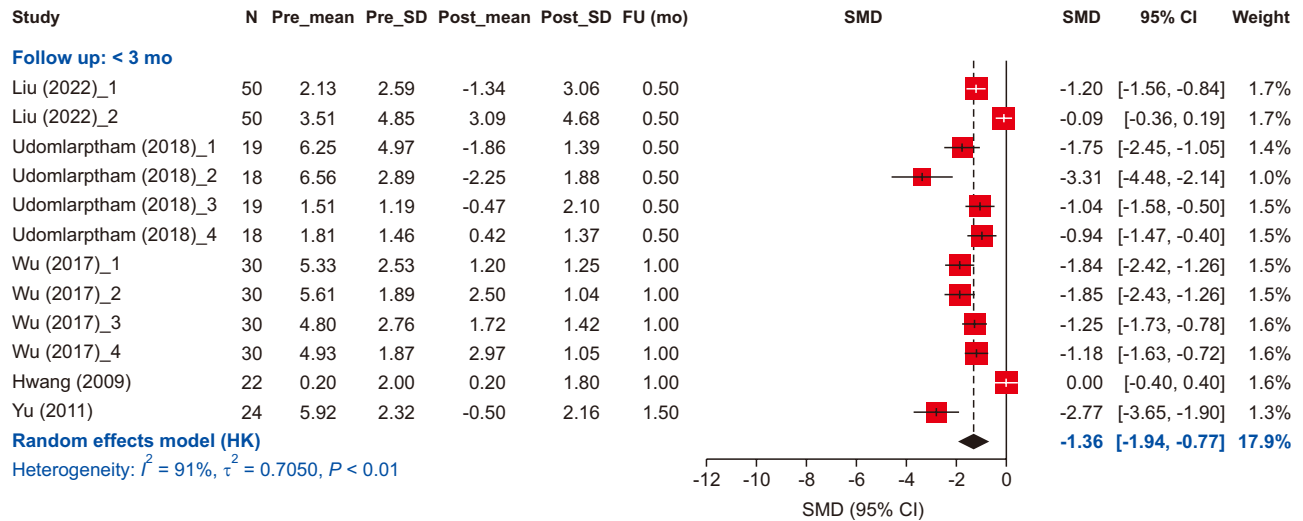


Figure 5. Skeletal symmetry based on different follow-up periods (study groups and outcomes are shown in Table 3). SD, standard deviation; FU, follow-up; SMD, standardized mean difference; CI, confidence interval, HK, Hoffman and Kringle.

use of computer simulation, and imaging modality for diagnosis and surgical planning.

Correction of maxillary canting and lip canting

Orthognathic surgery significantly reduced maxillary and lip canting. However, lip canting correction was found to be less predictable than maxillary canting.⁶³ Kim et al.²⁴ demonstrated a relationship between lip canting and canting correction of the anterior maxillary transverse occlusal planes. Lip asymmetry is influenced by muscular factors, and surgery may not cause significant changes in lip-line canting.⁶⁴ Lee et al.⁵⁰ reported an average lip cant of 3.12 for patients undergoing one-jaw surgery, which reduced to 1.27 after surgery.

Surgical planning and computer simulation

Facial asymmetry can only be analyzed in the frontal view; therefore, a frontal cephalogram in addition to a lateral cephalogram is required for diagnosis and surgical planning. However, in cases of facial asymmetry, 3D distortion of the mandible is often observed due to various yaw and roll patterns, which limits a comprehensive understanding of the mandibular morphology using only 2D imaging modalities.³⁰ Owing to technological advances in medical imaging, 3D imaging modalities, such as computed tomography (CT), intraoral scanners, and facial scanners, are readily available to clinicians. Integrating these datasets allows computer simulation surgery, which is reported to outperform traditional methods in enhancing facial midline symmetry.^{17,54}

Patients with facial asymmetry often show condylar deformation with degenerative changes, which can be accurately analyzed using CT.⁶⁵ Study groups using 2D

and 3D imaging modalities for surgery and those who planned surgery with or without computer simulation all showed significant improvements in asymmetry. However, it was not possible to directly compare the outcome variables of the studies that used 2D and 3D imaging modalities due to the nature of the meta-analysis. Additionally, the outcome variables used in these studies were mainly menton deviations and dental midline discrepancies, which do not fully represent facial asymmetry.

Skeletal symmetry outcomes related to transverse dimensions such as frontal ramal inclination and distance from the gonion to the midsagittal reference plane are strongly associated with facial contours. In patients with a translation asymmetry type, transverse movement of the distal segment results in correction of frontal ramal inclination with stability and improves soft tissue facial contour.^{15,20} A study comparing 2D and 3D planning in cleft patients with severe discrepancies showed that 3D planning yielded superior outcomes in terms of facial contour asymmetry, but we excluded the study due to cleft palate patients.⁶⁶ Additionally, Udomlarptham et al.¹² concluded that 3D planning was particularly advantageous to achieve bilateral mandibular contour symmetry.

TMDs

The effects of surgical intervention on TMD symptoms vary across studies. Consistent with the results of a previous systematic review focusing on various patients with skeletal malocclusion who underwent orthognathic surgery,⁶⁷ our analysis of patients with facial asymmetry revealed an overall improvement in the prevalence of

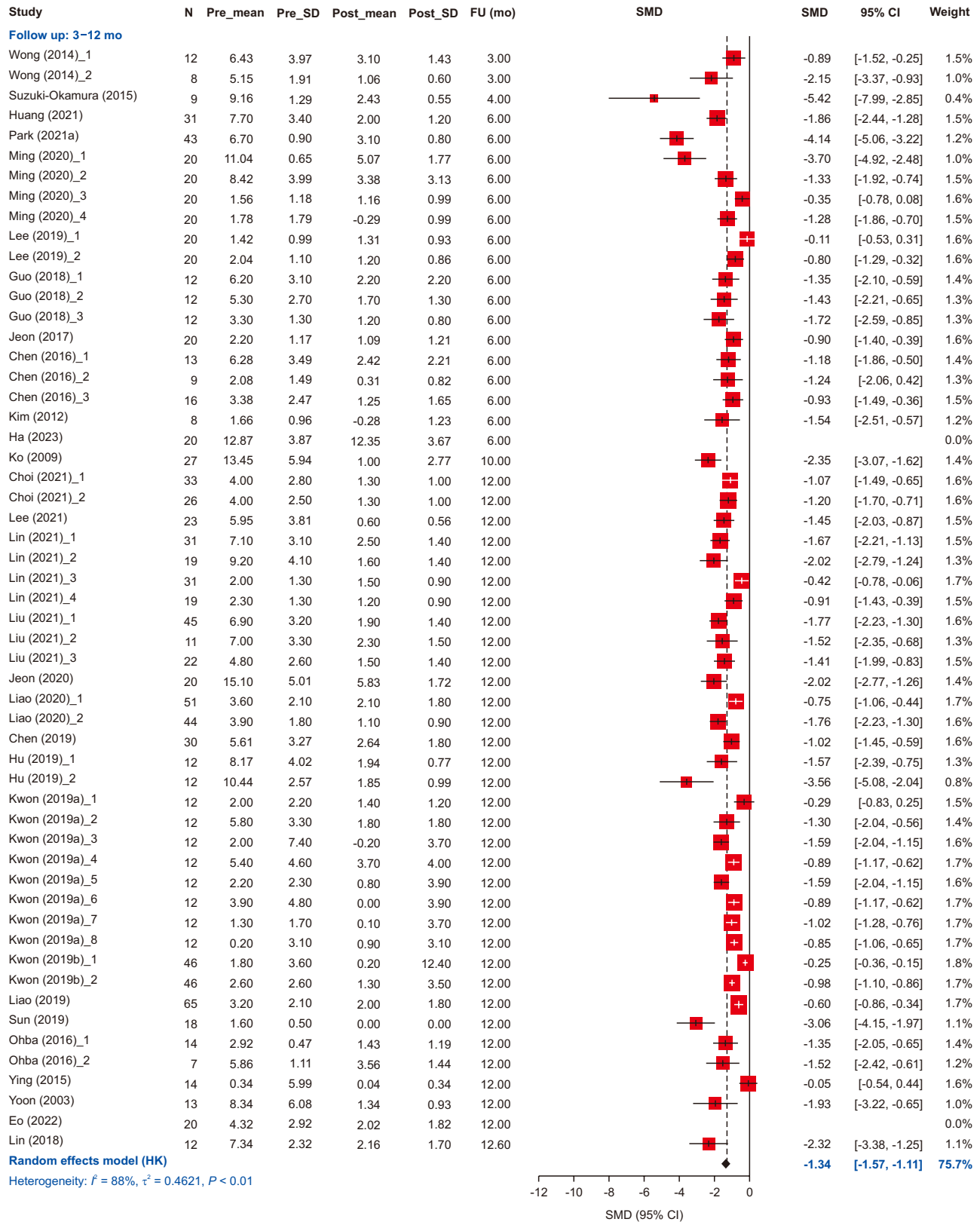


Figure 5. Continued.

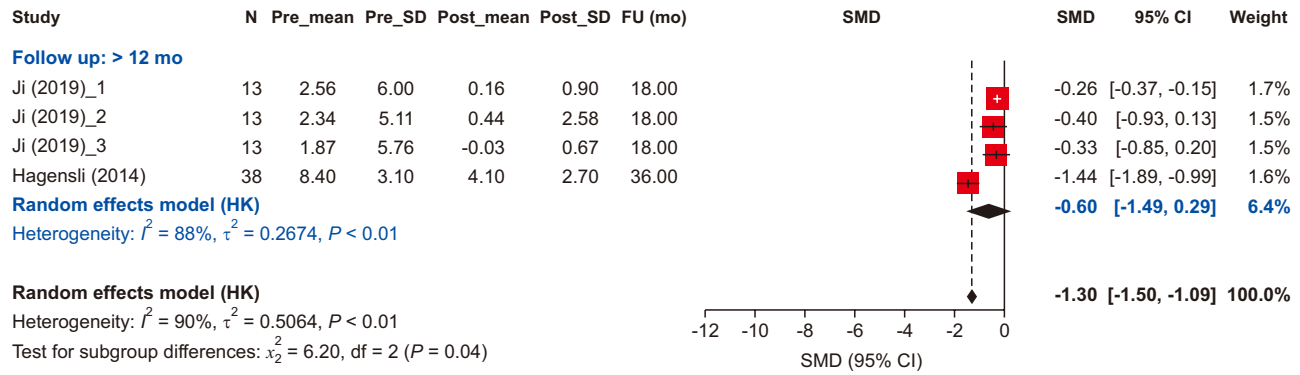


Figure 5. Continued.

pain.

However, differences in TMJ symptoms have been observed depending on the surgical technique used. Patients who underwent intraoral vertical ramus osteotomy (IVRO), intraoral vertical-sagittal ramus osteotomy (IVSRO), or sagittal split ramus osteotomy (SSRO) without fixation experienced a substantial reduction in TMJ symptoms.^{45-47,61,62} The favorable effect of surgeries with no fixation of the bone segments on the TMJ has been corroborated in previous studies. Fujimura et al.⁶¹ reported 92% and 83% improvements in clicking in patients who underwent IVSRO and IVRO, respectively. Chen et al.⁶⁸ also demonstrated a 71.4% improvement in pre-existing TMJ clicking in patients who underwent IVRO for mandibular setback. They showed that the rate of improvement of TMJ symptoms was not associated with the amount of setback. The alleviation of TMD symptoms after surgery may be attributed to the absence of fixation between the proximal and distal segments, allowing the proximal segment to attain a stable position.⁶⁹

In contrast, some patients who underwent conventional SSRO with fixation exhibited TMJ symptoms.^{46,47,62} Hu et al.⁷⁰ found that 8% of initially asymptomatic patients developed TMD symptoms 6 months postoperatively, emphasizing the challenges in replicating the original condylar position during SSRO. This difficulty poses a risk of excessive pressure on the articular disc or an unfavorable condylar position, potentially resulting in joint noise, pain, or exacerbation of pre-existing TMD symptoms.⁶⁹ However, Toh and Leung reported that, despite the surgical technique used (IVRO, SSRO, or a combination of the two techniques), 12.5% of patients who were previously asymptomatic developed signs and symptoms after surgery.⁶² AlWarawreh et al.⁷¹ reported that most patients who underwent SSRO with rigid fixation showed no change in the signs and symptoms of TMD. Eshghpour et al.⁷² studied the biomechanical stress of three different modalities, two bicortical screws,

three bicortical screws, and a miniplate, with SSRO using finite element analysis and concluded that the miniplate showed the least displacement of the bony segments.

Stability

Long-term stability is a crucial factor determining the success of orthognathic surgery. Short-term relapse can be attributed to factors such as condylar displacement during surgery, while long-term stability is influenced by condylar remodeling and skeletal growth.⁷³ We revealed that skeletal symmetry improvements remained stable even when relapse patterns were identified up to 3 years post-surgery. Most studies demonstrated stable menton and lower midline positions following surgery, suggesting no significant relapse. Most skeletal relapses occurred within the first 12 months postoperatively, with similar amounts of relapse observed between the immediate postoperative period and the 3-month to 12-month postoperative period. These relapse patterns align with previous studies reporting that most surgical relapses occur within 1 year after surgery.^{39,74}

Limitations

Our study has several limitations. First, we included ramus height and body length as parameters to assess skeletal symmetry. However, postsurgical changes in these variables may be influenced by the surgical technique, specifically SSRO and IVRO. Despite the high prevalence of SSRO in the included studies, the surgical technique may have influenced the outcomes related to skeletal symmetry. Second, although the subgroup analysis was performed based on predefined variables, high statistical heterogeneity was observed in most groups. One possible explanation for this is the limited number of studies on these variables. Distinct types of facial asymmetries can be present, including rotation, translation, and yaw. However, the specific type of asymmetry and amount of surgical movement in the jaws were not consistently defined across the included studies, which

may have contributed to the heterogeneity of the outcome parameters. Finally, as we focused on the outcome of surgery in patients with facial asymmetry, additional factors concerning skeletal stability, such as positional changes of the proximal segment and condylar head remodeling, were not studied. Further studies are warranted to focus on factors associated with long-term stability.

CONCLUSIONS

This systematic review and meta-analysis contributes to the existing body of knowledge by elucidating the effectiveness of surgical correction of facial asymmetry. Our findings support the positive outcomes of this approach in terms of skeletal improvement, long-term stability, TMD signs and symptom relief, psychological well-being, and QoL. However, it is essential to acknowledge that the included studies exhibited a low-to-moderate risk of bias. Some bias may be inevitable owing to the limited follow-up after treatment. The overall certainty of the evidence was low, indicating the need for further research to address these limitations and deepen our understanding of facial asymmetry correction and related factors.

AUTHOR CONTRIBUTIONS

Conceptualization: MJK, SHJ. Data curation: YJK, MYK, NJ, HGS. Formal analysis: MJK. Funding acquisition: HGS, MJK, SHJ. Investigation: YJK, MYK, HGS. Methodology: YDK, MHJ. Project administration: HGS, MJK. Resources: HGS, MJK. Software: MJK. Supervision: YDK, SHJ. Validation: MHJ, MJK. Visualization: YJK, NJ, MJK. Writing—original draft: YJK, MYK, MHJ. Writing—review & editing: YJK, NJ, SHJ.

CONFLICTS OF INTEREST

No potential conflict of interest relevant to this article was reported.

FUNDING

This research was supported by the grants from the National Evidence-based Healthcare Collaborating Agency (NECA, No. NA-21-010, NA22-007) and the Basic Science Research Program through the National Research Foundation of Korea (NRF) funded by the Ministry of Science, ICT & Future Planning (NRF-2020R1A2C2009296).

SUPPLEMENTARY MATERIAL

Supplementary data is available at <https://doi.org/10.4041/kjod23.194>.

REFERENCES

1. Wang TT, Wessels L, Hussain G, Merten S. Discriminative thresholds in facial asymmetry: a review of the literature. *Aesthet Surg J* 2017;37:375-85. <https://doi.org/10.1093/asj/sjw271>
2. Baek SH, Cho IS, Chang YI, Kim MJ. Skeletodental factors affecting chin point deviation in female patients with class III malocclusion and facial asymmetry: a three-dimensional analysis using computed tomography. *Oral Surg Oral Med Oral Pathol Oral Radiol Endod* 2007;104:628-39. <https://doi.org/10.1016/j.tripleo.2007.03.002>
3. Farkas LG, Cheung G. Facial asymmetry in healthy North American Caucasians. An anthropometrical study. *Angle Orthod* 1981;51:70-7. <https://pubmed.ncbi.nlm.nih.gov/6939355/>
4. Tani M, Iketani M, Watanabe M, Suda S, Fujimura N, Miyazawa M, et al. Posterior-anterior cephalometric analysis in patients with dentofacial deformities. *J Jpn Stomatol Soc* 1989;35:1749-59. <https://doi.org/10.5794/jjoms.35.1749>
5. Severt TR, Proffit WR. The prevalence of facial asymmetry in the dentofacial deformities population at the University of North Carolina. *Int J Adult Orthodon Orthognath Surg* 1997;12:171-6. <https://pubmed.ncbi.nlm.nih.gov/9511487/>
6. Peck H, Peck S. A concept of facial esthetics. *Angle Orthod* 1970;40:284-318. <https://pubmed.ncbi.nlm.nih.gov/4917993/>
7. Chew MT. Spectrum and management of dentofacial deformities in a multiethnic Asian population. *Angle Orthod* 2006;76:806-9. <https://pubmed.ncbi.nlm.nih.gov/17029514/>
8. Burstone CJ. Diagnosis and treatment planning of patients with asymmetries. *Semin Orthod* 1998;4:153-64. [https://doi.org/10.1016/s1073-8746\(98\)80017-0](https://doi.org/10.1016/s1073-8746(98)80017-0)
9. Page MJ, McKenzie JE, Bossuyt PM, Boutron I, Hoffmann TC, Mulrow CD, et al. The PRISMA 2020 statement: an updated guideline for reporting systematic reviews. *Int J Surg* 2021;88:105906. <https://doi.org/10.1016/j.ijsu.2021.105906>
10. Guyatt GH, Oxman AD, Vist GE, Kunz R, Falck-Ytter Y, Alonso-Coello P, et al.; GRADE Working Group. GRADE: an emerging consensus on rating quality of evidence and strength of recommendations. *BMJ* 2008;336:924-6. <https://doi.org/10.1136/bmj.39489.470347.AD>

11. Egger M, Davey Smith G, Schneider M, Minder C. Bias in meta-analysis detected by a simple, graphical test. *BMJ* 1997;315:629-34. <https://doi.org/10.1136/bmj.315.7109.629>
12. Udomlarptham N, Lin CH, Wang YC, Ko EW. Does two-dimensional vs. three-dimensional surgical simulation produce better surgical outcomes among patients with class III facial asymmetry? *Int J Oral Maxillofac Surg* 2018;47:1022-31. <https://doi.org/10.1016/j.ijom.2018.02.014>
13. Hwang HS, Min YS, Lee SC, Sun MK, Lim HS. Change of lip-line cant after 1-jaw orthognathic surgery in patients with mandibular asymmetry. *Am J Orthod Dentofacial Orthop* 2009;136:564-9. <https://doi.org/10.1016/j.ajodo.2007.10.060>
14. Wu TY, Lin HH, Lo LJ, Ho CT. Postoperative outcomes of two- and three-dimensional planning in orthognathic surgery: a comparative study. *J Plast Reconstr Aesthet Surg* 2017;70:1101-11. <https://doi.org/10.1016/j.jbjs.2017.04.012>
15. Yu SJ. The change of frontal ramal inclination (FRI) after orthognathic surgery with laterognathism: posteroanterior cephalometric study. *J Korean Assoc Oral Maxillofac Surg* 2011;37:21-9. <https://doi.org/10.5125/jkaoms.2011.37.1.21>
16. Wong TY, Liu JK, Fang JJ, Wu TC, Tu YH. Use of the matching optimal symmetry plane method in planning surgical correction of facial asymmetry--a preliminary report of 20 patients. *J Oral Maxillofac Surg* 2014;72:1180.e1-13. <https://doi.org/10.1016/j.joms.2014.02.020>
17. Suzuki-Okamura E, Higashihori N, Kawamoto T, Moriyama K. Three-dimensional analysis of hard and soft tissue changes in patients with facial asymmetry undergoing 2-jaw surgery. *Oral Surg Oral Med Oral Pathol Oral Radiol* 2015;120:299-306. <https://doi.org/10.1016/j.oooo.2015.05.020>
18. Ha SH, Meny AH, Jeong CG, Yeo JH, Baek SH, Choi JY. The accuracy and stability of intentional change of frontal-ramal inclination in orthognathic surgery for facial asymmetry patients. *J Craniofac Surg* 2023;34:e462-8. <https://doi.org/10.1097/SCS.00000000000009306>
19. Huang L, Li Z, Yan J, Chen L, Piao ZG. Evaluation of facial soft tissue thickness in asymmetric mandibular deformities after orthognathic surgery. *Maxillofac Plast Reconstr Surg* 2021;43:37. <https://doi.org/10.1186/s40902-021-00323-5>
20. Park EH, Ha AR, Kim KA, Park KH, Kang YG. Ramal inclination in the frontal plane after bimaxillary orthognathic surgery in skeletal class III facial asymmetry: spontaneous changes and stability. *J Orofac Orthop* 2023;84(Suppl 2):37-44. <https://doi.org/10.1007/s00056-021-00344-9>
21. Ming Y, Hu Y, Wang T, Zhang J, Li Y, Xu W, et al. Three-dimensional evaluation of skeletal and dental changes in patients with skeletal class III malocclusion and facial asymmetry after surgical-orthodontic treatment. *J Xray Sci Technol* 2020;28:783-98. <https://doi.org/10.3233/XST-190628>
22. Guo J, Wang T, Han JJ, Jung S, Kook MS, Park HJ, et al. Corrective outcome and transverse stability after orthognathic surgery using a surgery-first approach in mandibular prognathism with and without facial asymmetry. *Oral Surg Oral Med Oral Pathol Oral Radiol* 2018;126:22-30. <https://doi.org/10.1016/j.oooo.2018.01.017>
23. Jeon EG, Lee ST, Kwon TG. Perioral soft tissue change after isolated mandibular surgery for asymmetry patients. *J Craniomaxillofac Surg* 2017;45:962-8. <https://doi.org/10.1016/j.jcms.2017.01.039>
24. Kim SJ, Choi JY, Baek SH. Evaluation of canting correction of the maxillary transverse occlusal plane and change of the lip canting in Class III two-jaw orthognathic surgery. *Angle Orthod* 2012;82:1092-7. <https://doi.org/10.2319/011512-36.1>
25. Freudlsperger C, Rückschloß T, Ristow O, Bodem J, Kargus S, Seeberger R, et al. Effect of occlusal plane correction on lip cant in two-jaw orthognathic surgery- a three-dimensional analysis. *J Craniomaxillofac Surg* 2017;45:1026-30. <https://doi.org/10.1016/j.jcms.2017.03.014>
26. Ko EW, Huang CS, Chen YR. Characteristics and corrective outcome of face asymmetry by orthognathic surgery. *J Oral Maxillofac Surg* 2009;67:2201-9. <https://doi.org/10.1016/j.joms.2009.04.039>
27. Lee DH, Cho SA, Jeon JH. Mandibular stability after sagittal split ramus osteotomy with hybrid technique in asymmetric patients. *J Craniofac Surg* 2022;33:920-5. <https://doi.org/10.1097/SCS.00000000000008157>
28. Choi JW, Park H, Kwon SM, Lee JY. Surgery-first orthognathic approach for the correction of facial asymmetry. *J Craniomaxillofac Surg* 2021;49:435-42. <https://doi.org/10.1016/j.jcms.2021.04.005>
29. Lin CL, Chen YA, Yao CF, Chang CS, Liao YF, Chen YR. Comparative stability and outcomes of two surgical approaches for correction of class III asymmetry with lip or occlusal cant. *Clin Oral Investig* 2021;25:5449-62. <https://doi.org/10.1007/s00784-021-03853-4>
30. Jeon HJ, Lee JS, Lee JW, Yang JD, Chung HY, Cho BC, et al. Stability of lingual plate osteotomy in orthognathic surgery for patients with severe facial asymmetry: a retrospective analysis with 1-year follow-up. *J Craniomaxillofac Surg* 2020;48:156-61. <https://doi.org/10.1016/j.jcms.2019.12.014>

31. Hu P, Li J, Du W, Ji H, Xu C, Luo E. The drilling guiding templates and pre-bent titanium plates improves the operation accuracy of orthognathic surgery with computer-aided design and computer-aided manufacturing occlusal splints for patients with facial asymmetry. *J Craniofac Surg* 2019;30:2144-8. <https://doi.org/10.1097/SCS.00000000000005656>
32. Kwon SM, Baik HS, Jung HD, Jang W, Choi YJ. Diagnosis and surgical outcomes of facial asymmetry according to the occlusal cant and menton deviation. *J Oral Maxillofac Surg* 2019;77:1261-75. <https://doi.org/10.1016/j.joms.2019.01.028>
33. Kwon SM, Hwang JJ, Jung YH, Cho BH, Lee KJ, Hwang CJ, et al. Similarity index for intuitive assessment of three-dimensional facial asymmetry. *Sci Rep* 2019;9:10959. <https://doi.org/10.1038/s41598-019-47477-x>
34. Ying B, Ye N, Jiang Y, Liu Y, Hu J, Zhu S. Correction of facial asymmetry associated with vertical maxillary excess and mandibular prognathism by combined orthognathic surgery and guiding templates and splints fabricated by rapid prototyping technique. *Int J Oral Maxillofac Surg* 2015;44:1330-6. <https://doi.org/10.1016/j.ijom.2015.05.012>
35. Yoon SY, Park SH, Yoon KC, Park IK. Stability and relapse of facial asymmetry following orthognathic surgery in patients with asymmetric prognathism. *J Korean Soc Plast Reconstr Surg* 2003;30:679-84. <https://www.e-aps.org/m/journal/view.php?number=2286>
36. Chen YF, Liao YF, Chen YA, Chen YR. Surgical-orthodontic treatment for class II asymmetry: outcome and influencing factors. *Sci Rep* 2019;9:17956. <https://doi.org/10.1038/s41598-019-54317-5>
37. Lin CW, Wang YC, Chen YH, Ko EW. Dentoskeletal parameters related to visual perception of facial asymmetry in patients with skeletal class III malocclusion after orthognathic surgery. *Int J Oral Maxillofac Surg* 2018;47:48-56. <https://doi.org/10.1016/j.ijom.2017.06.031>
38. Ji H, Du W, Xu C, Zhao Q, Ye B, Luo E. Computer-assisted osteotomy guides and pre-bent titanium plates improve the planning for correction of facial asymmetry. *Int J Oral Maxillofac Surg* 2019;48:1043-50. <https://doi.org/10.1016/j.ijom.2019.01.026>
39. Hågensli N, Stenvik A, Espeland L. Asymmetric mandibular prognathism: outcome, stability and patient satisfaction after BSSO surgery. A retrospective study. *J Craniomaxillofac Surg* 2014;42:1735-41. <https://doi.org/10.1016/j.jcms.2014.06.008>
40. Fujita T, Shirakura M, Koh M, Itoh G, Hayashi H, Tanne K. Changes in the lip-line in asymmetrical cases treated with isolated mandibular surgery. *J Orthod* 2013;40:313-7. <https://doi.org/10.1179/1465313313Y.00000000056>
41. Yamashita Y, Nakamura Y, Shimada T, Nomura Y, Hirashita A. Asymmetry of the lips of orthognathic surgery patients. *Am J Orthod Dentofacial Orthop* 2009;136:559-63. <https://doi.org/10.1016/j.ajodo.2007.10.057>
42. Aoyama I, Oikawa T, Nakaoka K, Sekiya T, Hamada Y, Nakamura Y. Lip morphology in patients with facial asymmetry can be corrected by 2-jaw surgery. *J Oral Maxillofac Surg* 2018;76:2404-10. <https://doi.org/10.1016/j.joms.2018.04.017>
43. Xu W, Tan H, Meng X, Ming Y, Wang T, Zheng L. Three-dimensional analysis of lip soft tissue changes and related jaw changes in patients with skeletal class III malocclusion and facial asymmetry. *J Xray Sci Technol* 2021;29:903-16. <https://doi.org/10.3233/XST-210903>
44. Verzé L, Bianchi FA, Schellino E, Ramieri G. Soft tissue changes after orthodontic surgical correction of jaws asymmetry evaluated by three-dimensional surface laser scanner. *J Craniofac Surg* 2012;23:1448-52. <https://doi.org/10.1097/SCS.0b013e31824e25fc>
45. Kim YS, Ryu DM. Changes of temporomandibular joint symptoms after orthognathic surgery in the asymmetric prognathism patients. *J Korean Assoc Oral Maxillofac Surg* 2007;33:518-23. <https://www.jkaoms.org/journal/view.html?uid=584&vmd=Full>
46. Park J, Hong KE, Yun JE, Shin ES, Kim CH, Kim BJ, et al. Positional changes of the mandibular condyle in unilateral sagittal split ramus osteotomy combined with intraoral vertical ramus osteotomy for asymmetric class III malocclusion. *J Korean Assoc Oral Maxillofac Surg* 2021;47:373-81. <https://doi.org/10.5125/jkaoms.2021.47.5.373>
47. Ohba S, Tominaga J, Shido R, Koga T, Yamamoto H, Zaiima H, et al. Influence of different treatment procedures on the temporomandibular joint after mandibular setback in skeletal class III - a retrospective study. *J Craniomaxillofac Surg* 2022;50:712-8. <https://doi.org/10.1016/j.jcms.2022.07.009>
48. Vongkamolchoon S, Sinha SP, Liao YF, Chen YR, Huang CS. The impact of a surgery-first approach on oral health-related quality of life. *Int J Oral Maxillofac Surg* 2021;50:1336-41. <https://doi.org/10.1016/j.ijom.2021.02.010>
49. Liu Y, Li Y. BSSRO improves mandibular morphology mainly through correction of body length and volume in patients with asymmetric mandibular prognathism. *J Clin Med* 2022;11:7131. <https://doi.org/10.3390/jcm11237131>
50. Lee UL, Nam JH, Choi WC, Kim HW, Kim HJ, Choi YJ. Comparison of lip line cant change after 1-jaw and 2-jaw surgery. *J Craniofac Surg* 2019;30:1820-

4. <https://doi.org/10.1097/SCS.0000000000005556>
51. Chen YJ, Yao CC, Chang ZC, Lai HH, Lu SC, Kok SH. A new classification of mandibular asymmetry and evaluation of surgical-orthodontic treatment outcomes in Class III malocclusion. *J Craniomaxillofac Surg* 2016;44:676-83. <https://doi.org/10.1016/j.jcms.2016.03.011>
52. Eo PS, Park TH, Ryu JY, Lee JS, Yang JD, Chung HY, et al. The effect of orthognathic surgery on changes in masticatory muscle volume in patients with facial asymmetry. *J Craniofac Surg* 2022;33:1288-93. <https://doi.org/10.1097/SCS.0000000000008322>
53. Liu LC, Chen YA, Chen RF, Yao CF, Liao YF, Chen YR. Type of mandibular asymmetry affects changes and outcomes of bimaxillary surgery for class III asymmetry. *Clin Oral Investig* 2022;26:1077-88. <https://doi.org/10.1007/s00784-021-04092-3>
54. Liao YF, Chen YA, Chen YC, Chen YR. Outcomes of conventional versus virtual surgical planning of orthognathic surgery using surgery-first approach for class III asymmetry. *Clin Oral Investig* 2020;24:1509-16. <https://doi.org/10.1007/s00784-020-03241-4>
55. Liao YF, Chen YF, Yao CF, Chen YA, Chen YR. Long-term outcomes of bimaxillary surgery for treatment of asymmetric skeletal class III deformity using surgery-first approach. *Clin Oral Investig* 2019;23:1685-93. <https://doi.org/10.1007/s00784-018-2603-y>
56. Sun L, Lee KM. Three-dimensional evaluation of the postsurgical stability of mandibular setback with the surgery-first approach: comparison between patients with symmetry and asymmetry. *J Oral Maxillofac Surg* 2019;77:1469.e1-1469.e11. <https://doi.org/10.1016/j.joms.2019.03.020>
57. Ohba S, Nakao N, Kawasaki T, Miura KI, Minamizato T, Koga Y, et al. Skeletal stability after sagittal split ramus osteotomy with physiological positioning in patients with skeletal mandibular prognathism and facial asymmetry. *Br J Oral Maxillofac Surg* 2016;54:920-6. <https://doi.org/10.1016/j.bjoms.2016.06.010>
58. Moroi A, Ishihara Y, Sotobori M, Iguchi R, Kosaka A, Ikawa H, et al. Changes in occlusal function after orthognathic surgery in mandibular prognathism with and without asymmetry. *Int J Oral Maxillofac Surg* 2015;44:971-6. <https://doi.org/10.1016/j.ijom.2015.03.015>
59. Ueki K, Hashiba Y, Marukawa K, Yoshida K, Shimizu C, Nakagawa K, et al. Comparison of maxillary stability after Le Fort I osteotomy for occlusal cant correction surgery and maxillary advanced surgery. *Oral Surg Oral Med Oral Pathol Oral Radiol Endod* 2007;104:38-43. <https://doi.org/10.1016/j.tripleo.2006.11.018>
60. Lee GC, Yoo JK, Kim SH, Moon CH. Lip line changes in Class III facial asymmetry patients after orthodontic camouflage treatment, one-jaw surgery, and two-jaw surgery: a preliminary study. *Angle Orthod* 2017;87:239-45. <https://doi.org/10.2319/033016-254.1>
61. Fujimura K, Segami N, Sato J, Kaneyama K, Nishimura M. Comparison of the clinical outcomes of patients having sounds in the temporomandibular joint with skeletal mandibular deformities treated by vertico-sagittal ramus osteotomy or vertical ramus osteotomy. *Oral Surg Oral Med Oral Pathol Oral Radiol Endod* 2005;99:24-9. <https://doi.org/10.1016/j.tripleo.2004.03.020>
62. Toh AQJ, Leung YY. The effect of orthognathic surgery on temporomandibular disorder. *J Craniomaxillofac Surg* 2022;50:218-24. <https://doi.org/10.1016/j.jcms.2021.11.012>
63. Park YW. Correction of lip canting using bioabsorbables during orthognathic surgery. *Maxillofac Plast Reconstr Surg* 2014;36:178-83. <https://doi.org/10.14402/jkamprs.2014.36.4.178>
64. Kang SH, Kim MK, An SI, Lee JY. The effect of orthognathic surgery on the lip lines while smiling in skeletal class III patients with facial asymmetry. *Maxillofac Plast Reconstr Surg* 2016;38:18. <https://doi.org/10.1186/s40902-016-0065-1>
65. Jha N, Kim M, Cevidanes L, Kim YJ. Three-dimensional quantitative assessment of condylar displacement and adaptive remodeling in asymmetrical mandibular prognathism patients after sagittal split ramus osteotomy. *J Craniofac Surg* 2023;34:240-6. <https://doi.org/10.1097/SCS.0000000000008836>
66. Hsu PJ, Denadai R, Pai BCJ, Lin HH, Lo LJ. Outcome of facial contour asymmetry after conventional two-dimensional versus computer-assisted three-dimensional planning in cleft orthognathic surgery. *Sci Rep* 2020;10:2346. <https://doi.org/10.1038/s41598-020-58682-4>
67. Al-Moraissi EA, Wolford LM, Perez D, Laskin DM, Ellis E 3rd. Does orthognathic surgery cause or cure temporomandibular disorders? A systematic review and meta-analysis. *J Oral Maxillofac Surg* 2017;75:1835-47. <https://doi.org/10.1016/j.joms.2017.03.029>
68. Chen CM, Chen PJ, Hsu HJ. Changes in preexisting temporomandibular joint clicking after orthognathic surgery in patients with mandibular prognathism. *Bioengineering (Basel)* 2022;9:725. <https://doi.org/10.3390/bioengineering9120725>
69. He P, Iwanaga J, Matsushita Y, Adeeb N, Topale N, Tubbs RS, et al. A comparative review of mandibular orthognathic surgeries with a focus on intraoral vertico-sagittal ramus osteotomy. *Cureus* 2017;9:e1924. <https://doi.org/10.7759/cureus.1924>

70. Hu J, Wang D, Zou S. Effects of mandibular setback on the temporomandibular joint: a comparison of oblique and sagittal split ramus osteotomy. *J Oral Maxillofac Surg* 2000;58:375-80; discussion 380-1. [https://doi.org/10.1016/s0278-2391\(00\)90915-7](https://doi.org/10.1016/s0278-2391(00)90915-7)
71. AlWarawreh AM, AlTamimi ZH, Khraisat HM, Kretschmer W. Prevalence of temporomandibular disorder symptoms among orthognathic patients in Southern Germany: retrospective study. *Int J Dent* 2018;2018:4706487. <https://doi.org/10.1155/2018/4706487>
72. Eshghpour M, Samieirad S, Shooshtari Z, Shams A, Ghadirimoghaddam N. Three different fixation modalities following mandibular setback surgery with sagittal split ramus osteotomy: a comparative study using three-dimensional finite elements analysis. *World J Plast Surg* 2023;12:43-57. <https://doi.org/10.52547/wjps.12.1.43>
73. Sahoo NK, Agarwal SS, Datana S, Bhandari SK. Long-term study of relapse after mandibular orthognathic surgery: advancement versus setback. *J Maxillofac Oral Surg* 2022;21:469-80. <https://doi.org/10.1007/s12663-020-01445-5>
74. Bailey L', Cevidanes LH, Proffit WR. Stability and predictability of orthognathic surgery. *Am J Orthod Dentofacial Orthop* 2004;126:273-7. <https://pubmed.ncbi.nlm.nih.gov/15356484/>