

Effects of a modified surgical protocol on the positional accuracy of dental implants placed using fully guided implant surgery in the partially edentulous posterior ridge with distal extension: a dentiform model study

Young Woo Song¹, Seung Ha Yoo², Ui-Won Jung^{2*}

¹Department of Periodontology, Dental Hospital, Veterans Health Service Medical Center, Seoul, Republic of Korea

²Department of Periodontology, Research Institute for Periodontal Regeneration, Yonsei University College of Dentistry, Seoul, Republic of Korea

ORCID

Young Woo Song

<https://orcid.org/0000-0003-1835-5646>

Seung Ha Yoo

<https://orcid.org/0009-0002-6885-8786>

Ui-Won Jung

<https://orcid.org/0000-0001-6371-4172>

Corresponding author

Ui-Won Jung

Department of Periodontology,
Research Institute for Periodontal
Regeneration, Yonsei University
College of Dentistry, 50-1 Yonsei-
ro, Seodaemun-gu, Seoul 03722,
Republic of Korea

Tel +82-2-22283185

E-mail drjew@yuhs.ac

Received October 18, 2023 /

Last Revision January 2, 2024 /

Accepted February 6, 2024

This study was supported by
the Yonsei University College of
Dentistry Fund (grant number
6-2023-0008).

PURPOSE. The present experiment aimed to evaluate the placement accuracy of fully guided implant surgery using a mucosa-supported surgical guide when the protocol of osteotomy and installation was modified (MP) compared to when the protocol was sequentially and conventionally carried out (CP). **MATERIALS AND METHODS.** For 24 mandibular dentiform models, 12 dentists (6 experts and 6 beginners) performed fully guided implant placements two times at the right first and second molar sites using a mucosa-supported surgical guide, once by the CP (CP group) and at the other time by the MP (MP group). The presurgical and postsurgical stereolithographic images were superimposed, and the deviations between the virtually planned and actually placed implant positions and the procedure time were compared statistically ($P < .05$). **RESULTS.** The accuracies were similar in the CP and MP groups. In the CP group, the mean platform and apex deviations at the second molar site for the beginners were +0.75 mm and +1.14 mm, respectively, which were significantly larger than those for the experts ($P < .05$). In the MP group, only the mean vertical deviation at the second molar site for the beginners (+0.53 mm) was significantly larger than that for the experts ($P < .05$). The procedure time was significantly longer for the MP group (+94.0 sec) than for the CP group ($P < .05$). **CONCLUSION.** In fully guided implant surgery using a mucosa-supported guide, the MP may improve the placement accuracy when compared to the CP, especially at sites farther from the most-posterior natural tooth. [J Adv Prosthodont 2024;16:1-11]

KEYWORDS

In vitro study; Dental implant; Guided surgery; Stereolithography; Accuracy

© 2024 The Korean Academy of Prosthodontics

© This is an Open Access article distributed under the terms of the Creative Commons Attribution Non-Commercial License (<https://creativecommons.org/licenses/by-nc/4.0>) which permits unrestricted non-commercial use, distribution, and reproduction in any medium, provided the original work is properly cited.

INTRODUCTION

The introduction of computer-aided design and manufacturing technology into the field of dentistry has led to fully guided implant surgery which has become one of the most popular treatment modalities. This approach provides clinical advantages in terms of reducing the invasiveness of surgery and enabling accurate placement at the position planned using computer software based on preoperative computed tomography images and intraoral scan data.¹ However, guided surgery does not always guarantee the accuracy,^{2,3} especially in the posteriorly extended edentulous area where there are no natural teeth distal to the implant placement site.

Mucosa-supported surgical guides are known to be less stable than tooth-supported ones, which makes it more difficult to place an implant as virtually planned before the surgery.^{2,4,5} Furthermore, it has been revealed that when multiple implants are placed in the posteriorly extended edentulous area, the accuracy of placement decreases as the distance from the adjacent fixed structure (i.e., the natural tooth) in the mesial direction increases, since this increases the fulcrum movement.² In such cases, it is suggested to use an additional device such as an anchor pin on the distal side to reinforce the stability of the mucosa-supported stent,^{2,6-8} but this is not always possible if there is an anatomic hindrance such as restricted mouth opening or proximity to critical nerves or vessels.^{9,10}

To address these problems, applying extra drills or fixture mounts at the adjacent implant sites has been suggested as an alternative to using anchor pins. By this modified protocol (MP), for instance, assuming that multiple fixtures are to be placed at the first and second molar sites, an extra drill or mount applied to the osteotomy site of the second molar would make the mucosa-supported surgical guide resemble a tooth-supported one during the osteotomy and installation process at the first molar site, and the opposite case will reduce the fulcrum movement applied to the second molar site since the drill or mount inserted at the first molar site will function as a stable structure. It is reasonable to assume that adjusting the order of osteotomy and installation of the MP in

the forementioned way could improve the accuracy of fully guided implant surgery using the mucosa-supported surgical guide, but there is no scientific evidence to support this hypothesis.

Therefore, the present *in vitro* study aimed to evaluate the placement accuracy of fully guided implant surgery by the MP compared to that by the conventional protocol of osteotomy and installation (CP), when a mucosa-supported surgical guide was used in the partially edentulous distal-free-end case.

MATERIALS AND METHODS

This *in vitro* study involved 12 periodontal residents who studied and practiced at Yonsei University Dental Hospital placing implants in a dentiform model: 6 were experienced surgeons who had performed more than 100 implant placements (experts), while the other 6 were less experienced, having performed fewer than 10 implant surgeries (beginners).

Twenty-four dentiform models of the mandible were prepared for the present study. Each model comprised an alveolar bone portion made of resin and a mucosal portion made of silicone. The model had a distal-end-edentulous site at the right mandibular first and second molar sites, with an adjacent second premolar on mesial (Fig. 1A).

A self-tapping tapered dental implant (5 mm in diameter and 10 mm in length) with a sandblasted, large-grit, and acid-etched surface (Superline III, Dentium, Suwon, South Korea) was used in this study (Fig. 1B). A PMMA (polymethylmethacrylate)-based, sleeveless, mucosa-supported surgical guide that covered the right lower quadrant was three-dimensionally printed based on virtual planning using computer software (Dentium Digital Guide Software, Dentium) (Fig. 1C).

Each participant placed 10-mm-long fixtures using the following two fully guided implant surgical protocols (Fig. 2):

- Conventional protocol (CP), in which osteotomy and installation were performed from the first molar site to the second molar site:
 - i . 10-mm-length initial drilling conducted at the first molar site first and then at the second molar site




Fig. 1. Experimental materials: (A) Mandibular dentiform model, (B) Implant fixture (Superline III, Dentium), and (C) Muco-sa-supported surgical guide.

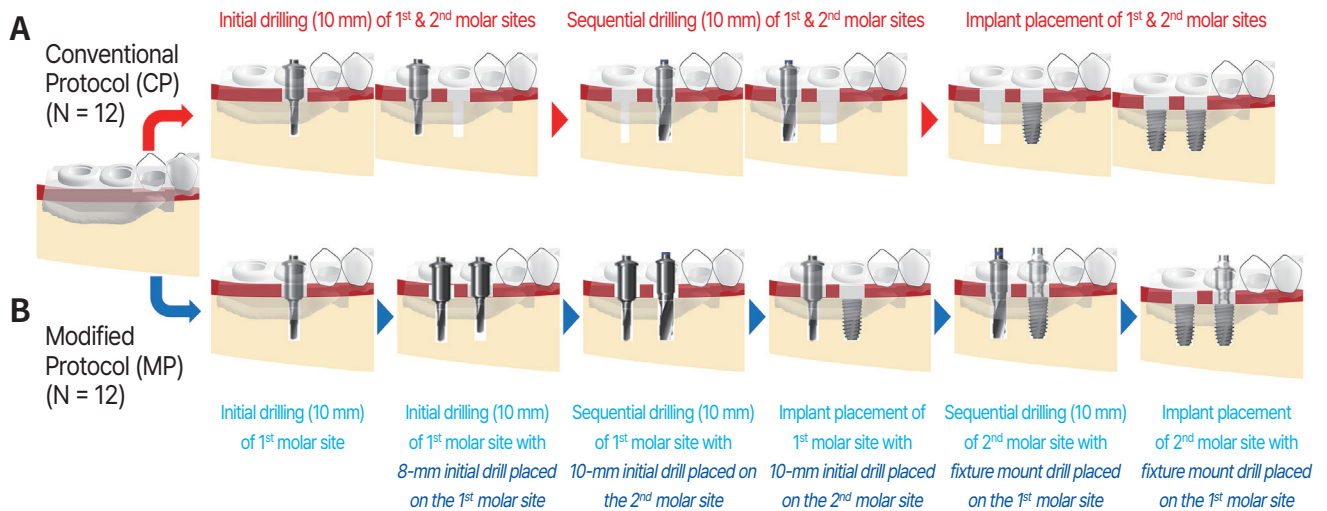


Fig. 2. Protocols for fully guided implant placement: (A) conventional protocol (CP) and (B) modified protocol (MP).

- ii. Sequential 10-mm-length osteotomy until the final drill in the same manner described previously
- iii. Installation of the fixtures at the first molar site first and then at the second molar site
- MP, in which osteotomy and installation were each performed utilizing the extra drills and fixture mounts in a different order from that used for the CP:
 - i. 10-mm-length initial drilling conducted at the first molar site
 - ii. 10-mm-length initial drilling conducted at the second molar site with 8-mm-length initial drill placed at the first molar site
 - iii. Sequential 10-mm-length osteotomy until the final drill at the first molar site with 10-mm-length initial drill placed at the second molar site
 - iv. Fixture installation at the first molar site with the 10-mm-length initial drill placed at the second molar site
 - v. Sequential 10-mm-length osteotomy until the final drill at the second molar site with a fixture mount adaptor placed over the first molar fixture
 - vi. Fixture installation at the second molar site with the fixture mount adaptor placed over the first molar fixture

Each dentiform was assigned to one of the two following groups according to the surgical protocol:

- CP group (12 dentiform models; 24 implants placed), involving a dentiform with the surgery performed using the CP.
- MP group (12 dentiform models; 24 implants placed), involving a dentiform with the surgery performed using the MP.

The presurgical and surgical procedures were carried out on a dental phantom manikin in order to simulate the clinical environment as closely as possible. All of the surgeons had been unaware of the MP before participating in the study, and each participant received instructions about the protocol 1 hour prior to performing the MP group model surgery.

The same dentiform model was used throughout this study. A single experienced researcher (S.H.Y.) conducted virtual planning to design and fabricate 24 identical surgical guide. A cone-beam computed tomography scan was performed (field of view of 16 × 18 cm, 85 kV, 8 mA, and exposure time of 24 sec; Rainbow CT, Dentium) and an optical impression was obtained using an intraoral scanner (Trios, 3Shape, Copenhagen, Denmark). These two datasets were transferred to a computer and superimposed using a software (Dentium Digital Guide Software, Dentium) for presurgical virtual implant placement in a prosthetically ideal position. Then, the mucosa-supported surgical guide was designed and sent to a dental laboratory for fabrication.

The two surgeries for the CP and MP performed by each participant were separated by an interval of 2 weeks. Whether a particular dentist performed the CP or MP first was decided by a four-block randomized sequence generated using a web-based program (<http://www.sealedenveope.com>).

The surgical procedures in both the CP and MP groups were carried out in a flapless manner on the dentiform model fixed to the dental phantom manikin. The surgery started with mucosa removal from the soft-tissue punch, and then osteotomy and fixture installation were performed according to either the CP or MP based on the group assignment. After the surgery, intraorally scannable healing abutments (Scan Abutment, Dentium) were applied over

the fixtures, and an optical impression of the right lower posterior sextant was taken using the intraoral scanner (Trios, 3Shape) to obtain postsurgical stereolithography (STL) files that included the actually placed implant position.

All of the measurements were made by a single investigator (S.H.Y.) who was blinded to the group allocation.

The positional accuracy of each implant placed using the CP or MP was evaluated by comparing the virtually planned position with the actually placed position using superimposed optical scan data based on the previously reported reverse-engineering method.^{2,3,11}

The presurgical project file which was extracted from the virtual planning software and the postsurgical STL file were uploaded to dental computer-aided design software (DentalCAD, exocad, Darmstadt, Germany). These presurgical and postsurgical datasets for the CP and MP groups with a merged layer of the virtual scan abutment were transferred to 3D analysis software (Geomagic Verify, SculptCAD, Dallas, TX, USA) and were superimposed on each other using residual teeth on the dentiform model as definitive reference structures. From the virtual scan abutment in the presurgical and postsurgical data, the center of the platform and apex as well as the apex of the implant fixture were visualized in an inverse manner, for quantitative evaluations of the extent of deviation between the presurgery and postsurgery conditions.

In accordance with the previous research,^{2,3,11} the following four parameters were measured to assess the positional accuracy:

- Vertical deviation (in millimeters), corresponding to the linearly measured deviation in the aspect of the vertical height of the implant platform.
- Angular deviation (in degrees), corresponding to the angle between the virtually planned and actually placed implant axes of the implant.
- Platform deviation (in millimeters), corresponding to the linear deviation in the horizontal aspect at the implant platform level.
- Apex deviation (in millimeters), corresponding to the linear deviation in the horizontal aspect at the implant apex level.

The aforementioned measuring process is summa-

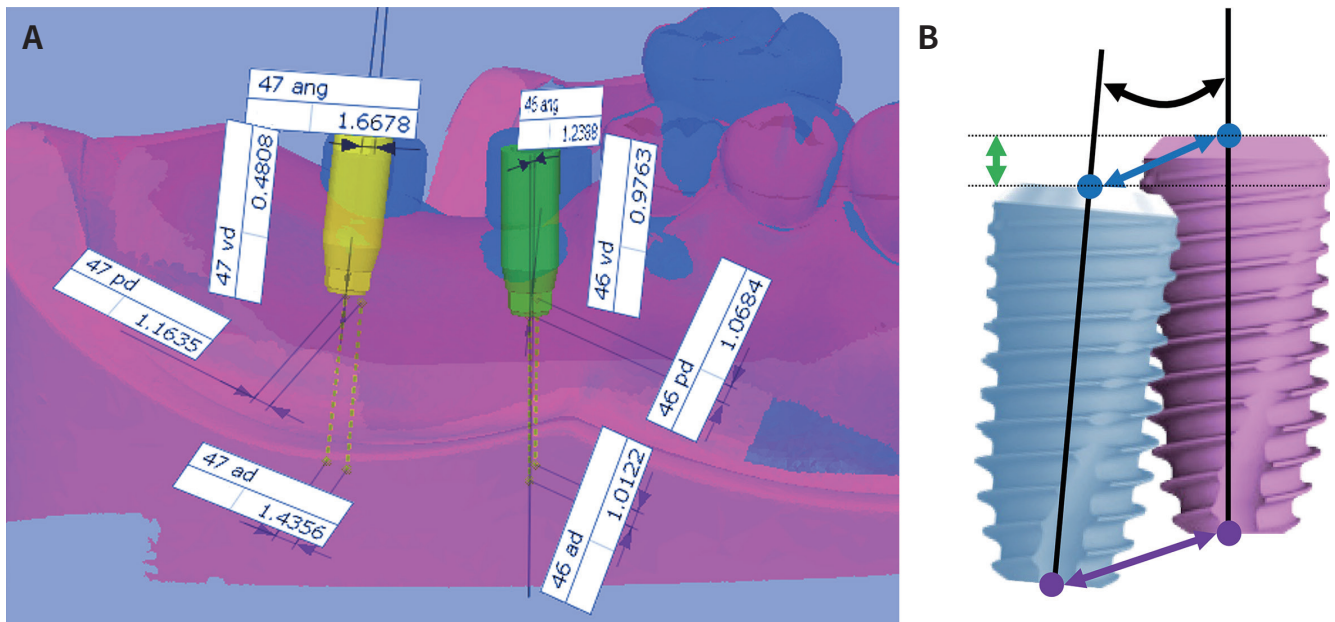


Fig. 3. Measurements of placement accuracy. (A) Superimposition of presurgical (magenta) and postsurgical (blue) stereolithographic images. According to the locations of virtual scan abutments (presurgical, green and yellow; postsurgical, blue), the deviations between the virtually planned and actually placed positions were estimated. (B) Schematic diagram of the deviations measured between the virtually planned (magenta fixture) and actually placed (blue fixture) positions. The vertical deviation (green double-headed arrow) was measured as the distance between the two black-dotted parallel lines passing through the center of the fixture platform. The angular deviation (black curved double-headed arrow) was measured between the black lines corresponding to the long axes of the fixtures. The platform deviation (blue double-headed arrow) was measured between the blue dots representing the center of the fixture platform. The apex deviation (purple double-headed arrow) was measured between the purple dots showing the center of the fixture apex.

rized in Fig. 3.

The total time spent on each surgical procedure in the CP and MP groups was estimated using a stopwatch from the start of delivering the surgical template to the dentiform model to the final installation of the implant fixture at the second molar site. The measured time was recorded in seconds.

The data were represented by mean \pm standard-deviation values and analyzed statistically using standard software (SPSS version 26, IBM, Armonk, NY, USA). The Mann-Whitney U test was used to compare the deviations and procedure time between the CP and MP groups, and subgroup comparisons were additionally conducted based on the implanted sites and the surgeons' experience. Comparisons between the first molar and second molar sites within the CP and MP groups were carried out using the Wilcoxon signed-rank test. Statistical significance was set as $P < .05$.

RESULTS

The results for the accuracy of implant placement are summarized in Fig. 4 and Fig. 5 and Table 1, and Table 2.

For each dentiform model, an average amount of deviation of the two implant fixtures was estimated as a representative value for statistical comparison. The vertical, angular, platform, and apex deviations were 0.86 ± 0.33 mm, $4.96 \pm 1.47^\circ$, 1.48 ± 0.25 mm, and 2.23 ± 0.63 mm, respectively, in the CP group, and 0.75 ± 0.37 mm, $4.36 \pm 1.57^\circ$, 1.42 ± 0.55 mm, and 1.91 ± 0.42 mm, respectively, in the MP group. All deviations were smaller in the MP group than in the CP group, but none of the intergroup comparisons were statistically significant.

At both the first and second molar sites, the CP group demonstrated slightly larger values for all devi-

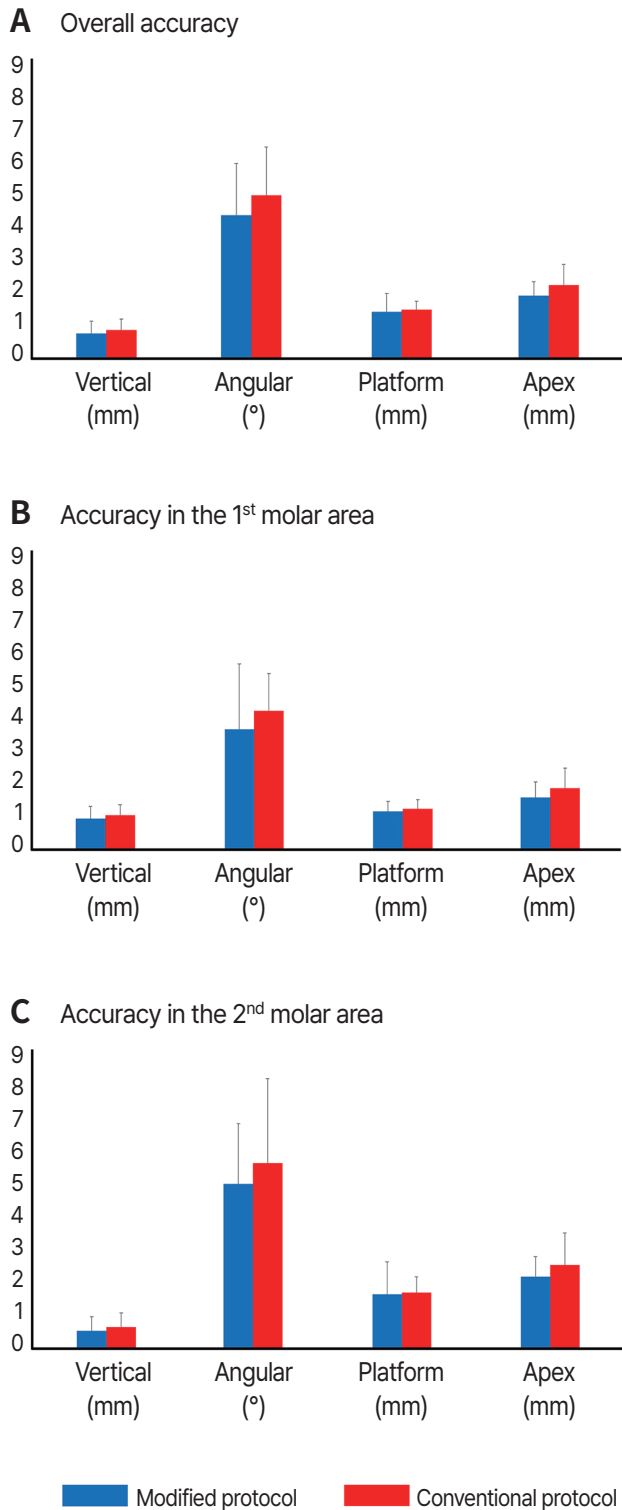


Fig. 4. Results of placement accuracy. (A) Overall accuracies in the MP and CP groups, (B) Accuracies in the MP and CP groups at the first molar site, (C) Accuracies in the MP and CP groups at the second molar site.

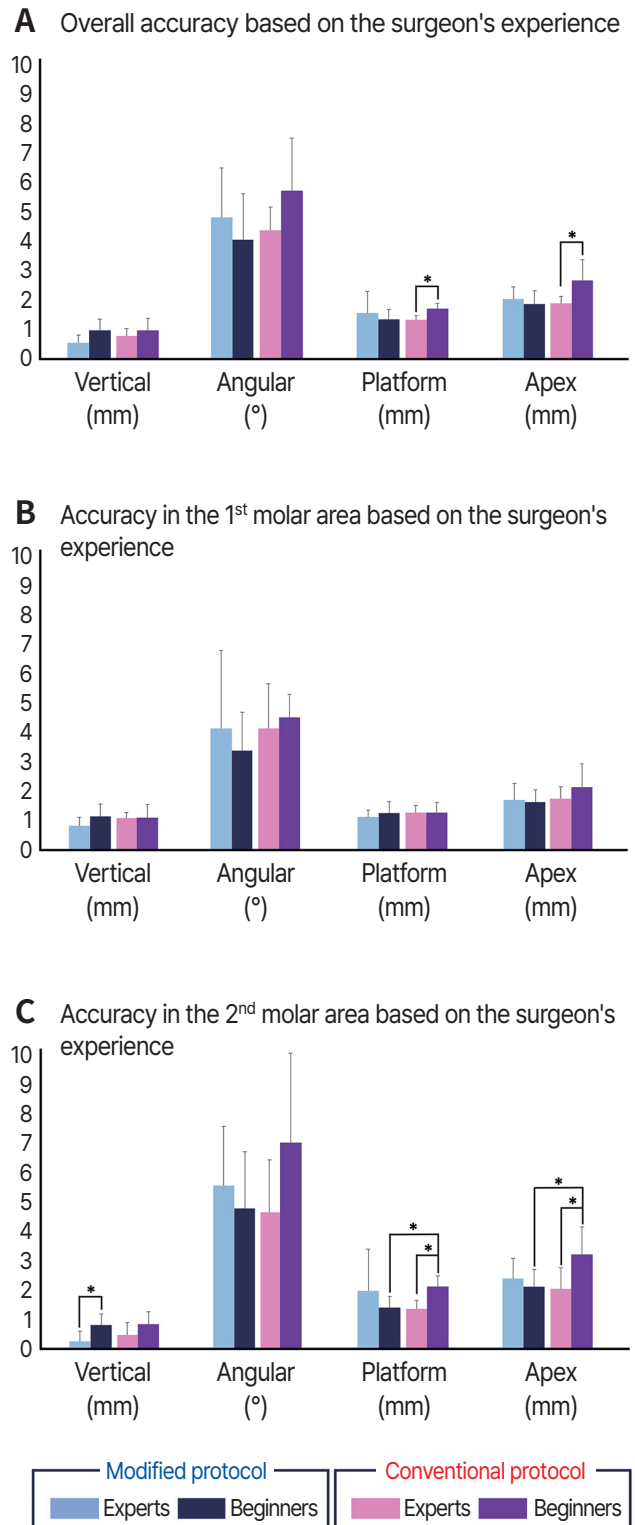


Fig. 5. Results of placement accuracy according to the surgeons' experience. (A) Overall accuracies in the MP and CP groups, (B) Accuracies in the MP and CP groups at the first molar site, and (C) Accuracies in the MP and CP groups at the second molar site. Asterisks indicate statistically significant differences ($P < .05$).

Table 1. Overall accuracy of the implant placement (mean ± standard deviation)

Protocol	Vertical (mm)	Angular (°)	Platform (mm)	Apex (mm)
Modified	0.75 ± 0.37	4.36 ± 1.57	1.42 ± 0.55	1.91 ± 0.42
Conventional	0.86 ± 0.33	4.96 ± 1.47	1.48 ± 0.25	2.23 ± 0.63

Table 2. Subgroup analysis of the accuracy of the implant placement analysis (mean ± standard deviation)

	Protocol	Vertical (mm)	Angular (°)	Platform (mm)	Apex (mm)
(a) Accuracy of the implant placement based on the implanted sites					
First molar	Modified	0.96 ± 0.37	3.68 ± 1.99	1.18 ± 0.31	1.62 ± 0.47
	Conventional	1.07 ± 0.32	4.24 ± 1.14	1.26 ± 0.28	1.89 ± 0.62
Second molar	Modified	0.53 ± 0.44	5.04 ± 1.86	1.66 ± 1.00	2.20 ± 0.61
	Conventional	0.65 ± 0.43	5.68 ± 2.60	1.71 ± 0.49	2.56 ± 0.98
(b) Accuracy of the implant placement based on the surgeons' experience					
Experts	Modified	0.96 ± 0.37	3.68 ± 1.99	1.18 ± 0.31	1.62 ± 0.47
	Conventional	1.07 ± 0.32	4.24 ± 1.14	1.26 ± 0.28*	1.89 ± 0.62*
Beginners	Modified	0.53 ± 0.44	5.04 ± 1.86	1.66 ± 1.00	2.20 ± 0.61
	Conventional	0.65 ± 0.43	5.68 ± 2.60	1.71 ± 0.49*	2.56 ± 0.98*
(c) Accuracy of the implant placement based the surgeons' experience in the first molar site					
Experts	Modified	0.81 ± 0.28	4.06 ± 2.59	1.11 ± 0.24	1.66 ± 0.55
	Conventional	1.06 ± 0.18	4.06 ± 1.49	1.26 ± 0.24	1.70 ± 0.39
Beginners	Modified	1.12 ± 0.41	3.31 ± 1.29	1.25 ± 0.38	1.58 ± 0.41
	Conventional	1.07 ± 0.45	4.43 ± 0.76	1.26 ± 0.34	2.09 ± 0.78
(d) Accuracy of the implant placement based the surgeons' experience in the second molar site					
Experts	Modified	0.27 ± 0.33 ⁺	5.42 ± 1.95	1.94 ± 0.38	2.33 ± 0.67
	Conventional	0.48 ± 0.41	4.54 ± 1.72	1.33 ± 0.29*	1.99 ± 0.70*
Beginners	Modified	0.80 ± 0.38 ⁺	4.67 ± 1.86	1.38 ± 0.38 [#]	2.06 ± 0.58 [#]
	Conventional	0.83 ± 0.42	6.83 ± 2.95	2.08 ± 0.35 ^{*,#}	3.13 ± 0.92 ^{*,#}

⁺ Statistical significance found between the experts and beginners within the modified protocol ($P < .05$).

^{*} Statistical significance found between the experts and beginners within the conventional protocol ($P < .05$).

[#] Statistical significance found between the modified and conventional protocols within the beginners ($P < .05$).

ations than the MP group, but none of the intergroup comparisons were statistically significant.

In the CP group, the implants placed by the experts showed smaller values for all deviations than those placed by the beginners, but the differences were statistically significant only for the platform deviation (1.30 ± 0.14 mm vs. 1.67 ± 0.17 mm) and the apex deviation (1.85 ± 0.23 mm vs. 2.61 ± 0.69 mm) ($P < 0.05$). In contrast, none of the deviations in the MP group differed significantly between the experts and beginners.

Comparing the accuracy between the experts and beginners at each implanted site revealed no signifi-

cant differences at the first molar site. At the second molar site, the beginners exhibited significantly larger platform and apex deviations (2.08 ± 0.35 mm and 3.13 ± 0.92 mm, respectively) compared with the experts (1.33 ± 0.29 mm and 1.99 ± 0.70 mm, respectively) when the surgery was performed using the CP ($P < .05$), and the vertical deviation when using the MP was significantly larger for the beginners (0.80 ± 0.38 mm) than for the experts (0.27 ± 0.33 mm, $P < .05$).

Intergroup comparisons of accuracy between the CP and MP for the experts and beginners at each implanted site revealed no significant difference when

the implant was placed at the first molar site by either the experts or the beginners. At the second molar site, the experts showed similar accuracies when using the CP and MP, whereas the platform and apex deviations for the beginners were significantly larger when the implant was placed using the CP than when using the MP (2.08 ± 0.35 mm vs. 1.38 ± 0.38 mm, $P < .05$; and 3.13 ± 0.92 mm vs. 2.06 ± 0.58 mm, $P < .05$; respectively).

The total time required to perform the osteotomy and fixture installation was significantly longer for the MP group (484.8 ± 108.2 sec) than for the CP group (390.8 ± 81.3 sec, $P < .05$). The procedure time did not differ significantly between the experts and beginners either for the CP or MP surgery. The results are listed in Table 3.

DISCUSSION

This study investigated the positional accuracies of fully guided implant placement using a mucosa-supported surgical template with two surgical protocols: the CP and the MP. The deviations for all of the measured parameters were slightly higher in the CP group than in the MP group. Comparing the accuracies for the MP revealed that the experts and beginners performed similarly, whereas the linear platform and apex deviations were larger for the beginners than for the experts for the surgery using the CP, especially at the second molar site where it was farther from the adjacent natural tooth.

A previous systematic review reported that changing the plan made prior to surgery is one of the intra-operative complications of fully guided implant surgery,¹² and this may occur due to displacement of the implant fixture during the installation stage. A me-

ta-analysis found that the mean linear deviation was 1.12 mm at the entry point and 1.39 mm at the apex.¹² Another review found similar mean platform, apex, and angular deviations of 0.99 mm, 1.24 mm, and 3.81° , respectively.⁶ The mean linear and angular deviations in the present CP and MP groups were larger (> 1.4 mm and $> 4^\circ$, respectively) than the aforementioned results, which is probably attributable to the use of a mucosa-supported template in cases of distal extension. This outcome is supported by several previous studies' finding that performing flapless implant surgery results in the surgical guide being more stable when it is supported by the mucosa than by the tooth,^{2,6,12} which is considered to be due to the mucosal resilience that eventually causes unwanted class-I lever movement of the template.¹³

The deviation was smaller at the second molar site when the implants were placed using the MP rather than the CP in the present study. A recently reported multilevel regression analysis found that when a mucosa-supported surgical stent was used for fully guided implant placement, the deviations were significantly larger when the implant site was farther from the most-posterior natural tooth located mesial to the edentulous site.² This was attributed to the rigidity of the resin-based surgical guide and the magnitude of class-I lever movement, which respectively decrease and increase as the implant is positioned farther from the adjacent natural tooth, and this problem could be controlled by the use of a distal anchor pin.² In the present study, the use of an extra drill and fixture mount placed at the first molar site during the osteotomy and fixture installation phases seemed to move the fulcrum distal from the most-posterior natural tooth to the first molar implant site, which consequently reduced the class I lever movement.

Table 3. Procedure time (seconds, mean \pm standard deviation)

	Procedure time	Surgeons' experience	Procedure time
Modified	$484.8 \pm 108.2^{\#}$	Experts	440.0 ± 81.5
		Beginners	529.5 ± 119.5
Conventional	$390.8 \pm 81.3^{\#}$	Experts	401.7 ± 91.7
		Beginners	379.8 ± 76.5

[#] Statistical significance found between the modified and conventional protocols ($P < .05$).

In the same vein, utilizing the extra drill at the second molar site is thought to have reduced the deviation at the first molar site. Numerous previous studies found that the stability of the surgical guide and placement accuracy could be optimized when fixed structures such as natural teeth or anchor pins are located both mesial and distal to the implant site.^{8,14-18} In the MP group of the present study, placing the extra drill at the second molar site while performing the osteotomy and during the installation stages at the first molar site increased the stability of the template and make the mucosa-supported guide resemble the tooth- or anchor-pin-supported one. This suggests that this simple modification to the surgical protocol is a useful alternative to placing the anchor pin distal to the mucosa-supported stent, which could be beneficial in terms of both avoiding having to use an additional instrument and reducing the surgical invasiveness.

Even though the accuracy improved, it took a mean of approximately 1.5 minutes (94 seconds) longer for the surgeons to place the implant using the MP compared with using the CP. This seemed to be obvious given that the osteotomy procedure for the MP is more complicated than that for the CP, which could be considered a drawback. However, this time difference between the two groups is not clinically important given that it usually takes tens of minutes to place the implant and, more importantly, the procedure time did not differ markedly between the experts and beginners, which implies that the experience level of the surgeon does not affect how the MP is implemented.

Whether the accuracy during guided implant surgery is lower for less experienced surgeons is controversial. Previous *in vitro* studies found that the accuracy was lower for less experienced implant surgeons than for the more experienced ones.^{19,20} A clinical study found that implants tended to be placed less accurately by dentists who were in the beginning of their professional career, especially in the buccolingual direction when they performed guided implant placement.²¹ There was also a warning from the European Association for Osseointegration Consensus Conference in 2012 that more training was needed to increase the accuracy of fully guided surgery.²² In contrast, recently reported studies have suggested that there is no significant difference in placement accu-

accuracy between more experienced and less experienced surgeons, as verified both *in vitro*¹¹ and clinically.^{3,4,23} However, those data should be interpreted with caution since the included less experienced surgeons were mostly trainees and so were supervised by experts during the procedures.^{3,4,23}

When the surgery method was based on the CP, the deviations caused by the beginners were significantly larger than those caused by the experts, especially at the platform and apex levels. It seemed that the inaccuracy occurring at the second molar site by the beginners critically contributed to this difference, since the deviations did not differ significantly between the experts and beginners at the first molar site. At the second molar site, the difference in the apex deviation between the beginners and experts in the CP group was noticeably larger than the difference in the platform deviation, which could be attributed to the circular movement of class-I lever movement appearing in the distal end part of the surgical guide. Since this lever movement starts from the platform level of the fixture and ends at its apex level, when the distal-end part of the surgical template rotates apically around the most posterior natural tooth, the deviation between the planned and actually placed positions is more likely to be larger at the apex level than at the platform level. It could be cautiously assumed that the large discrepancies that occurred when the beginners were performing the CP surgery resulted from pressure applied to the distal-free-end part of the surgical guide during the implant installation being higher than that applied by the experts. This pressure seemed to have had smaller influence when the surgery was performed using the MP because placing the extra drill or fixture mount at the first molar site moved the fulcrum point distally, which consequently shortened the range of lever movement. This assumption may explain why the difference observed between the experts and beginners in the MP group became smaller, with statistical significance seen only in the vertical deviation among the four measured parameters.

Some limitations of this study should be mentioned. Firstly, placing the anchor pin at a distal position was not included as an individual group. This needs to be compared with the MP as a positive control group in

the future. Secondly, given that the difference in displacement observed between the MP and CP mostly did not exceed 1 mm, the improvement provided by the MP might not be clinically significant. Indeed, a previous systematic review stated that a deviation of up to 2 mm was unlikely to cause any critical problem regarding anatomic considerations, such as avoiding the mandibular canal or the mental foramen during the surgery.²⁴ Nonetheless, most clinicians would agree that digital dentistry-based fully guided implant surgery has become the foundation for prosthetic-driven treatment and the immediate delivery of a prefabricated prosthesis.²⁵⁻²⁷ Therefore, the accuracy of fully guided implant placement should be improved in order to reach the clinically acceptable limit for passive prosthesis fitting, which is currently known to be below 150 μm .^{28,29} Based on the outcomes obtained in the present *in vitro* study, further research should be performed at the *in vivo* and clinical levels.

CONCLUSION

When placing the implant by the fully guided implant surgery using a mucosa-supported template, modifying the sequence of osteotomy and installation utilizing the spare drills and fixture mounts may enhance the accuracy of implant placement compared to the surgery driven by conventional sequence, and the enhancement was more prominent at sites farther from the most posterior natural tooth. This new protocol could potentially be a useful option for improving the outcomes of mucosa-supported guide-based implant placement in situations when an anchor pin cannot be utilized.

ACKNOWLEDGEMENTS

We are very grateful to the 12 periodontal residents of Yonsei University Dental Hospital who participated in this research.

REFERENCES

1. D'haese J, Ackhurst J, Wismeijer D, De Bruyn H, Tahmaseb A. Current state of the art of computer-guided implant surgery. *Periodontol* 2000 2017;73:121-33.
2. Park JY, Song YW, Park SH, Kim JH, Park JM, Lee JS. Clinical factors influencing implant positioning by guided surgery using a nonmetal sleeve template in the partially edentulous ridge: Multiple regression analysis of a prospective cohort. *Clin Oral Implants Res* 2020;31:1187-98.
3. Song YW, Park JY, Jung JY, Kim JN, Hu KS, Lee JS. Does the fixture thread depth affect the accuracy of implant placement during fully guided immediate implant placement?: A human cadaver study. *Clin Oral Implants Res* 2023;34:116-26.
4. Cassetta M, Giansanti M, Di Mambro A, Stefanelli LV. Accuracy of positioning of implants inserted using a mucosa-supported stereolithographic surgical guide in the edentulous maxilla and mandible. *Int J Oral Maxillofac Implants* 2014;29:1071-8.
5. Verhamme LM, Meijer GJ, Soehardi A, Bergé SJ, Xi T, Maal TJJ. An accuracy study of computer-planned implant placement in the augmented maxilla using osteosynthesis screws. *Int J Oral Maxillofac Surg* 2017;46:511-7.
6. Van Assche N, Vercruyssen M, Coucke W, Teughels W, Jacobs R, Quirynen M. Accuracy of computer-aided implant placement. *Clin Oral Implants Res* 2012;23 Suppl 6:112-23.
7. Zhou W, Liu Z, Song L, Kuo CL, Shafer DM. Clinical factors affecting the accuracy of guided implant surgery-a systematic review and meta-analysis. *J Evid Based Dent Pract* 2018;18:28-40.
8. Matsumura A, Nakano T, Ono S, Kaminaka A, Yatani H, Kabata D. Multivariate analysis of causal factors influencing accuracy of guided implant surgery for partial edentulism: a retrospective clinical study. *Int J Implant Dent* 2021;7:28.
9. Orgev A, Pellerito J, Polido W, Morton D, Lin WS. Bead-anchored surgical templates for static computer-assisted implant surgery: A dental technique. *J Prosthodont* 2022;31:722-7.
10. Kalpidis CD, Setayesh RM. Hemorrhaging associated with endosseous implant placement in the anterior mandible: a review of the literature. *J Periodontol* 2004;75:631-45.
11. Song YW, Kim J, Kim JH, Park JM, Jung UW, Cha JK. Accuracy of dental implant placement by a novel in-house model-free and zero-setup fully guided surgical

- template made of a light-cured composite resin (VARO Guide®): a comparative in vitro study. *Materials (Basel)* 2021;14:4023.
12. Tahmaseb A, Wismeijer D, Coucke W, Derksen W. Computer technology applications in surgical implant dentistry: a systematic review. *Int J Oral Maxillofac Implants* 2014;29 Suppl:25-42.
 13. Vasak C, Watzak G, Gahleitner A, Strbac G, Schemper M, Zechner W. Computed tomography-based evaluation of template (NobelGuide™)-guided implant positions: a prospective radiological study. *Clin Oral Implants Res* 2011;22:1157-63.
 14. Arisan V, Karabuda ZC, Ozdemir T. Accuracy of two stereolithographic guide systems for computer-aided implant placement: a computed tomography-based clinical comparative study. *J Periodontol* 2010;81:43-51.
 15. Cassetta M, Stefanelli LV, Giansanti M, Di Mambro A, Calasso S. Depth deviation and occurrence of early surgical complications or unexpected events using a single stereolithographic surgi-guide. *Int J Oral Maxillofac Surg* 2011;40:1377-87.
 16. Cassetta M, Stefanelli LV, Giansanti M, Di Mambro A, Calasso S. Accuracy of a computer-aided implant surgical technique. *Int J Periodontics Restorative Dent* 2013;33:317-25.
 17. D'haese J, Van De Velde T, Elaut L, De Bruyn H. A prospective study on the accuracy of mucosally supported stereolithographic surgical guides in fully edentulous maxillae. *Clin Implant Dent Relat Res* 2012;14:293-303.
 18. Di Giacomo GA, Cury PR, de Araujo NS, Sendyk WR, Sendyk CL. Clinical application of stereolithographic surgical guides for implant placement: preliminary results. *J Periodontol* 2005;76:503-7.
 19. Cho UH, Yu W, Kyung HM. Root contact during drilling for microimplant placement. Affect of surgery site and operator expertise. *Angle Orthod* 2010;80:130-6.
 20. Cushen SE, Turkeyilmaz I. Impact of operator experience on the accuracy of implant placement with stereolithographic surgical templates: an in vitro study. *J Prosthet Dent* 2013;109:248-54.
 21. Marei HF, Abdel-Hady A, Al-Khalifa K, Al-Mahalawy H. Influence of surgeon experience on the accuracy of implant placement via a partially computer-guided surgical protocol. *Int J Oral Maxillofac Implants* 2019;34:1177-83.
 22. Sicilia A, Botticelli D; Working Group 3. Computer-guided implant therapy and soft- and hard-tissue aspects. The Third EAO Consensus Conference 2012. *Clin Oral Implants Res* 2012;23 Suppl 6:157-61.
 23. Van de Wiele G, Teughels W, Vercruyssen M, Coucke W, Temmerman A, Quirynen M. The accuracy of guided surgery via mucosa-supported stereolithographic surgical templates in the hands of surgeons with little experience. *Clin Oral Implants Res* 2015;26:1489-94.
 24. Tahmaseb A, Wu V, Wismeijer D, Coucke W, Evans C. The accuracy of static computer-aided implant surgery: A systematic review and meta-analysis. *Clin Oral Implants Res* 2018;29 Suppl 16:416-35.
 25. Chen Z, Li J, Sinjab K, Mendonca G, Yu H, Wang HL. Accuracy of flapless immediate implant placement in anterior maxilla using computer-assisted versus free-hand surgery: A cadaver study. *Clin Oral Implants Res* 2018;29:1186-94.
 26. Tahmaseb A, De Clerck R, Aartman I, Wismeijer D. Digital protocol for reference-based guided surgery and immediate loading: a prospective clinical study. *Int J Oral Maxillofac Implants* 2012;27:1258-70.
 27. Younes F, Cosyn J, De Bruyckere T, Cleymaet R, Bouckaert E, Eghbali A. A randomized controlled study on the accuracy of free-handed, pilot-drill guided and fully guided implant surgery in partially edentulous patients. *J Clin Periodontol* 2018;45:721-32.
 28. Castillo-de-Oyagüe R, Sánchez-Turrión A, López-Lozano JF, Albaladejo A, Torres-Lagares D, Montero J, Suárez-García MJ. Vertical misfit of laser-sintered and vacuum-cast implant-supported crown copings luted with definitive and temporary luting agents. *Med Oral Patol Oral Cir Bucal* 2012;17:e610-7.
 29. Jemt T. Failures and complications in 391 consecutively inserted fixed prostheses supported by Brånemark implants in edentulous jaws: a study of treatment from the time of prosthesis placement to the first annual checkup. *Int J Oral Maxillofac Implants* 1991;6:270-6.