



Accessory infraorbital foramen location using cone-beam computed tomography

Daesung An¹, Kumar K C², Chakorn Vorakulpipat¹, Supak Ngamsom³, Thongnard Kumchai⁴, Sunya Ruangsitt⁴, Teeranut Chaiyasamut¹, Natthamet Wongsirichat⁴

¹Department of Oral & Maxillofacial Surgery, Faculty of Dentistry, Mahidol University, Bangkok, Thailand

²Department of Oral and Maxillofacial surgery, OM Samaj Dental Hospital, Naikap, Kathmandu, Nepal

³Oral and Maxillofacial Radiology Department, Faculty of Dentistry, Mahidol University, Bangkok, Thailand

⁴Oral and Maxillofacial Surgery Department, Faculty of Dentistry, Bangkokthonburi University, Bangkok, Thailand

Background: Accessory infraorbital foramen (AIOF) can change the normal course of emerging branches of the infraorbital nerve and blood vessels exiting the infraorbital foramen (IOF). This study aimed to examine the AIOF, number of foramina, and their position in relation to IOF using cone-beam computed tomography (CBCT).

Methods: We performed a retrospective CBCT assessment of hospital records between January 2018 and August 2022. The CBCT of 507 patients were examined to extract information on the prevalence, number, position, linear distance from the IOF, and diameter of AIOF in relation to demographic factors. Descriptive statistics were used to evaluate the prevalence of AIOF. Mean and standard deviation were used to calculate the linear distance and diameter of the AIOF, respectively. The AIOFs, its distribution, and number were compared between sexes and sides using the chi-square test. The independent t-test and Mann–Mann-Whitney test were used to compare the mean difference between the sexes and sides. Statistical significance was set at $P < 0.05$.

Results: In this current study, the prevalence of AIOF was 7.1% (36 of the 507 patients). Additionally, the current study examined the number of foramina using a single foramen on each side and double foramina located bilaterally at a distance from the AIOF to the IOF. The mean AIOF diameter was also studied, and the AIOF position with respect to the IOF on CBCT was superomedial or inferomedial. There were no statistically significant associations between any of the parameters assessed in this study when comparing sex and sides.

Conclusions: A greater number of patients with AIOF presented with a single foramen and unilateral occurrence, without a statistically significant difference. The AIOF was most commonly located superomedial to the IOF.

Keywords: Accessory Infraorbital Foramen; Infraorbital Foramen; Prevalence; Thailand.



This is an Open Access article distributed under the terms of the Creative Commons Attribution Non-Commercial License (<http://creativecommons.org/licenses/by-nc/4.0/>) which permits unrestricted non-commercial use, distribution, and reproduction in any medium, provided the original work is properly cited.



INTRODUCTION

The infraorbital foramen (IOF) is an opening on the maxillary bone below the infraorbital rim. It carries the infraorbital nerve (ION), which divides into the inferior palpebral, nasal, and superior labial branches (Fig. 1).

Previous studies have demonstrated an accessory infraorbital foramen (AIOF) through which some fibers of the ION and vessels transverse [1-3]. During regional nerve block of the ION, and if the AIOF is present, some terminal fibers may escape, resulting in inadequate analgesia and anesthesia when using a desired technique [4].

Received: June 3, 2023 • Revised: July 24, 2023 • Accepted: August 28, 2023

Corresponding Author: Teeranut Chaiyasamut, D.D.S., Grad. Dip. In Clin. Sc. (Oral & Maxillofacial Surgery), Diplomate, Thai Board of Oral & Maxillofacial Surgery Department of Oral & Maxillofacial Surgery, Faculty of Dentistry, Mahidol University, 6 Yothi Street Rachathewe District Bangkok 10400 Thailand

Tel: +66 02 200 7845 E-mail: teeranut.cha@gmail.com

Copyright© 2023 Journal of Dental Anesthesia and Pain Medicine

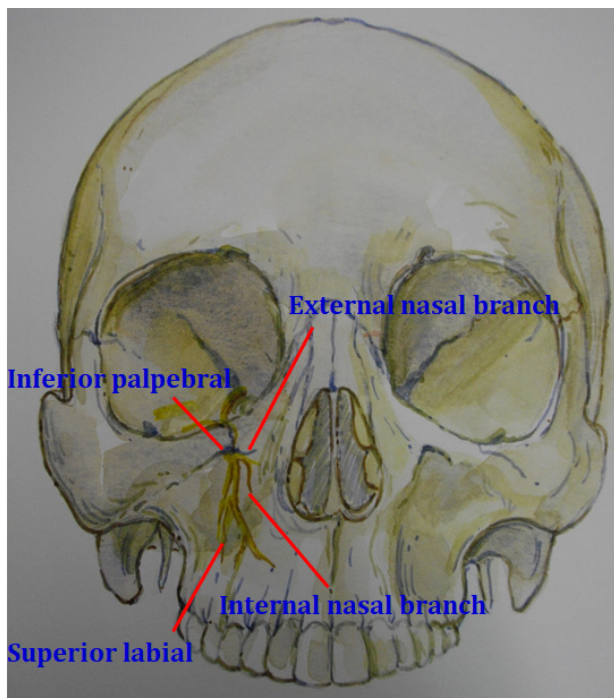


Fig. 1. Infraorbital foramen carrying the inferior palpebral, nasal, and superior labial branches to supply the skin of the lower eyelid etc.

However, significant evidence has revealed variations in AIOF morphology and relative positions among different populations [5-9].

Therefore, knowing the precise AIOF localization is crucial for providing an effective ION block and preventing any injury to the ION during mid-facial operations, such as orthognathic surgery, cosmetic operations, and midfacial fracture treatment [9]. Despite its clinical relevance, there is limited information on the details and location of AIOF.

With the development of cone-beam computed tomography (CBCT) for the maxillofacial area, dental surgeons can now employ numerous imaging planes. Cone-beam computed tomography can provide multiplanar images, including axial, sagittal, and coronal views [10]. Therefore, many researchers now choose three-dimensional (3D) CBCT analysis to evaluate maxillomandibular morphology, which provides better image resolution, shorter time, lower radiation dose, and lower cost.

Various anatomical studies on AIOF using dry human skulls, cadavers, and CBCT have been reported [5-9, 11-15]. Two studies by Agthong [12] and Apinhasmit [13]

on Thai dry human skulls have showed a 4% frequency of AIOF occurrence. To the best of our knowledge, no previous study has evaluated the prevalence and location of AIOF using CBCT in a Thai population. Therefore, this study aimed to examine the presence of AIOF, number of foramina, and AIOF position in relation to IOF in the Thai population using CBCT.

METHODS

A retrospective CBCT evaluation of the prevalence, number, and location of AIOF using CBCT images and its relationship with patient factors was performed at the Department of Oral and Maxillofacial Surgery and Department of Oral and Maxillofacial Radiology, Faculty of Dentistry, Mahidol University, Thailand. Ethical clearance was obtained from the Mahidol University Institutional Review Board (MU-IRB) (certificate of approval No. MU-DT/PY-IRB 2021/061.0207 and project number 2121/DT059).

1. Sample size

The sample size was estimated using an infinite population proportion equation [16,17]. A study by Ali et al. in 2018 found 29% of patients (58 of 200) with AIOF [5]. Assuming that 29% of the population had a factor of interest, the study would require a sample size of 317 [5].

2. Inclusive criteria

The study participants were patients who underwent CBCT at the Oral and Maxillofacial Radiology Clinic, Faculty of Dentistry, Mahidol University between January 2018 and August 2022 aged ≥ 18 years old. All CBCT images were obtained using Kodak CS9500 (Carestream, New York, NY, USA).

3. Exclusive criteria

Cone-beam computed tomography of patients with congenital anomalies or syndromes with signs in the head

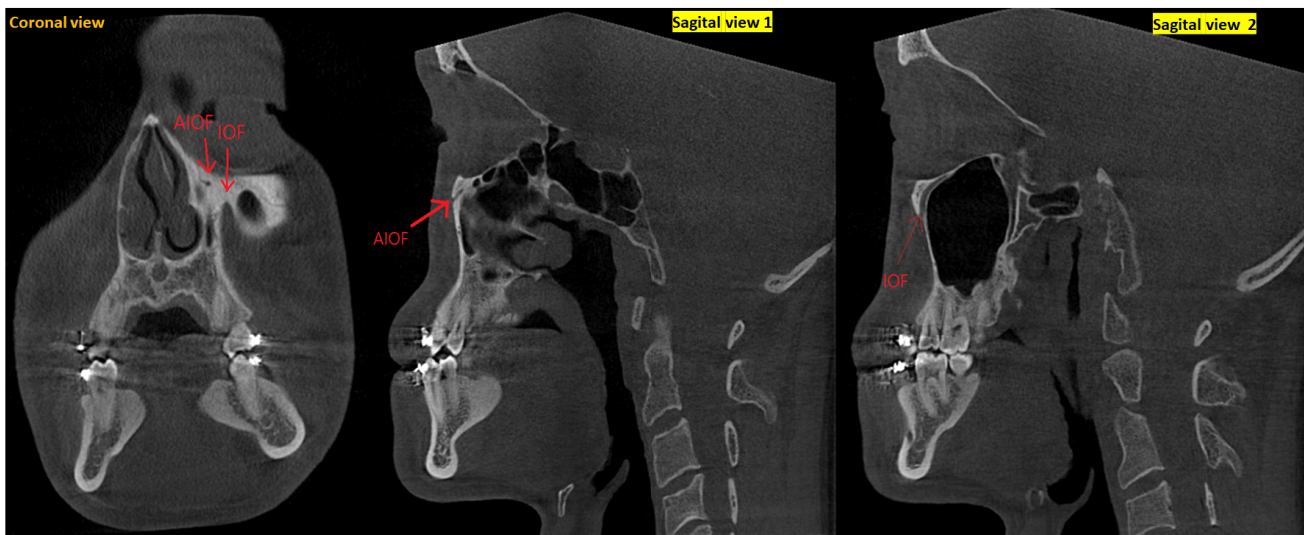


Fig. 2. Cone-beam computed tomography in the planes showed Infraorbital foramen and accessory infraorbital foramen. AIOF, accessory infraorbital foramen; IOF, infraorbital foramen.

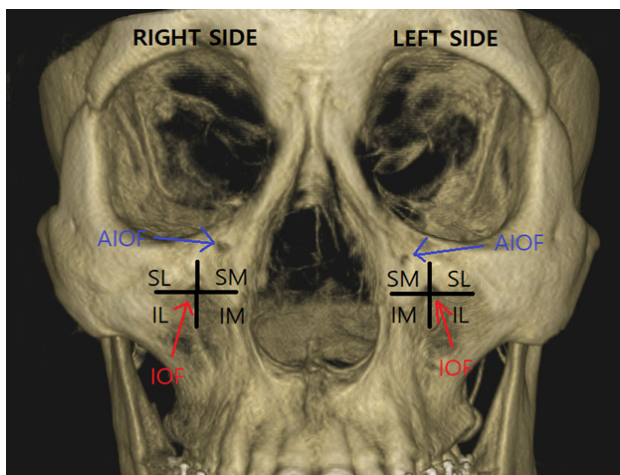


Fig. 3. Anatomical landmarks between right and left sides showing the infraorbital foramen in red circle and four probable positions of an accessory infraorbital foramen. AIOF, accessory infraorbital foramen; IL, inferolateral; IM, inferomedial; IOF, infraorbital foramen; SL, superolateral; SM, superomedial.

and neck region, including Turner syndrome and skeletal dysplasia, history of previous trauma, surgical procedures in the midfacial region that might have affected the actual IOF anatomy, and inadequate CBCT images, such as blurred images or severe artifacts, were excluded from the study.

4. Patients' demographic data

Patients' demographic data, including age and sex, were recorded. The IOF and AIOFs were evaluated using

a CBCT viewer (CS 3D imaging, Carestream Dental) equipped with the same monitor under dim light.

Examiners were allowed to freely move the CBCT scanner in all three planes (axial, sagittal, and coronal) and permitted to adjust the orientation tools, such as magnification, brightness, and contrast (Fig. 2). The infraorbital and main foramina were identified as the largest and most prominent foramina, respectively (Fig. 1). The relationship between the main foramen and AIOF location was noted in four areas surrounding the main foramen (Fig. 3).

The AIOFs were evaluated based on the number recorded as single, double, or multiple (if >2 foramina were present) on either side. The linear distance (mm) of the AIOFs to the center of the main foramen and AIOF diameter (mm) were measured using the ruler function in the CS 3D imaging program. The largest accessory foramen was used as a reference point when multiple accessory foramina were present. All data were recorded in pro forma format.

5. Statistical analysis

All data were recorded on an Excel spreadsheet and transferred to SPSS (version 22.0; IBM Corp., Armonk, NY, USA) for statistical analysis. Descriptive statistics were used to evaluate the prevalence of AIOF. The linear

Table 1. Demographic data of patients

	Total number assessed (%)	Mean age (years)
Male	167 (33%)	27.14
Female	340 (67%)	27.58

Table 2. Distribution of accessory infraorbital foramen (present/absent) according to sex

	Male	Female	Total	P-value
AIOF Present	10	26	36	0.494
AIOF Absent	157	314	471	
Total	167	340	507	

chi-square test. AIOF, accessory infraorbital foramen.

Table 3. Distribution of total accessory infraorbital foramen present according to sex

Case character	Male	Female	Total	P-value
Bilateral cases	5	7	12	0.420
Unilateral Right cases	2	8	10	
Unilateral Left cases	3	11	14	
Total	10	26	36	

Association of number of Accessory infraorbital Foramen between Sides and Sex

	Number of foramina	Male	Female	Total	P-value
Right side	One foramen	7	13	20	0.456
	Two foramina	0	2	2	
	Total	7	15	22	
Left side	One foramen	8	18	26	0.518
Total		15	33	48	

chi-square test

distance from the AIOFs to the main foramen and AIOF diameter were reported using mean and standard deviation.

The presence, distribution, and number of AIOFs were compared between sexes and sides using the chi-square test. The independent t-test and Mann-Mann-Whitney test were used to compare the mean difference between the sexes and sides. Statistical significance was set at $P < 0.05$.

Before data collection, the principal investigator was calibrated by an oral and maxillofacial radiologist to evaluate 20% of the participants. The inter-rater reliability was 0.948, based on a Cohen’s kappa analysis [18]. The principal investigator evaluated the data twice within two weeks interval. The intra-rater reliability was 0.893, based on the Cohen’s kappa analysis [18].

RESULTS

A total of 507 patients were assessed to identify the AIOF, of which 340 (67%) were females, with an average

age of 27.4 years (range: 18–51 years) (Table 1). The Accessory AIOF was recognized in 36 patients (prevalence rate: 7.1%; 95% confidence interval, 4.8–9.3%), among whom single foramen was present in 10 (1.9%) on the right side only, 14 (2.7%) on the left side only, and 12 (2.3%) located bilaterally. Multiple AIOFs (two foramina) were present in two patients on the unilateral right side only. The distribution of AIOF in relation to sex did not differ significantly (Tables 2 and 3; $P > 0.05$). The number of AIOFs between the sides and sexes did not show a statistically significant difference (Table 3; $P > 0.05$).

The mean distance of AIOF from the IOF was measured as 5.12 ± 2.08 mm on the right side and 5.13 ± 1.84 mm on the left side. When comparing the mean distances on both sides between males and females, there was no statistically significant difference (Table 4; $P > 0.05$).

The mean diameter of AIOF was measured to be 0.69 ± 0.18 mm on the right side and 0.80 ± 0.29 mm on the left side. A comparison of the mean AIOF diameter on both sides between the males and females showed no

Table 4. Distance and diameter of accessory infraorbital foramen from infraorbital foramen compared between sides and sex

	Male (Mean \pm SD)	Female (Mean \pm SD)	P-value
Distance on Right side (mm)	n = 7 5.25 \pm 2.79	n = 15 5.06 \pm 1.77	0.944*
Distance on Left side (mm)	n = 8 5.51 \pm 2.11	n = 18 4.96 \pm 1.68	0.483 [†]
AIOF diameter on Right side (mm)	n = 7 0.64 \pm 0.15	n = 15 0.71 \pm 0.20	0.425 [†]
AIOF diameter on Left side (mm)	n = 8 0.90 \pm 0.41	n = 18 0.75 \pm 0.23	0.396*

*Mann-Whitney U test

[†]Independent sample t-test

AIOF, accessory infraorbital foramen; SD, standard deviation.

Table 5. Distribution of position of accessory infraorbital foramen compared between sex and sides

Position of foramen	Male	Female	Total	P-value
Superomedial	9	24	33	0.185
Inferomedial	0	2	2	
Inferolateral	1	0	1	
Total	10	26	36	

Sides	Superomedial	Inferomedial	Inferolateral	Total	P-value
Unilateral Right	10	0	0	10	0.273
Unilateral Left	11	2	1	14	
Bilateral	12	0	0	12	
Total	33	2	1	36	

chi-square test

statistically significant difference (Table 4; $P > 0.05$). The position of AIOF with respect to the IOF on CBCT revealed that 33 (91.6%) patients had the foramen in a superomedial area, two (5.5%) patients in an inferomedial position, and the remaining one patient in an inferolateral position. A comparison of the position with respect to sex and side showed no statistically significant differences (Table 5; $P > 0.05$).

DISCUSSION

In this retrospective CBCT evaluation, the prevalence, number, position, linear distance from the IOF and diameter of AIOF were assessed in relation to demographic factors. The results of this study showed no statistically significant association between sex and side. The prevalence rate in this study was 7.1%, which is close to 8.6% found in a study by Sokhn et al. [7]. In human

CBCT assessment studies by Ali et al. [5], Dagistan et al. [6], and Rusu et al. [8], they demonstrated higher AIOF prevalence rates of 29%, 56%, and 13%, respectively, compared to this study. However, a study by Orhan et al. showed no AIOF in 177 patients [9].

In 2022, Suntirumjairucksa and Chentanez studied 216 dry skulls in Thailand and found 19.91% prevalence of AIOF [11]. Overall, the prevalence rate in this study was corroborated by a systematic review conducted in 2015 that revealed the prevalence of AIOF in skulls and cadavers ranging between 0.8–27.3% [19].

In this study, the AIOF was equally distributed among males and females, which is similar to the results of previous studies [6–8]. In this study, a higher number of the AIOF (34 of 36 patients with AIOF) was documented as a single number, regardless of the side of occurrence. Only two patients with AIOF had multiple foramina, and each patient had two foramina.

A 2017 study by Ali et al. showed that six of 58

individuals with AIOF had multiple AIOF, with two AIOFs present in five patients and three in one patient [5]. Dagistan reported that two accessory foramina were present in most patients (133 of 250 sides) [6].

In a study by Rusu et al., approximately 94% of patients with AIOF (29 of 31 patients) had single foramen, while there were double and triple foramina in each remaining patient. Approximately 7.6% of 105 Lebanese adults have one accessory foramen, while 1% of them possessed two accessory foramina in a study by Sokhn et al. [7]. A larger number of identified patients with AIOF had unilateral occurrence with a single foramen in this study (22 of 36 patients with AIOF), which is consistent with previous studies [6-8,11].

The accessory foramina were equally distributed between the sexes and sides in this study. The bilateral occurrence of AIOF in this study was 33.33% (12 of 36 AIOFs), which was inconsistent with previous studies performed in human CBCT ranging between 13-22.4% [5, 14]. These discrepancies could be due to variability in the population, racial groups, and sample sizes.

The mean distance of the AIOFs from the IOFs in this study was greater (5 mm) when compared with that in a study by Ali et al. (right side, mean distance = 1.03 mm; left side, 0.81 mm) [5]. In this study, 92% of the AIOFs were located at a superomedial position. According to the study by Ali et al., 70.7% of the AIOFs were found superomedially, with the remaining cases being situated inferomedially with regard to the IOF. Additionally, the majority of AIOFs in the study by Suntiruanjairucksa and Chentanez were situated superomedially to the IOF, with the exception of three cases, which were situated inferolaterally [11]. The results of this study and others were inconsistent with those of the study by Rusu et al. [8], in which all identified AIOFs were inferior to the IOF.

The mean diameter of the AIOF in this study was <1 mm, which is in contrast to that in the study by Sokhn et al. (approximately 3 mm). Such a small foramen can be missed on other radiographs, such as orthopantomograms. Thus, CBCT has a higher spatial

resolution, which offers the advantage of identifying a foramen, such as the AIOF, irrespective of the size.

Accessory infraorbital foramen is an anatomical variant corresponding to IOF and ION. Based on this study, AIOF can be found unilaterally or bilaterally as a single or double foramina, or in multiple numbers, as identified in other studies [19]. Furthermore, from a surgical standpoint, the IOF is positioned near vital tissues, including the orbital, nasal, and buccal regions. The position of the majority of AIOFs is superomedial to the IOF.

When a clinician performs an ION block, there may be inadequate anesthesia and analgesia if an accessory infraorbital nerve is present, as well as a risk of nerve injury. Therefore, recognition of the location and composition of the ION and existence of the AIOF and nerve branches is crucial to deliver effective and precise analgesia for smooth surgical procedures. Whenever there is an infraorbital fracture on CBCT, proper preoperative assessment of the presence of AIOF should be performed before reduction and plate placement to protect the neurovascular bundle.

Additionally, researchers have established the existence of an AIOF through which the inferior palpebral and external nasal branches of the ION pass to innervate the face, upper lip, nasal area, and eyelids [1]. From the results of this study, clinicians can locate the AIOF in the superomedial position within 5 mm of distance in most patients. Supplementary anesthesia may be required at this site if an AIOF is identified.

The larger sample size in this study provides more strength than earlier studies with smaller sample sizes.

Additionally, the accuracy of CBCT in identifying AIOF provided definitive results for the samples involved. The results of this study could provide additional benefits in studies related to the anatomical relationship between AIOF and IOF. The selected CBCT images in this study involved the Thai population who mostly sought orthognathic surgery at tertiary dental hospitals. Therefore, representation of the entire Thai population was not possible in this study.

In conclusion, this retrospective CBCT assessment reported a 7.1% prevalence rate of AIOF. A greater number of patients with AIOF presented with a single foramen and unilateral occurrence, although the difference was not statistically significant. The foramen was most frequently located superomedial to the IOF. There were no statistically significant associations between any of the parameters assessed in this study when comparing sex and sides.

AUTHOR ORCID*s*

Daesung An: <https://orcid.org/0009-0009-3531-6885>
Kumar K C: <https://orcid.org/0000-0001-9620-7388>
Chakorn Vorakulpipat: <https://orcid.org/0000-0001-6627-8732>
Supak Ngamsom: <https://orcid.org/0000-0003-1985-7744>
Thongnard Kumchai: <https://orcid.org/0000-0002-7791-9811>
Sunya Ruangsitt: <https://orcid.org/0009-0009-5163-1199>
Teeranut Chaiyasamut: <https://orcid.org/0000-0003-0487-5333>
Natthamet Wongsirichat: <https://orcid.org/0000-0003-3005-2680>

AUTHOR CONTRIBUTIONS

Daesung An: Writing - original draft
Kumar K C: Writing - review & editing
Chakorn Vorakulpipat: Conceptualization, Resources, Visualization
Supak Ngamsom: Methodology, Supervision
Thongnard Kumchai: Visualization
Sunya Ruangsitt: Resources, Visualization
Teeranut Chaiyasamut: Conceptualization, Supervision
Natthamet Wongsirichat: Resources, Supervision, Visualization, Writing - review & editing

ACKNOWLEDGMENTS: We would like to thank the staff at the Department of Oral and Maxillofacial Surgery and Radiology, Faculty of Dentistry, Mahidol University, and Bangkokthonburi University for their support throughout the study period.

DECLARATION OF INTERESTS: The authors declare no conflicts of interest.

FUNDING: This study did not receive any funding from research grants.

INFORMED CONSENT STATEMENT: Patient consent was waived because of the retrospective nature of the radiographic evaluation of hospital records.

INSTITUTIONAL REVIEW BOARD STATEMENT OR ETHICS

APPROVAL: Ethical clearance was obtained from the Mahidol University Institutional Review Board (certificate of approval No. MU-DT/PY-IRB 2021/061.0207 and project number 2121/DT059).

REFERENCES

- Hwang K, Suh MS, Chung IH. Cutaneous distribution of infraorbital nerve. *J Craniofac Surg* 2004; 15: 3-5.
- Canan S, Asim OM, Okan B, Ozek C, Alper M. Anatomic variations of the infraorbital foramen. *Ann Plast Surg* 1999; 43: 613-7.
- Kazkayasi M, Ergin A, Ersoy M, Tekdemir I, Elhan A. Microscopic anatomy of the infraorbital canal, nerve, and foramen. *Otolaryngol Head Neck Surg* 2003; 129: 692-7.
- Aggarwal A, Kaur H, Gupta T, Tubbs RS, Sahni D, Batra YK, et al. Anatomical study of the infraorbital foramen: a basis for successful infraorbital nerve block. *Clin Anat* 2015; 28: 753-60.
- Ali IK, Sansare K, Karjodkar FR, Salve P. Cone beam computed tomography assessment of accessory infraorbital foramen and determination of infraorbital foramen position. *J Craniofac Surg* 2018; 29: e124-6.
- Dagistan S, Miloğlu Ö, Altun O, Umar EK. Retrospective morphometric analysis of the infraorbital foramen with cone beam computed tomography. *Niger J Clin Pract* 2017; 20: 1053-64.
- Sokhn S, Challita R, Challita A, Challita R. The infraorbital foramen in a sample of the lebanese population: a radiographic study. *Cureus* 2019; 11: e6381.
- Rusu MC, Săndulescu M, Cârstocea L. False and true accessory infraorbital foramina, and the infraorbital lamina cribriformis. *Morphologie* 2020; 104: 51-8.
- Orhan K, Misirli M, Aksoy S, Seki U, Hincal E, Ormeci T, et al. Morphometric analysis of the infraorbital foramen, canal and groove using cone beam CT: considerations for creating artificial organs. *Int J Artif Organs* 2016; 39: 28-36.
- Scarfe WC, Farman AG, Sukovic P. Clinical applications

- of cone-beam computed tomography in dental practice. *J Can Dent Assoc* 2006; 72: 75-80.
11. Suntirumjairucksa J, Chentanez V. Localization of infraorbital foramen and accessory infraorbital foramen with reference to facial bony landmarks: predictive method and its accuracy. *Anat Cell Biol* 2022; 55: 55-62.
 12. Agthong S, Huanmanop T, Chentanez V. Anatomical variations of the supraorbital, infraorbital, and mental foramina related to gender and side. *J Oral Maxillofac Surg* 2005; 63: 800-4.
 13. Apinhasmit W, Chompoopong S, Methathrathip D, Sansuk R, Phetphunphiphat W. Supraorbital notch/foramen, infraorbital foramen and mental foramen in thais: anthropometric measurements and surgical relevance. *J Med Assoc Thai* 2006; 89: 675-82.
 14. Shin KJ, Lee SH, Park MG, Shin HJ, Lee AG. Location of the accessory infraorbital foramen with reference to external landmarks and its clinical implications. *Sci Rep* 2020 May 22; 10: 8566.
 15. Polo CL, Abdelkarim AZ, von Arx T, Lozanoff S. The morphology of the infraorbital nerve and foramen in the presence of an accessory infraorbital foramen. *J Craniofac Surg* 2019; 30: 244-53.
 16. Daniel WW, Cross CL. *Biostatistics: a foundation for analysis in the health sciences*: Wiley, 2018.
 17. Ngamjarus C, Chongsuvivatwong V, McNeil, E. *n4Studies: Sample size and power calculations for android*. The Thailand Research Fund: Prince of Songkla University. 2014.
 18. McHugh ML. Interrater reliability: the kappa statistic. *Biochem Med (Zagreb)* 2012; 22: 276-82.
 19. Hwang K, Lee SJ, Kim SY, Hwang SW. Frequency of existence, numbers, and location of the accessory infraorbital foramen. *J Craniofac Surg* 2015; 26: 274-6.