

Penetrating right ventricular injury following a single gunshot to the left flank in Iraq: a case report

Zryan Salar Majeed, MBChB^{1,2} , Yad N. Othman, MBChB¹ , Razhan K. Ali, MBChB¹ ¹Department of Thoracic and Cardiovascular Surgery, Shar Teaching Hospital, As Sulaimaniyah, Iraq²Shorsh Military Teaching Hospital, As Sulaimaniyah, Iraq

Received: November 16, 2022

Revised: December 19, 2022

Accepted: December 26, 2022

Correspondence toYad N. Othman, MBChB
Department of Thoracic and
Cardiovascular Surgery, Shar Teaching
Hospital, Malik Mahmood Circle Rd, As
Sulaimaniyah 46002, Iraq
Tel: +964-750-170-6831
Email: Yad.osman@gmail.com

A century ago, cardiac injuries usually resulted in death. However, despite all the advances in medicine, these injuries still have high mortality and morbidity rates. In the present case, we describe a patient with a bullet injury to the right ventricle who survived at our hospital despite the limitations of our center with regard to modalities and equipment. A 30-year-old man was brought to our emergency department with a bullet wound to his left flank. He was hemodynamically unstable. After only 8 minutes in the hospital and without further investigations he was rushed to the operating room. During laparotomy, a clot was visible in the left diaphragm, which dislodged and caused extensive bleeding. The decision was made to perform a sternotomy in the absence of a sternal saw. An oblique 8-cm injury to the right ventricle was discovered following rapid exploration. It was repaired without the need for cardiopulmonary bypass surgery. After a few days in the hospital, the patient was discharged home. In the event of a penetrating cardiac injury, rapid decision-making is crucial for survival. Whenever possible, the patient should be transferred to the operating room, as emergency department thoracotomies are associated with a high mortality rate.

Keywords: Penetrating cardiac injury; Gunshot; Heart ventricles; Emergency department thoracotomy; Case reports

INTRODUCTION

A hundred years ago, an injury to the heart was considered a death sentence and impossible to survive. Despite all the advances in medical technology, this condition still is highly fatal.

Although the first successful cardiac repair was done in 1896 by Ludwig Rehn, even in the modern era, up to 80% to 90% of victims sustaining a cardiac injury will not reach the hospital—only a few other conditions have such a grave prognosis [1,2]. Cardiac injuries in general are due to either penetrating or blunt

trauma [3]. Our case was a victim of the former. The survival of such patients depends on the speed of the assessment and management [3]. Although it is sometimes straightforward, the process of detecting cardiac injuries often poses a diagnostic dilemma [3]. The vast majority of patients with penetrating cardiac injuries develop cardiac tamponade rather than hemorrhage [2]. The right ventricle is more frequently injured following penetrating cardiac trauma [4,5].

Our patient was hemodynamically stable and did not exsanguinate because of a clot that was blocking the site of injury. As

described throughout history, cardiac injuries are complex and need highly specialized centers to receive the best possible treatment. We report the case of a patient who survived at Shar Teaching Hospital despite the lack of proper diagnostic and therapeutic modalities to deal with cardiac injuries.

CASE REPORT

On August 30, 2022, a 30-year-old man was brought to our emergency department following a bullet injury to his left flank. The accident happened at a location about 10 minutes away from the hospital. At the scene, he had developed cardiac arrest, as reported by his friend who was a paramedic in the police department, and cardiopulmonary respiration was started immediately. The patient was immediately brought to the hospital without waiting for an ambulance.

On arrival, the patient was conscious, dyspneic, agitated, and pale. The vitals included a blood pressure of 85/55 mmHg, an oxygen saturation of 88% without an oxygen mask, and a pulse rate of 114 beats/min. The patient was in stage III hemorrhagic shock.

The patient was managed according to the principles of Advanced Trauma Life Support. On inspection of the trunk, there was a wound in the right parasternal region at the third intercostal, with a round irregular outline (Fig. 1A). There was no sucking air and no paradoxical movement. There was almost no air

entry on the right side of the chest. We noted mild subcutaneous emphysema and tenderness on palpation. Immediate tube thoracostomy was commenced. An air leak was present with no drainage of blood.

On examination of the abdomen, there was a small (approximately 1 cm) round wound on the left flank (midaxillary line) with tattooing around the edges (Fig. 1A). The abdomen was rigid on palpation. There were no other associated injuries. A focused assessment with sonography for trauma (FAST) scan was negative at the time of the initial assessment.

The decision to perform emergency exploratory laparotomy and sternotomy or thoracotomy was based on a clinical examination and the general condition of the patient. A massive transfusion protocol was followed, and the patient was transferred to the operating room. The vital signs improved, and the patient became hemodynamically stable. With the exception of a FAST scan, no imaging was done.

Intraoperatively, under general anesthesia, the patient was intubated. The general surgery team started with their laparotomy while the cardiothoracic team was on standby. After the peritoneum was opened, 200 mL of blood was drained. Upon examination, a 2-cm injury to the greater curvature of the stomach and a 3-cm injury to the left dome of the diaphragm was found. No other intraabdominal organ was injured according to a systematic check. There was no retroperitoneal hematoma. The patients' vitals were stable, so the general surgery team commenced

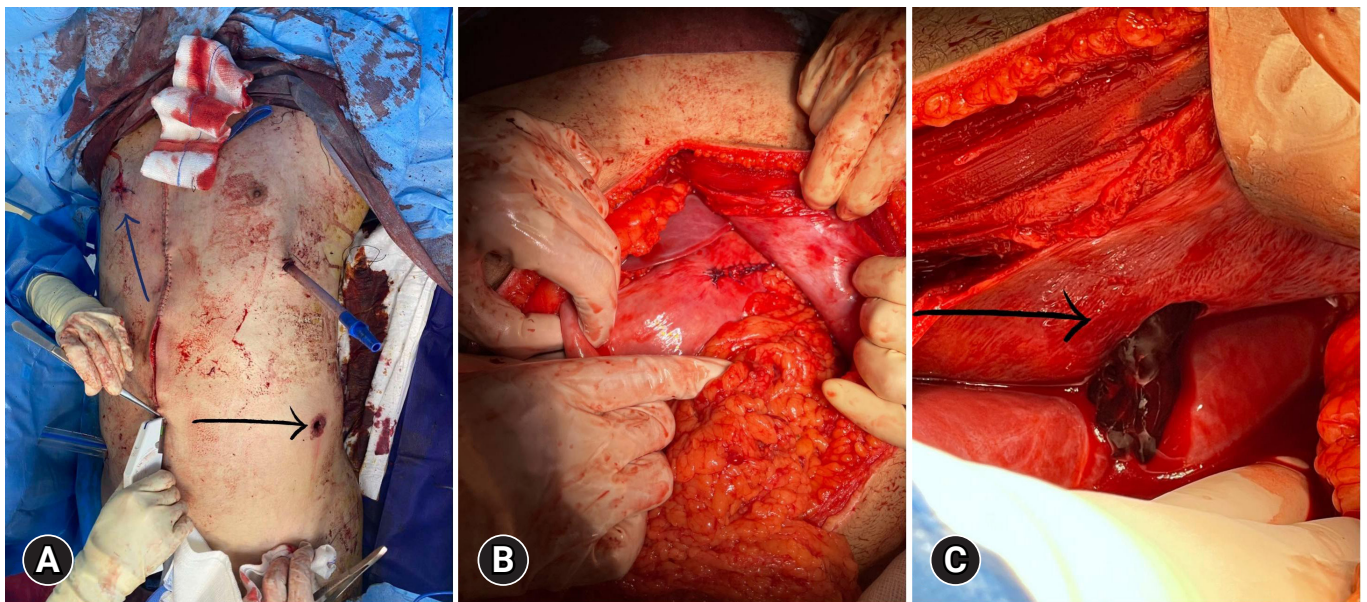


Fig. 1. Intraoperative photos. (A) Two wounds on the patient's inlet (black arrow) and outlet (blue arrow). (B) Repaired injury to the anterior wall of stomach. (C) A clot in the left hemidiaphragm (black arrow) after the initial injury to the diaphragm.

with the repair of the stomach (Fig. 1B). After completing the repair of the stomach, a clot dislodged from the left dome of the diaphragm and severe bleeding from the injury filled the abdomen (Fig. 1C).

Immediate median sternotomy was started by the cardiothoracic team. The central tendon of the diaphragm was also simultaneously opened to find and control the source of bleeding with pressure. The sternum was opened using a hammer and chisel, which were the only tools available at the emergency department. It took less than a minute. After the pericardium was opened, an obvious right ventricular defect was identified. There was no bleeding because of the light manual pressure exerted by one of the cardiothoracic surgeons (Fig. 2A). The injury was an 8-cm oblique linear defect on the anterior aspect of the right ventricle, not extending to the right coronary artery.

Primary repair of the injury was performed without putting the patient on bypass, since no bypass facilities were available. In addition, a small left parenchymal injury was identified at the left lower lobe of the lung. It was repaired and the blood drained from the left side of the thorax (Fig. 2B). The right third and fourth ribs were partially fractured 2 cm lateral to the sternal edge. No other intrathoracic injuries were found. Chest drains were placed in the mediastinum and the left pleura. The diaphragm injury was also repaired. After proper hemostasis and another systematic check of the thorax and abdomen were done to exclude any other missed injuries and the presence of surgical material, the sternotomy and laparotomy were closed. A corrugate drain was left in the abdomen. The patient was subsequently

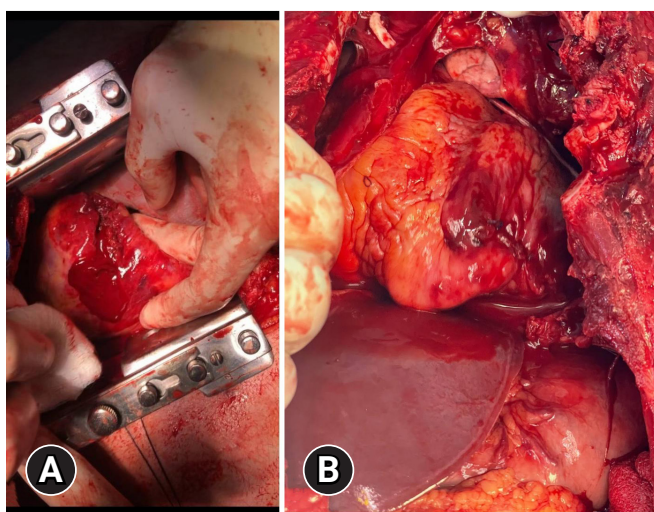


Fig. 2. Intraoperative pictures 2. (A) A right ventricular injury controlled with one's finger. (B) The left lower lobe injury after repair.

transferred to the intensive care unit. After 24 hours, the patient was hemodynamically stable. Blood gases were normal, and the patient was extubated successfully.

After being discharged from the intensive care unit after 48 hours, all the vital signs were stable, and the patient's only complaint was mild right-side chest pain. Echocardiography showed good cardiac contractility with no collection in the mediastinum. Ultrasonography showed no collections in the pleural spaces. The patient stayed in the cardiothoracic ward for 5 days. On day 4, the chest tubes were removed. He was then discharged safely.

Ethics statement

The study was approved by the Ethical Committee of Shar Teaching Hospital (No. 11489). The patient provided written informed consent for publication of the research details and clinical images.

DISCUSSION

Depending on the presentation, cardiac injuries can be classified into five categories as defined by Saadia et al. [6]: lifeless, critically unstable, cardiac tamponade, thoracoabdominal injuries, and benign presentation. Thoracoabdominal injuries are defined as being in the epigastrium. These injuries are usually masked by the intraabdominal injury in which the abdomen is accessed first [6]. Our patient presented with a gunshot to the left flank and was first dealt with by the general surgery team.

One of the most important considerations is the prehospital management of penetrating cardiac injuries. It is paramount that the retrieval time of a patient to a hospital be rapid enough that even proper resuscitation be postponed if it causes delay. This might offer better chances of survival, with less than 10 to 12 minutes being a good predictor [1,7].

Before the advent of ultrasonography, cases with suspected cardiac injury were diagnosed and managed using a subxiphoid pericardial window. Ultrasonography of the pericardium showed to be a significant modality even in unstable patients, with sensitivity reaching close to 100% for pericardial effusion at some centers [8]. In a case series by Patel et al. [9], ultrasonography performed by the surgeons had a sensitivity of 87%. In our patient, a FAST scan was the only investigation performed. It turned out to be negative.

The decision of the preferred incision in penetrating cardiac injury depends on the available surgical modalities, surgical experience, and type of injury. Both thoracotomy and sternotomy are options, and their significance varies based on the factors previously mentioned [10]. We performed a sternotomy because the

patient was prepared for a laparotomy and the source of bleeding indicated a cardiac origin. With one hand to control the bleeding, an immediate sternotomy was performed.

According to the literature, in penetrating cardiac injuries, the most common site of injury is the right ventricle, followed by the left ventricle [5]. Another important consideration is the presence of concomitant coronary artery injury. This usually carries a very high mortality rate (up to 50%) and requires emergent cardiopulmonary bypass. The most common injury is to the left anterior descending artery [5]. These are considered complex injuries. They can also be associated with valvular and septal injuries, which manifest as tamponade, hemothorax, and echocardiographic changes [5,11].

Surgery on a beating heart is difficult and requires patience and extensive surgical experience. This is especially true if there is an injury to the coronary arteries that requires revascularization [12]. Fortunately, our patient had no associated coronary artery injury, as visualized in Fig. 3.

The survival of such patients also depends on the type and place of operation. Emergency department thoracotomy carries a high mortality rate (near 95%). Operating room thoracotomy, in contrast, has a 64% chance of survival [7]. The presence of an intraabdominal injury and field cardiopulmonary resuscitation are independent risk factors for mortality [7].

In conclusion, for patients presenting with a penetrating injury to the trunk, we cannot rule out cardiac injury even if the injury is not located in the cardiac box. A high index of suspicion is needed based on the patient's overall clinical state, and decision-making should be rapid and precise. It is also important to note that emergency department thoracotomy carries a high mortality rate and should not be sought if there is time to transfer the patient to an appropriate operating theater, as was done in our scenario.

ARTICLE INFORMATION

Author contributions

Conceptualization: YNO; Data curation: YNO, ZSM; Resources: YNO, ZSM; Formal analysis: YNO; Methodology: YNO; Project administration: YNO; Visualization: all authors; Writing—original draft: YNO; Writing—review & editing: RKA. All authors read and approved the final manuscript.

Conflicts of interest

The authors have no conflicts of interest to declare.

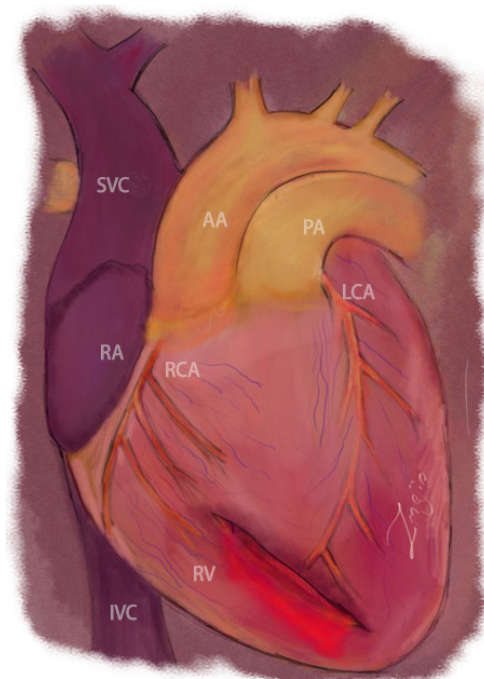


Fig. 3. A hand drawing of the heart (drawn by ZSM), showing the site of the injury and its proximity to the major coronaries. Note the left anterior descending distally. SVC, superior vena cava; AA, ascending aorta; PA, pulmonary artery; LCA, left coronary artery; RA, right atrium; RCA, right coronary artery; IVC, inferior vena cava; RV, right ventricle.

Funding

The authors did not receive any financial support for this study.

Data availability

Data sharing is not applicable as no new data were created or analyzed in this study.

REFERENCES

1. Kang N, Hsee L, Rizoli S, Alison P. Penetrating cardiac injury: overcoming the limits set by Nature. *Injury* 2009;40:919–27.
2. O'Connor J, Ditillo M, Scalea T. Penetrating cardiac injury. *J R Army Med Corps* 2009;155:185–90.
3. Ngwisanyi W, Moeng SF, Moeng M. Shockwave cardiac injury in thoracoabdominal gunshot wound. *Int J Surg Case Rep* 2021;80:105673.
4. Symbas PN, Harlaftis N, Waldo WJ. Penetrating cardiac wounds: a comparison of different therapeutic methods. *Ann Surg* 1976;183:377–81.

5. Wall MJ Jr, Mattox KL, Chen CD, Baldwin JC. Acute management of complex cardiac injuries. *J Trauma* 1997;42:905–12.
6. Saadia R, Levy RD, Degiannis E, Velmahos GC. Penetrating cardiac injuries: clinical classification and management strategy. *Br J Surg* 1994;81:1572–5.
7. Asensio JA, Ogun OA, Petrone P, et al. Penetrating cardiac injuries: predictive model for outcomes based on 2016 patients from the National Trauma Data Bank. *Eur J Trauma Emerg Surg* 2018;44:835–41.
8. Governatori NJ, Saul T, Siadecki SD, Lewiss RE. Ultrasound in the evaluation of penetrating thoraco-abdominal trauma: a review of the literature. *Med Ultrason* 2015;17:528–34.
9. Patel AN, Brenning C, Cotner J, et al. Successful diagnosis of penetrating cardiac injury using surgeon-performed sonography. *Ann Thorac Surg* 2003;76:2043–7.
10. Besir Y, Gokalp O, Eygi B, et al. Choice of incision in penetrating cardiac injuries: which one must we prefer: thoracotomy or sternotomy. *Ulus Travma Acil Cerrahi Derg* 2015;21:266–70.
11. Demetriades D. Cardiac penetrating injuries: personal experience of 45 cases. *Br J Surg* 1984;71:95–7.
12. Narayan P, Caputo M, Roidl M, Casula R. The use of off pump surgery for management of penetrating coronary artery injury. *Eur J Cardiothorac Surg* 2002;21:361–2.