

Facilitating combined upper and lower abdominal laparoscopic surgeries

Atef M.M. Darwish¹, Dina A.M. Darwish¹, Vefa Dervis², Rabih Nohman³

¹Department of Obstetrics & Gynecology, Assiut University, Assiut, Egypt

²Department of Pulmonology, Seed Medical Center, Doha, Qatar

³Department of General Surgery, Al Emadi Hospital, Doha, Qatar

Key words: Laparoscopy, Portal, Abdomen, Surgery, Gynecology

Received: July 26, 2023

Revised: September 4, 2023

Accepted: September 15, 2023

Correspondence to

Atef M.M. Darwish

Department of Obstetrics & Gynecology,
Assiut University, Besery Way, Al Walideyah
Al Qebleyah, Assiut 2074020,
Egypt

Tel: 947-0201001572723

Fax: 974-30200336

E-mail: atef_darwish@yahoo.com

Laparoscopic procedures can be performed concurrently in a single setting.¹ Laparoscopic entry sites for combined upper and lower abdominal surgeries are a controversial issue with no international recommendations. As the umbilicus is the optimum primary entry point for laparoscopy, it is typically used in such cases. The Darwish point was recently identified as a secure (primary) laparoscopic entry point in exceptional situations.² It is a right-sided meeting point of an imaginary transverse line at the umbilical level and a vertical line 2.5 cm medial to the anterior superior iliac spine. It can subsequently serve as a right-sided auxiliary (secondary) laparoscopic entry site in some cases of combined upper abdominal (e.g., cholecystectomy, adhesiolysis) and lower abdominal laparoscopic surgeries (e.g., appendectomy, myomectomy, and ovarian cystectomy)

in female patients. In such cases, an additional left-sided auxiliary (secondary) portal should be prepared laterally to the left inferior epigastric vessels, as high as possible, but below the umbilical level. In this way, both upper and lower abdominal surgeries can be easily done, with the advantage of minimizing secondary laparoscopic portal numbers and resulting in a better aesthetic appearance of the abdomen.

In conclusion, the Darwish point may be used as an alternative “primary,” as well as a “secondary,” laparoscopic portal in combined upper and lower abdominal laparoscopic surgeries. Figure 1 shows the entry portals suggested for most combined upper and lower abdominal laparoscopic surgeries. We performed many combined upper and lower abdominal surgeries via this approach, with successful results in terms of ease of access to the surgical site and

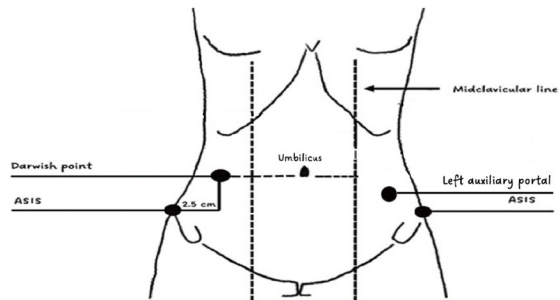


Figure 1. Abdominal access in combined upper and lower abdominal laparoscopic surgery.

minimized portal numbers.² Regarding upper abdominal surgery via this approach, the French position (lithotomy) is recommended for better access and surgeon comfort by maintaining a perfect azimuth angle. Using the Darwish point as a secondary portal may pave the way for random-

ized controlled trials to compare this new approach with conventional laparoscopic entry portals for this type of surgery.

ORCID

Atef M.M. Darwish, <https://orcid.org/0000-0003-0167-9337>

REFERENCES

1. Savita K, Khedkar I, Bhartia VK. Combined procedures with laparoscopic cholecystectomy. *Indian J Surg* 2010;72:377-80.
2. Darwish AMM, Darwish DAM. The Darwish point: an alternative nonumbilical primary laparoscopic entry site. *J Gynecol Surg* 2023;39:104-5.