

# Anatomic coracoclavicular ligament reconstruction with triple flip-buttons leads to good functional outcomes and low reduction loss: a case series

Raúl Águila<sup>1\*</sup>, Gonzalo Gana<sup>1</sup>, J Tomás Muñoz<sup>2</sup>, Diego García de la Pastora<sup>3</sup>, Andrés Oyarzún<sup>4</sup>, Gabriel Mansilla<sup>5</sup>, Sebastián Coda<sup>1</sup>, J Tomás Rojas<sup>1,6,\*</sup>

<sup>1</sup>Department of Orthopaedics and Traumatology, Clínica Santa María, Santiago, Chile

<sup>2</sup>Faculty of Medicine, Universidad de los Andes, Santiago, Chile

<sup>3</sup>Faculty of Science, Universidad de los Andes, Santiago, Chile

<sup>4</sup>Faculty of Medicine, Universidad de Chile, Santiago, Chile

<sup>5</sup>Research Support Team, Clínica Santa María, Santiago, Chile

<sup>6</sup>Department of Orthopaedics and Traumatology, Hospital San José, Santiago, Chile

**Background:** The management of acromioclavicular (AC) joint dislocation remains controversial. Recently, anatomic coracoclavicular (CC) fixation with a double clavicular tunnel and three flip-buttons has shown promising results. This study aimed to evaluate functional and radiological outcomes in patients with high-grade AC joint dislocation treated with anatomic CC fixation using double clavicular tunnels and three flip-buttons.

**Methods:** A retrospective, unicentric study was performed. The study included patients with high-grade AC joint dislocation who underwent surgery with anatomic CC fixation using double clavicular tunnels and three flip-buttons. Demographic data were obtained from medical records. A functional evaluation using subjective shoulder value (SSV), visual analog scale (VAS), and disabilities of the arm, shoulder, and hand (DASH) questionnaires was performed, and an evaluation of preoperative and postoperative comparative Zanca view images was performed. Factors associated with functional outcomes and radiological AC reduction were analyzed.

**Results:** A total of 83 patients completed follow-up and were included in the analysis. The mean SSV, VAS, and DASH scores were 92.8, 0.8, and 6.4, respectively. Patients who had complications experienced significantly worse functional outcomes (DASH:  $P=0.037$ ). Suboptimal final AC reduction was observed in nine patients (11.1%), and significantly more frequently in patients older than 40 years ( $P=0.031$ ) and in surgeries performed more than 7 days after injury ( $P=0.034$ ). There were two reoperations (2.4%).

**Conclusions:** Anatomic CC fixation with a double clavicular tunnel and three flip-buttons leads to good functional outcomes, low complication rates, and high rates of optimal AC reduction.

**Level of evidence:** Level IV, case series.

**Keywords:** Acromioclavicular joint; Coracoclavicular fixation; Patient reported outcome measures; Outcome assessment; X-rays

## INTRODUCTION

Acromioclavicular (AC) joint dislocations are frequent lesions

representing 4%–12% of shoulder injuries [1,2]. Most of these injuries occur during sports activities in male patients during their second or third decades of life [3,4]. There is a consensus in the

Received: October 14, 2022    Revised: January 16, 2023    Accepted: January 18, 2023

Correspondence to: Raúl Águila

Department of Orthopaedics and Traumatology, Clínica Santa María, Avenida Santa María 500, Providencia 750000, Región Metropolitana, Chile

Tel: +56-2-2913-0000, E-mail: [researchteamcsm@gmail.com](mailto:researchteamcsm@gmail.com), ORCID: <https://orcid.org/0000-0002-1556-7718>

\*These authors contributed equally to this work and share authorship.

Copyright© 2023 Korean Shoulder and Elbow Society.

This is an Open Access article distributed under the terms of the Creative Commons Attribution Non-Commercial License (<http://creativecommons.org/licenses/by-nc/4.0/>) which permits unrestricted non-commercial use, distribution, and reproduction in any medium, provided the original work is properly cited.

scientific literature that low-grade dislocations [5,6] (Rockwood classification types I and II [5] and International Society of Arthroscopy, Knee Surgery and Orthopaedic Sports Medicine (ISAKOS) consensus type IIIa [6]) can be treated conservatively [7,8]. Meanwhile, high-grade dislocations (grades IIIb, IV, V, and VI) benefit from surgical reduction and stabilization [9,10].

Multiple techniques have been described for the surgical treatment of these injuries, with the goal of obtaining anatomic reduction and stability of the AC joint. These techniques include flexible and rigid coracoclavicular (CC) fixation, AC fixation, tendon transfer, and reconstruction with grafts, among others [11-17]. Anatomic CC fixation mimics the native insertion point of the conoid and trapezoid ligaments using one point of fixation in the coracoid and two points of fixation in the clavicle [11,16,18-20]. Anatomic CC fixation has shown good functional outcomes [16,17] and lower reduction loss than single clavicular tunnel fixation [21]. This technique, without the use of grafts, has proven to be a useful treatment for acute AC joint dislocation (first 14–21 days from injury) [21-23].

Devices designed for CC fixation usually use a non-anatomic configuration with a single clavicular tunnel (TightRope, Dog Bone, ZipTight, and others) and have high costs. CC fixation using a flip-button (Fliptack) is an accessible and affordable option originally designed for a single clavicular tunnel [24]. Recently, Breuer et al. [16] described a modification of this device using a double clavicular tunnel and three Fliptack buttons, which showed good functional results and low rates of reduction loss.

This study aimed to evaluate functional and radiological outcomes together with complications in patients with high-grade AC joint dislocation treated with anatomic CC fixation using double clavicular tunnels and three flip-buttons. Our hypothesis is that the use of this technique in patients with unstable AC joint dislocation will lead to good functional outcomes, low complication rates, and low rates of reduction loss.

## METHODS

This study protocol was approved by the Research Ethics Committee of Clínica Santa María (No. 85100023). Written informed consent was obtained from all participants.

A retrospective review of patients with AC joint dislocation who underwent surgery at a single clinical center between 2013 and 2019 was performed. The inclusion criteria were patients with: (1) high-grade AC joint dislocations (Rockwood IIIb, IV, V, and VI), (2) surgery with anatomic CC fixation using double clavicular tunnels and three flip-buttons (Fliptack), and (3) complete radiological studies (preoperative and delayed postoperative

comparative Zanca views). The exclusion criteria were: (1) any other types of surgery to treat AC joint dislocation, such as transfers (Weaver-Dunn), AC fixation, rigid CC fixation (Bosworth), single flexible CC fixation and others; (2) other additional operative procedures during the surgery, such as distal clavicle resection; (3) surgeries more than 14 days after injury, considered as the limit for acute injury as reported by other authors [16,25,26]; and (4) a history of surgery in the affected shoulder.

For preoperative diagnosis and AC joint dislocation classification, comparative Zanca and bilateral axillary views were used. The indication for surgery was determined considering many variables, such as age, activity level, patient preference, and Rockwood grade. For patients who met the inclusion criteria, demographic data, including sport activity, injury mechanism, and days to surgery, among other factors, were obtained from medical records. All patients were contacted and asked to complete a final evaluation using the subjective shoulder value (SSV; subjective perception of shoulder function; scale of 0–100, where 100 = best score) [27], a visual analog scale for pain (VAS; subjective perception of pain in the shoulder; scale of 0–10, where 0 = best score), and disabilities of the arm, shoulder, and hand (DASH; self-administered measure of symptoms and functional status; scale of 0–100, where 0 = best score) [28] questionnaires.

Similar to Clavert et al. [29] and Shin and Kim [25], we considered the following complications: visible osteoarthritis in the AC joint, visible osteolysis of the distal clavicle, system failure, persistent shoulder stiffness (defined as glenohumeral range of motion limitation [30] for more than six months, without improvement during clinical controls), coracoid or clavicle fractures, perioperative infection, or any other adverse event occurring within the peri- or postoperative period that deviated from the expected course as a result of the surgical intervention, as defined by Martetschläger et al. [18]. The authors investigated the occurrence of all post-operative complications through medical records and radiological data.

There were 112 patients who met the inclusion criteria. Of these patients, 83 (73%) completed follow-up with a median follow-up period of 4.2 years. For patients who completed the final evaluation, radiographic evaluation was performed. All radiological measurements were performed by one fellowship-trained shoulder surgeon (JTR) who did not participate in the surgeries of this study, using XERO Viewer 8.1.2 (Agfa HealthCare). A comparative Zanca view was used for both preoperative and postoperative images [31]. A line between the most cranial point of each coracoid was drawn. The CC distance between each coracoid and the clavicle was measured perpendicularly to the line

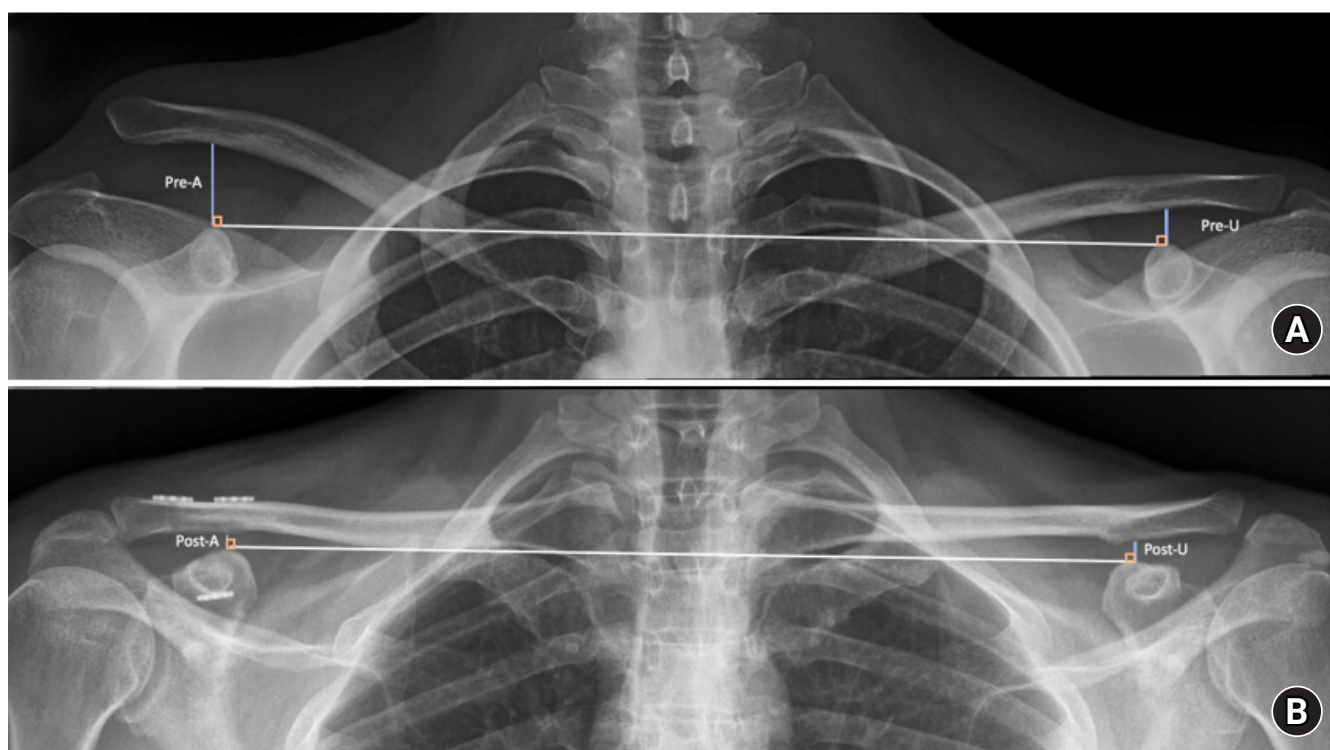
between the two coracoids (Fig. 1) [32]. In both preoperative and postoperative Zanca views, the CC distances of the affected and unaffected side, as well as the difference between them were recorded. The displacement ratio was expressed as a percentage and was calculated as the difference between the CC distance of the affected and unaffected sides divided by the unaffected side [21]. An optimal final AC reduction was considered to be less than 50% of the displacement ratio, and a suboptimal final AC reduction was more than 50% of the displacement ratio [31]. A comparative Zanca view taken immediately after surgery was not analyzed, so the of reduction was not calculated. Only the preoperative and final AC reductions were analyzed.

Surgeries were performed following the same technique by one surgeon on the shoulder team of a clinical center (RA, GG, SC, AV, HC). With the patient in a beach chair position, a supraclavicular approach was performed. All procedures were performed without arthroscopic assistance. A 4.0-mm drill hole was made on the coracoid, and one flip-button (Fliptack, Karl Storz SE & Co.) together with two high resistance sutures (Parcus suture, Parcus Medical) were passed through the coracoid hole and

flipped under the coracoid. The position of the clavicular tunnels was chosen during the operation by the surgeon, taking into consideration the anatomic insertion of the native conoid and trapezoid ligaments and a distance of 4.5 cm and 2.5 cm from the lateral border of the clavicle. Subsequently, two 2.5-mm drill holes were made in the clavicle, and one of the Parcus sutures (two tails and the loop) was passed through each clavicle hole. A reduction of the AC joint was made, and the system was blocked using one flip-button on each tunnel with a knot [16].

Postoperatively, patients underwent a standard rehabilitation protocol. Patients used a shoulder brace for four weeks. Elevation over 90°, pressure on the injury and extension of the shoulder in the horizontal plane at 90° were forbidden. Passive movements of the shoulder and active motions of the elbow and wrist were performed starting after the first postoperative day. Physiotherapy started at the fourth week with progressive active and passive motions. Patients were allowed to resume their regular sport activities at the 12th week. Contact sports were allowed starting at the 16th postoperative week.

A descriptive analysis of the sample was performed. A Shap-



**Fig. 1.** (A) Preoperative Zanca view. (B) Postoperative Zanca view. A line was drawn between the most cranial point of each coracoid (white lines). The coracoclavicular (CC) distance between each coracoid and clavicle was measured perpendicular to the line between the two coracoids (blue lines).

iro-Wilk test was used to assess normality in quantitative variables. Quantitative variables are expressed as the means and standard deviations and categorical variables are expressed as absolute frequencies and percentages. The t-tests and Wilcoxon–Mann-Whitney tests were used to compare quantitative variables according to normality distribution, and the chi-squared test or Fisher’s exact test was used for categorical variables. A dichotomic analysis looking for associated factors was performed in patients with optimal and suboptimal final AC reduction. All analyses were performed using Stata ver. 14 (StataCorp.), and a significance level of 0.05 was chosen.

## RESULTS

A total of 83 patients (37.7 years, 95% male) completed follow-up and were included in the analysis. Most of them (83%) were Rockwood type V with a mean time to surgery of 3 days (Table 1).

At the end of follow-up, the mean SSV, VAS, and DASH scores were 92.8, 0.8, and 6.4, respectively. Patients who had complications showed significantly worse functional outcomes (DASH:  $P=0.037$ ) (Table 2). There was no association between functional outcomes and final AC reduction.

There was a significant decrease in the CC distance of the affected side and in the displacement ratio (Table 3). There were

**Table 1.** Demographic data and injury classification

Variable	Value
Age (yr)	37 ± 10 (17–59)
Day to surgery	3.4 ± 3.1 (0.0–18.0)
Follow-up period (yr)	5.0 ± 2.0 (2.1–9.3)
Sex	
Male	79 (95.2)
Female	4 (4.8)
Side	
Right	46 (55.4)
Left	37 (44.6)
Dominant hand	45 (54.2)
Rockwood classification	
3	7 (8.4)
4	7 (8.4)
5	69 (83.1)
Sport level	
Non-competitive	59 (71.1)
Competitive	17 (20.5)
No sport	7 (8.4)
Age	
≤ 40 yr	47 (56.6)
> 40 yr	36 (43.4)
Day to surgery	
< 3	35 (42.2)
3–7	42 (50.6)
> 7	6 (7.2)

Values are presented as mean ± standard deviation (range) or number (%).

**Table 2.** Functional outcomes and comparison with different variables

Variable	SSV score		VAS score		DASH score	
	Mean ± SD (range)	P-value <sup>a)</sup>	Mean ± SD (range)	P-value <sup>a)</sup>	Mean ± SD (range)	P-value <sup>a)</sup>
Final AC reduction		0.512		0.235		0.057
Optimal	92.6 ± 8.6 (65.0–100.0)		0.9 ± 1.2 (0.0–5.0)		6.8 ± 8.9 (0.0–36.4)	
Suboptimal	94.4 ± 6.8 (80.0–100.0)		0.4 ± 1.0 (0.0–3.0)		2.8 ± 5.5 (0.0–13.6)	
Side		0.536		0.189		0.836
Dominant hand	93.7 ± 7.7 (65.0–100.0)		0.7 ± 1.2 (0.0–4.0)		6.2 ± 8.3 (0.0–36.4)	
Non-dominant hand	92.1 ± 9.1 (65.0–100.0)		0.9 ± 1.2 (0.0–5.0)		6.5 ± 9.0 (0.0–36.4)	
Complication		< 0.001*		< 0.001*		0.037*
Yes	83.6 ± 12.1 (65.0–100.0)		2.2 ± 1.2 (0.0–5.0)		11.1 ± 9.6 (0.0–34.1)	
No	95.3 ± 4.9 (80.0–100.0)		0.4 ± 0.0 (0.0–4.0)		5.1 ± 7.9 (0.0–36.4)	
Reoperation		0.393		0.547		0.452
Yes	97.5 ± 3.5 (95.0–100.0)		1.5 ± 2.1 (0.0–3.0)		8.0 ± 8.0 (2.3–13.6)	
No	92.8 ± 8.4 (65.0–100.0)		0.8 ± 1.2 (0.0–5.0)		6.3 ± 8.6 (0.0–36.4)	
Age		0.091		0.686		0.618
≤ 40 yr	92.4 ± 7.7 (70.0–100.0)		0.8 ± 1.2 (0.0–4.0)		6.8 ± 9.1 (0.0–36.4)	
> 40 yr	93.6 ± 9.2 (65.0–100.0)		0.8 ± 1.2 (0.0–5.0)		5.7 ± 8.0 (0.0–34.1)	
Delay surgery		0.698		0.766		0.935
≤ 7 day	92.8 ± 8.5 (65.0–100.0)		0.8 ± 1.2 (0.0–5.0)		6.5 ± 8.8 (0.0–36.4)	
> 7 day	94.2 ± 7.4 (80.0–100.0)		0.8 ± 1.2 (0.0–3.0)		4.5 ± 5.2 (0.0–13.6)	

SSV: subjective shoulder value, VAS: visual analog scale, DASH: disabilities of the arm, shoulder and hand, SD: standard deviation, AC: acromioclavicular.

<sup>a)</sup>Wilcoxon Mann-Whitney test.

\*Significant difference with  $P < 0.05$ .

**Table 3.** Preoperative and postoperative radiological evaluation

Variable	Preoperative	Postoperative	P-value <sup>a)</sup>
CC distance unaffected side (mm)	8.9 ± 1.9 (1.0 to 12.6)	9.2 ± 1.7 (5.1 to 12.6)	0.406
CC distance affected side (mm)	18.8 ± 4.7 (2.0 to 26.1)	8.9 ± 3.4 (3.0 to 19.4)	<0.001*
Displacement ratio (%)	117 ± 0.5 (-0.1 to 2.6)	-1 ± 0.4 (-0.6 to 1.1)	<0.001*

Values are presented as mean ± standard deviation (range).

CC: coracoclavicular.

<sup>a)</sup>Student t-test.

\*Significant difference with P < 0.05.

nine patients (11.1%) who had a suboptimal final AC reduction. After searching for a threshold to identify significant differences between groups, patients older than 40 years and surgeries performed 7 days after the injury were associated with more suboptimal final AC reduction (P = 0.031 and P = 0.034, respectively) (Table 4).

Complications were observed in 16 patients (19.3%), with AC joint osteoarthritis being the most frequent (10.8%). There were two reoperations (2.4%). One of them was due to button failure (considered a complication), and the other was due to a supraspinatus tear not directly associated with the initial injury. There were two coracoid fractures, neither of which required surgery, and both had good functional outcomes. There were no infections, hematomas, thrombotic events, or other severe complications (Table 5).

## DISCUSSION

The main finding of this study is that anatomic CC fixation with double clavicular tunnels and three flip-buttons is associated with good functional outcomes, low complication rates, and high rates of optimal AC reduction. Additionally, this study showed no association between final AC reduction and functional outcomes.

To the best of our knowledge, only one study has evaluated this technique. Breuer et al. [16] evaluated functional and radiological results and showed similar functional outcomes (SSV, 95; VAS, 0.9; DASH, 9.1) with 98% satisfaction. These authors showed better functional outcomes in younger patients, surgery before 10 days, and lower reduction losses. These associations were not found in this study, but an association with poor functional outcomes in patients who had complications was observed. All surgeries were performed openly, without arthroscopic assistance. An open procedure with a small incision gives excellent functional and radiological result [16], allowing the surgeon to explore the AC joint intraoperatively when needed.

There are controversies regarding the correlation between radiographic and clinical outcomes. Breuer et al. [16] showed greater CC distances were correlated with worse Constant scores.

**Table 4.** Comparison between optimal and suboptimal final reduction of AC joint

Variable	Optimal (n=72)	Suboptimal (n=9)	P-value <sup>a)</sup>
Sex			0.699
Male	69 (88.5)	9 (11.5)	
Female	3 (100.0)	0	
Side			0.307
Dominant hand	37 (86.0)	6 (14.0)	
Non-dominant hand	35 (92.1)	3 (7.9)	
Complication			0.843
Yes	14 (87.5)	2 (12.5)	
No	58 (89.2)	7 (10.8)	
Reoperation			0.789
Yes	2 (100.0)	0	
No	70 (88.6)	9 (11.4)	
Age			0.031*
≤ 40 yr	44 (95.7)	2 (4.3)	
> 40 yr	28 (80.0)	7 (20.0)	
Delay surgery			0.034*
≤ 7 day	69 (90.8)	7 (9.2)	
> 7 day	3 (60.0)	2 (40.0)	

Values are presented as number (%).

AC: acromioclavicular.

<sup>a)</sup>Fisher's exact test.

\*Significant difference with P < 0.05.

**Table 5.** Reoperation and complications

Variable	No. (%)
Reoperation	2 (2.4)
Complication	16 (19.3)
Acromioclavicular osteoarthritis	9 (10.8)
Distal clavicular osteolysis	2 (2.4)
Shoulder stiffness	2 (2.4)
Coracoid fracture	2 (2.4)
Buttons failure	1 (1.2)

Nevertheless, other studies and the present one show no correlation between reduction loss and functional outcomes [26,33,34]. This could be interpreted as joint stability and lesser CC distances being enough to improve clinical outcomes even when the final reduction does not place the joint in the native position. In the same line, the Breuer et al.'s study [16] did not show any dif-

ferences between clinical outcomes and reduction loss.

Regarding factors associated with reduction loss, a delayed time to surgery was the most common [10,16]. Breuer et al. [16] reported greater reduction loss with a delay of 10 days. In the present study, even a 7-day delay in surgery was associated with worst radiological final AC reduction, which suggests the importance of early surgery in patients with indications. It should be noted that only six patients (7%) underwent surgery after 7 days compared to 77 (93%) before 7 days. This asymmetry in group size could have weakened the results of the comparative analysis. Additionally, in this study, age greater than 40 years was also associated with worse final AC reduction, similar to other published articles [10,16].

Other studies evaluating flexible CC fixations report similar functional outcomes in either single or double [3,15,17] clavicular tunnels. Despite similar functional outcomes, compared to a single tunnel, double clavicular tunnels show less postoperative reduction loss in comparative clinical studies [21]. One advantage of the double clavicular tunnel with the three flip-button technique is that this configuration is between two and seven times cheaper than other commercially available options such as ZipTight, Dog Bone, TightRope, or Twin Tail.

A direct comparison of complication rates between different studies is not possible, because the criteria utilized are usually different or not clearly described [16,18,25,29,35]. In general, complication rates have been reported to range between 22.4% [29] and 44% [25], with the most frequent complications being reduction loss, clavicular osteolysis and osteoarthritis, hardware failure, and coracoid fractures. The present study showed a global complication rate of 19.3% with AC joint osteoarthritis being the most common (10.8%), similar to what was described by Breuer et al. [16] (8%). Some studies showed a correlation between the presence of complications and worst functional outcomes. Martetschläger et al. [18] revealed a reduced satisfaction and Clavert et al. [29] demonstrated significant lower Constant scores in patients with complications. The present study showed that the presence of complications was correlated with worse SSV, VAS, and DASH assessment, independent of the final reduction of the AC joint.

The findings of the present study should be interpreted with the following limitations in mind. First, this is a retrospective case series study with a mid-term follow-up period. Second, we observed 25.9% loss to follow-up, which could have affected the final results. Third, we did not include postoperative radiographic stress views (Alexander X-rays view) when assessing final radiographic horizontal stability [31,32,36], we only assessed vertical instability. This could underestimate the remaining postoper-

ative instability of the AC joint [31,32]. This was because at the beginning of this study, there were no conclusive data on the use of this projection. Fourth, only the preoperative and final AC reduction was analyzed and loss of reduction was not calculated.

## CONCLUSIONS

Anatomic CC fixation with a double clavicular tunnel and three flip-buttons leads to good functional outcomes, low complication rates, and high rates of optimal AC reduction. Functional outcomes were worse in patients who had complications and were not associated with AC reduction. A suboptimal final AC reduction was more common in patients older than 40 years and in those with a surgery delay of more than 7 days. Further studies should be conducted to analyze the cost-benefit of using double versus single clavicular tunnels.

## NOTES

### ORCID

Raúl Águila	<a href="https://orcid.org/0000-0002-1556-7718">https://orcid.org/0000-0002-1556-7718</a>
Diego García de la Pastora	<a href="https://orcid.org/0000-0002-5201-4661">https://orcid.org/0000-0002-5201-4661</a>
Andrés Oyarzún	<a href="https://orcid.org/0000-0002-0035-8980">https://orcid.org/0000-0002-0035-8980</a>
J Tomás Rojas	<a href="https://orcid.org/0000-0002-5929-1805">https://orcid.org/0000-0002-5929-1805</a>

### Author contributions

Conceptualization: RA, GG, JTR. Data curation: RA, GG, DGP, SC. Formal Analysis: JTR. Investigation: RA, JTM, DGP, AO, SC, JTR. Methodology: RA, JTR. Project administration: RA. Resources: RA. Supervision: RA, JTR. Validation: RA. Visualization: RA. Writing – original draft: RA, JTR. Writing – review & editing: RA, GM, JTR.

### Conflict of interest

None.

### Funding

None.

### Data availability

Contact the corresponding author for data availability.

### Acknowledgments

The authors are grateful to Andrea Canals for statistical analysis, to Maria T. Allende for manuscript preparation, and to Alejandro Viacava and Hector Carreño for the performed surgeries.

## REFERENCES

1. Wylie JD, Johnson JD, DiVenere J, Mazzocca AD. Shoulder acromioclavicular and coracoclavicular ligament injuries: common problems and solutions. *Clin Sports Med* 2018;37:197–207.
2. Nordqvist A, Petersson CJ. Incidence and causes of shoulder girdle injuries in an urban population. *J Shoulder Elbow Surg* 1995;4:107–12.
3. Pallis M, Cameron KL, Svoboda SJ, Owens BD. Epidemiology of acromioclavicular joint injury in young athletes. *Am J Sports Med* 2012;40:2072–7.
4. Chillemi C, Franceschini V, Dei Giudici L, et al. Epidemiology of isolated acromioclavicular joint dislocation. *Emerg Med Int* 2013;2013:171609.
5. Gorbaty JD, Hsu JE, Gee AO. Classifications in Brief: Rockwood Classification of Acromioclavicular Joint Separations. *Clin Orthop Relat Res* 2017;475:283–7.
6. Beitzel K, Mazzocca AD, Bak K, et al. ISAKOS Upper Extremity Committee consensus statement on the need for diversification of the Rockwood classification for acromioclavicular joint injuries. *Arthroscopy* 2014;30:271–8.
7. Mouhsine E, Garofalo R, Crevoisier X, Farron A. Grade I and II acromioclavicular dislocations: results of conservative treatment. *J Shoulder Elbow Surg* 2003;12:599–602.
8. Beitzel K, Cote MP, Apostolakis J, et al. Current concepts in the treatment of acromioclavicular joint dislocations. *Arthroscopy* 2013;29:387–97.
9. Mazzocca AD, Arciero RA, Bicos J. Evaluation and treatment of acromioclavicular joint injuries. *Am J Sports Med* 2007;35:316–29.
10. Tang G, Zhang Y, Liu Y, Qin X, Hu J, Li X. Comparison of surgical and conservative treatment of Rockwood type-III acromioclavicular dislocation: a meta-analysis. *Medicine (Baltimore)* 2018;97:e9690.
11. Carofino BC, Mazzocca AD. The anatomic coracoclavicular ligament reconstruction: surgical technique and indications. *J Shoulder Elbow Surg* 2010;19(2 Suppl):37–46.
12. Katsenis DL, Stamoulis D, Begkas D, Tsamados S. Minimally invasive reconstruction of acute type IV and Type V acromioclavicular separations. *Orthopedics* 2015;38:e324–30.
13. Lee SJ, Nicholas SJ, Akizuki KH, McHugh MP, Kremenic IJ, Ben-Avi S. Reconstruction of the coracoclavicular ligaments with tendon grafts: a comparative biomechanical study. *Am J Sports Med* 2003;31:648–55.
14. Struhl S, Wolfson TS. Continuous loop double endobutton reconstruction for acromioclavicular joint dislocation. *Am J Sports Med* 2015;43:2437–44.
15. Yin J, Yin Z, Gong G, Zhu C, Sun C, Liu X. Comparison of hook plate with versus without double-tunnel coracoclavicular ligament reconstruction for repair of acute acromioclavicular joint dislocations: a prospective randomized controlled clinical trial. *Int J Surg* 2018;54(Pt A):18–23.
16. Breuer R, Unterrainer A, Komjati M, Tiefenboeck TM, Trieb K, Pirkl C. Minimally Invasive AC Joint Reconstruction System (MINAR®) in modified triple-button technique for the treatment of acute AC joint dislocation. *J Clin Med* 2019;8:1683.
17. Cano-Martínez JA, Nicolás-Serrano G, Bento-Gerard J, Pícazo-Marín F, Andrés-Grau J. Acute high-grade acromioclavicular dislocations treated with triple button device (MINAR): preliminary results. *Injury* 2016;47:2512–9.
18. Martetschläger F, Horan MP, Warth RJ, Millett PJ. Complications after anatomic fixation and reconstruction of the coracoclavicular ligaments. *Am J Sports Med* 2013;41:2896–903.
19. Eisenstein ED, Lanzi JT, Waterman BR, Bader JM, Pallis MP. Medialized clavicular bone tunnel position predicts failure after anatomic coracoclavicular ligament reconstruction in young, active male patients. *Am J Sports Med* 2016;44:2682–9.
20. Cook JB, Shaha JS, Rowles DJ, Bottoni CR, Shaha SH, Tokish JM. Clavicular bone tunnel malposition leads to early failures in coracoclavicular ligament reconstructions. *Am J Sports Med* 2013;41:142–8.
21. Gu F, Tan L, Wang T, et al. Comparison of single versus double TightRope system in the treatment of acute acromioclavicular joint dislocation. *J Shoulder Elbow Surg* 2021;30:1915–23.
22. Costic RS, Labriola JE, Rodosky MW, Debski RE. Biomechanical rationale for development of anatomical reconstructions of coracoclavicular ligaments after complete acromioclavicular joint dislocations. *Am J Sports Med* 2004;32:1929–36.
23. Walz L, Salzmann GM, Fabbro T, Eichhorn S, Imhoff AB. The anatomic reconstruction of acromioclavicular joint dislocations using 2 TightRope devices: a biomechanical study. *Am J Sports Med* 2008;36:2398–406.
24. Rosslenbroich SB, Schliemann B, Schneider KN, et al. Minimally invasive coracoclavicular ligament reconstruction with a flip-button technique (MINAR): clinical and radiological mid-term results. *Am J Sports Med* 2015;43:1751–7.
25. Shin SJ, Kim NK. Complications after arthroscopic coracoclavicular reconstruction using a single adjustable-loop-length suspensory fixation device in acute acromioclavicular joint dislocation. *Arthroscopy* 2015;31:816–24.
26. Tiefenboeck TM, Boesmueller S, Popp D, et al. The use of the LARS system in the treatment of AC joint instability: long-term results after a mean of 7.4 years. *Orthop Traumatol Surg Res*

- 2018;104:749–54.
27. Gilbert MK, Gerber C. Comparison of the subjective shoulder value and the Constant score. *J Shoulder Elbow Surg* 2007;16:717–21.
  28. Hudak PL, Amadio PC, Bombardier C. Development of an upper extremity outcome measure: the DASH (disabilities of the arm, shoulder and hand) [corrected]. *Am J Ind Med* 1996;29:602–8.
  29. Clavert P, Meyer A, Boyer P, et al. Complication rates and types of failure after arthroscopic acute acromioclavicular dislocation fixation: prospective multicenter study of 116 cases. *Orthop Traumatol Surg Res* 2015;101(8 Suppl):S313–6.
  30. Itoi E, Arce G, Bain GI, et al. Shoulder stiffness: current concepts and concerns. *Arthroscopy* 2016;32:1402–14.
  31. Zumstein MA, Schiessl P, Ambuehl B, et al. New quantitative radiographic parameters for vertical and horizontal instability in acromioclavicular joint dislocations. *Knee Surg Sports Traumatol Arthrosc* 2018;26:125–35.
  32. Murphy RJ, Moor BK, Lesniewski PJ, Hayoz A, Alcantara W, Zumstein MA. Evaluation of the circles measurement and the ABC classification of acromioclavicular joint injuries. *Am J Sports Med* 2021;49:1619–25.
  33. Vulliet P, Le Hanneur M, Cladiere V, Loriaut P, Boyer P. A comparison between two double-button endoscopically assisted surgical techniques for the treatment acute acromioclavicular dislocations. *Musculoskelet Surg* 2018;102:73–9.
  34. Hann C, Kraus N, Minkus M, Maziak N, Scheibel M. Combined arthroscopically assisted coraco- and acromioclavicular stabilization of acute high-grade acromioclavicular joint separations. *Knee Surg Sports Traumatol Arthrosc* 2018;26:212–20.
  35. Schliemann B, Roßlenbroich SB, Schneider KN, et al. Why does minimally invasive coracoclavicular ligament reconstruction using a flip button repair technique fail?: an analysis of risk factors and complications. *Knee Surg Sports Traumatol Arthrosc* 2015;23:1419–25.
  36. Karargyris O, Murphy RJ, Arenas A, Bolliger L, Zumstein MA. Improved identification of unstable acromioclavicular joint injuries in a clinical population using the acromial center line to dorsal clavicle radiographic measurement. *J Shoulder Elbow Surg* 2020;29:1599–605.