

Pleuroperitoneal communication-associated pleuritis as an uncommon cause of fever of unknown origin in a child on peritoneal dialysis: a case report

Juhee Park¹ , Heeyon Yoon¹ , Jiwon Jung¹ , Jina Lee¹ , Joo Hoon Lee¹ 

¹Department of Pediatrics, Asan Medical Center Children's Hospital, University of Ulsan College of Medicine, Seoul, Republic of Korea

Pleuroperitoneal communication (PPC) is a rare mechanical complication of peritoneal dialysis (PD), which causes dialysate to move from the peritoneal cavity to the pleural cavity, resulting in pleural effusion. Typically, PPC is discovered through pleural effusion in PD patients who are not in volume overload status. A unique characteristic of the pleural effusion caused by PPC is that it is not resolved by increasing ultrafiltration by dialysis. In this report, we present a 7-year-old girl with PD after birth with the history of various infectious PD-related complications, presenting with fever ongoing for 6 months. PPC-associated pleuritis was suspected as the cause of fever, which eventually developed after long-term PD and induced complicated pleural effusion, lung inflammation, and prolonged fever for 6 months.

Keywords: Case reports; Child; Fever; Peritoneal dialysis; Pleural effusion

Introduction

Children with end-stage kidney disease (ESKD) should receive kidney replacement therapy through hemodialysis or peritoneal dialysis (PD). Given the lack of comparative studies of PD and hemodialysis outcomes in children with ESKD, the choice primarily depends on patient and family preference or the availability of nearby medical centers [1]. However, PD holds various advantages over hemodialysis, such as fewer dietary restrictions, including fluid intake, allowing treatment to be performed at home without needing vascular access. Therefore, PD is the most common dialysis treatment modality for pediatric patients with ESKD [2,3].

Complications associated with PD typically range from infectious (peritonitis, exit site or tunnel infection) to non-infectious

problems (hernia, hydrothorax, hemoperitoneum, nutritional or metabolic issues) [4,5]. Hydrothorax (pleural effusion) in patients on chronic PD can be caused by various etiologies such as heart failure, uremic pleuritis, or volume load due to decreased dialysis efficiency, tuberculosis, neoplasm, and parapneumonic effusion. Pleuroperitoneal communication (PPC; fistula or leak), is a rare and potentially life-threatening complication of chronic PD that causes pleural effusion. Usually, PPC is discovered through pleural effusion in patients on PD who are not in volume overload status, which persists despite increasing dialysis efficiency using high osmolar dialysate or increasing dialysis frequency and instill-dialysate volume.

In adults with PD, the estimated incidence of PPC is 0.64% to 5.10%. However, the incidence in children is unclear, with reports ranging from 0.9% from 3.0%, given the lack of pediat-

Received: May 15, 2023; Revised: June 24, 2023; Accepted: June 26, 2023

Correspondence to

Joo Hoon Lee
Department of Pediatrics, Asan Medical Center Children's Hospital, University of Ulsan College of Medicine, Seoul, Republic of Korea
E-mail: pedkid@gmail.com

© 2023 Korean Society of Pediatric Nephrology

This is an Open Access article distributed under the terms of the Creative Commons Attribution Non-Commercial License (<http://creativecommons.org/licenses/by-nc/4.0>) which permits unrestricted noncommercial use, distribution, and reproduction in any medium, provided the original work is properly cited.

ric patients on PD due to ESKD [6]. Low incidence and unclear pathophysiology create challenges for pediatricians to diagnose and treat PPC in children treated with long-term PD.

Herein, we present the case of a 7-year-old female child on chronic PD since birth who presented with prolonged fever for 6 months associated with suspicious PPC-associated pleuritis.

Case report

A 7-year-old girl with ESKD on PD was admitted due to fever, malaise, and poor oral intake on December 31, 2021. An intermittent fever (37.8–38.5 °C) persisted for 2 weeks despite oral antibiotic treatment (cefditoren 3 mg/kg/day) in the outpatient clinic. She was born at gestational age 33 weeks 6 days, weighing 4,120 g. She was admitted to the neonatal intensive care unit owing to a prenatally identified large sacrococcygeal immature teratoma (size 17×14×7 cm) and multiple anomalies, including rectal atresia and fixed equinus of both feet. Excisional operation of the teratoma was performed on the eighth day after birth. She developed ESKD due to teratoma-induced renal vessel compression and ischemic events with cardiac arrest during the operation, which was treated with continuous kidney replacement therapy for 3 months, followed by chronic continuous PD. She was discharged at 5 months at 3.9 kg body weight with a PD modality consisting of eight dialysis cycles with 60 mL of 2.5% dextrose dialysate at 2.5-hour intervals. As she grew up, she adapted to an automated continuous-cyclic PD schedule: 350 mL of 1.5% dextrose dialysate exchanges for six cycles at 2-hour intervals from 8 PM to 8 AM, followed by 300 mL of 7.5% glucose dialysate retention for 12 hours. She had suffered from several infectious PD complications, including peritonitis, exit site infections, and wound dehiscence and underwent three rounds of PD catheter change operations and two rounds of laparoscopic exploration and peritoneal adhesiolysis operations. The most recent case of peritonitis due to *klebsiella aerogenes* occurred 2 months before admission. On admission, she had symptoms including fever, chill, general weakness, weight loss of 1 kg over 1 month, intermittent cough, and rhinorrhea. She had no signs of respiratory distress, such as tachypnea, dyspnea, and cyanosis. Her height was 93.3 cm (<3rd percentile), and her weight was 11.6 kg (<3rd percentile). Her vital signs were as follows: systolic/diastolic blood pressure 68/38 mmHg, heart rate 123/min, respiratory rate 20/min, body temperature 37.8 °C, and oxygen saturation 95% in room air. On physical examination, she appeared chronically ill. Lung sounds were clear

without wheezing or crackles. Bowel sounds were normoactive, with a soft abdomen without focal abdominal tenderness. The vesicostomy and ileostomy (due to rectal atresia) sites were clear. Pitting edema was not observed. Initial laboratory evaluation was as follows: white blood cell counts 26,600/ μ L (neutrophils 82.7%, lymphocytes 8.5%, monocytes 6.1%), hemoglobin 9.2 g/dL, platelets 365,000/ μ L, blood urea nitrogen 50 mg/dL, creatinine 8.23 mg/dL, B-type natriuretic peptide 2 pg/mL (normal range: <36 pg/mL), and C-reactive protein (CRP) 7.44 mg/dL (normal range: 0–0.6 mg/dL). PD fluid analysis was clear with a differential count of nucleated cells 82/ μ L consisting of 41% neutrophils and 15% lymphocytes. Chest radiography and computed tomography (CT) revealed multifocal peribronchial infiltration with subpleural consolidation in both lower lungs and suggestive complicated bilateral pleural effusion with diffuse enhancing pleural thickening (Fig. 1). Multiple reactive lymph node hyperplasias were also observed in the mediastinum, lobar/interlobar, and axillae. Left ureteral residual contrast dye from voiding cystourethrography, performed 80 days before admission, was observed on X-rays. Abdominopelvic CT results were as follows: PD catheter insertion with its tip in the pelvic cavity, moderate ascites with mild peritoneal thickening in the upper abdomen, bilateral hydronephroureterosis, a severe parenchymal atrophic change in both kidneys, residual contrast material in the left pelvicalyceal system, and irregular lobulated margined bladder. Considering her pneumonic features, we initially treated her with ampicillin-sulbactam (50 mg/kg/day ampicillin, 30 mg/kg/day/sulbactam). However, we amended to piperacillin-tazobactam (100 mg/kg/day piperacillin, 25 mg/kg/day tazobactam) on the seventh hospital day to cover *K. aerogenes*, which was the cause of peritonitis 2 months before. Nevertheless, her CRP increased to 11.7 mg/dL with persistent mild fever (<38.0 °C). We subsequently switched to vancomycin (10 mg/kg/day) and meropenem (20 mg/kg/day) combination therapy on hospital day 13, and initial and repeated culture studies, including blood, PD fluid, sputum, and stool, were all negative. Tests for severe acute respiratory syndrome coronavirus 2, other respiratory viruses, tuberculosis interferon-gamma, and mycoplasma antibodies were also negative. We had performed a cystoscopy to remove contrast media of the left pelvicalyceal system injected during the voiding cystourethrography study for the transplantation work up 4 months before, considering the possibility of contrast-induced inflammation; however, the patient's fever elevated to 40.2 °C and CRP to 13.3 mg/dL after the procedure. The culture result of the drained contrast was

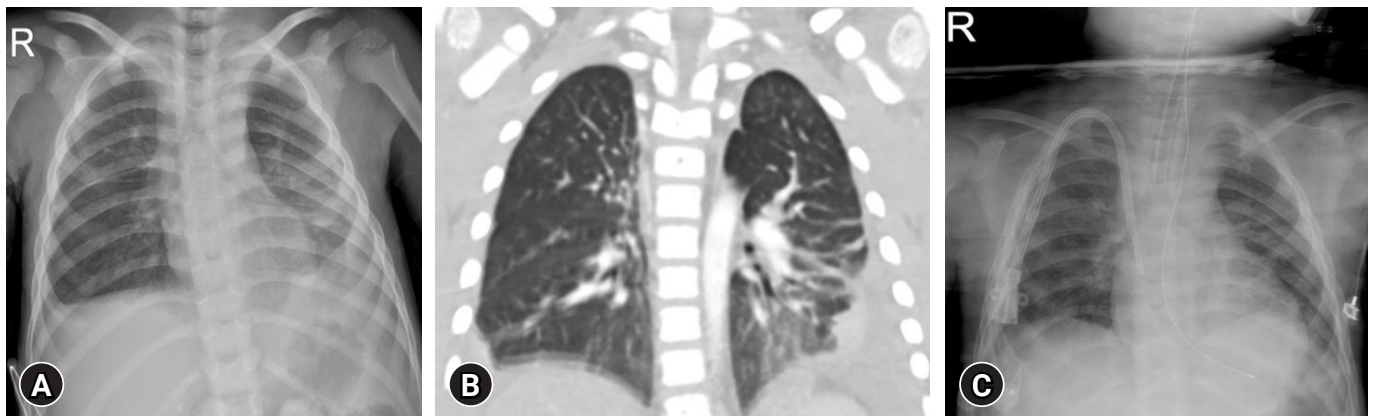


Fig. 1. Chest radiologic findings of a 7-year-old girl on peritoneal dialysis since birth, presenting with prolonged fever. Chest X-ray (A) and computed tomography (B) revealed multifocal peribronchial infiltration and complicated bilateral pleural effusion with diffuse enhancing pleural thickening in both lower lungs. Waxing and waning fever subsided, and pleural effusion decreased (C) after the cessation of peritoneal dialysis 6 months later.

negative. We also performed whole body positron emission tomography-CT (^{18}F -fludeoxyglucose) (Fig. 2). Despite observing mild hypermetabolic uptake in both lungs and pleural effusion, ascites, and lymph nodes in the right lower paratracheal, subcarinal, pulmonary hilar, and left inguinal areas, we concluded that the possibility of malignancy was low. Although we requested that a radiologist and a thoracic surgeon drain the pleural effusion to identify any undiscovered organisms or malignancies that might have caused prolonged inflammation, they could not aspirate or drain the effusion as the absolute amount of fluid was too small. We discontinued vancomycin first to rule out drug fever after 4 weeks of treatment. The intermittent fever occurred up to $38.3\text{ }^{\circ}\text{C}$ but then dropped, and CRP decreased to 5.63 mg/dL . Nine days later, intravenous meropenem treatment was converted to intraperitoneal imipenem administration to cover potentially undetected pleural or peritoneal *K. aerogenes* infection. The fever disappeared, CRP further decreased to 4.61 mg/dL , and the patient was discharged after 52 days of admission (Fig. 3A). She was re-admitted a week later due to re-aggravated fever and CRP of $40.2\text{ }^{\circ}\text{C}$ and 9.61 mg/dL , respectively. Intraperitoneal imipenem treatment was changed to intravenous meropenem. A total of 12 times PD fluid bacteria/fungus/acid-fast bacilli culture tests performed for 3 months were all negative, and white blood cell counts of PD fluid analyses were normal (Table 1). We discontinued antibiotics 9 days after readmission, as we could not identify any infection focus and had to differentiate drug fever. We performed a follow-up CT of the chest and abdomen, indicating findings similar to previous studies. We evaluated the fever of unknown ori-

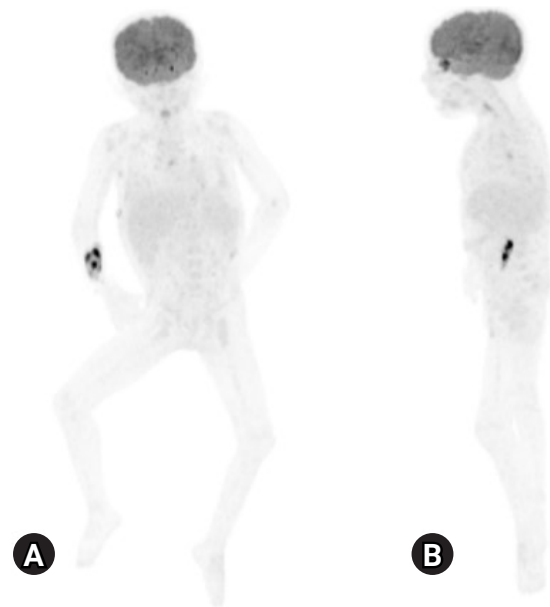


Fig. 2. ^{18}F -fludeoxyglucose whole body positron emission tomography-computed tomography (PET-CT) of a 7-year-old girl on peritoneal dialysis since birth. Whole body PET-CT (A) coronal and (B) right lateral views, demonstrated mild hypermetabolic uptake of subpleural consolidation and ground glass opacity lesions in both lungs and bilateral pleural effusions, ascites, and lymph nodes in the right lower paratracheal, subcarinal, pulmonary hilar, and left inguinal areas (injection site: right forearm).

gin (FUO), including immunologic workups, brain magnetic resonance images, and bone marrow biopsy, and the results were nonspecific. We diagnosed her with systemic juvenile idiopathic arthritis as we could not find any other cause (Table 2),

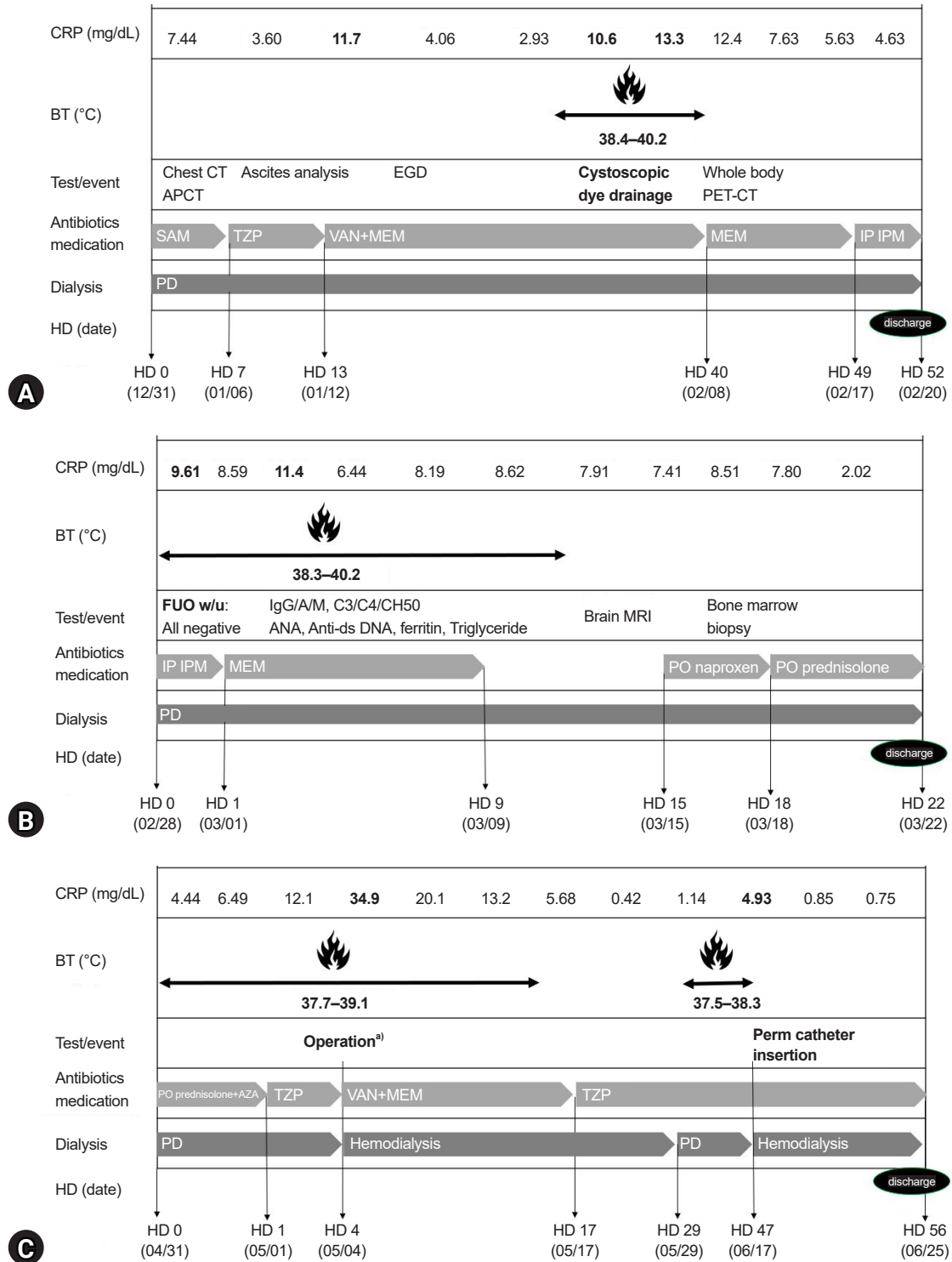


Fig. 3. The clinical courses, laboratory findings, and treatment of a 7-year-old girl on PD with prolonged fever. (A) First admission (Dec 31, 2021–Feb 20, 2022). (B) Second admission (Feb 28, 2022–Mar 22, 2022). (C) Third admission (May 1, 2022–Jun 25, 2022). CRP, C-reactive protein; BT, body temperature; CT, computed tomography; APCT, abdominal and pelvic CT; EGD, esophagogastroduodenoscopy; PET-CT, positron emission tomography-CT; SAM, ampicillin-sulbactam; TZP, piperacillin-tazobactam; VAN, vancomycin; MEM, meropenem; IP IPM, intraperitoneal imipenem; HD, hospital day; FUO, fever of unknown origin; Ig, immunoglobulin; ANA, antinuclear antibody; C3, complement component 3; C4, complement component 4; CH50, complement component CH50; MRI, magnetic resonance imaging; PO, per oral; PD, peritoneal dialysis; AZA, azathioprine. ^{a)}Bladder augmentation and left nephroureterectomy operation for preparing the future kidney transplantation (May 2, 2022).

Table 1. The result of PD fluid analyses (WBC cell count and neutrophil percentage), culture, CRP, and body temperature through the hospital course

Date	Body temperature (°C)	Serum CRP (mg/dL)	Dialysate			Antibiotic treatment
			WBC (/μL)	Neutrophil (%)	Culture	
Jan 1, 2022	38.0	6.65	82	8	No growth	Ampicillin-sulbactam
Jan 5, 2022	38.2	4.24	12	27	No growth	Ampicillin-sulbactam
Jan 10, 2022	37.8	4.04	91	61	No growth	Piperacillin-tazobactam
Jan 12, 2022	37.5	7.24	1	16	No growth	Vancomycin, meropenem
Jan 13, 2022	37.4	11.7	1	3	No growth	Vancomycin, meropenem
Jan 24, 2022	37.6	3.80	1	4	No growth	Vancomycin, meropenem
Feb 3, 2022	38.0	5.10	1	5	No growth	Vancomycin, meropenem
Feb 5, 2022	38.1	7.53	1	5	No growth	Vancomycin, meropenem
Feb 7, 2022	40.2	10.6	1	3	No growth	Vancomycin, meropenem
Feb 28, 2022	38.0	8.59	1	2	No growth	Intraperitoneal imipenem
Mar 7, 2022	38.2	8.49	1	4	No growth	Meropenem
Mar 13, 2022	38.2	8.62	1	30	No growth	No antibiotics

PD, peritoneal dialysis; WBC, white blood cell; CRP, C-reactive protein.

Table 2. The results of fever of unknown origin work up

Infection/hemato-oncologic work up	Result
Blood, urine, stool, sputum, PD fluid bacteria, fungus culture	No growth
Blood CMV, EBV DNA PCR	Negative
Respiratory virus PCR	Negative
Mycoplasma IgM	Negative
IGRA	Negative
Bone marrow biopsy	Normocellular marrow for age No evidence of neoplastic cell infiltration
Whole body PET-CT (Feb 11, 2022)	Mild hypermetabolic both pleural effusions and ascites Mild hypermetabolic subpleural consolidation and GGO lesion in RLL and left lung
Brain MRI (Mar 18, 2022)	Subtle thinning of the corpus callosum Subtle extent of periventricular T2/FLAIR hyperintensities with diminished white matter volume
Immunologic work up (Mar 17, 2022) ^{a)}	
IgG (mg/dL)	1,110 (650–1,600)
IgA (mg/dL)	15.0 (40.0–350)
IgM (mg/dL)	80.4 (50.0–300)
C3 (mg/dL)	175 (82.0–170)
C4 (mg/dL)	40.4 (12.0–36.0)
CH50 (mg/dL)	62.5 (46.7–63.3)
ANA	<1:40
Lymphocyte subset	Normal
NK cell activity (%)	26.8 (11.8–31.9)
No. of NK cell (/μL)	437 (126–592)

PD, peritoneal dialysis; CMV, cytomegalovirus; EBV, Epstein-Barr virus; PCR, polymerase chain reaction; Ig, immunoglobulin; IGRA, interferon-gamma release assay; PET-CT, positron emission tomography-computed tomography; GGO, ground glass opacity; RLL, right lower lung; MRI, magnetic resonance imaging; T2/FLAIR, T2-weighted-fluid-attenuated inversion recovery; C3, complement component 3; C4, complement component 4; CH50, complement component CH50; ANA, antinuclear antibody; NK, natural killer.

^{a)}Values are presented as results (normal range).

started naproxen on hospital day 15, and subsequently added prednisolone (2 mg/kg/day) on day 18. The fever disappeared, and CRP dropped to 2.02 mg/dL. She was discharged after 22

days of admission (Fig. 3B), and azathioprine (1–2 mg/kg/day) was added at the outpatient clinic with CRP ranging from 2.16 to 4.44 mg/dL. She was admitted for bladder augmentation before

kidney transplantation on May 1, 2022. We discontinued immunosuppressants, added stress-dose hydrocortisone, and started prophylactic antibiotics (piperacillin-tazobactam) before surgery. Bladder augmentation and left nephroureterectomy operation were electively performed on hospital day 4. After open abdominal surgery, we stopped her PD and started hemodialysis. CRP elevated to 34.9 mg/dL 2 days after surgery with a mild fever (<38.0 °C). We, therefore, switched from piperacillin-tazobactam to vancomycin and meropenem. CRP slowly decreased without fever while the patient was on hemodialysis for 2 weeks instead of PD. CRP was normalized to 0.42 mg/dL for the first time within 6 months after initial fever onset. A small amount of pleural effusion was still observed on chest X-rays. Three weeks after surgery, after restarting PD, a mild fever developed (37.9 °C), and CRP elevated to 4.93 mg/dL. We planned to perform peritoneal scintigraphy to identify the presence of a PPC, but the test was not available for children at our center. We requested a thoracic surgeon to explore the diaphragm to find a fistula or foramen; however, he refused the procedure because pleural thickening had already progressed, and diaphragm detachment was expected to be very difficult. We ceased PD and restarted hemodialysis, which normalized body temperature, and CRP dropped to 0.78 mg/dL. After resuming PD to confirm if PD and the PPC were the cause of the fever and elevation of inflammatory markers, body temperature rose and CRP increased. We finally decided to stop PD to switch to hemodialysis. The PD catheter was removed, the right subclavian perm catheter was inserted on June 17, 2022, and hemodialysis was stably started and maintained at a 3 times/week schedule (Fig. 3C). Since she started hemodialysis, her fever has not recurred, and pleural effusion, pneumonia, and inflammation markers have slowly improved. The FUO that persisted for 6 months, despite treatment with broad-spectrum antibiotics and immunosuppressants, was finally resolved. The bilateral pleural effusion also gradually improved after discontinuing PD (Fig. 1C). Currently, she attends outpatient clinics and adapts well to hemodialysis, which is scheduled 3 times a week, while awaiting kidney transplantation.

Discussion

Herein we report the case of a 7-year-old female child on PD with complicated pleural effusion and pleuroperitoneal inflammation due to PPC, who developed a prolonged fever. PPC is a mechanical complication of PD [4]. Although the pathophys-

iology of PPC is unknown, the negative thoracic pressure with increased intra-abdominal pressure caused by dialysate instillation is considered to open small defects in the diaphragm and promote migration of dialysate into the pleural space [6].

Several predisposing factors for PPC include congenital factors with a predominance of right-sided effusions such as diaphragmatic muscular hypotonia, congenital diaphragmatic defects, *WT1* mutation syndromes, lymphatic drainage disorders, polycystic kidney disease [5,7,8], and acquired factors such as previous episodes of peritonitis and long-term dialysis with high osmolar dialysate [6,9]. Our patient was on PD for 7 years, during which she had several bouts of peritonitis, contributing to make small defects of diaphragm. We did not perform genetic tests for *WT1* mutation in this patient.

In this case, we reached a delayed diagnosis of PPC-associated pleuritis after 6 months of fever. Despite conducting various workups to identify the cause of the FUO, no specific causes could explain the fever except complicated pleural effusion, pneumonic consolidation, and pleuroperitoneal thickening. She had no symptoms of dyspnea, respiratory difficulties, or signs of volume overload such as edema and weight gain. To our knowledge, no other case of PPC manifesting as fever has been reported.

Diagnosis of PPC is complicated because there are no standardized methods. Many patients with PPC are asymptomatic, but classic symptoms include hypertension, edema, dyspnea, pleuritic chest pain, increased demands of O₂, and inadequate ultrafiltration despite increasing dialysate fluid volume or osmolarity (high dextrose dialysate fluid) [9,10]. Thoracentesis for pleural fluid analysis can identify the characteristics of the pleural fluid to determine whether its composition is close to that of the dialysis fluid, including low lactate dehydrogenase and protein levels and glucose levels higher than the plasma glucose level by 50 mg/dL (sweet hydrothorax) [11]. However, thoracentesis is an invasive test that cannot be performed if the fluid amount is too small to drain. Failure to perform thoracentesis contributed to the delay in diagnosis. In our case, thoracentesis and draining of the pleural fluid for fluid analyses and various cultures were planned but canceled as it was considered dangerous due to the small amount and stickiness of the fluid, causing a delay in diagnosis. CT peritoneography is a common and noninvasive diagnostic tool for cases of large PPC; however, its low sensitivity prevents it from detecting smaller defects [12], and contrast may cause nephrotoxicity [13]. Among the current diagnostic methods, peritoneal scintigraphy is the

safest and most accurate method, with 40% to 50% sensitivity [9,12]. Confirming the presence of radioactive nuclear medicine (technetium 99m) in the thoracic cavity over time is possible after injecting the dialysis solution with the medicine into the peritoneal cavity [9]. However, the test has limited utility in locating the site of a fistula [5,7]. We could not perform peritoneal scintigraphy because the test was unavailable for children at our center, complicating our ability to diagnose PPC.

In this case, we had to stop PD and change to permanent hemodialysis to treat PPC-associated pleuritis. After starting hemodialysis, the inflammation markers decreased, the fever subsided, the pleural effusion improved, and she recovered from the fever, which led to three hospitalizations and discharges over 6 months. Additionally, due to its difficulty, we did not perform a thoracoscopic examination to evaluate the PPC-associated pleuritis. There is no guideline for treating PPC, so the choice of treatment depends on the severity of the patient's symptoms [10]. Treatment options include decreasing the intraperitoneal pressure by stopping the PD temporarily for 6 weeks to 3 months, avoiding daytime dwell, or reducing dialysate fluid volume with continuous pleural fluid drainage [14], which is successful in approximately 50% of PD patients [10,12,14]. Other methods also include changing to hemodialysis permanently [5] or performing chemical pleurodesis using autologous blood, talc, tetracycline, or bleomycin [3]. Video-assisted thoracoscopic pleurodesis or direct repair can also be considered [15]. The rate of resuming PD without recurrence of PPC after surgical repair is 90% for both adults and children; however, surgical treatment is not performed universally as it is complicated and difficult to identify the site of the fistula, especially in children [15].

Early suspicion and a systematic approach to PPC are essential to minimize misdiagnosis or diagnosis delay, especially in patients on chronic PD who present with refractory or recurrent pleural effusions that do not respond to conventional therapy [13]. Diagnosing and treating PPC in children promptly is challenging, given the lack of cases. However, the sum of patients can lead to the implementation of guidelines for diagnostic tools and novel treatments. Fever is a rare manifestation of PPC-associated pleuritis, but this case highlights that PPC-induced complicated pleural effusion and inflammation could cause prolonged fever when no other factor is identified.

Ethical statements

This report was approved by the Institutional Review Board of Asan Medical Center (IRB number S2023-0609-0001), and the informed consents were waived due to the nature of the retrospective study.

Conflicts of interest

Joo Hoon Lee is an editorial board member of the journal but was not involved in the peer reviewer selection, evaluation, or decision process of this article. No other potential conflict of interest relevant to this article was reported.

Funding

None.

Author contributions

Conceptualization: JL, JHL

Data curation: JP, HY

Investigation: JP, HY

Project administration: JJ, JL, JHL

Visualization: JP

Writing Original draft: JP

Writing review & editing: JJ, JHL

All authors read and approved the final manuscript.

References

1. Verrina E, Edefonti A, Gianoglio B, Rinaldi S, Sorino P, Zacchello G, et al. A multicenter experience on patient and technique survival in children on chronic dialysis. *Pediatr Nephrol* 2004;19:82-90.
2. Verrina E. Peritoneal dialysis. In: Avner ED, Harmon WE, Niaudet P, Yoshikawa N, editors. *Pediatric nephrology*. 6th ed. Springer; 2009. p. 1785-810.
3. Ambarsari CG, Bermanshah EK, Putra MA, Rahman FHF, Pardede SO. Effective management of peritoneal dialysis-associated hydrothorax in a child: a case report. *Case Rep Nephrol Dial* 2020;10:18-25.
4. Crabtree JH. Rescue and salvage procedures for mechanical and infectious complications of peritoneal dialysis. *Int J Artif Organs* 2006;29:67-8.
5. Kennedy C, McCarthy C, Alken S, McWilliams J, Morgan RK, Denton M, et al. Pleuroperitoneal leak complicating peritoneal dialysis: a case

- series. *Int J Nephrol* 2011;2011:526753.
6. Dufek S, Holtta T, Fischbach M, Ariceta G, Jankauskiene A, Cerkauskiene R, et al. Pleuro-peritoneal or pericardio-peritoneal leak in children on chronic peritoneal dialysis: a survey from the European Paediatric Dialysis Working Group. *Pediatr Nephrol* 2015;30:2021-7.
 7. Dang MH, Mathew M, Raj R. Pleuroperitoneal leak as an uncommon cause of pleural effusion in peritoneal dialysis: a case report and literature review. *Case Rep Nephrol* 2020;2020:8832080.
 8. Cho HY, Lee BS, Kang CH, Kim WH, Ha IS, Cheong HI, et al. Hydrothorax in a patient with Denys-Drash syndrome associated with a diaphragmatic defect. *Pediatr Nephrol* 2006;21:1909-12.
 9. Yaxley J, Twomey K. Peritoneal dialysis complicated by pleuroperitoneal communication and hydrothorax. *Ochsner J* 2017;17:124-7.
 10. Chow KM, Szeto CC, Li PK. Management options for hydrothorax complicating peritoneal dialysis. *Semin Dial* 2003;16:389-94.
 11. Bohra N, Sullivan A, Chaudhary H, Demko T. The use of pleural fluid to serum glucose ratio in establishing the diagnosis of a not so sweet PD-related hydrothorax: case report and literature review. *Case Rep Nephrol* 2020;2020:8811288.
 12. Alhasan KA. Recurrent hydrothorax in a child on peritoneal dialysis: a case report and review of the literature. *Clin Case Rep* 2018;7:149-51.
 13. Aksoy OY, Gulaldi NCM, Bayrakci US. Hydrothorax in a pediatric patient on peritoneal dialysis: Answers. *Pediatr Nephrol* 2020;35:1421-3.
 14. Dai BB, Lin BD, Yang LY, Wan JX, Pan YB. Novel conservative treatment for peritoneal dialysis-related hydrothorax: Two case reports. *World J Clin Cases* 2020;8:6437-43.
 15. Mori T, Fujino A, Takahashi M, Furugane R, Kobayashi T, Kano M, et al. Successful endoscopic surgical treatment of pleuroperitoneal communication in two infant cases. *Surg Case Rep* 2021;7:181.