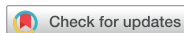

Images in
Cardiovascular Medicine



Q Fever Endocarditis Combined With Thrombus and Antiphospholipid Syndrome

Jieun Lee , MD¹, You-Jung Choi , MD, PhD¹, Hwan Seok Yong , MD, PhD², Man-Jong Baek , MD, PhD³, Jin Oh Na , MD, PhD¹, and Jah Yeon Choi , MD, PhD¹

¹Division of Cardiology, Cardiovascular Center, Korea University Guro Hospital, Seoul, Korea

²Department of Radiology, Korea University Guro Hospital, Seoul, Korea

³Department of Thoracic and Cardiovascular Surgery, Korea University Guro Hospital, Seoul, Korea

OPEN ACCESS

Received: Sep 6, 2022

Revised: Oct 24, 2022

Accepted: Nov 23, 2022

Published online: Dec 27, 2022

Correspondence to

Jah Yeon Choi, MD, PhD

Division of Cardiology, Cardiovascular Center, Korea University Guro Hospital, 148, Gurodong-ro, Guro-gu, Seoul 08308, Korea.
Email: kekeruki@gmail.com

A 63-year-old man presented with dyspnea. Transthoracic echocardiography (TTE) revealed severe degenerative aortic stenosis with decreased left ventricular contractility. Transesophageal echocardiography (TEE) and cardiac computed tomography (CT) showed an outpouching structure at aortomitral intervalvular fibrosa (Figure 1A-D, Supplementary Video 1), compatible with pseudoaneurysm suggesting sequelae of previous infective endocarditis. As he did not suffer from fever or elevated inflammatory markers, surgical aortic valve replacement (SAVR) was performed. On surgery, when extracting the leaflets, subannular pouching was seen without evidence of active inflammation or infection (Figure 1E and F).

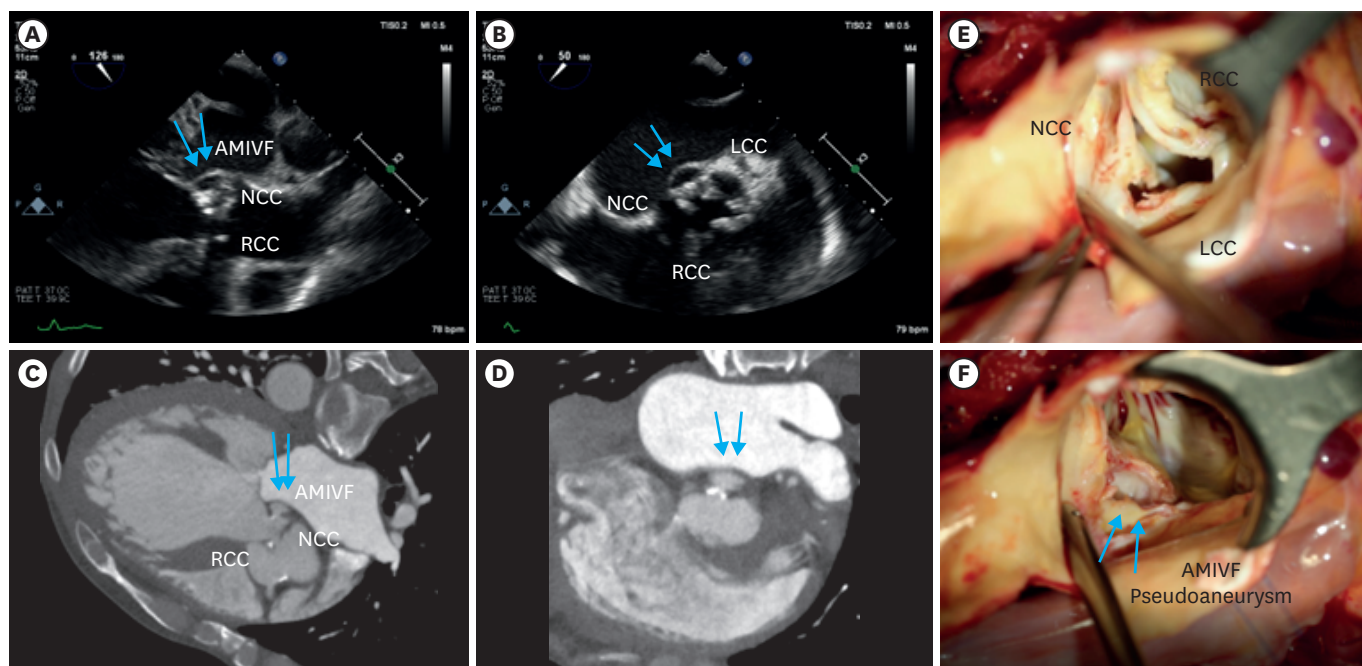


Figure 1. Pre-operative TEE, CT images and Intra-op findings. (A-D) Severe degenerative aortic stenosis with regurgitation and left ventricular dilatation. Outpouching structure at AMIVF with systolic expansion (blue arrows) suggesting pseudoaneurysm. (E) Thickened aortic valve leaflets were noted, especially on NCC and LCC. (F) When extracting the degenerative aortic valve leaflets, subannular pouching was seen between NCC and LCC sides without evidence of active inflammation or infection (blue arrows). AMIVF = aortomitral intervalvular fibrosa; CT = computed tomography; LCC = left coronary cusp; NCC = noncoronary cusp; TEE = transesophageal echocardiography.

Copyright © 2023. The Korean Society of Cardiology

This is an Open Access article distributed under the terms of the Creative Commons Attribution Non-Commercial License (<https://creativecommons.org/licenses/by-nc/4.0>) which permits unrestricted noncommercial use, distribution, and reproduction in any medium, provided the original work is properly cited.

ORCID iDs

- Jieun Lee  <https://orcid.org/0000-0002-7113-6568>
- You-Jung Choi  <https://orcid.org/0000-0003-3512-855X>
- Hwan Seok Yong  <https://orcid.org/0000-0003-0247-8932>
- Man-Jong Baek  <https://orcid.org/0000-0002-1494-4323>
- Jin Oh Na  <https://orcid.org/0000-0002-5096-4428>
- Jah Yeon Choi  <https://orcid.org/0000-0002-6793-4137>

One-year follow-up TTE showed markedly increased aortic valve pressure gradient. TEE and cardiac CT revealed symmetric nodular thickening of bioprosthetic leaflets with opening limitation (**Figure 2A-D**). Based on the diagnosis of subclinical bioprosthetic valve thrombosis, anticoagulation therapy was started. During the hospitalization, the patient had persistent fever with bicytopenia and hepatosplenomegaly, but repetitive blood cultures were negative. There was no definite fever focus in 18F-fluorodeoxyglucose (18F-FDG) positron emission tomography (PET)-CT (**Figure 2E**). Since the patient worked on a farm in Dangjin, where Q fever is relatively prevalent, an indirect immunofluorescence assay for *Coxiella burnetii* was conducted and turned out positive. Additional coagulopathy tests showed positive for lupus anticoagulant, anti-cardiolipin immunoglobulin M (IgM), and anti-beta2 GPI IgM both at baseline and 12-week follow-up. Finally, the patient was diagnosed with Q fever endocarditis combined with antiphospholipid syndrome and treated with doxycycline with hydroxychloroquine and maintained anticoagulation. Recent TTE and cardiac CT follow-up showed complete resolution of bioprosthetic thrombus (**Figure 3**).

Detailed history taking and multimodal imaging are crucial for early diagnosis and treatment for a rare condition of Q fever endocarditis combined with antiphospholipid syndrome.

We obtained written informed consent from the patient.

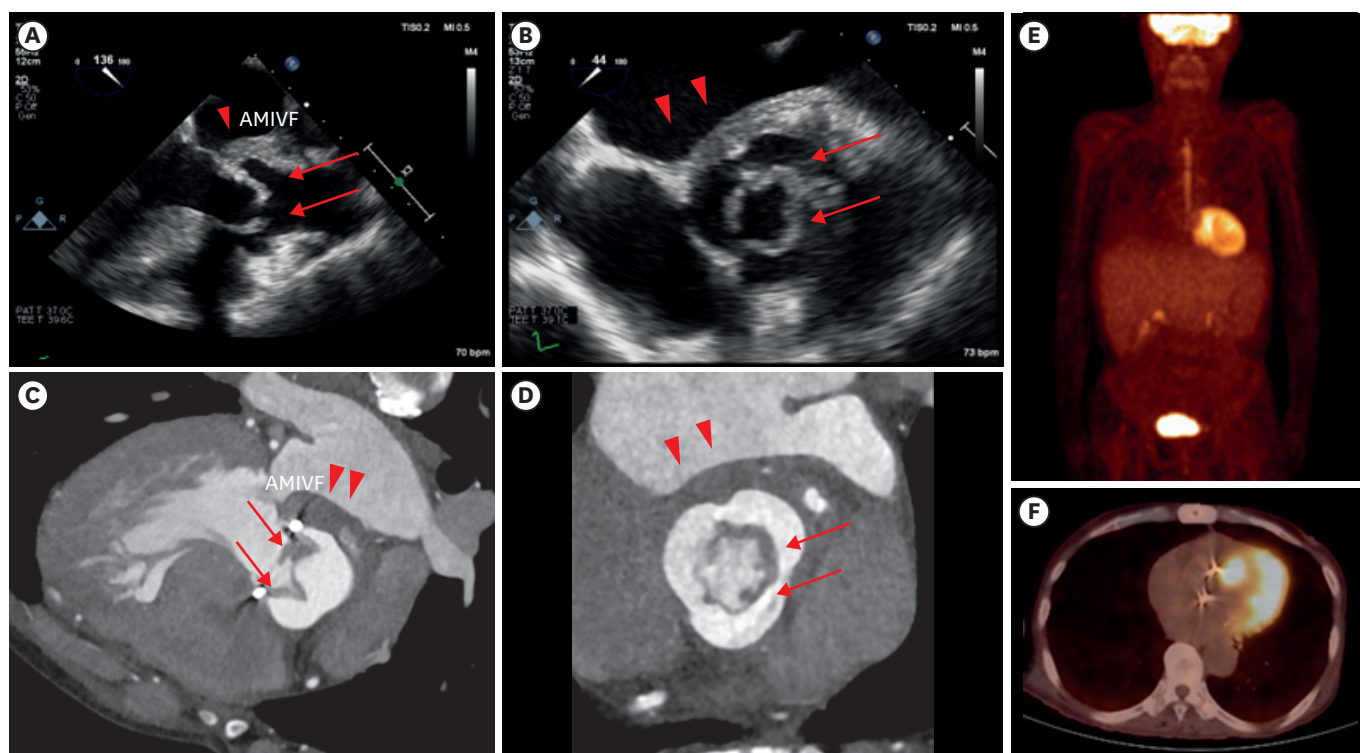


Figure 2. One-year follow-up TEE, CT and 18F-FDG PET-CT images. (A-D) Symmetric nodular thickening of bioprosthetic aortic valve leaflets with opening limitation (red arrows), suggestive of valve thrombus, combined with thickened left atrial wall on AMIVF side (red arrowheads); (E, F) There was no definite abnormal hypermetabolic lesion at the periprosthetic valve in 18F-FDG PET-CT, and there was only mild uptake on hepatosplenomegaly. 18F-FDG = 18F-fluorodeoxyglucose; AMIVF = aortomitral intervalvular fibrosis; CT = computed tomography; LCC = left coronary cusp; NCC = noncoronary cusp; PET = positron emission tomography.

Funding

The authors received no financial support for the research, authorship, and/or publication of this article.

Conflict of Interest

The authors have no financial conflicts of interest.

Data Sharing Statement

The data generated in this study is available from the corresponding author upon reasonable request.

Author Contributions

Conceptualization: Choi JY; Supervision: Na JO, Choi JY; Visualization: Yong HS, Choi JY; Writing- original draft: Lee J; Writing- review & editing: Lee J, Choi YJ, Yong HS, Baek MJ, Na JO, Choi JY.

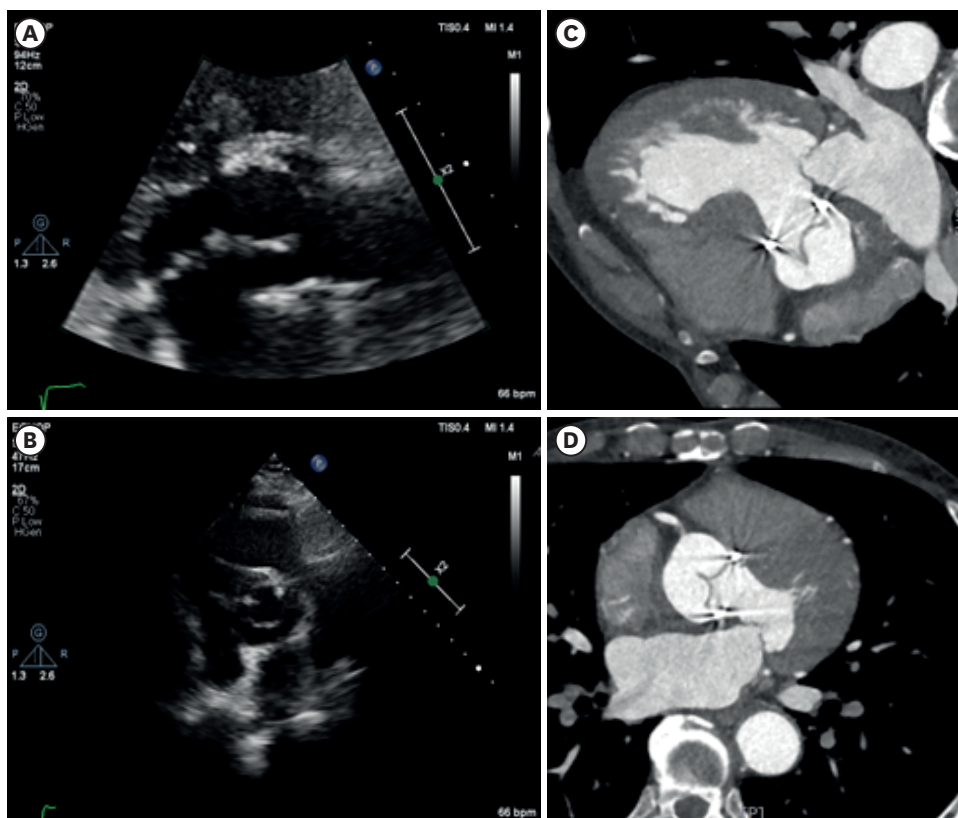


Figure 3. Follow-up TTE and CT images after anticoagulation and antibiotics. (A-D) Symmetric nodular thickening of bioprosthetic AV leaflets were disappeared, suggesting complete resolution of prosthetic AV thrombus. AV = aortic valve; CT = computed tomography; TTE = transthoracic echocardiography.

SUPPLEMENTARY MATERIAL

Supplementary Video 1

Three-dimensional TEE of pseudoaneurysm.

[Click here to view](#)