



# Fenestrated popliteal vein pierced by a branch of the tibial nerve

Edward C. Muo<sup>1</sup>, Joe Iwanaga<sup>2,3,4,5</sup>, Juan J. Cardona<sup>2</sup>, Łukasz Olewnik<sup>6</sup>, Aaron S. Dumont<sup>2</sup>, R. Shane Tubbs<sup>2,3,5,7,8,9,10</sup>

<sup>1</sup>Tulane University School of Medicine, New Orleans, LA, <sup>2</sup>Department of Neurosurgery, Tulane Center for Clinical Neurosciences, Tulane University School of Medicine, New Orleans, LA, <sup>3</sup>Department of Neurology, Tulane Center for Clinical Neurosciences, Tulane University School of Medicine, New Orleans, LA, USA, <sup>4</sup>Department of Oral and Maxillofacial Anatomy, Graduate School of Medical and Dental Sciences, Tokyo Medical and Dental University, Tokyo, Japan, <sup>5</sup>Department of Structural & Cellular Biology, Tulane University School of Medicine, New Orleans, LA, USA, <sup>6</sup>Department of Anatomical Dissection and Donation, Medical University of Lodz, Lodz, Poland, <sup>7</sup>Department of Anatomical Sciences, St. George's University, St. George's, Grenada, <sup>8</sup>Department of Surgery, Tulane University School of Medicine, New Orleans, LA, <sup>9</sup>Department of Neurosurgery and Ochsner Neuroscience Institute, Ochsner Health System, New Orleans, LA, USA, <sup>10</sup>University of Queensland, Brisbane, QLD, Australia

**Abstract:** Knowledge of anatomical variations is important so as to avoid potential iatrogenic injury or misdiagnosis on imaging. Here we report an unusual finding and relationship between the tibial nerve and popliteal vein. During the routine dissection of an adult cadaver, it was noted that a branch of the tibial nerve in the popliteal fossa pierced the most distal part of the popliteal vein. This unusual finding is described and relevant reports in the literature discussed. Our hopes are that such a report might help surgeons avoid injury to such a fenestrated popliteal vein and the tibial nerve branch traveling through it therefore decreasing patient morbidity.

**Key words:** Anatomy, Cadaver, Anatomical variations, Venous fenestration, Case report

Received February 2, 2023; 1st Revised March 11, 2023; 2nd Revised May 27, 2023; Accepted June 5, 2023


## Introduction

Venous circulation of the lower limb shows great variation among individuals in comparison to arterial circulation [1]. Normal venous drainage of the leg is characterized by superficial and deep veins that drain muscular compartments of the leg, ankle and foot, and surrounding cutaneous microcirculation [1]. The deep veins of the leg include the fibular (FV), anterior tibial, and posterior tibial (PTV) veins which drain into the popliteal vein situated in the popliteal fossa and posterior to the knee. The popliteal vein ends at the adductor hiatus where it drains into the femoral vein [2]. The

deep veins of the leg are generally paired as they travel with their corresponding arteries. Two major superficial veins of the leg include the great saphenous and small saphenous veins which derive venous blood from the medial and lateral aspects of the foot, respectively and drain to the deep veins of the lower limb.

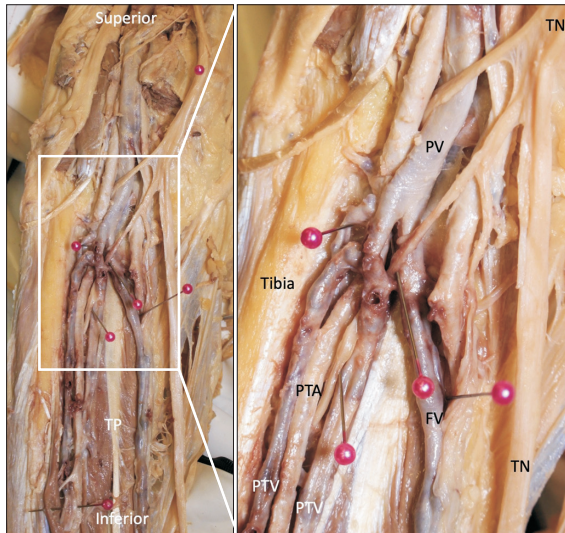
Vascular malformations are the result of abnormalities in vascular embryological development and can involve arteries, veins, capillaries, lymphatics, or a combination of these vessels. Due to their considerable phenotypic variability and symptomatology, vascular malformations are often misdiagnosed or entirely missed upon clinical examination [3]. Venous malformations are the most common type of vascular malformation, comprising two thirds of all known vascular malformations [4, 5]. Forty percent of venous malformations are found in the limbs with more than half involving the deep veins [4]. Venous malformations of the lower limb are frequently asymptomatic; however, some are associated with various pathological syndromes [4].

### Corresponding author:

Juan J. Cardona   
Department of Neurosurgery, Tulane University School of Medicine,  
New Orleans, LA 70112, USA  
E-mail: jcardonaz@tulane.edu

Copyright © 2023. Anatomy & Cell Biology

This is an Open Access article distributed under the terms of the Creative Commons Attribution Non-Commercial License (<http://creativecommons.org/licenses/by-nc/4.0/>) which permits unrestricted non-commercial use, distribution, and reproduction in any medium, provided the original work is properly cited.



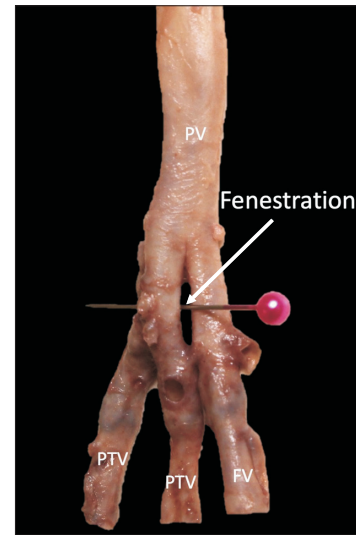
**Fig. 1.** Tibial nerve branch to the posterior tibialis muscle traveling through the fenestrated distal PV. FV, fibular vein; PTA, posterior tibial artery; PTV, posterior tibial vein; PV, popliteal vein; TN, tibial nerve; TP, tibialis posterior muscle.

Deep venous system anomalies in vascular malformations include aplasia, phlebectasia, or hypoplasia of venous trunks, avalvulia, and aneurysms [5]. Genuine diffuse phlebectasia of Bockenheimer and Servelle-Martorell syndrome are pure venous malformations that affect the lower limb [5]. Combined malformations that affect the deep veins and surrounding tissues in the lower limb include Maffucci syndrome, Blue rubber bleb nevus syndrome, and Klippel-Trenaunay syndrome [5]. Over time, lower limb malformations can produce venous reflux, leading to chronic venous insufficiency, deep vein thrombosis, and hemorrhage [4, 5]. Management of venous malformations is greatly dependent upon the size and localized or diffuse nature of the lesion and occur through multiple modalities including compression garments, sclerotherapy, endovenous laser therapy, cryotherapy, and surgical resection [4].

Here, we report an anatomical venous variation of the posterior leg found incidentally in a cadaver during routine dissection.

## Case report

A venous variation was found in the right lower limb during a routine dissection of an 87-year-old at death embalmed female cadaver (Figs. 1, 2). A tibial nerve branch to the tibialis posterior muscle pierced the distal popliteal vein which then gave rise to two PTVs and the FV. Only the nerve branch



**Fig. 2.** Perforation in the distal popliteal vein (PV) which then gives rise to the posterior tibial veins (PTV) and fibular vein (FV).

traveled through the perforation through the popliteal vein. Both popliteal and posterior tibial arteries ran anterior to the popliteal vein perforation. The posterior tibial artery was located between the two PTVs. No additional anatomical variations were found in the ipsilateral popliteal fossa and adjacent areas and no similar vein perforation was identified on the left side. No obvious surgical scar was found in or around the dissected area.

## Discussion

Variations of the venous drainage at and near the popliteal fossa have been documented in the literature with the use of cadavers, venography, and ultrasound and have served as a method of identification of deep venous system malformations of the lower limb. Reported variations include agenesis of the deep veins, duplication or presence of multiple vessels at the popliteal fossa (unilateral and bilateral), high confluence of the tibial veins, and anatomical course variations of lower limb deep veins in relation to their corresponding arteries. With computed tomography venography, Park et al. [6] identified variations of the femoral and popliteal veins including agenesis of the femoropopliteal vein in three patients that also had a persistent sciatic vein instead of a femoropopliteal vein. Also reported from the study was multiplication (duplication and complex networks) and anatomical course variation of the femoropopliteal vein in relation to its artery where patients displayed medial malposition, anterior ro-

tation, and posterior rotation of the vein [6]. Unilateral or bilateral duplication of the popliteal and femoral veins have also been correlated to a greater risk of deep vein thrombosis because of a decrease in blood flow velocity and pooling of blood, stimulating the formation of a thrombus [7].

Calf veins also show anatomical variation among individuals. Using color doppler ultrasound, Engelhorn et al. [8] described a variation of the PTV where the PTVs were absent or hypoplastic in patients suspected of having deep vein thrombosis [8]. Yi and Kim [9] reported more variations in the PTVs than in the anterior tibial and FVs. PTV variations were classified into four types. The most common type was one proximal and two distal posterior tibial veins and the least common was two proximal and three distal PTVs [9]. Confluence of the tibial veins has been observed in multiple studies with Park et al. [6] documenting anterior and PTVs extending above the knee joint, and Quinlan et al. [10] reporting formation of the popliteal vein both proximal and distal to the knee joint. Variations in drainage of the fibular veins include trifurcation or draining solely into the anterior or PTV [10].

In the clinical setting, tibial nerve compression by the tendinous arch of the origin of the soleus muscle in the popliteal fossa has been reported [11]. However, we could not find any reports in the literature of tibial nerve compression by it or one of its branches traveling through a fenestrated popliteal vein such as reported in the present case. Embryologically, the development of veins of the lower extremities starts at around four weeks and ends by the twelfth week. Overall, venous embryogenesis is divided in three stages: 1, the primitive fibular vein which is the first developed and main vein of the lower limb; 2, replaced by the axial vein; and 3, later by the femoral vein. This development is specially regulated by three important angio-guiding nerves: 1, the axial nerve which becomes the sciatic nerve; 2, the pre-axial nerve which becomes the femoral nerve; and 3, the post-axial nerve which becomes the femoral cutaneous nerve [12, 13]. These nerves allow the proper growth of the venous vessels (sciatic vein, femoral vein, and cranial extension of the small saphenous vein, respectively) by releasing important substance such as vascular endothelial growth factor. Furthermore, these three venous plexuses merge at the popliteal region forming the embryonic popliteal crossroad which will become the saphenopopliteal junction as remnant [12, 13]. Therefore, adding the important limb rotation process which the cranial and caudal aspects become medial (tibial) and lateral (fibular),

there is the possibility that several different configurations between the popliteal vein and its relationships develop during these processes, particularly an axonal growth could be entrapped within the venous blood vessel to give rise to the variant morphology described herein [12, 13]. Interestingly, other veins of the body might be pierced by adjacent nerves such as the spinal accessory nerve traveling through the internal jugular vein or the auriculotemporal nerve traversing the superficial temporal vein [14]. In our case, such an anatomical variation might be encountered during, for example, repair of popliteal artery aneurysms. Therefore, during such surgical exposures, the surgeon would need to be cognizant of potential damage to the tibial nerve or its branches when retracting overlying popliteal vein.

The venous flow could also be disturbed by the nerve compression. In general, the venous flow could be affected by the venous valve disorders which might result in varicose veins. The present variation might be another etiology of such pathological condition.

## ORCID

Edward C. Muo: <https://orcid.org/0000-0003-2386-0575>

Joe Iwanaga: <https://orcid.org/0000-0002-8502-7952>

Juan J. Cardona: <https://orcid.org/0000-0002-4148-5687>

Łukasz Olewnik: <https://orcid.org/0000-0002-6414-9504>

Aaron S. Dumont: <https://orcid.org/0000-0002-8077-8992>

R. Shane Tubbs: <https://orcid.org/0000-0003-1317-1047>

## Author Contributions

Conceptualization: ECM, JI, RST. Data acquisition: JI, ŁO. Data analysis or interpretation: JI, ASD, RST. Drafting of the manuscript: ECM, JJC. Critical revision of the manuscript: JJC, ŁO, ASD, RST. Approval of the final version of the manuscript: all authors.

## Conflicts of Interest

No potential conflict of interest relevant to this article was reported.

## Funding

None.

## Acknowledgements

The authors sincerely thank those who donated their bodies to science so that anatomical research could be performed. Results from such research can potentially increase mankind's overall knowledge that can then improve patient care. Therefore, these donors and their families deserve our highest gratitude [15].

## References

1. Black CM. Anatomy and physiology of the lower-extremity deep and superficial veins. *Tech Vasc Interv Radiol* 2014;17:68-73.
2. Kale A, Gayretli O, Oztürk A, Gürses IA, Dikici F, Usta A, Sahinoğlu K. Classification and localization of the adductor hiatus: a cadaver study. *Balkan Med J* 2012;29:395-400.
3. Steiner JE, Drolet BA. Classification of Vascular Anomalies: an update. *Semin Intervent Radiol* 2017;34:225-32.
4. Christenson BM, Gipson MG, Smith MT. Pelvic vascular malformations. *Semin Intervent Radiol* 2013;30:364-71.
5. Eifert S, Villavicencio JL, Kao TC, Taute BM, Rich NM. Prevalence of deep venous anomalies in congenital vascular malformations of venous predominance. *J Vasc Surg* 2000;31:462-71.
6. Park EA, Chung JW, Lee W, Yin YH, Ha J, Kim SJ, Park JH. Three-dimensional evaluation of the anatomic variations of the femoral vein and popliteal vein in relation to the accompanying artery by using CT venography. *Korean J Radiol* 2011;12:327-40.
7. Sadowska A, Spodnik JH, Wójcik S. Variations in popliteal fossa venous anatomy: implications for diagnosis of deep-vein thrombosis. *Folia Morphol (Warsz)* 2013;72:51-6.
8. Engelhorn CA, Cerri G, Coral F, Gosalan CJ, Engelhorn ALDV. [Anatomical variations of tibial vessels: differential diagnosis of deep vein thrombosis by vascular ultrasound]. *J Vasc Bras* 2013;12:216-20. Portuguese.
9. Yi KH, Kim HJ. Is variation in posterior tibial veins a risk factor for deep-vein thrombosis? *Clin Anat* 2021;34:829-34.
10. Quinlan DJ, Alikhan R, Gishen P, Sidhu PS. Variations in lower limb venous anatomy: implications for US diagnosis of deep vein thrombosis. *Radiology* 2003;228:443-8.
11. Mastaglia FL. Tibial nerve entrapment in the popliteal fossa. *Muscle Nerve* 2000;23:1883-6.
12. Simka M. Anatomy of lower limb. In: Tiwary SK, editor. *Approach to lower limb oedema*. Springer; 2022. p.13-24.
13. Sawyer E, Sinkler MA, Tadi P. Anatomy, bony pelvis and lower limb: popliteal vein. *StatPearls Publishing*; 2023.
14. Cesarek MR, Olewnik Ł, Iwanaga J, Dumont AS, Tubbs RS. A previously unreported variant of the auriculotemporal nerve. *Morphologie* 2022;106:310-3.
15. Iwanaga J, Singh V, Ohtsuka A, Hwang Y, Kim HJ, Moryś J, Ravi KS, Ribatti D, Trainor PA, Sañudo JR, Apaydin N, Şengül G, Albertine KH, Walocha JA, Loukas M, Duparc F, Paulsen F, Del Sol M, Addis P, Hegazy A, Tubbs RS. Acknowledging the use of human cadaveric tissues in research papers: recommendations from anatomical journal editors. *Clin Anat* 2021;34:2-4.