



# Magnetic resonance angiography in assessment of anomalies of anterior cerebral artery in adults

Noha Abdelfattah Ahmed Madkour

Department of Diagnostic and Interventional Radiology, Kasr Alainy Hospital, Faculty of Medicine, Cairo University, Cairo, Egypt

**Abstract:** Anomalies of anterior cerebral artery (ACA) include aplasia, hypoplasia and variations in number. Magnetic resonance angiography (MRA) is a non-invasive diagnostic technique for assessment of anomalies of cerebral arteries. The aim of the study was to determine the role of MRA in detection of variants of ACA in adults. This study is an observational retrospective study. This study included forty-nine adult cases (28 males and 21 females), mean age  $48 \pm 12.9$  SD with anomalies of ACA in MRA. Magnetic resonance imaging of the brain and MRA were done to all patients. Cerebral MRA and magnetic resonance images were evaluated for frequency and distribution of variants of anterior cerebral arteries, associated aneurysms and infarctions. Odds ratios (ORs) and relative risk were calculated to determine risk of occurrence of cerebral infarctions in patients with anomalies of ACA. Hypoplasia of ACA was the commonest anomaly of ACA (51% of cases). Risk of occurrence of cerebral infarctions was higher in cases with azygos variant (OR, 3.3;  $P=0.35$ ) than in those with hypoplastic ACA (OR, 2;  $P=0.58$ ). MRA was highly reliable in identification of different variants of ACA and concomitant vascular changes.

**Key words:** Anomalies, Anterior cerebral artery, Magnetic resonance angiography, Adults

Received June 10, 2023; Revised July 18, 2023; Accepted August 8, 2023

## Introduction

Anterior cerebral artery (ACA) is one of the main terminal branches of intracranial internal carotid artery (ICA) [1, 2]. ACA shares in the anterior circulation of circle of Willis (CW) [3, 4].

Anomalies or variants of ACA include aplasia, hypoplasia and variations in number [5, 6]. In reported studies, the commonest anomaly of ACA was aplasia or hypoplasia of A1 segment of ACA [7, 8].

Incidence of aplasia and hypoplasia of A1 segment of ACA were 6.7% and 3% respectively at magnetic resonance angiography (MRA) in adults [9, 10].

While in autopsies, hypoplasia of ACA was discovered in 10% of cases and aplasia was noted in 2% of cases [11].

Many studies stated that anomalies of ACA were related to serious clinical implications due to co-existence of aneurysms and brain infarctions with ACA variants especially with azygos ACA as a consequence of hemodynamic instability [12-15].

MRA is a crucial non-invasive imaging modality in defining anomalies of cerebral arteries and any associated intracranial aneurysms [16-18].

## Aim of the study

To determine the role of MRA in detection of variants of ACA in adults.

### Corresponding author:

Noha Abdelfattah Ahmed Madkour 

Department of Diagnostic and Interventional Radiology, Kasr Alainy Hospital, Faculty of Medicine, Cairo University, Cairo 11562, Egypt  
E-mail: [dramohamadkour@kasralainy.edu.eg](mailto:dramohamadkour@kasralainy.edu.eg)

Copyright © 2023. Anatomy & Cell Biology

This is an Open Access article distributed under the terms of the Creative Commons Attribution Non-Commercial License (<http://creativecommons.org/licenses/by-nc/4.0/>) which permits unrestricted non-commercial use, distribution, and reproduction in any medium, provided the original work is properly cited.

## Materials and Methods

This study is a retrospective observational cohort study. Institutional ethical approval was not necessary due to retrospective nature of the study. The study included 49 adult human subjects with ACA anomalies on brain MRA examinations. The study was conducted during the period from February 2015 till April 2023.

Of 74 brain MRA cases, forty nine cases were with anomalies of ACA in cerebral MRA and twenty five cases were with normal brain MRA. The cases were referred from outpatient clinics to department of Radiodiagnosis in Kasr Alainy Hospital, Cairo University. All cases performed magnetic resonance imaging (MRI) of the brain and cerebral MRA on 1.5 Tesla (Achieva; Philips Medical System) using head coil.

### Data acquisition

MRI brain: Axial T1WI: Time of repetition/time of echo (TR/TE): 488/15, T2WI: 3,732/100, FLAIR: TR/TE/time of inversion (TI): 6,000/120/2,000, coronal T2 and sagittal T2. Field of view 24 cm, 256×256 matrix, 6 mm slices thickness, 1.5 mm slice gap.

Three-dimension time of flight MRA (3D TOF MRA): TR/TE: 25/6.9, flip 20, 160 slices. Field of view: 160 mm, thickness 1 mm, and matrix: 512×512. Maximum intensity projection (MIP) axial images were generated.

3D TOF MRA and maximum intensity projection images were evaluated for anomalies of the ACA, associated aneurysms and ICA stenosis. Magnetic resonance brain images were reviewed for any associated brain infarctions.

All procedures followed were in accordance with the ethical standards of code of ethics of the World Medical Association (Declaration of Helsinki).

### Inclusion criteria

First, adult patients with ACA anomalies detected by brain MRA. Second, patients with variations of ACA with and without accompanying brain lesions.

### Exclusion criteria

First, cases without variations of ACA in brain MRA. Second, cases with anomalies of anterior communicating artery (AcomA). Third, children, post-operative cases, patients with metallic implants and aneurysmal clips.

### Statistics

Odds ratios and relative risk were calculated to determine risk of occurrence of cerebral infarctions in patients with different types of ACA anomalies using Fisher's exact test. Data were expressed as number and percentage of cases. Chi square test was used to assess the association between cate-

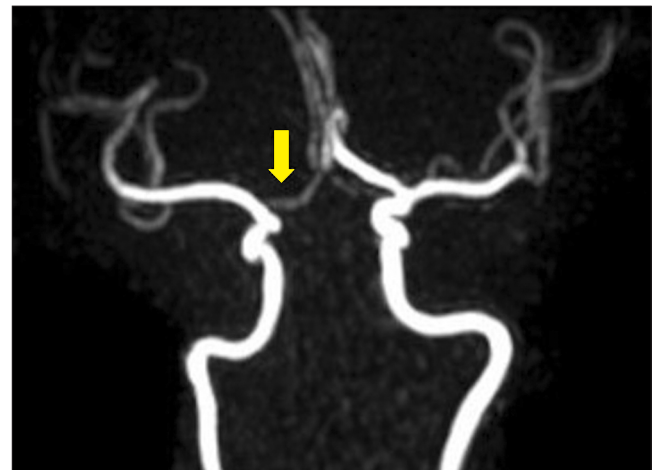


Fig. 1. Magnetic resonance angiography of both ICA and cerebral branches in a 64-year-old male patient. Hypoplastic A1 segment of right ACA (arrow). ICA, internal carotid artery; ACA, anterior cerebral artery.

**Table 1.** Frequency, distribution of anomalies of ACA and associated vascular abnormalities (n=49)

ACA variants	Cases	Sex (male:female)	Age	Site (right:left)	Associated aneurysms	Associated infarctions	Associated ICA stenosis
Hypoplasia (A1 segment)	25 (51.02)	15:10	47.5±11.6	23:2	-	2 cases with contralateral ACA infarctions (8)	2 (8)
Aplasia (A1 segment)	15 (30.6)	8:7	48.9±11.29	11:4	-	-	-
Azygos (A2 segment)	7 (14.28)	4:3	44±17	-	1 (14.28)	1 case with bilateral frontal infarctions (14.28)	2 (28.56)
Bihemispheric (A2 segment)	2 (4.08)	1:1	70.5±10.6	1:1	-	-	-
Total cases	49 (100.0)	28:21	48.4±12.9	35:7 and 7 azygos	1 (2)	3 (6.12)	4 (8.16)

Values are presented as number (%) or mean±SD. ACA, anterior cerebral artery; ICA, internal carotid artery.

gorical variables. A  $P$ -value  $<0.05$  was considered significant. Statistical analysis was performed with Statistical Package for the Social Sciences (IBM SPSS Statistics version 29; IBM Co.).

## Results

The commonest anomaly of ACA in the current study was hypoplasia of A1 precommunicating segment of ACA which was predominantly right sided (Table 1, Fig. 1).

Insignificant association between morphological variants of ACA and patients' sex was noted (Table 2).

Although insignificant association between azygos, hypoplastic ACA and cerebral infarctions was observed, but risk of occurrence of brain infarctions was higher in patients with azygos ACA than that in hypoplastic ACA (Table 3).

Multiple MRA views were mandatory to identify common trunk of bihemispheric variant of ACA (Fig. 2).

One case with saccular aneurysm was noted within distal A2 segment of azygos ACA representing 2% of total patients with ACA anomalies (Table 1).

**Table 2.** Association between morphological variants of ACA and patients' sex

ACA variants	Male	Female	Chi-square value	$P$ -value
Hypoplastic ACA	15 (60)	10 (40)	1.00	0.31
Aplastic ACA	8 (53.3)	7 (46.6)	0.06	0.79
Azygos ACA	4 (57.1)	3 (42.85)	0.14	0.71
Bihemispheric ACA	1 (50)	1 (50)	0.00	1.00
Total ACA variants	28 (57.1)	21 (42.85)	0.72	0.39

Values are presented as number (%). ACA, anterior cerebral artery.

**Table 3.** Statistical values for brain infarctions associated with azygos ACA and hypoplastic A1 segment of ACA

ACA anomaly	Associated infarctions (present/total)	Odds ratios for brain infarctions	95% confidence interval	Relative risk	$P$ -value <sup>a)</sup>
Azygos ACA	1/7 (14.28)	3.3	0.26, 42.6	3.0	0.35
Hypoplastic ACA	2/25 (8)	2.0	0.16, 23.6	1.91	0.58

Values are presented as number (%). ACA, anterior cerebral artery. <sup>a)</sup>Fisher's exact test was used.

Combined anomalies of anterior and posterior circulation of CW were noted in five cases (10.2%) with ACA anomalies which were combined aplastic/hypoplastic A1 segment of ACA and hypoplastic proximal posterior cerebral artery (PCA).

## Discussion

In the current study, hypoplastic ACA was the commonest anomaly of ACA which was in discordance with Uchino et al. [19], who deduced that aplastic ACA was the commonest variation of ACA. Also, the former study had limitations in detection of bihemispheric ACA. In the present study, bihemispheric ACA was the least common variant of ACA.

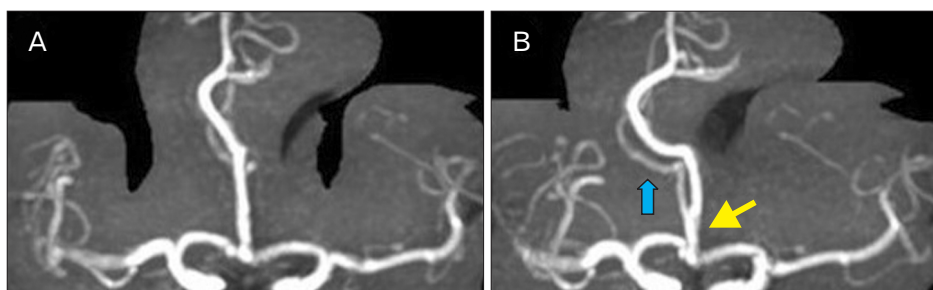
In the present study, cases with right sided hypoplastic ACA were more common than left sided cases with high male preponderance which coincided with other studies [20, 21].

Zampakis et al. [22], investigated the role of computed tomography angiography in detection of cerebral arterial anomalies and found that hypoplastic ACA was more common than aplastic ACA with incidence of 27% and 9% respectively which was in agreement with the current study.

In the present study, there was no adult cases with triple ACA. Triple ACA, is a third artery that originates from AcomA with normal A2 segments of ACA presenting a rare incidence of 1.3% in MRA and autopsy studies [9, 23].

Some researchers identified the presence of few incidental cerebral aneurysms in association with azygos ACA reaching to 11% which accorded with the current study [19, 24, 25].

Infrequent incidence of cerebral infarctions 2% was re-



**Fig. 2.** Magnetic resonance angiography (MRA) of both intracranial ICA in a 63-year-old male patient with bihemispheric ACA. Antero-posterior (A) and right oblique (B) views of MRA revealed hypoplastic right ACA (blue arrow) and dominant left ACA arising from a common A2 trunk (yellow arrow). ICA, internal carotid artery; ACA, anterior cerebral artery.

ported by Uchino et al. [19], in association with ACA anomalies mostly with aplastic ACA. While in the current study, a slightly higher percentage of 6% was noted for ACA variants who sustained brain infarctions.

Clinically significant pathologies including brain strokes could be associated with azygos ACA. Anomalies of ACA could predispose to bilateral infarctions as in occluded azygos ACA or unilateral cerebral infarctions due to wandering of thrombi into the hypertrophied contralateral segment of ACA in cases with aplastic and hypoplastic ACA [26-28].

ICA stenosis and atherosclerosis have been described in association with anomalies of ACA especially with hypoplastic ACA [29, 30]. While in the current study, few cases with ICA stenosis existed together with hypoplastic and azygos ACA.

In a large cross sectional MRA study analyzed by Hindenes et al. [31], combined anomalous ACA and hypoplastic or missing proximal PCA was noted in 1.1% of cases with variations in CW. While in the current study, combined anomalies of ACA and hypoplastic proximal PCA were noted in 10% of cases with ACA anomalies. Inconsistency with the previous study was due to different sample population.

Limitations of the study were relatively small sample size and rarity of the cases. Strengths of the study were the foremost capabilities of brain MRA in evaluation of ACA variants by providing images of high definition and improved tissue contrast.

In conclusion, MRA was highly reliable in identification of different anomalies of ACA and concomitant vascular changes.

## ORCID

Noha Abdelfattah Ahmed Madkour:  
<https://orcid.org/0000-0001-8723-179X>

## Author Contributions

Conceptualization: NAAM. Data acquisition: NAAM. Data analysis or interpretation: NAAM. Drafting of the manuscript: NAAM. Critical revision of the manuscript: NAAM. Approval of the final version of the manuscript: NAAM.

## Conflicts of Interest

No potential conflict of interest relevant to this article was reported.

## Funding

None.

## References

1. Lasjaunias PL, Berenstein A, Brugge KG. Surgical neuroangiography. 1, clinical vascular anatomy and variations. 2nd ed. Springer; 2001. p. 479-631.
2. Stefani MA, Schneider FL, Marrone AC, Severino AG, Jackowski AP, Wallace MC. Anatomic variations of anterior cerebral artery cortical branches. *Clin Anat* 2000;13:231-6.
3. Stock KW, Wetzel S, Kirsch E, Bongartz G, Steinbrich W, Radue EW. Anatomic evaluation of the circle of Willis: MR angiography versus intraarterial digital subtraction angiography. *AJNR Am J Neuroradiol* 1996;17:1495-9.
4. Barboriak DP, Provenzale JM. Pictorial review: magnetic resonance angiography of arterial variants at the Circle of Willis. *Clin Radiol* 1997;52:429-36.
5. Patruș B, Laissy JP, Jouini S, Kawiecki W, Coty P, Thiébot J. Magnetic resonance angiography (MRA) of the circle of Willis: a prospective comparison with conventional angiography in 54 subjects. *Neuroradiology* 1994;36:193-7.
6. Baptista AG. Studies on the arteries of the brain. II. The anterior cerebral artery: some anatomic features and their clinical implications. *Neurology* 1963;13:825-35.
7. Ravikanth R, Philip B. Magnetic resonance angiography determined variations in the circle of Willis: analysis of a large series from a single center. *Tzu Chi Med J* 2019;31:52-9.
8. Alpers BJ, Berry RG, Paddison RM. Anatomical studies of the circle of Willis in normal brain. *AMA Arch Neurol Psychiatry* 1959;81:409-18.
9. Krabbe-Hartkamp MJ, van der Grond J, de Leeuw FE, de Groot JC, Algra A, Hillen B, Breteler MM, Mali WP. Circle of Willis: morphologic variation on three-dimensional time-of-flight MR angiograms. *Radiology* 1998;207:103-11.
10. Taşar M, Yetişer S, Taşar A, Uğurel S, Gönül E, Sağlam M. Congenital absence or hypoplasia of the carotid artery: radioclinical issues. *Am J Otolaryngol* 2004;25:339-49.
11. Perlmutter D, Rhoton AL Jr. Microsurgical anatomy of the anterior cerebral-anterior communicating-recurrent artery complex. *J Neurosurg.* 1976;45:259-72.
12. Shatri J, Cerkezi S, Ademi V, Reci V, Bexheti S. Anatomical variations and dimensions of arteries in the anterior part of the circle of Willis. *Folia Morphol (Warsz)* 2019;78:259-66.
13. Stehbens WE. Aneurysms and anatomical variation of cerebral

- arteries. *Arch Pathol* 1963;75:45-64.
14. Huber P, Braun J, Hirschmann D, Agyeman JF. Incidence of berry aneurysms of the unpaired pericallosal artery: angiographic study. *Neuroradiology* 1980;19:143-7.
  15. Kayembe KN, Sasahara M, Hazama F. Cerebral aneurysms and variations in the circle of Willis. *Stroke* 1984;15:846-50.
  16. Ghazali RM, Shuaib IL. Comparison between 3D TOF magnetic resonance angiography and intraarterial digital subtraction angiography in imaging the circle of Willis. *Malays J Med Sci* 2003;10:37-42.
  17. Grandin CB, Mathurin P, Duprez T, Stroobandt G, Hammer F, Goffette P, Cosnard G. Diagnosis of intracranial aneurysms: accuracy of MR angiography at 0.5 T. *AJNR Am J Neuroradiol* 1998;19:245-52.
  18. Huston J 3rd, Nichols DA, Luetmer PH, Goodwin JT, Meyer FB, Wiebers DO, Weaver AL. Blinded prospective evaluation of sensitivity of MR angiography to known intracranial aneurysms: importance of aneurysm size. *AJNR Am J Neuroradiol* 1994;15:1607-14.
  19. Uchino A, Nomiya K, Takase Y, Kudo S. Anterior cerebral artery variations detected by MR angiography. *Neuroradiology* 2006;48:647-52.
  20. Pentylala S, Sankar KD, Bhanu PS, Kumar NSS. Magnetic resonance angiography of hypoplastic A1 segment of anterior cerebral artery at 3.0-Tesla in Andhra Pradesh population of India. *Anat Cell Biol* 2019;52:43-7.
  21. Qiu C, Zhang Y, Xue C, Jiang S, Zhang W. MRA study on variation of the circle of willis in healthy Chinese male adults. *Biomed Res Int* 2015;2015:976340.
  22. Zampakis P, Panagiotopoulos V, Petsas T, Kalogeropoulou C. Common and uncommon intracranial arterial anatomic variations in multi-detector computed tomography angiography (MDCTA). What radiologists should be aware of. *Insights Imaging* 2015;6:33-42.
  23. Singh R, Kannabathula AB, Sunam H, Deha D. Anatomical variations of circle of Willis - a cadaveric study. *Int Surg J* 2017;4:1249-58.
  24. Truwit CL. Embryology of the cerebral vasculature. *Neuroimaging Clin N Am* 1994;4:663-89.
  25. Huh JS, Park SK, Shin JJ, Kim TH. Saccular aneurysm of the azygos anterior cerebral artery: three case reports. *J Korean Neurosurg Soc* 2007;42:342-5.
  26. Nutik S, Dilenge D. Carotid-anterior cerebral artery anastomosis. Case report. *J Neurosurg* 1976;44:378-82.
  27. Okahara M, Kiyosue H, Mori H, Tanoue S, Sainou M, Nagatomi H. Anatomic variations of the cerebral arteries and their embryology: a pictorial review. *Eur Radiol* 2002;12:2548-61.
  28. Yamaguchi K, Uchino A, Sawada A, Takase Y, Kuroda Y, Kudo S. Bilateral anterior cerebral artery territory infarction associated with unilateral hypoplasia of the A1 segment: report of two cases. *Radiat Med* 2004;22:422-5.
  29. Waaijer A, van Leeuwen MS, van der Worp HB, Verhagen HJ, Mali WP, Velthuis BK. Anatomic variations in the circle of Willis in patients with symptomatic carotid artery stenosis assessed with multidetector row CT angiography. *Cerebrovasc Dis* 2007;23:267-74.
  30. Kwak HS, Hwang SB, Chung GH, Lee SY. Pattern of circle of Willis between normal subject and patients with carotid atherosclerotic plaque. *Neurol Asia* 2015;20:7-14.
  31. Hindenes LB, Häberg AK, Johnsen LH, Mathiesen EB, Robben D, Vangberg TR. Variations in the Circle of Willis in a large population sample using 3D TOF angiography: the Tromsø study. *PLoS One* 2020;15:e0241373.