



Stenotrophomonas maltophilia Periprosthetic Joint Infection after Hip Revision Arthroplasty

Valentino Latallade, MD, Carlos Lucero, MD, Pablo Slullitel, MD, Martin Buttaró, MD

*Hip Surgery Unit, Institute of Orthopaedics “Carlos E. Ottolenghi”,
Italian Hospital of Buenos Aires, Buenos Aires, Argentina*

Stenotrophomonas maltophilia, a well-established opportunistic bacterium, primarily impacts healthcare settings. Infection of the musculoskeletal system with this bacterium is rare. We report on the first known case of hip periprosthetic joint infection (PJI) caused by *S. maltophilia*. The potential for development of a PJI caused by this pathogen should be considered by orthopaedic surgeons, particularly in patients with multiple severe comorbidities.

Key Words: Total hip arthroplasty, Revision surgery, Infection, *Stenotrophomonas maltophilia*

Periprosthetic joint infection (PJI), a serious complication of orthopaedic reconstructive surgery in adults, can have a significant impact on patient health and survival¹⁾. It is the leading reason for performance of primary revision total knee replacement (TKR), and the third leading reason for performance of primary revision total hip arthroplasty (THA). The prevalence of PJI is between 1-2%²⁾ for TKR and 0.3-2.9%³⁾ for THA. While *Staphylococcus aureus* and *Staphylococcus coagulase-negative* are the germs most commonly associated with this complication, with a prevalence of 50-75%⁴⁾ of cases, infection caused by

uncommon organisms can also occur.

PJI caused by *Stenotrophomonas maltophilia* in orthopedics is rare, with only a few reported cases. A case of a patient with soleus myositis and no history of trauma was reported in 2002⁵⁾, and rare complications resulting from infection with this organism during spinal procedures including vertebroplasty and lumbar microdiscectomy have also been reported⁶⁾. In addition, a case of PJI after reverse total shoulder arthroplasty^{6,7)} and a case involving performance of total elbow arthroplasty leading to an above-elbow amputation has also been reported⁸⁾. To the best of our knowledge, this is the first report of PJI related to the hip caused by this organism.

CASE REPORT

The written informed consent was obtained from the patient for the publication of this report. We report on the case of a 73-year-old male who was admitted to the hospital with signs of infection at the surgical site on his left hip. The patient had undergone a staged bilateral THA (Fig. 1A) 20 years prior due to avascular necrosis. The patient's past medical history included empty sella syndrome with multiple complications from neurosurgical bleeding, penicillin allergy, adrenal insufficiency, and prolonged hospitalization

Submitted: November 2, 2022 **1st revision:** February 9, 2023
2nd revision: March 27, 2023 **Final acceptance:** March 27, 2023

Address reprint request to

Valentino Latallade, MD

(<https://orcid.org/0000-0002-2249-1969>)

Hip Surgery Unit, Institute of Orthopaedics “Carlos E. Ottolenghi”,
Italian Hospital of Buenos Aires, 4190 Peron St., C1199ABH
Buenos Aires, Argentina

TEL: +54-2804365627

E-mail: valentino.latallade@hospitalitaliano.org.ar

This is an Open Access article distributed under the terms of the Creative Commons Attribution Non-Commercial License (<http://creativecommons.org/licenses/by-nc/4.0>) which permits unrestricted non-commercial use, distribution, and reproduction in any medium, provided the original work is properly cited.

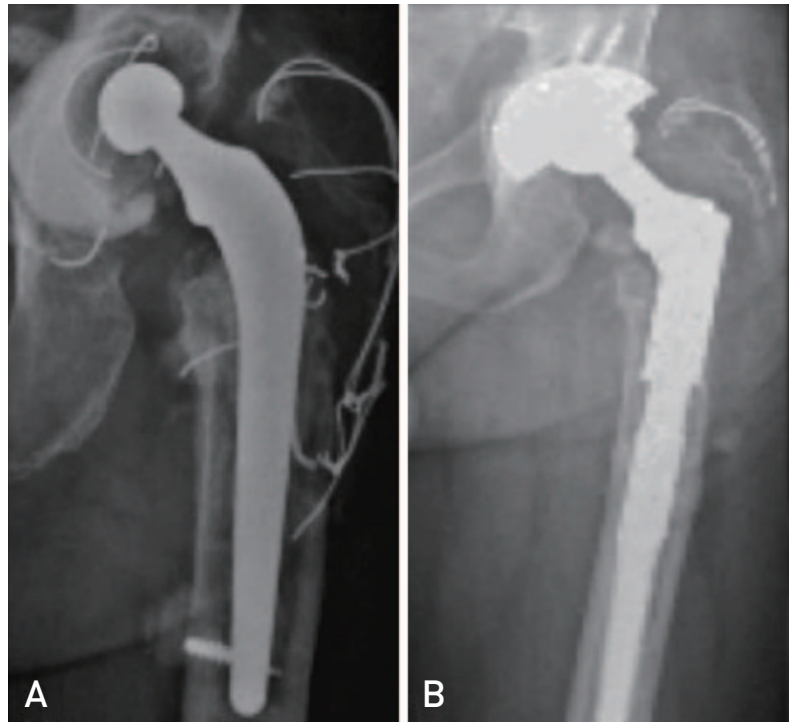


Fig. 1. (A) Staged bilateral total hip arthroplasty 20 years ago due to avascular necrosis. (B) One-stage revision performed in our center twelve years after the index surgery due an aseptic loosening of his left hip.

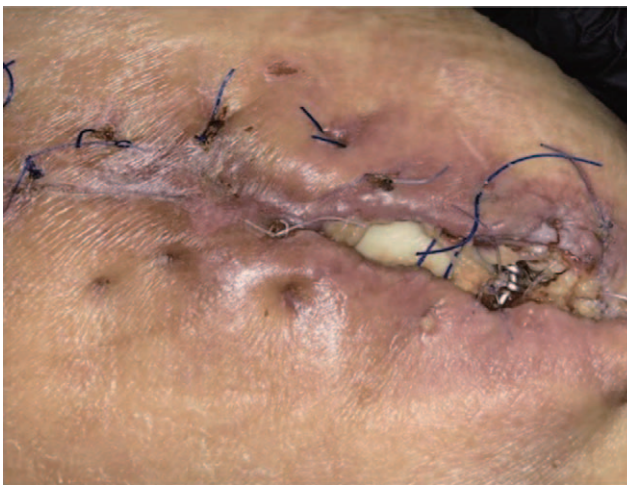

Fig. 2. Infected patient wound, fifteen days after one time revision.

due to drug addiction.

Twelve years after the index surgery, the patient developed an aseptic loosening of his left hip, which was treated with a one-stage revision performed in our center (Fig. 1B). Preoperative laboratory results showed the following: white cell count (WBC)=5,560/mm³ (normal value, 5,000-10,000/mm³), erythrocyte sedimentation rate (ESR)=43 mm/hr (normal value, 2-20 mm/hr), and ultrasensitive C-reactive

protein (CRP)=10 mg/L (normal value, 0-5 mg/L). In the post-surgery check-ups on day 15, the patient presented with purulent wound drainage (Fig. 2). Mainly the clinical evaluation, combined with the elevation of markers of infection (ESR=33 mm/hr, CRP=20 mg/L) was suggestive of deep THA infection. WBC and blood glucose levels were in the normal range. Based on these findings along with a joint aspiration (*Escherichia coli* with resistance to ampicillin) an open debridement and irrigation with prosthetic retention was performed followed by administration of antibiotic therapy (DAIR [debridement, antibiotics and implant retention]). DAIR was performed instead of a two-stage revision due to difficulties with obtaining insurance authorization for the patient. Deep tissue samples were sent for culture and administration of broad-spectrum antibiotics was initiated with intravenous (IV) ciprofloxacin 500 mg/12 hours for six weeks. The same germ isolated during the preoperative joint aspiration was obtained from intraoperative cultures. However, due to persistent signs of infection, two DAIR were performed, one at three weeks and one at six weeks postoperatively. *Staphylococcus epidermidis* was cultured in all samples. A six-week course of IV antibiotic therapy consisting of vancomycin 1 g every 12 hours and rifampicin 300 mg every 12 hours was administered, according to the antibiogram. The patient remained asymptomatic with no

signs of infection at the surgical site.

Two years after surgery, the patient suffered two episodes of prosthetic dislocation. Serum laboratory results showed WBC 13,700/mm³, ESR 35 mm/hr, and CRP 108 mg/dL. Due to instability and chronic wound infection, two-stage revision was performed, including placement of a cement spacer with antibiotics in the first stage (Fig. 3). Empirical IV meropenem 500 mg every 12 hours and trimethoprim 80 mg/sulfamethoxazole 400 mg were administered for two weeks. *S. epidermidis* was detected in the intraoperative cultures; a six-week course of teicoplanin 400 mg every 12 hours and ciprofloxacin 500 mg every 12 hours was prescribed by the infectology service. Two weeks later, the patient was hospitalized for fever and persistent wound drainage. Laboratory results showed WBC 11,240/mm³, ESR 25 mm/hr, and CRP 137 mg/dL. A new surgical debridement was performed and the spacer was kept in place. The presence of *E. coli* was detected in intraoperative cultures. During his hospital stay, the patient developed deep vein thrombosis and intestinal ischemia that required resection of the transverse and small colon. He was then transferred to the intensive care unit (ICU) in order to undergo further treatment. Due to persistent signs of infection, additional



Fig. 3. First of two-stage revision with a cement spacer with antibiotics, two years after last DAIR (debridement, antibiotics and implant retention).

surgical debridements were performed, including revision of the spacer. The presence of *Candida parapsilosis* was detected in intraoperative samples, and treatment was adjusted to include antifungals (fluconazole 200 mg every 12 hours) for 10 weeks. The patient's condition showed improvement and he was discharged from the hospital. However, due to multiple independent risk factors, he was not able to undergo the second stage of revision surgery.

Two years after discharge, the patient was readmitted due to a reactivation of his chronic wound infection; symptoms included fever, fistulous lesions, and purulent spontaneous drainage. Laboratory results showed WBC 7,611/mm³, ESR 47 mm/hr, and CRP 36 mg/dL. A revision of the cement spacer, antibiotic-loaded with vancomycin and liposomal amphotericin B, was performed. The presence of methicillin-sensitive *S. aureus*, *E. coli*, and *Acinetobacter baumannii* was detected in cultures. Three months after the initial revision, once the markers of inflammation had normalized and in the absence of clinical signs of infection, the second stage of the re-implantation arthroplasty procedure was performed using a femoral tumor stem and an uncemented porous tantalum cup created with 3D printing (Fig. 4), in order to address the acetabular defect. However, five months after surgery, the patient experienced another episode of dislocation and reactivation of his chronic infection. Laboratory results showed WBC 8,455/mm³, ESR 32 mm/hr, and CRP

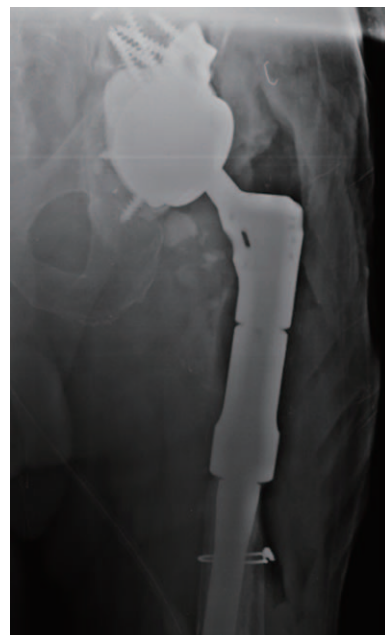

Fig. 4. Second stage of re-implantation arthroplasty with a femoral tumor stem and uncemented porous tantalum cup created with three-dimensional printing, two years and three months after patient discharge.

57 mg/dL. DAIR was performed again with wide resection of necrotic tissue and retention of all components (Fig. 5). Despite detection of a large number of WBC by microscopic analysis, no microorganisms were isolated, although conduct of an overseeding sample resulted in identification of *S. maltophilia*. The patient was prescribed suppressive antibiotic therapy with levofloxacin at a dosage of 750 mg per 24 hours. However, three months later, the patient suffered a new prosthesis dislocation. Currently, the patient is still living with a chronically dislocated hip revision prosthesis and has been taking suppressive antibiotics for one year, with no signs of reactivation of the chronic infection (Fig. 6). Based on the patient's clinical and inflammatory parameters, the infectologists plan on discontinuing the suppressive antibiotic therapy in the next few weeks. The latest laboratory results showed WBC 7,430/mm³, ESR 36 mm/hr, and CRP 47 mg/dL. The patient and his family have decided not to undergo another revision surgery.

DISCUSSION

S. maltophilia, a well-established opportunistic Gram-negative bacterium, primarily causes infection in healthcare settings, such as hospital-acquired and ventilator-associated pneumonia and infections of the bloodstream⁹. It can also be a cause of occasional community-acquired infection. Prolonged hospital stays, being a patient in an ICU, and the use of mechanical ventilation have been identified as risk factors associated with infection with *S. maltophilia*¹⁰.

Few cases of infection with *S. maltophilia* have been reported in the orthopedic literature. Complications of spine surgery due to infections caused by this pathogen have been

reported, and isolated and scattered cases have been reported in the literature. In one such case, development of epidural pus following a lumbar microdiscectomy was reported in a patient who was not immunocompromised¹¹, which was treated successfully with a six-week course of IV administration of cefoperazone-sulbactam, followed by six weeks of oral levofloxacin. A few cases of skin infection in healthy patients or patients with concomitant diseases have also been reported. However, antibiotic treatment with trimethoprim-sulfamethoxazole along with surgical debridement was effective in a case of myositis⁵.

S. maltophilia is a microorganism with natural resistance to many antibiotics including beta-lactams and aminoglycosides, which are widely used in the empirical treatment of nosocomial bacteremia and pneumonia¹². Few antibiotics are effective against *S. maltophilia*; trimethoprim-sulfamethoxazole and levofloxacin are used in treatment of infection with *S. maltophilia*¹²⁻¹⁴. However, the initial empirical treatment of nosocomial infections such as bacteremia and pneumonia does not usually include administration of these antibiotics. Instead, based on current recommendations for treatment of infection with *S. maltophilia*, which are based on case series, case reports, and the results of *in vitro* susceptibility tests, levofloxacin and trimethoprim-sulfamethoxazole are the most commonly used agents^{15,16}.

In this case the patient had a chronic infection that was difficult to treat, so that treatment with IV administration of antibiotics was unsuccessful. Chronic infections are known to have an association with biofilms, and *S. maltophilia* can adhere to foreign material, forming a biofilm for protection from host defenses and antimicrobial agents, which can be attributed in part to its positively charged surface and fim-

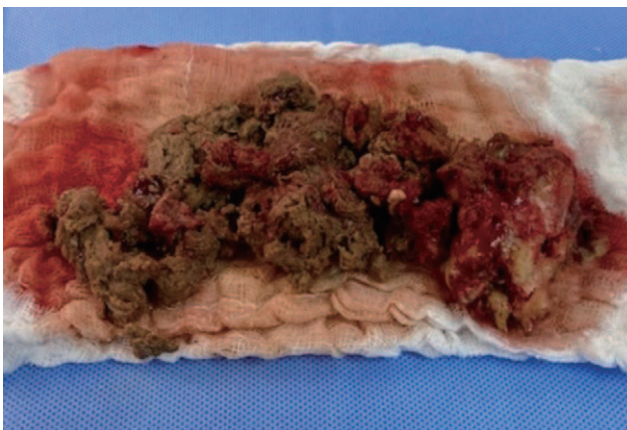


Fig. 5. Necrotic tissue resected in new DAIR (debridement, antibiotics and implant retention), five months after tumoral re-implantation arthroplasty.

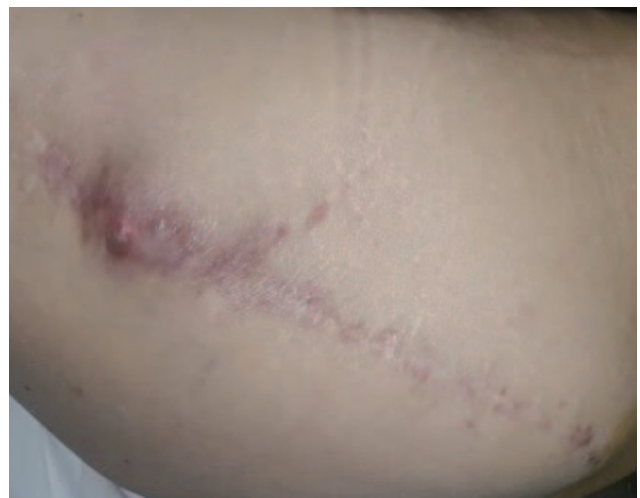

Fig. 6. Latest patient control, with no signs of wound infection.

brial adhesions. In addition, *S. maltophilia* is naturally resistant to beta-lactam antibiotics, including carbapenems and aminoglycosides. Based on this, we can emphasize the fact that the emergence of the microorganism was a result of prolonged administration of antibiotic for treatment of a long-term infection in a patient with multiple underlying health conditions related to infection with *S. maltophilia*.

To the best of our knowledge, this is the first reported case of infection with *S. maltophilia* in an infected revision hip arthroplasty. Unfortunately, in this case the outcome was not favorable. Based on the findings of this case, orthopedic surgeons should be informed with regard to the potential of *S. maltophilia* as a rare but infectious microorganism and the need for responsible antimicrobial stewardship in order to prevent the emergence and spread of these types of antibiotic-resistant bacteria. Currently, infection with *S. maltophilia* in deep prosthetic joint infections is rare; however, with the growing resistance to antibiotics, it could potentially pose a major problem in the near future.

FUNDING

No funding to declare.

CONFLICT OF INTEREST

The authors declare that there is no potential conflict of interest relevant to this article.

REFERENCES

- Kurtz SM, Lau E, Schmier J, Ong KL, Zhao K, Parvizi J. Infection burden for hip and knee arthroplasty in the United States. *J Arthroplasty*. 2008;23:984-91. <https://doi.org/10.1016/j.arth.2007.10.017>
- Levy DM, Wetters NG, Levine BR. Prevention of periprosthetic joint infections of the hip and knee. *Am J Orthop (Belle Mead NJ)*. 2016;45:E299-307.
- Kurtz S, Ong K, Lau E, Mowat F, Halpern M. Projections of primary and revision hip and knee arthroplasty in the United States from 2005 to 2030. *J Bone Joint Surg Am*. 2007;89:780-5. <https://doi.org/10.2106/JBJS.F.00222>
- Parvizi J, Zmistowski B, Berbari EF, et al. New definition for periprosthetic joint infection: from the Workgroup of the Musculoskeletal Infection Society. *Clin Orthop Relat Res*. 2011;469:2992-4. <https://doi.org/10.1007/s11999-011-2102-9>
- Downhour NP, Petersen EA, Krueger TS, Tangella KV, Nix DE. Severe cellulitis/myositis caused by *Stenotrophomonas maltophilia*. *Ann Pharmacother*. 2002;36:63-6. <https://doi.org/10.1345/aph.1A148>
- Alfonso Olmos M, Silva González A, Duarte Clemente J, Villas Tomé C. Infected vertebroplasty due to uncommon bacteria solved surgically: a rare and threatening life complication of a common procedure: report of a case and a review of the literature. *Spine (Phila Pa 1976)*. 2006;31:E770-3. <https://doi.org/10.1097/01.brs.0000240202.91336.99>
- Hantes ME, Papageorgiou F, Komnos GA. *Stenotrophomonas maltophilia* periprosthetic joint infection after reverse total shoulder arthroplasty. *IDCases*. 2020;21:e00796. <https://doi.org/10.1016/j.idcr.2020.e00796>
- Henning S, Teare L. *Stenotrophomonas maltophilia* infection: an unusual complication of total elbow arthroplasty. *JMM Case Rep*. 2014;1:e000661. <https://doi.org/10.1099/jmmcr.0.000661>
- Aisenberg G, Rolston KV, Dickey BF, Kontoyiannis DP, Raad II, Safdar A. *Stenotrophomonas maltophilia* pneumonia in cancer patients without traditional risk factors for infection, 1997-2004. *Eur J Clin Microbiol Infect Dis*. 2007;26:13-20. <https://doi.org/10.1007/s10096-006-0243-7>
- Tseng CC, Fang WF, Huang KT, et al. Risk factors for mortality in patients with nosocomial *Stenotrophomonas maltophilia* pneumonia. *Infect Control Hosp Epidemiol*. 2009;30:1193-202. <https://doi.org/10.1086/648455>
- Adsul NM, Panigrahi V, Acharya S, Kalra KL, Chahal RS. *Stenotrophomonas maltophilia* spondylodiscitis following lumbar microdiscectomy mimicking a cotton granuloma: a case report and literature review. *Surg Neurol Int*. 2020;11:28. https://doi.org/10.25259/SNI_23_2020
- Senol E, DesJardin J, Stark PC, Barefoot L, Snyderman DR. Attributable mortality of *Stenotrophomonas maltophilia* bacteremia. *Clin Infect Dis*. 2002;34:1653-6. <https://doi.org/10.1086/340707>
- Chung HS, Hong SG, Lee Y, et al. Antimicrobial susceptibility of *Stenotrophomonas maltophilia* isolates from a Korean tertiary care hospital. *Yonsei Med J*. 2012;53:439-41. <https://doi.org/10.3349/ymj.2012.53.2.439>
- Wang WS, Liu CP, Lee CM, Huang FY. *Stenotrophomonas maltophilia* bacteremia in adults: four years' experience in a medical center in northern Taiwan. *J Microbiol Immunol Infect*. 2004;37:359-65.
- Fiore M, Rondinella C, Paolucci A, Morante L, De Paolis M, Sambri A. Functional outcome after reimplantation in patients treated with and without an antibiotic-loaded cement spacers for hip prosthetic joint infections. *Hip Pelvis*. 2023;35:32-9. <https://doi.org/10.5371/hp.2023.35.1.32>
- Kim SJ, Cho YJ. Current guideline for diagnosis of periprosthetic joint infection: a review article. *Hip Pelvis*. 2021;33:11-7. <https://doi.org/10.5371/hp.2021.33.1.11>