



Primary Arthroplasty for Unstable and Failed Intertrochanteric Fractures: Role of Multi-Planar Trochanteric Wiring Technique

Javahir A. Pachore, MS (Ortho), MCh (Ortho), Vikram Indrajit Shah, MS (Ortho)*,
Sachin Upadhyay, MS (Ortho), FIJR^{††}, Shrikunj Babulal Patel, DNB (Ortho)[§]

Department of Hip Arthroplasty, Shalby Hospitals, Ahmedabad, India

*Department of Knee and Hip Arthroplasty, Shalby Hospitals, Ahmedabad, India**

Department of Orthopaedics, NSCB Medical College, Jabalpur, India[†]

Department of Trauma and Arthroplasty, Shalby Hospitals, Jabalpur, India[†]

Department of Arthroplasty and Trauma, Shalby Hospitals, Ahmedabad, India[§]

Purpose: The primary objective of the current study is to demonstrate the trochanteric wiring technique. A secondary objective is to evaluate the clinico-radiological outcomes of use of the wiring technique during primary arthroplasty for treatment of unstable and failed intertrochanteric fractures.

Materials and Methods: A prospective study including follow-up of 127 patients with unstable and failed intertrochanteric fractures who underwent primary hip arthroplasty using novel multi-planar trochanteric wiring was conducted. The average follow-up period was 17.8 ± 4.7 months. Clinical assessment was performed using the Harris hip score (HHS). Radiographic evaluation was performed for assessment of union of the trochanter and any mechanical failure. $P < 0.05$ was considered statistically significant.

Results: At the latest follow-up, the mean HHS showed significant improvement from 79.9 ± 1.8 (at three months) to 91.6 ± 5.1 ($P < 0.05$). In addition, no significant difference in the HHS was observed between male and female patients ($P = 0.29$) and between fresh and failed intertrochanteric fractures ($P = 0.08$). Union was achieved in all cases of fractured trochanter, except one. Wire breakage was observed in three patients. There were five cases of limb length discrepancy, three cases of lurch, and three cases of wire-related bursitis. There were no cases of dislocation or infection. Radiographs showed stable prosthesis in situ with no evidence of subsidence.

Conclusion: Use of the proposed wiring technique was helpful in restoring the abductor level arm and multi-planar stability, which enabled better rehabilitation and resulted in excellent clinical and radiological outcomes with minimal risk of mechanical failure.

Key Words: Hip fractures, Intertrochanteric fractures, Failed intertrochanteric fractures, Abductor lever arm, Harris hip score

Submitted: October 14, 2022 **1st revision:** February 27, 2023

2nd revision: March 20, 2023 **3rd revision:** March 22, 2023

Final acceptance: March 23, 2023

Address reprint request to

Sachin Upadhyay, MS (Ortho), FIJR

(<https://orcid.org/0000-0002-2640-0147>)

Department of Orthopaedics, NSCB Medical College, Tilwara Rd,

Doctors Colony, Medical College Colony, Jabalpur 482003, India

TEL: +91-9329078849

E-mail: drsachinupadhyay@gmail.com

This is an Open Access article distributed under the terms of the Creative Commons Attribution Non-Commercial License (<http://creativecommons.org/licenses/by-nc/4.0>) which permits unrestricted non-commercial use, distribution, and reproduction in any medium, provided the original work is properly cited.

INTRODUCTION

Along with increasing life-expectancy worldwide, the incidence of intertrochanteric fracture has shown a dramatic increase. Femoral intertrochanteric fractures are common in the geriatric population with decreased bone mineral density, resulting from a low energy injury^{1,2}. In these patients there is a significant burden of comorbidity associated with high incidence of perioperative morbidity and mortality which can lead to significant deterioration of the patient's health-related quality of life. Therefore, consideration of appropriate surgical intervention and quality patient care is necessary. Use of an appropriate surgical technique is of critical importance in trochanteric reconstruction during primary hip arthroplasty³⁻⁵. It enables earlier ambulation and rehabilitation, which in-turn is helpful in restoration of biomechanical function of the hip joint. In addition, stable fixation enables better repair of the capsule and soft tissues, reducing the risk of dislocation, as well as problems with healing such as non-union, with maintenance of the abductor lever arm.

Several techniques from simple wiring to specific trochanteric armanentarium, have been used successively in-order to minimize impairment of healing and to ensure the integrity of the abductor lever arm. There is increasing concern about the potential side effects of use of the reconstruction technique for fixation of trochanteric fragments. Despite use of any repair technique and efforts to fix the fractured fragments, its secondary migration is an usual complication⁶. Many patients present with pain, bursitis over the trochanteric region, and an associated lurch, as well as weakness of the abductor, and radiographs showing impaired trochanteric healing and loosened, broken, or proud wires during the follow-up period⁶. Revision surgical interventions are then performed for removal of hardware and as an attempt to reconstruct the trochanter. Therefore, in an effort to address these critical concerns, the authors have developed a modified approach focused on multi-planar stability. According to our hypothesis, the proposed multi-planar wiring technique is an efficient method for fixation of fractured fragments of the greater trochanter in performance of arthroplasty for treatment of intertrochanteric fractures of the hip. Our study was designed to examine the clinical and radiological outcomes after primary hip arthroplasty using multi-planar trochanteric wiring for treatment of unstable and/or failed intertrochanteric fractures in elderly patients and to provide a discussion of these findings along with a review of previously reported literature.

MATERIALS AND METHODS

After obtaining approval from the respective institutional review board and ethical committee of Shalby Hospitals (No. ECR/711/Inst/GJ/2015), a prospective study along with follow-up of 127 patients with unstable intertrochanteric fracture of the femur (types AO type 31-A2.2, A2.3, and A3) and failed intertrochanteric fractures who underwent primary hip arthroplasty using novel multi-planar trochanteric wiring at Shalby Hospitals (Ahmedabad, India) from January 2018 to September 2020 was conducted. Written informed consent was obtained from all patients who participated in the current study. Patients of either sex diagnosed with unstable and/or failed intertrochanteric fracture were eligible for inclusion in the study. The exclusion criteria were as follows: (1) open fractures and preoperative neurological deficit, (2) preoperative evidence of any infection, (3) peptic ulceration and upper gastrointestinal hemorrhage, cancer, hyperkalaemia, coagulopathies, hematological or neuro-muscular disorders, (4) hypersensitivity to non-steroidal anti-inflammatory drugs or local anesthetics agents, (5) preoperative abnormal cardiac, liver, or renal profile functions that had not been sufficiently optimized, (6) known psychiatric diagnosis and/or any other circumstances that would indicate that inclusion would not be in the best interest of the cohort or could prevent the protocol-specified evaluation of outcome, and (7) a physical or language barrier that might impede the patient's ability to understand the procedure, or patient refusal. A formula for simple random sampling for an infinite population was used for estimation of sample size and assumptions were considered based on a non-union rate of 5.3%, using a cerclage wire as reported by Panousis et al.⁷. Based on the results of a power analysis, at a 95% confidence interval (5% alpha; $\alpha=0.05$), 80% power and 0.04 absolute precision (marginal error), a study including a minimum of 121 patients was required.

Of 156 patients screened, 127 patients met the inclusion criteria and were recruited. There were 92 patients with fresh fractures (types AO type 31-A2.2 [n=37], A2.3 [n=31], and A3 [n=24]) and 35 patients with a failed intertrochanteric fracture (DHS [dynamic hip screw] [n=18], proximal femoral nail A2 [n=9], elastic titanium nail [n=2], Smith-Peterson nail plate [n=1], angle blade plate [n=2], and locking proximal femoral plate [n=3]). The flow chart for the study is shown in Fig. 1. Recording of clinico-demographic variables including age, sex, body mass index (BMI), comorbidity if any (co-morbidities such as hypertension,

obesity, diabetes, optimized states of renal/cardiac/liver/pulmonary co-morbidities), and American Society of Anesthesia score (ASA grade) was performed preoperatively (Table 1). Prior to the surgical intervention, infection was preoperatively dismissed in patients with concomitant medical conditions (such as urinary tract infection, cellulitis, abscess, etc., which are known to cause elevation of inflammatory markers) based on complete blood white cell count, total leukocyte count, erythrocyte sedimentation rate, and C-reactive protein levels. All surgeries were performed in lateral decubitus position under spinal anesthesia using a posterior lateral approach. A stay suture of piriformis and external rotators which can be sutured along with the capsule at the time of closure was used for routine exposure. The fractured trochanter fragments were left undetached as much as possible during the exposure. While incising the capsule caution was used in order to prevent damage to the labrum, an important stabilizer for prevention of dislocation, keeping the option open for performance of bipolar or total hip replacement. Patients with erosion of acetabular cartilage due to penetration of the implant underwent total hip arthroplasty. Selection of a stem was dependent upon available

bone stock and stability of the trial on the table. In cases involving an extension of the fracture in the subtrochanteric area our stem of choice was a solution stem (DePuy), which enables good distal fixation. A Summit stem and Corail Stem (DePuy) were used in cases where no major extension of the fracture was detected in the subtrochanteric area. With use of both stems, due to good modularity, we were able to place the full coating into the proximal canal rather than maintaining it for adjustment of the limb length, which will enable primary stability and provide the advantage of coating for ingrowth. The Corail stem was preferred when the canal was wider, which occurs more often in females. In addition, we have used wiring before reaming in the subtrochanteric area as a specific prophylactic measure in order to prevent an iatrogenic fracture. Assessment of range of motion, limb length, and stability was performed after implantation of the prosthesis. All patients had an uncemented implant. Assessment of limb length is always difficult in these groups of patients due to unavailable anatomical landmarks and/or distorted anatomy. We have used soft tissue tension, stability testing, and level of the knees. After reduction of the joint, meticulous reduction of fractured trochanteric

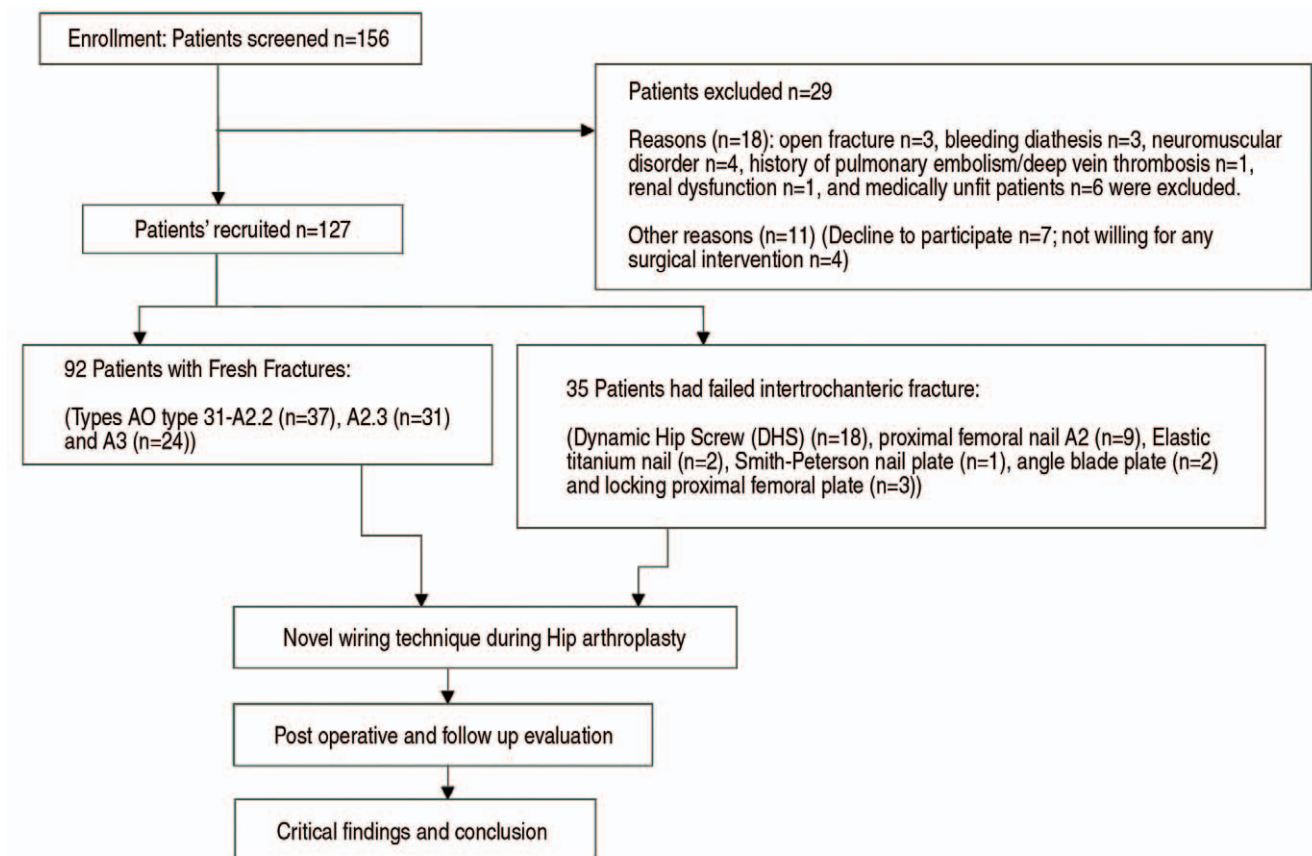


Fig. 1. Flow chart of the study design.

Table 1. Clinico-Demographic Variables

Variable	Unstable intertrochanteric fractures (n=92)	Failed intertrochanteric fracture (n=35)	P-value
Age (yr)	70.9±3.5	71.8±1.0	0.14
Sex, M:F	40:52	16:19	0.82
Body mass index (kg/m ²)	24.4±1.7	23.9±2.0	0.17
ASA grading			
1	34	12	0.77
2	47	15	0.40
3	9	7	0.12
4	2	1	0.82
Patient with two or more comorbidities	56 (60.9)	19 (54.3)	0.50
Follow-up (mo)	17.9±5.0	17.7±4.0	0.50
Etiology	AO/OTA classification	Modes of prior failure fixation	
	Types AO type 31-A2.2 (n=37), A2.3 (n=31), and A3 (n=24)	DHS (dynamic hip screw) (n=18), proximal femoral nail A2 (n=9), elastic titanium nail (n=2), Smith-Peterson nail plate (n=1), angle blade plate (n=2), and locking proximal femoral plate (n=3)	
Stem		Solution stem: 83 (65.4) Summit: 35 (27.6) Corail: 9 (7.1)	
Hemiarthroplasty /total hip arthroplasty		77 (60.6)/50 (39.4)	

Values are presented as mean±standard deviation, number only, or number (%).

M: male, F: female, ASA: American Society of Anesthesiologists.

fragments was performed and fixation was performed using the proposed multi-planar wiring technique. The operating limb was kept in abduction while maintaining the reduction and during wire tightening primarily in cases of a failed intertrochanteric fracture. This maneuver was helpful in confirming the reduction of the greater trochanteric fragment to the correct position. We have used pull through sutures for closure of the posterior rotators and capsular flap. The postoperative course was uneventful. Mobilization and guarded weight bearing was allowed according to the patient's tolerance. The patient was discharged on the sixth postoperative day. All patients followed a standard protocol for rehabilitation.

1. Novel Wiring Technique

The proposed technique involves three steps. First, a vertical wire loop configuration (AO 20-gauge) was used to anchor the trochanter, followed by insertion of two paral-

lel 1.5-mm Kirschner wires (K-wires) from the tip of the trochanter to the medial cortex and finally a figure-of-8 stainless steel (SS) loop wire (AO 20-gauge) was used to augment the fixation (Fig. 2-4). Two holes with a diameter of 1 mm were drilled unicortically over the lateral surface of the intact femoral cortex below the abductor tubercle with a distance of approximately 1 cm in between for the standard two separate parallel SS loop wires (Fig. 2). Wires were inserted through these holes and pulled out intramedullary prior to implantation of the prosthesis. There are two matters requiring consideration: first, sufficient wire length and strength to resist the tensile forces generated in tensioning, and second, the wires should be properly pulled/stretched out, allowing no loosening of intramedullary in order to avoid any mal-positioning or wire breakage during insertion of the prosthesis. After reduction of the joint these two wires are pulled out from the top of the trochanter, one anteriorly and the other posteriorly, as an inside-out approach through the wire passer in order

to avoid damage to the gluteus medius and tightened using an AO tension device (Fig. 3). These separate wires capture a large area on the surface of the trochanter and anchor the trochanter as vertical loops, preventing superior migration. Vertical wiring also provides even distribution of pressure over the base of the surface of the greater trochanteric fracture, which was not a feature of any of the previously described techniques. There are advantages with use of this vertical wire loop configuration. First, it prevents proximal migration of the trochanter and second, if one wire loop fails the second loop will hold until either union of the trochanter or some fibrous union is observed. In addition,

the trochanter is also subjected to greater rotational forces during movements. In consideration of this matter we require a rigid fixation for achievement of stability and union. Our technique additionally involves the use of two parallel 1.5 mm K-wires and a figure-of-8 SS loop wire in order to augment the standard two parallel SS wire technique (Fig. 4). Two parallel K-wires were inserted from the tip of the trochanter to the medial cortex of the proximal femur using an AO tension device, and a tension band principle figure-of-eight SS wire provides rigidity to the construct (Fig. 5). This tension band provides anterior, posterior, and rotational stability. Finally, stability can be achieved in three planes.

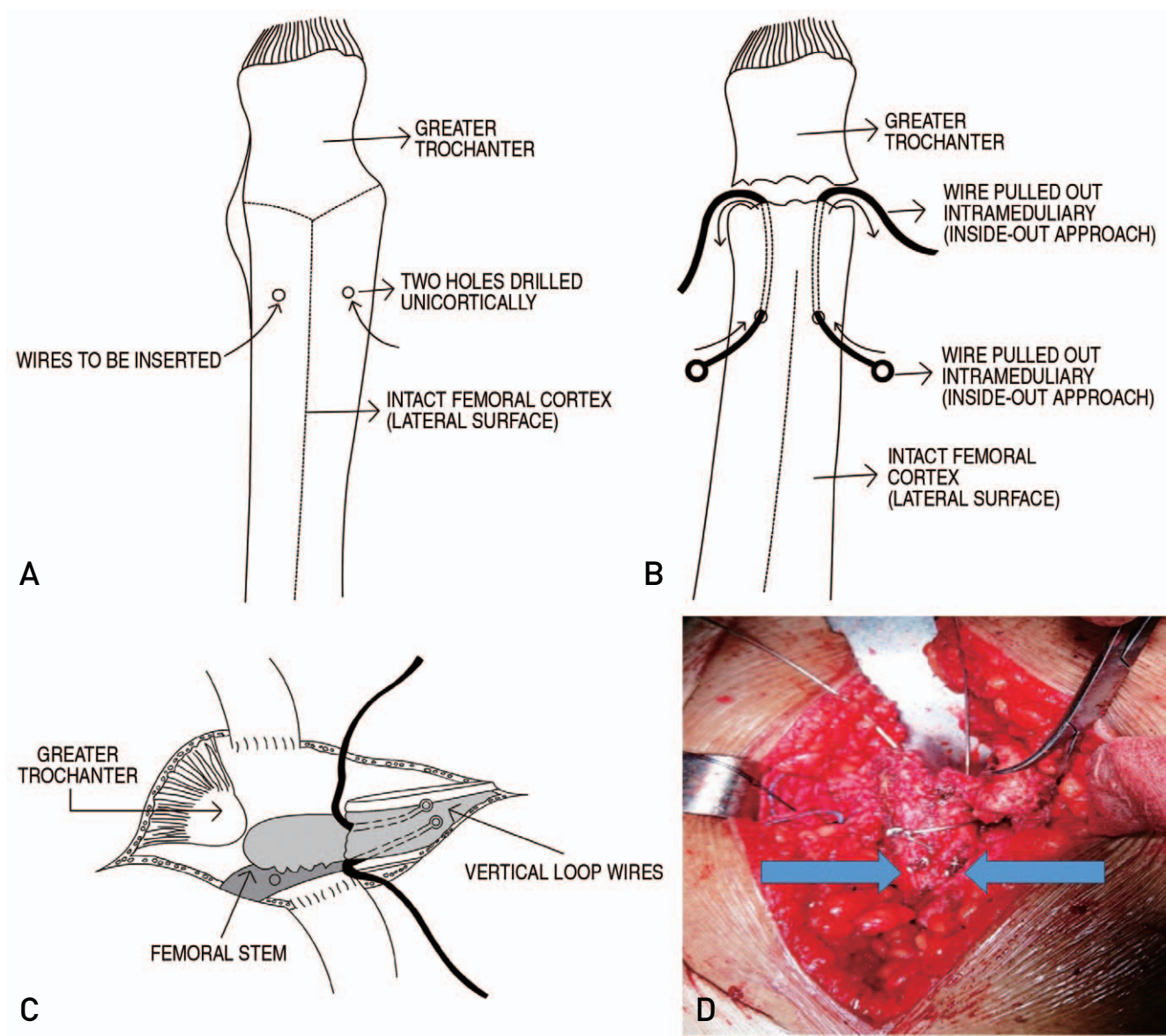


Fig. 2. Vertical loop wire insertion. (A-C) Schematic presentation: Two holes drilled over the lateral cortex, two intramedullary loop wires pulled out intramedullary. (D) Clinical intraoperative images of the vertical wire loop.

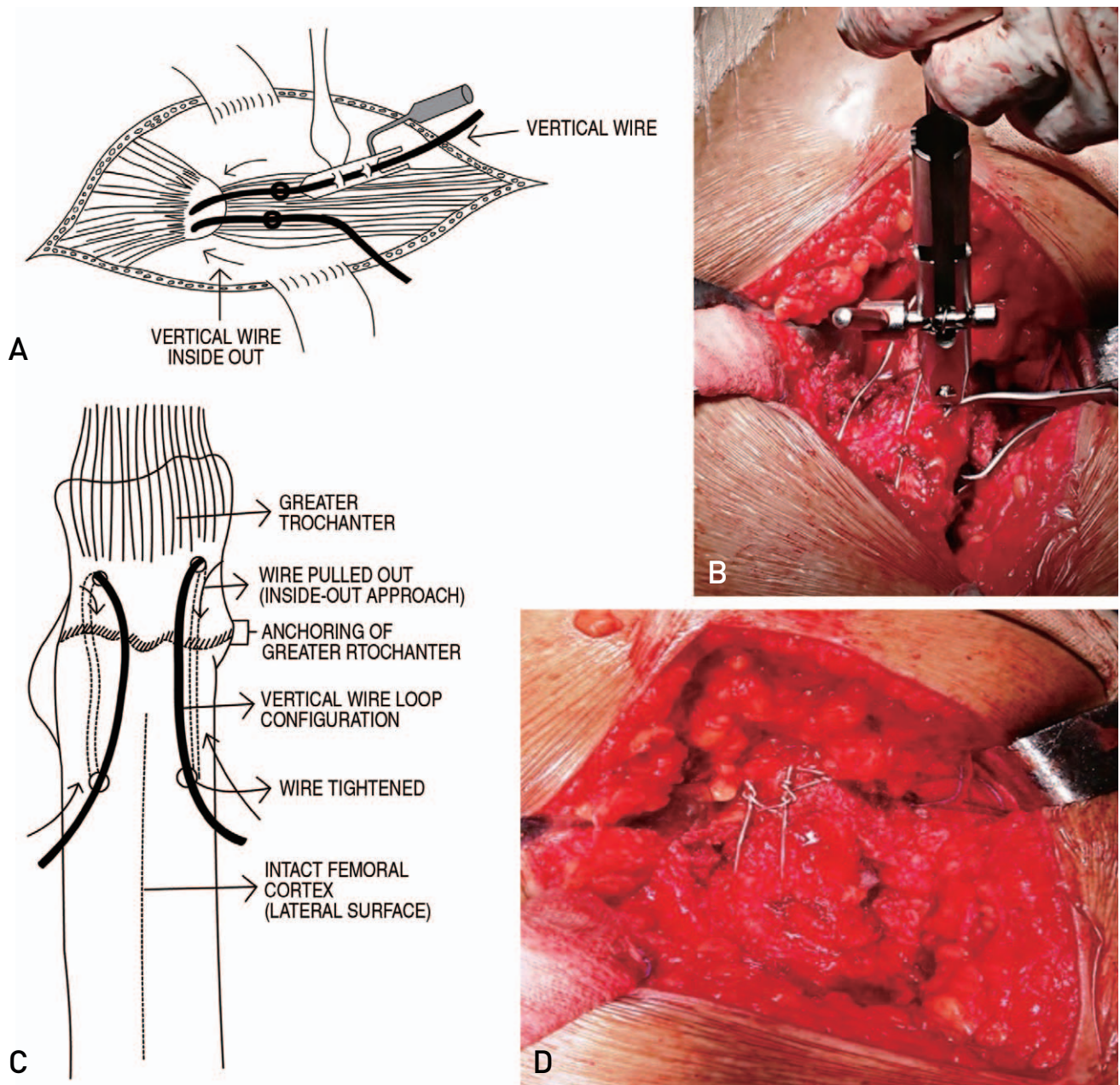


Fig. 3. (A) Schematic presentation: Tensioning of vertical wires loops after they were pulled out; inside-out approach. (B) Clinical intraoperative images of tensioning of vertical wires. (C) Schematic presentation: Vertical wires loops after tensioning. (D) Clinical intraoperative images of vertical wire loops.

Use of this combination can also be helpful in preventing loss of bone from the trochanteric fragment by increasing compression across the fracture of the greater trochanter (Fig. 6).

2. Outcome Measurement

All patients underwent routine clinical and radiological follow-up after surgery at three, six, and twelve months dur-

ing the first year and every six months thereafter. Evaluation of functional outcome: for clinical assessments, evaluation of the Harris hip score (HHS), the incidence of non-union, and complication of the wiring technique was performed at postoperative three, six, and 12 months and at the last follow-up. Evaluation of limb length discrepancy (LLD): “Direct” clinical measurement from the anterior superior iliac spine (ASIS) to the medial malleolus was performed using a tape measure for assessment of LLD during the fol-

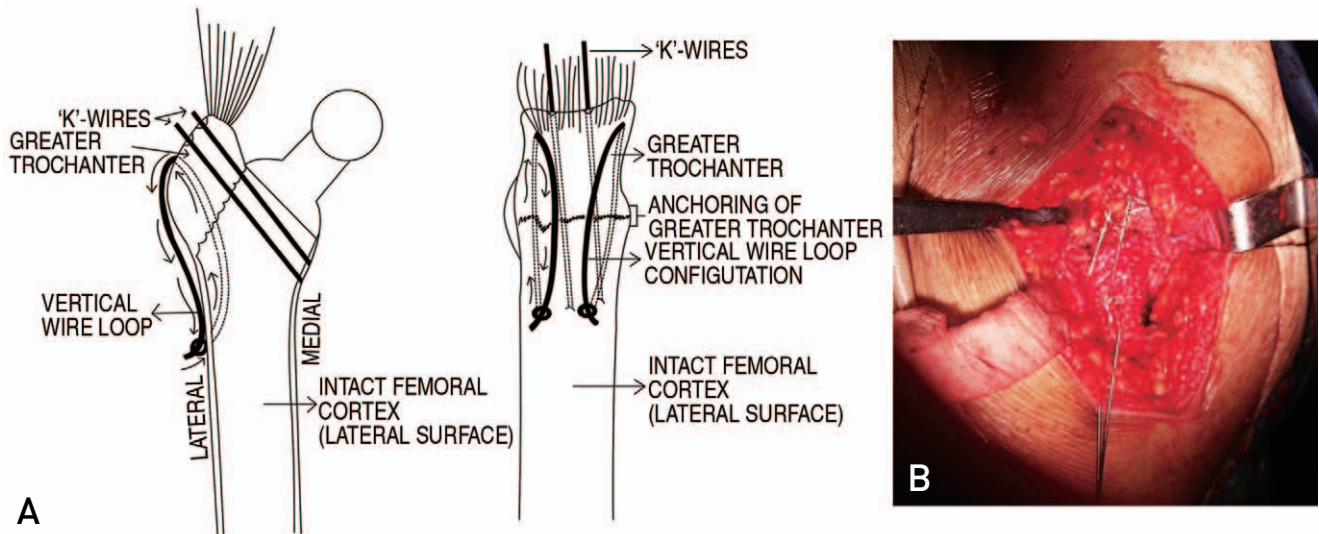


Fig. 4. (A) Schematic presentation: K-wire insertion and technique of the tension band principle (anteroposterior and lateral). (B) Intraoperative image.

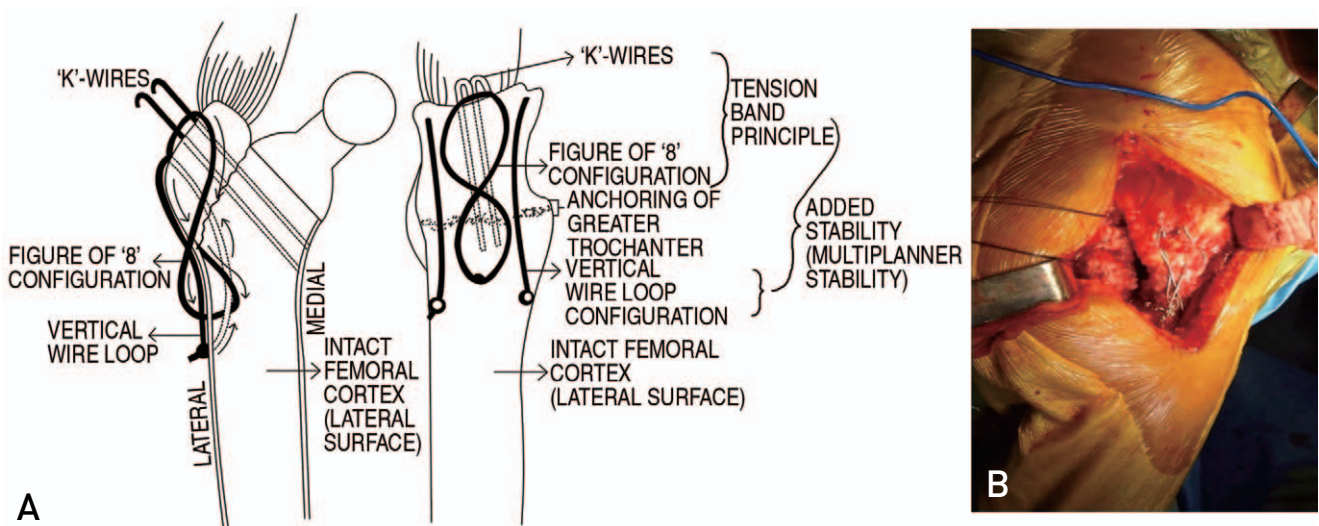


Fig. 5. Figure of 8-wiring. (A) Schematic presentation: Tensioning of figure of 8-wiring (anteroposterior and lateral). (B) Intraoperative image of figure of 8-wiring.

low-up period. Radiographic Evaluation included a standard anteroposterior pelvic radiograph obtained preoperatively and at the last follow-up visit, which was evaluated for union of the trochanter and any loosening and/or failure of the fixation wire loops. Healing was defined as continuity between the fragments of the trochanteric fracture and the adhesion site, as demonstrated by anteroposterior radiography of the hip. Fibrous union was defined as a distance of ≤ 1.5 cm and nonunion as >1.5 cm between the adhesion site and the trochanteric fragment after its proximal migration. Measurement of trochanteric migration was performed by comparing the

stem-to-tip distance in follow-up X-rays.

3. Statistical Analysis

Normally distributed data were computed for the cohort as mean \pm standard deviation or percentage. The chi-square test and Fisher's exact test were utilized for categorical variables and numerical variables, respectively. A Fisher's exact *P*-value was used in cases where the frequency was less than five. The chi-squared test was used to determine whether there is a significant difference between the expect-

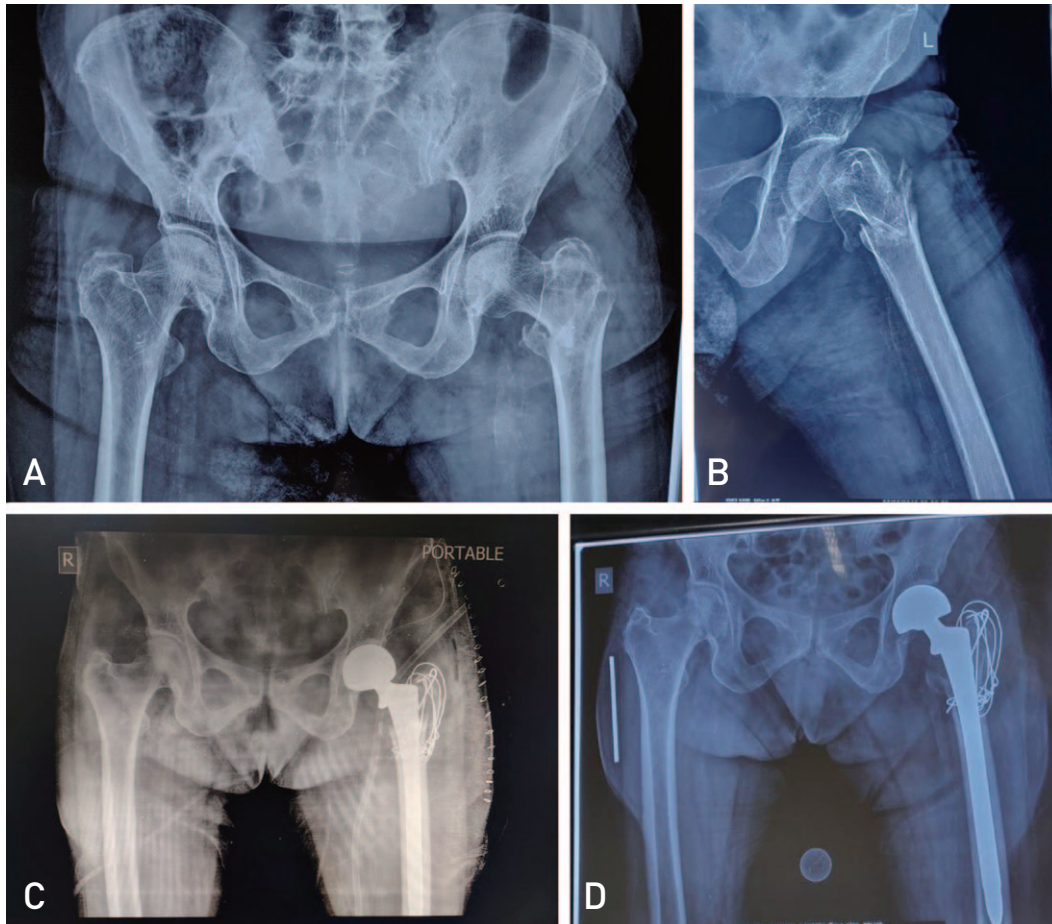


Fig. 6. (A, B) Preoperative X-rays. (A) Pelvis with both hips - anteroposterior view. (B) Hip with femur lateral view. (C) Immediate postoperative X-ray hip with femur. (D) Follow-up X-ray. Pelvis with both hips - anteroposterior view showing union of the trochanter.

ed frequencies and observed frequencies in one or more categories. Means were calculated. Unpaired Student *t*-tests were used for comparison of differences between two independent means. A $P < 0.05$ for two-tailed tests was considered significant. Analysis was performed using IBM SPSS Statistics for Windows software (ver. 22.0; IBM).

RESULTS

Prospective data were collected from all 127 patients who underwent primary arthroplasty using novel trochanteric wiring. The study included 71 female patients (55.9%) and 56 male patients (44.1%) with a mean age of 71.1 ± 3.0 years (range, 60-81 years). A total of 77 patients (60.6%) underwent hemi arthroplasty and 50 patients (39.4%) underwent total hip replacement depending on age, co-morbidity, and involvement of acetabular cartilage (Table 1).

The mean follow-up period was 17.8 ± 4.7 months (range,

12 to 24 months) and the minimum follow-up period was 12 months. No significant differences with regard to age ($P = 0.14$), sex ($P = 0.82$), BMI ($P = 0.17$), ASA grading ($P > 0.05$), and patients with co-morbidities ($P = 0.50$) were observed between the fresh and failed intertrochanteric fracture groups (Table 1). At the latest follow-up, the mean HHS showed significant improvement from 79.9 ± 1.8 (at three months) to 91.6 ± 5.1 ($P < 0.05$) (Table 2, Fig. 7). The mean HHS for the patients has shown gradual improvement with duration of follow-up from three months to the latest follow-up in the same age groups. However, no difference has been observed in different age groups. In addition, no difference in the HHS was observed between male and female patients ($P = 0.29$) (Table 2, Fig. 8, 9) and the difference between fresh and failed fractures was insignificant ($P = 0.08$) (Table 2, Fig. 10, 11).

Union was achieved for all cases of fractured trochanter (99.2%), except one (0.8%). The patient who developed non-

union had a history of trauma three months after the index surgery. Wire breakage was observed in three patients (2.4%); however, healing was not impaired and the trochanter was stable. This finding demonstrates that one of the systems remains intact and enables bone healing. Even with breakage of one vertical wire loop the other wire can hold the trochanter, which may encourage union.

Five patients (3.9%) had LLD. Two patients had a discrepancy of 1 cm, and three patients had a discrepancy of 0.5 cm. Three patients (2.4%) reported with a lurch. Wire related bursitis such as pain and swelling was reported in three patients

(2.4%). Two of these patients received conservative treatment and one of them required removal of hardware. There were no cases of dislocation or infection.

Radiographs showed stable prosthesis in situ without evidence of subsidence (Fig. 6). At the latest available follow-up all patients, except one, had returned to routine work and ambulated without use of walking aids. The patient who developed non-union walked with a lurch and does not want to undergo any further work up/surgical intervention.

Table 2. Postoperative HHS

Variable	3 mo	6 mo	12 mo	Last F/U
Sex				
Male	81.2±11.5	85.7±10.4	87.5±9.9	92.1±5.9
Female	79.8±6.0	83.8±7.6	85.8±7.5	91.1±5.1
P-value	0.37	0.23	0.27	0.29
P-value (3 mo/last F/U) (M/F)		<0.0001/<0.0001		
Etiology				
Unstable IT fractures	80.0±1.4	85.6±2.9	87.4±2.5	92.1±5.2
Failed IT fractures	79.7±2.6	84.8±1.6	86.6±2.9	90.4±4.5
P-value	0.40	0.12	0.13	0.08
P-value (3 mo/last F/U) (unstable/failed)		<0.0001/<0.0001		
Mean HHS	79.9±1.8	85.4±2.6	87.2±2.6	91.6±5.1
P-value (3 mo/last F/U)		<0.0001		

Values are presented as mean±standard deviation.

HHS: Harris hip score, F/U: follow-up, M: male, F: female, IT: intertrochanteric.

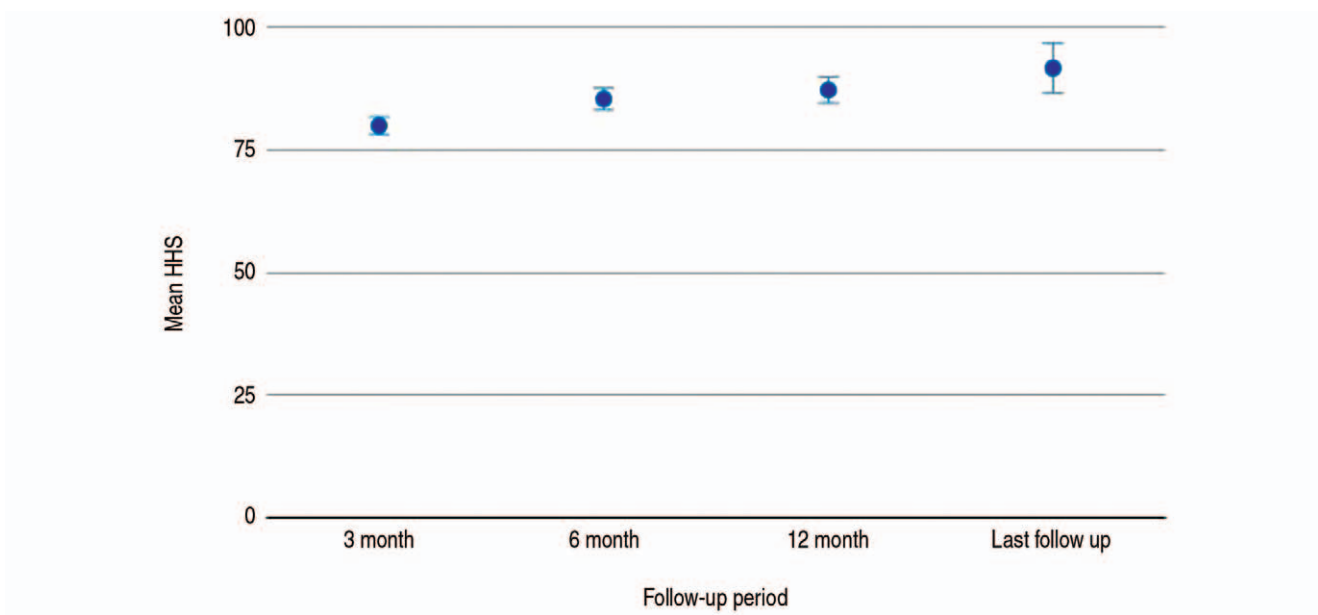


Fig. 7. Error bars showing the mean Harris hip score (HHS) of the patients: gradual improvement with duration of follow-up from three months to the latest follow-up.

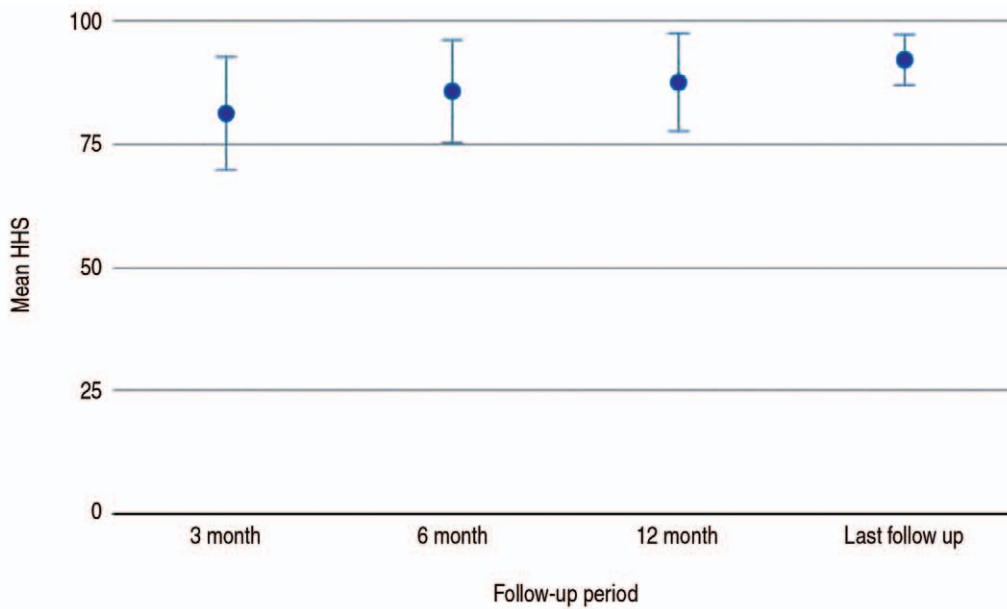


Fig. 8. Error bars showing the mean Harris hip score (HHS) of the male patients: gradual improvement with duration of follow-up from three months to the latest follow-up.

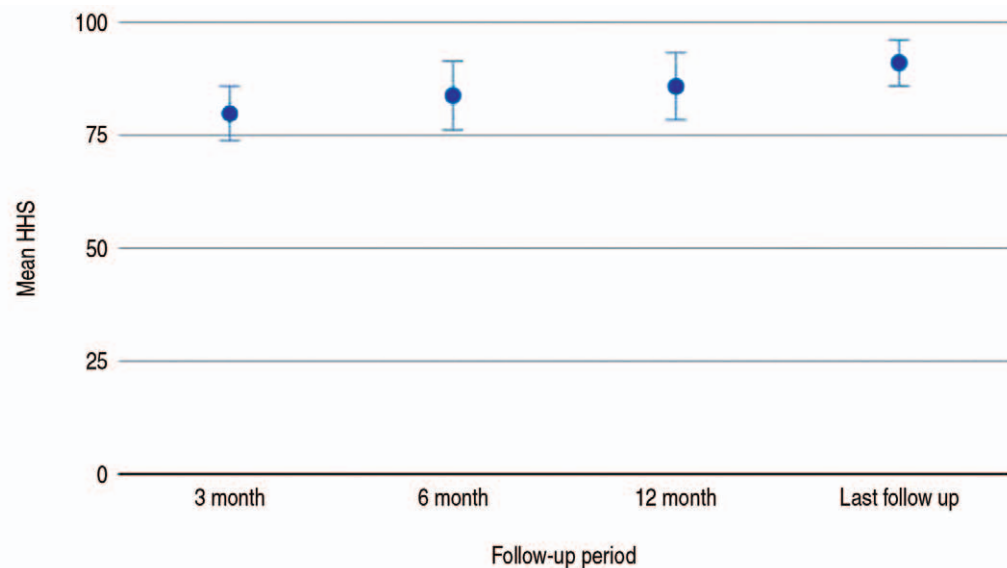


Fig. 9. Error bars showing the mean Harris hip score (HHS) of the female patients: gradual improvement with duration of follow-up from three months to the latest follow-up.

DISCUSSION

Weakness of abductor muscles due to displacement and non-union of the fractured trochanteric fragments following primary hip arthroplasty leads to a positive Trendelenburg's sign, walking discomfort, and periodic prosthetic instability⁸⁾. A proximal migration of the trochanteric fragment by more than 3 cm can lead to a significant reduction in the power of the abductor⁸⁾. The available literature also places

emphasis on preservation of abductor mechanics and the need for stable and rigid fixation of the trochanter. However, there is currently no consensus regarding the best fixation technique. The complications associated with available techniques include bursitis, impaired healing of the greater trochanter, breakage of wires and migration of the trochanter, resulting in substantial functional disability and a positive Trendelenburg sign⁶⁾.

Koyama et al.⁹⁾, who reattached an osteotomized fragment

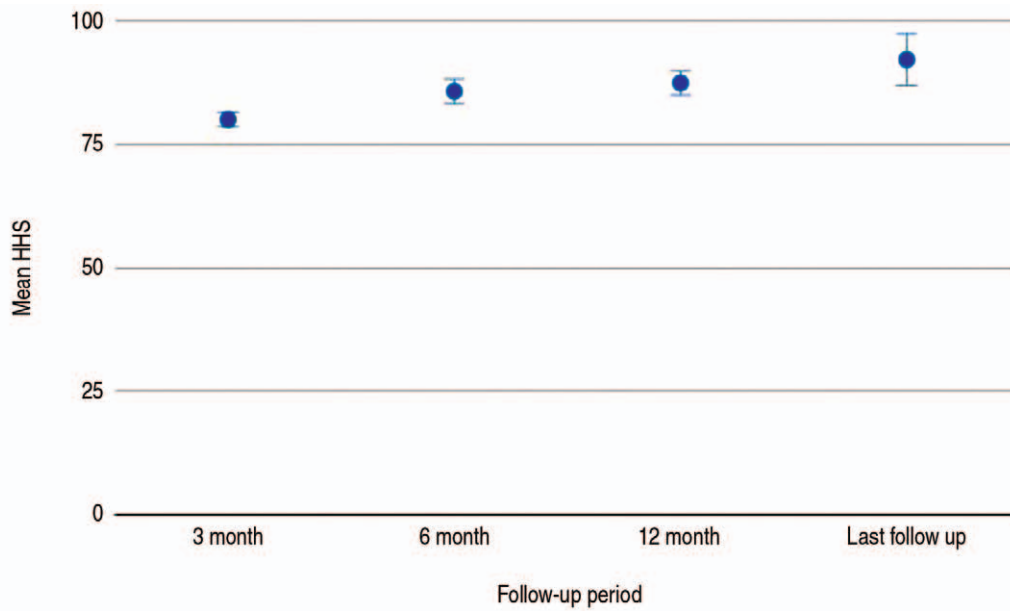


Fig. 10. Error bars showing the mean Harris hip score (HHS) of the patients with unstable intertrochanteric fractures: gradual improvement with duration of follow-up from three months to the latest follow-up.

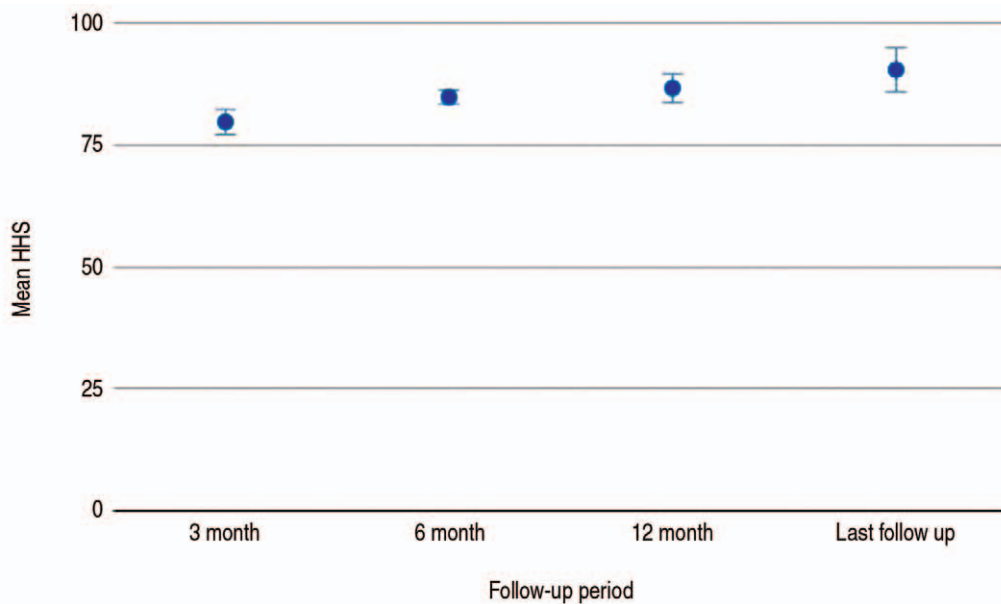


Fig. 11. Error bars showing the mean Harris hip score (HHS) of the patients with failed intertrochanteric fractures: gradual improvement with duration of follow-up from three months to the latest follow-up.

using a cable grip system, reported a non-union rate of 30.6% and other symptoms including tenderness and pain in 25.8% of patients. Likewise, a high rate of cable failure in the form of breakage, soft tissue irritation, and failed healing of the trochanter between 2.7% to 44% has been reported¹⁰⁾. A cable can provide stable fixation for relatively large fragments; however, its use is restricted in cases of poor bone stock and comminuted fractures. It is also expensive and is

frequently associated with symptoms of irritation. In addition, fragmentation of the cable can be a source of metallic debris, which can cause third body wear¹¹⁾. By contrast, the wiring technique is a cost-effective procedure associated with minimal damage to soft tissue. Also, because these wires can be customized into different shapes, it appears to be more suitable for fixation of different patterns of trochanteric fragments. Panousis et al.⁷⁾ reported a fibrous union rate of

7.1%, a non-union rate of 5.3%, and a wire breakage rate of 17.8% with use of a cerclage wire. Several other scholars have reported non-union rates ranging from 2.9% to 18.9% using different techniques (Table 3)^{10,12-14}. These authors reported that non-union and/or proximal migration usually occurs in cases where rupture of the wires occurs early in the follow-up period before union of the trochanter with the intact femur. This leads to pain, lurch, and periodic adduction contracture¹⁵. Contrary to the literature findings described above, the results of our study showed a low non-union rate of 0.8% (Table 3). This can be attributed to the rigid multi-planar stability provided by the proposed technique for maintenance of adequate compression on the surface of the fracture and prevention of the proximal migration of the trochanteric fragment.

Suh et al.¹⁶, who evaluated three different systems of fixation in terms of proximal migration reported a rate of 22.2% with use of figure of 8-wiring, 52.2% with use of cerclage wiring, and 9.1% with use of tension band wiring and concluded that the tension band wiring method was the optimal approach for fixation of trochanteric fragments in patients undergoing hip arthroplasty. In our study frank non-union occurred in only one patient who had migration greater than 2 cm. In the current series, breakage of the wires holding the trochanteric fragments was observed in 2.4% of patients; however, no migration of the trochanter was observed. Wire breakage is usually encountered after union of the trochanter has been achieved and any symptoms are probably caused by cyclic stress on the wires over time¹⁷. In our study, 2.4% of the patients complained of wire-related bursitis such as swelling or pain, which was thought to be a result of wire breakage and lean muscle mass.

The concept of biomechanical superiority of locking plates over other available systems in resisting forces acting over the trochanter still requires scientific confirmation. In addition, remaining challenges include postoperative trochanteric

pain, hardware complications, and revision surgery for management of hardware-related issues, limited flexibility for a customized shape, increased operative time, placement of screws, and cost¹⁸. The emergence of non-absorbable ethi-bond sutures/cable effectively resolves the complications of metal hardware. A union rate of 74.4% has been reported with use of these sutures¹⁹. Inadequate compressions at the fracture sites was the primary concern associated with use of these non-absorbable sutures.

Compared with other systems of fixation, the wiring technology provides low resistance to fatigue and breaking strength²⁰. In addition, because there were differences in the pattern of fractures of trochanteric fragments and stability, a single system/configuration for holding the fragments was inadequate to support a favorable outcome²¹. A successful approach must include application of adequate compression at the fracture sites. It must also withstand both vertical displacement and rotatory forces in the anteroposterior plane provided by the abductor musculature with the hip in flexion^{22,23}.

Cho et al.²⁴ performed surgery on 86 patients for treatment of unstable intertrochanteric fracture using standard cemented bipolar arthroplasty and trochanteric stabilization was performed using a double loop with tension band wiring. They reported on four patients with substantial displacement of the greater trochanter. The mean HHS was 79.2 at the final follow-up. Jayapalan et al.²⁵ reported on a prospective evaluation of the functional outcome of patients with unstable intertrochanteric fractures who were treated with primary cemented bipolar arthroplasty with trochanteric reconstruction using tension band wiring. The mean HHS was 85.6 ± 9.5 (range, 74-96) at the end of one-year follow-up. Their report did not mention union of the trochanteric fragment. In 2017, Sun et al.²⁶, who reported on a study evaluating the efficacy of different methods for fixation of the greater trochanter fracture fragment in patients with unstable intertrochanteric fractures undergoing hip arthroplasty, observed improvements in HHS from 74.8 to 85.7 points at the latest follow-up. Our study using HHS showed a better functional outcome (Table 4). This result indicated that

Table 3. Comparison of Percentage of Trochanteric Non-Union of Various Studies

Study	Total No. of patients	Trochanteric non-union
Kim et al. ¹⁴	21	2 (9.5)
McCarthy et al. ¹⁰	204	19 (9.3)
Ozan et al. ¹³	32	6 (18.8)
Lee et al. ¹²	69*	2 (2.9)
This study	127	1 (0.8)

Values are presented as number (%).

*Number of hips.

Table 4. Comparison of Mean HHS of Various Studies

Study	No. of patients	HHS
Cho et al. ²⁴	86	79.2
Jayapalan et al. ²⁵	30	85.6
Sun et al. ²⁶	63	85.7
This study	127	91.6

HHS: Harris hip score.

use of the proposed wiring technique resulted in restoration of the abductor and hip joint function for the unstable and failed intertrochanteric fractures, leading to improvement of the score for functional activities of the hip as well as quality of life.

The strength of our proposed technique is that it can enable a multi-planar stable fixation of trochanteric fragments and preservation of the hip abductor mechanism, because there was no disruption of soft-tissue attachments to the fractured fragments and wires were passed through a wire passer. In addition, use of this technique enables repositioning of the trochanter at the desired position, namely distalization and anterior or posterior position to avoid any impingement. This technique can also be used in cases where there is no calcar to support horizontal wiring as advocated by Charnley²⁷⁾. The majority of patients experienced relief from pain with no weakness of the abductor, indicating that use of the proposed intertrochanteric wiring technique resulted in restoration of the abductor lever mechanism for both fresh intertrochanteric fracture and failure of fracture fixation during primary arthroplasty, leading to an improved score for functional activities of the hip. Even in cases of poor bone stock, this system provided stable fixation; however, caution is required at the time of reconstruction. When excessive force is applied using a tension device there is a risk of cutting through the bone, resulting in failure of fixation. None of the patients suffered joint infection, peri-prosthetic fracture, prosthesis dislocation, deep vein thrombosis, or other complications following surgery. Posterior capsular repair using pull through sutures and trochanteric stabilization is the key to success in avoiding dislocation. There are some potential limitations to our study. First, although there was no control group, we have compared our results with available literature and found that they are significant. Second, our study had a short follow-up period. Conduct of a large randomized controlled study with a long follow-up period will be required in order to validate our observations.

CONCLUSION

The findings of our study demonstrated that the modified multi-planar wiring technique for fixation of trochanteric fracture fragments following primary hip arthroplasty can be helpful in restoring the abductor mechanism, resulting in minimal postoperative complications. Minimal soft tissue damage, biomechanically superior construct, ease of surgical technique, and perceived improved outcomes were the other factors associated with the cost effectiveness of

the current technique. Stability in all planes is regarded as a success, which is the principle of AO for fixation of any fracture, and this is more elastic due to the tension band principle. The added stability in different planes results in more rapid rehabilitation and excellent clinico-radiological outcomes.

FUNDING

No funding to declare.

ACKNOWLEDGEMENTS

We acknowledge all of the patients who participated in the study, nursing staff, and paramedical staff. We also acknowledge the contribution of the entire research team.

CONFLICT OF INTEREST

The author declares that there is no potential conflict of interest relevant to this article.

REFERENCES

1. Fan L, Dang X, Wang K. *Comparison between bipolar hemiarthroplasty and total hip arthroplasty for unstable intertrochanteric fractures in elderly osteoporotic patients.* *PLoS One.* 2012;7:e39531. <https://doi.org/10.1371/journal.pone.0039531>
2. Celiktas M, Togrul E, Kose O. *Calcar preservation arthroplasty for unstable intertrochanteric femoral fractures in elderly.* *Clin Orthop Surg.* 2015;7:436-42. <https://doi.org/10.4055/cios.2015.7.4.436>
3. Abdelkhalik M, Ali AM, Abdelwahab M. *Cemented bipolar hemiarthroplasty with a cerclage cable technique for unstable intertrochanteric hip fractures in elderly patients.* *Eur J Orthop Surg Traumatol.* 2013;23:443-8. <https://doi.org/10.1007/s00590-012-1006-z>
4. Kim Y, Moon JK, Hwang KT, Choi IY, Kim YH. *Cementless bipolar hemiarthroplasty for unstable intertrochanteric fractures in octogenarians.* *Acta Orthop Traumatol Turc.* 2014;48:424-30. <https://doi.org/10.3944/AOTT.2014.13.0119>
5. Grimsrud C, Monzon RJ, Richman J, Ries MD. *Cemented hip arthroplasty with a novel cerclage cable technique for unstable intertrochanteric hip fractures.* *J Arthroplasty.* 2005;20:337-43. <https://doi.org/10.1016/j.arth.2004.04.017>
6. Frankel A, Booth RE Jr, Balderston RA, Cohn J, Rothman RH. *Complications of trochanteric osteotomy. Long-term implications.* *Clin Orthop Relat Res.* 1993;(288):209-13. <https://doi.org/10.1097/00003086-199303000-00027>
7. Panousis KT, Tsifetakis SD, Orfanos J, Giannoulis P, Pilichos J, Papagelopoulos PJ. *Fixation of Chevron trochanteric osteotomy with two wire loops in isolated acetabular component revision.* *Orthopedics.* 2004;27:1236-9. <https://doi.org/10.3928/0147->

- 7447-20041201-10
8. Nutton RW, Checketts RG. *The effects of trochanteric osteotomy on abductor power. J Bone Joint Surg Br.* 1984;66:180-3. <https://doi.org/10.1302/0301-620X.66B2.6707052>
 9. Koyama K, Higuchi F, Kubo M, Okawa T, Inoue A. *Reattachment of the greater trochanter using the Dall-Miles cable grip system in revision hip arthroplasty. J Orthop Sci.* 2001;6:22-7. <https://doi.org/10.1007/s007760170020>
 10. McCarthy JC, Bono JV, Turner RH, Kremchek T, Lee J. *The outcome of trochanteric reattachment in revision total hip arthroplasty with a Cable Grip System: mean 6-year follow-up. J Arthroplasty.* 1999;14:810-4. [https://doi.org/10.1016/s0883-5403\(99\)90030-x](https://doi.org/10.1016/s0883-5403(99)90030-x)
 11. Silverton CD, Jacobs JJ, Rosenberg AG, Kull L, Conley A, Galante JO. *Complications of a cable grip system. J Arthroplasty.* 1996;11:400-4. [https://doi.org/10.1016/s0883-5403\(96\)80029-5](https://doi.org/10.1016/s0883-5403(96)80029-5)
 12. Lee JM, Cho Y, Kim J, Kim DW. *Wiring techniques for the fixation of trochanteric fragments during bipolar hemiarthroplasty for femoral intertrochanteric fracture: clinical study and technical note. Hip Pelvis.* 2017;29:44-53. <https://doi.org/10.5371/hp.2017.29.1.44>
 13. Ozan F, Koyuncu S, Pekedis M, Altay T, Yildiz H, Toker G. *Greater trochanteric fixation using a cable system for partial hip arthroplasty: a clinical and finite element analysis. Biomed Res Int.* 2014;2014:931537. <https://doi.org/10.1155/2014/931537>
 14. Kim WY, Shin ES, Moon CY. *Modified double tension band wiring for reattaching the greater trochanter when performing hemiarthroplasty for intertrochanteric fracture in elderly patients. J Korean Hip Soc.* 2009;21:257-62. <https://doi.org/10.5371/jkhs.2009.21.3.257>
 15. Lazansky MG. *Complications in total hip replacement with the Charnley technic. Clin Orthop Relat Res.* 1970;72:40-5.
 16. Suh YS, Choi SW, Park JS, Yim SJ, Shin BJ. *Comparison between the methods for fixation of greater trochanteric fragment in cemented bipolar hemiarthroplasty for unstable intertrochanteric fracture. J Korean Hip Soc.* 2008;20:104-9. <https://doi.org/10.5371/jkhs.2008.20.2.104>
 17. Amstutz HC. *Complications of total hip replacement. Clin Orthop Relat Res.* 1970;72:123-37.
 18. Tetreault AK, McGrory BJ. *Use of locking plates for fixation of the greater trochanter in patients with hip replacement. Arthroplast Today.* 2016;2:187-92. <https://doi.org/10.1016/j.artd.2016.09.006>
 19. Lee KH, Lee DH, Noh JH, Kim YV. *Is rigid fixation of the greater trochanter necessary for arthroplasty of intertrochanteric fractures? Orthop Traumatol Surg Res.* 2019;105:41-5. <https://doi.org/10.1016/j.otsr.2018.09.015>
 20. Shaw JA, Daubert HB. *Compression capability of cerclage fixation systems. A biomechanical study. Orthopedics.* 1988;11:1169-74. <https://doi.org/10.3928/0147-7447-19880801-08>
 21. Choi DH, Heo JY, Jang YJ, Chung YY. *Fixation of the greater trochanter in arthroplasty for unstable intertrochanteric fracture. J Korean Fract Soc.* 2014;27:58-64. <https://doi.org/10.12671/jkfs.2014.27.1.58>
 22. Paul JP, McGrouther DA. *Forces transmitted at the hip and knee joint of normal and disabled persons during a range of activities. Acta Orthop Belg.* 1975;41 Suppl 1:78-88.
 23. Silverton CD, Rosenberg AG. *Management of the trochanter. In: Callaghan JJ, Rosenberg AG, Rubash HE, ed. The adult hip. Lippincott-Raven; 1998. 1269-94.*
 24. Cho HM, Lee SR, Park MS, Chung WC. *Standard type cemented hemiarthroplasty with double loop and tension band wiring for unstable intertrochanteric fractures in the elderly. J Korean Hip Soc.* 2010;22:159-65. <https://doi.org/10.5371/jkhs.2010.22.2.159>
 25. Jayapalan JK, Pandian P, Pandian A, Rajendiran C, Duraisamy V. *Unstable intertrochanteric fracture in elderly treated with cemented bipolar hemiarthroplasty and trochanteric reconstruction. J Evid Based Med Healthc.* 2015;2:3905-13.
 26. Sun D, Park BS, Jang GI, Lee B. *The fixation method according to the fracture type of the greater trochanter in unstable intertrochanteric fractures undergoing arthroplasty. Hip Pelvis.* 2017;29:62-7. <https://doi.org/10.5371/hp.2017.29.1.62>
 27. Charnley J. *Total hip replacement by low-friction arthroplasty. Clin Orthop Relat Res.* 1970;72:7-21.