



# Total Hip Arthroplasty with Cemented Dual Mobility Cup into a Fully Porous Multihole Cup with Variable Angle Locking Screws for Acetabular Fractures in the Frail Elderly

Mathias van den Broek, MD, Kris Govaers, MD, PhD

*Department of Orthopaedic Surgery, az Sint-Blasius, Dendermonde, Belgium*

**Purpose:** The purpose was to examine the clinical and radiological outcomes after surgical treatment of acetabular fractures with total hip arthroplasty with a dual mobility cup cemented into a porous multihole cup in the population of frail elderly patients.

**Materials and Methods:** A retrospective review of 16 patients who underwent surgery (mean age, 76.7 years) with a mean follow-up period of 36.9 months was conducted. Following surgery, patients underwent postoperative follow-up at six weeks, three, six, and 12 months and clinical and radiological examinations were performed.

**Results:** Classification of fractures was based on the Letournel classification. Following surgery, all patients were allowed weight-bearing as tolerated immediately postoperative. Fourteen patients showed maintenance of preoperative mobility status at one year. The mean Harris hip score was 64.8 (range, 34.7-82.8) and 80.0 (range, 60.8-93.8) at three months and one year, respectively. The mortality rate was 12.5% at one year (2/16). Complications included heterotopic ossification (2/16), deep venous thrombosis (1/16), hematoma (1/16), and femoral revision due to a Vancouver B2 fracture (1/16). No case of deep infection, dislocation, or implant loosening was reported.

**Conclusion:** Total hip arthroplasty using a dual mobility cup cemented into a porous multihole cup with locking screws resulted in a stable construct with a capacity for immediate weight-bearing as tolerated with rapid relief of pain. The findings of this study suggest that this procedure can be regarded as a safe method that has shown promising clinical and radiological outcomes for treatment of patients with medical frailty.

**Key Words:** Arthroplasty, Acetabulum, Fractures, Frailty

**Submitted:** September 18, 2022 **1st revision:** October 19, 2022

**Final acceptance:** November 25, 2022

**Address reprint request to**

**Mathias van den Broek, MD**

(<https://orcid.org/0000-0002-1403-7600>)

Department of Orthopaedic Surgery, az Sint-Blasius, Kroonveldlaan

50, 9200 Dendermonde, Belgium

**TEL:** +32-52252607 **FAX:** +32-52252115

**E-mail:** [mathias.vandenbroek@azsintblasius.be](mailto:mathias.vandenbroek@azsintblasius.be)

This is an Open Access article distributed under the terms of the Creative Commons Attribution Non-Commercial License (<http://creativecommons.org/licenses/by-nc/4.0>) which permits unrestricted non-commercial use, distribution, and reproduction in any medium, provided the original work is properly cited.

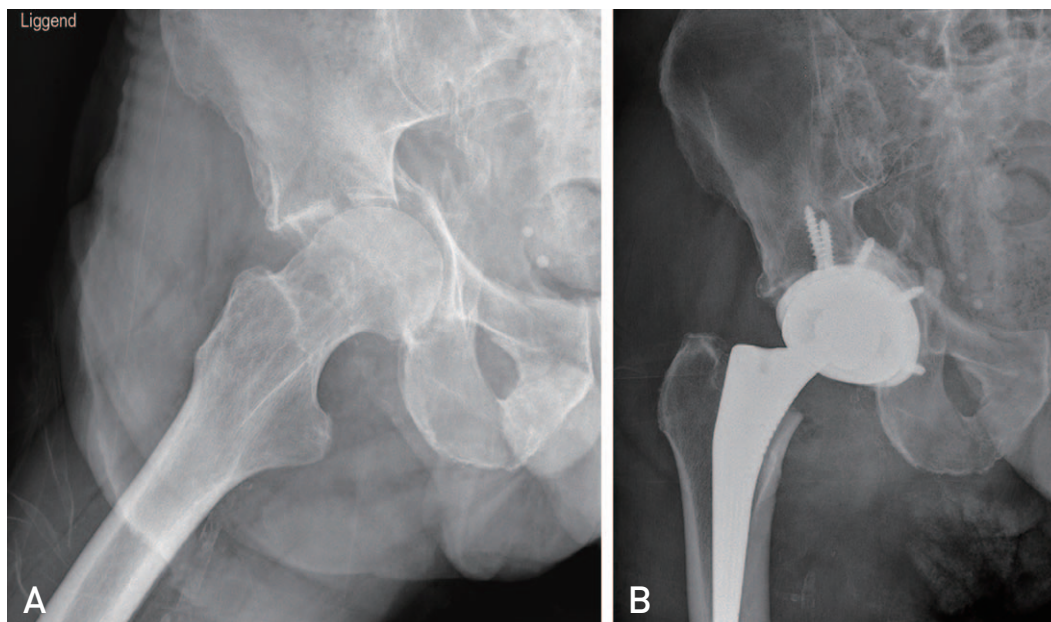
## INTRODUCTION

The aging population and a more active life-style among the elderly has led to increased incidence of osteoporotic fractures in recent decades<sup>1</sup>. A 2.4-fold increase in the incidence of acetabular fractures in patients over the age of 60 has been reported<sup>2</sup>. Although acetabular fractures in the elderly are typically a result of low-energy trauma, these fractures can have a complex appearance due to the quality of osteoporotic bone. Due to complicating factors such as medical co-morbidities and a degenerative joint there is still controversy regarding the optimal treatment for patients in the elderly population. Goals of treatment should include relief of pain, rapid mobilization, and a return to independent performance of daily activities. Traditional conservative treatment offered to such frail patients showed poor results, due to the long period of immobilization and inactivity<sup>3</sup>. However, a study conducted by Magu et al.<sup>4</sup> reported good functional and radiological outcomes after non-operative treatment and a recent study reported that no difference in mortality rate was observed between operative and nonoperative treatment<sup>5</sup>. Options for surgical treatment include percutaneous screw osteosyntheses for minimally displaced fractures<sup>6</sup>, open reduction and internal fixation (ORIF) or total hip arthroplasty (THA). Surgical performance of ORIF is difficult due to use of extended approaches, fracture comminution, and poor bone quality, and the outcomes

have been associated with a high risk for failure of fixation and development of posttraumatic arthritis<sup>7</sup>, requiring subsequent THA, and suboptimal outcome and results have been reported<sup>8</sup>. Acute THA is a feasible alternative for treatment of acetabular fractures in older patients and acceptable clinical outcomes and survivorship rates have been reported in several studies<sup>9-14</sup>. Complications including heterotopic ossification (HO), dislocation, and venous thromboembolic event have been reported in 0% to 60% of cases<sup>9-14</sup>.

Age is a well-documented risk factor for dislocation after THA<sup>15,16</sup> and dual mobility (DM) components have been utilized in an effort to reduce this risk of complication. The benefits of DM components, as well as lower rates of dislocation after THA<sup>17,18</sup> and even revision THA<sup>19</sup>, resulting from an increased head-to-neck ratio, greater jump distance, and greater range of motion (ROM)<sup>20</sup> have been demonstrated. More recently, the safety of cementing DM components into a well preserved stable acetabular cup has been demonstrated in revision settings such as recurrent dislocations or bone loss<sup>21-23</sup>.

The purpose of this study was to report on the clinical, radiological, and functional outcomes for 16 patients who underwent THA using a DM cup cemented into a porous multihole cup for treatment of complex acetabular fractures. In our opinion, use of a DM construct is beneficial in treatment of this type of fracture in this population due to the reduced risk of dislocation.



**Fig. 1.** (A) Preoperative anteroposterior radiograph of the right pelvis shows a pure transverse acetabular fracture. (B) Postoperative radiograph shows the dual mobility cup cemented into a multihole cup fixed with multiple angle locking screws into ilium, ischium, and pubis.

**MATERIALS AND METHODS**

A total of 16 patients (mean age, 76.7 years) who underwent operative treatment for a displaced acetabular fracture from July 2016 to December 2019 at az Sint-Blasius were included in the study. Radiographs (Fig. 1A) and a computed tomography scan were performed for evaluation of the fracture pattern and classification of fractures was based on the Letournel classification<sup>24</sup>. The American Society of Anesthesiologists (ASA) score was used in describing the patients' preoperative physiological status. Patients with cognitive dysfunction or bedbound patients were excluded. Ethical approval was obtained for this study at the Institutional Review Board of az Sint-Blasius (No. B0122022000001) and the written informed consent was obtained from all patients.

**1. Demographics**

The mean age of the patients (n=16) was 76.7 years (range, 59-91 years) and the mean ASA score was 2.9 (range, 2-4). Fourteen patients sustained a low energy fall. Pre-injury, 11 patients were able to walk without aid, four patients had

a walking frame, and one patient used one crutch. The mean operative time was 123.3 minutes (range, 95-148 minutes) and the mean length of stay was 9.9 days (range, 5-19 days) (Table 1). Traction was applied in eight patients prior to definitive surgery; skeletal traction was applied in five patients and skin traction in three patients. The mean time prior to this definitive surgery was 3.1 days (range, 0-9 days). The mean follow-up period was 36.9 months.

**1) Radiographic evaluation**

All patients sustained a comminuted, complex acetabular fracture. Ten fractures showed displacement less than 2 mm, and six fractures showed displacement of 2 mm or more. All fractures were classified as associated fractures according to Letournel's classification system; six T-type fractures, six transverse fractures, three anterior column posterior hemitransverse fractures, and one both column fracture.

**2. Surgical Procedure**

Preoperative optimization of patients was conducted by an anaesthetic medical team and all patients underwent a cardiac ultrasound examination for assessment of their car-

**Table 1.** Study Layout

Patient No.	Sex	Age (yr)	FU (mo)	ASA	OTA fracture classification	Length of stay (day)	Walking aid pre-injury	HHS		Complication
								3 mo	1 yr	
1	F	85	5	4	62B2.2	13	-	45.6	-	HO
2	M	77	48	3	62B2.2	14	-	71.7	83.8	-
3	F	75	66	3	62B1.1	19	-	67.8	83.6	-
4	M	70	27	3	62B1.1	10	1 crutch	53.4	60.8	PP fracture
5	M	74	50	2	62C2.1	14	-	75.8	93.8	-
6	M	67	54	3	62B2.2	13	-	60.8	62.8	-
7	F	91	45	3	62B2.2	8	Walking frame	57.8	71.8	-
8	M	59	33	2	62C2.2	5	-	75.8	87.8	-
9	F	64	66	2	62C2.2	7	-	80.8	89.8	-
10	M	73	32	3	62B1.1	14	Walking frame	70.8	73.8	HO
11	F	80	28	3	62B1.1	7	-	75.8	87.8	Hematoma
12	F	74	49	3	62B2.2	10	-	82.8	83.8	-
13	F	85	36	3	62B2.2	5	-	65.8	82.8	-
14	F	88	4	3	62C2.2	9	Walking frame	34.7	-	-
15	F	79	33	3	62B1.1	5	-	74.7	90.7	DVT
16	F	86	15	3	62B1.1	6	Walking frame	43.3	66.3	-
Total		76.7	36.9	2.9		9.9		64.8	80.0	

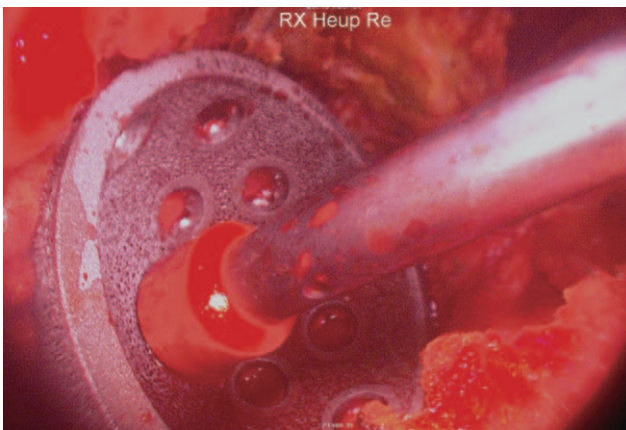
F: female, M: male, FU: follow-up, ASA: American Society of Anesthesiologists, OTA: Orthopaedic Trauma Association, HHS: Harris hip score, HO: heterotopic ossification, PP: periprosthetic, DVT: deep venous thrombosis.

biological status. Pre- and postoperative management of patients was administered daily by a multidisciplinary orthogeriatric team. Preoperative skin or skeletal traction was applied at the discretion of the on-call consultant on the day of injury. All procedures were performed under general anaesthesia; antibiotic prophylaxis included intravenous administration of 1.5 g of cefuroxime, which was repeated two times postoperatively. Tranexamic acid (1 g) was administered to patients at induction. All patients underwent surgery in lateral decubitus position using a posterolateral approach. Release of the gluteus maximus at its femoral insertion was performed in order to reduce stress on the fractured acetabulum caused by the retractors. After resection of the femoral neck, examination and evaluation of the acetabular fracture was performed. Reduction of the fracture was not attempted in cases of undisplaced comminution. In cases involving fracture displacement of 2 mm or more, the fracture was reduced by positioning a reduction clamp over the acetabulum. Sequential reaming was performed along with use of a curette for removal of acetabular cartilage. Adjustment and fixation of a multihole, fully porous acetabular cup (REDAPT; Smith & Nephew, Memphis, TN, USA) to the pelvis into the ilium, pubis, and ischium was performed using 4-9 locking screws, with avoidance of danger zones as described by Wasielewski et al.<sup>25)</sup> (Fig. 2). Optimal fixation and stability were achieved. Cement, including 1.2 g of Gentamycin was pressurized into the cup and an additional DM cup (POLARCUP; Smith & Nephew) was cemented into the socket in the precise version and inclination (Fig. 3). The cup size was 3-5 mm smaller than the inner shell in order to obtain an acceptable cement mantle. A cemented femoral component was used in nine cases. Following performance of stability testing and assessment


of the appropriate leg length, reattachment of the gluteus maximus tendon was performed using resorbable sutures and a routine closure was performed with repair of the external rotators, tensor fascia lata, and subcutaneous and cutaneous tissues. Low-molecular weight heparin and anti-embolic stockings were administered postoperatively as thromboembolic prophylaxis for four weeks. Under supervision of the physiotherapist, patients were allowed weight-bearing as tolerated with two crutches or a frame on postoperative day 1.

### 3. Follow-Up and Outcome Measures

Patients underwent postoperative follow-up at six weeks, three, six, and 12 months. At follow-up, clinical and radiological examinations and assessment of the Harris Hip Score were performed at three and 12 months. Information on adverse events was reported. Two patients died before the six-month follow-up. Evaluation of hip function was performed at the follow-up using the Harris hip score, which comprises four dimensions: pain, function, absence of deformity, and ROM. The higher the score, the better the hip function and vice versa. A score of <70 was regarded as poor, 70-79 as fair, 80-89 as good, and 90-100 as excellent, with a maximum score of 100. Radiographic assessment was performed preoperatively and at all follow-ups. Analysis of the follow-up radiographs was performed by an independent radiologist and one of the treating orthopaedic surgeons (M.B.) for evaluation of implant failure, loosening, HO, and fracture healing. Classification of HO was based on Brooker class I-IV. Class I indicates islands of bone within soft tissues, class II indicates bone spurs with >1 cm of space between bone surfaces, Class III indicates bone spurs with <1 cm of space between bone surfaces, and Class IV



**Fig. 2.** Introduction of the multihole, fully porous acetabular cup into the acetabulum.



**Fig. 3.** Cementing of a dual mobility cup into the multihole cup in the precise version and inclination.

indicates ankylosis of the hip joint.

## RESULTS

### 1. Functional Outcomes

All patients were allowed weight-bearing with a walking frame or crutches as tolerated on postoperative day 1. Postoperatively, 12 patients were able to return to their previous living arrangements, while four patients received care in nursing homes at a mean time of 9.9 days (range, 5-19 days) after surgery. At three months, the mean Harris hip score was poor, respectively, 64.8 (range, 34.7-82.8). However, this score had increased to good at one year, respectively, 80.0 (range, 60.8-93.8). At six weeks all patients were still using at least one crutch; however, maintenance of preoperative mobility status was demonstrated in 14 patients at one year.

### 2. Radiographic Outcomes

Immediately postoperative, satisfactory position of the multihole cup, screws, and the femoral component was demonstrated on all radiographs (Fig. 1B). Radiographs taken at one year (n=14) showed that the position was maintained along with fracture union in all cases. No signs of loosening were reported. HO was observed in two cases, which were both classified as Brooker class 1. As of the latest follow-up (n=12), no radiological abnormalities have been reported.

### 3. Mortality and Complications

The mortality rate was two of 16 (12.5%) at six months and three of 16 at 28 months (18.8%). Immediately postoperative, one patient developed a postoperative hematoma that did not require additional treatment. One patient who suffered a deep venous thrombosis (DVT) was treated with LMWH (low-molecular-weight heparin) for three months. One patient who sustained a low-energy fall during admission to the hospital five days postoperatively and suffered a periprosthetic Vancouver B2 fracture underwent femoral stem revision, with good clinical and radiological outcomes. Packed cells were administered in five patients who developed postoperative anemia (Haemoglobin <7 g/dL). As of the most recent follow-up, there were no cases of dislocation or deep infection.

## DISCUSSION

Acetabular fractures are more common in the elderly and require the use of an advanced approach utilizing a team of specialists. Although different treatment options have been proposed, decisions regarding treatment are made according to the fracture type, the patient's medical status, and the surgical preference. However, this study supports the use of a surgical approach with use of a DM cup cemented into a porous multihole cup; good clinical, functional, and radiological outcomes have been reported in selected patients.

Good results have been reported with use of conservative treatment in cases involving minimally or nondisplaced and stable acetabular fractures<sup>4,5,26</sup>; however, when using a conservative approach long periods of immobilization and inactivity can lead to development of complications such as urinary tract infections, muscle wasting, pneumonias, and pressure ulcers<sup>3</sup>. In addition, this can lead to development of posttraumatic arthritis, which requires THA at a later stage. Although ORIF is the preferred option for treatment of displaced acetabular fractures, the outcome may be hindered by factors such as marginal impaction, avascular necrosis, and pre-existing arthritis<sup>7,11</sup>. Achieving good anatomical reduction is difficult in osteoporotic bone; according to the findings of a systematic review, anatomical reduction was only achieved in 45% of cases and 22% of patients required reconversion to THA<sup>10</sup>. In addition, inferior results have been reported for delayed THA after ORIF for treatment of acetabular fractures<sup>8</sup>. Acute THA appears to be a feasible option for treatment of acetabular fractures in older patients. A recent meta-analysis by Jauregui et al.<sup>13</sup> reported satisfactory clinical outcomes and survivorship rates. However, there is potential for subsidence of the acetabular component due to the difficulty of ample fixation caused by osteoporosis and an unstable fracture pattern<sup>12</sup>.

Use of a Burch-Schneider reconstruction ring in combination with a cemented acetabular cup has been proposed in order to obtain a more stable acetabular construct<sup>27-29</sup>, and good clinical and radiological results have been reported.

In our study we report on use of a porous multihole acetabular cup cemented into the ilium, ischium, and pubis using variable angle locking screws in order to bypass the acetabular fracture.

Enhanced cup fixation was reported after application of additional acetabular screws into the acetabular cup<sup>30</sup> after THA and application of locking screws into their respective plates, as utilized in trauma settings, resulted in improved fixation of osteoporotic fractures in long bones, via creation

of a more rigid fixed angle construct<sup>31</sup>). Although locking screws were not found to be superior to standard screw fixation<sup>30</sup>), Milne et al.<sup>32</sup>) reported superior biomechanically significant results from introduction of polyaxial locking compression screws over cancellous screws into a non-cemented acetabular cup and reduced interfacial micromotion. In our study, application of this concept resulted in complete union of all fractures at one year, without signs of loosening or subsidence.

Complications, including DVT, HO, and dislocations do occur following primary THA for treatment of acetabular fractures, and in our series, the complication rate (25%) was comparable to those reported in previous studies, ranging from 20% to 60%<sup>9-10,12-14,27</sup>).

We believe that the operative time should be minimized as much as possible in these frail patients. In our study the mean operative time was 123 minutes, compared to 203 minutes and 209 minutes for ORIF and ORIF and THA, respectively<sup>10</sup>). Some studies promoting the use of a more complex acetabular Burch-Schneider reinforcement ring in performance of acute THA reported that the operating time ranged from 149 minutes<sup>28</sup>) to 234 minutes<sup>29</sup>).

Regardless of the treatment, the mortality rate following acetabular fractures in the elderly remains high. Capone et al.<sup>9</sup>) reported a one-year mortality rate of 22.6% in patients over 55 years of age and 8.8% for treatment with ORIF and THA, respectively. Another recent study reported a one-year mortality rate of 26% in patients who received conservative treatment versus 18% in the cohort of patients who underwent surgery<sup>5</sup>). In our study, the one-year mortality rate was even lower, 12.5%, respectively. In our opinion, this low percentage can be attributed in part to the relatively short operative time, use of the tissue respecting posterior approach, and rapid ambulation.

After an ORIF patients were allowed a restricted weight-bearing regime<sup>7,9</sup>), while patients in our study were allowed full mobilization and weight-bearing as tolerated' from postoperative day one. A similar postoperative protocol was utilized in other studies<sup>12,27-29</sup>). At six weeks postoperatively, all of our study patients were using at least one crutch; however, maintenance of preoperative mobility status was demonstrated in 88% of the patients at one year.

In this study, the mean Harris hip score at three months was poor, 64.8 (range, 34.7-82.8). However, this score had increased to good at one year, 80.0. This score is comparable to scores reported in the study by Enocson and Blomfeldt<sup>28</sup>), using a Burch-Schneider ring.

A recent meta-analysis of THA for treatment of acetab-

ular fractures reported a weighted mean Harris hip score of 83.3 points at the latest follow-up, which is in agreement with our results<sup>13</sup>). The risk of dislocation in that meta-analysis was 6.1%. We believe that the use of a DM acetabular construct is preferable in this population of elderly patients with a higher risk of dislocation<sup>15,16</sup>). DM cups, first introduced by Bousquet in the late 1970s, were developed for prevention of THA dislocation based on the large-diameter head concept<sup>20</sup>). The benefits of DM components with lower dislocation rates after THA<sup>17,18</sup>) and even after revision THA<sup>19</sup>) have been demonstrated. Use of the combination of the DM cup cemented into a porous multihole cup in our cohort has resulted in no dislocations.

Therefore, fracture fixation is enhanced and the risk of dislocation is reduced with use of the implanted construct using variable angle locking screws in combination with a DM cup; no study on the use of this operative technique described in our study for treatment of acetabular fractures has been previously reported in the literature. However, some studies have described the use of a DM cup cemented into a well-fixed acetabular cup and good results were reported in a revision arthroplasty setting for management of recurrent dislocations and bone loss<sup>21-23</sup>). The well documented clinical and radiological follow-up at fixed times is another strength of this study.

This study has some limitations. It was conducted as a retrospective review of prospectively collected data and is therefore reliant on the accuracy of the initial documentation included in the clinical notes. A control group was not included for comparison and the patients' preoperative data were not available. In addition, this was a single center study and the surgical procedures were performed by a single surgeon (K.G.). In addition to the small sample size (n=16), the lack of evaluation using a health-related quality of life assessment or activities of daily living evaluation is another limitation.

## CONCLUSION

In conclusion, the use of a DM cup cemented into a porous multihole cup with locking screws appears to be a safe option for treatment of acetabular fractures in elderly patients with encouraging functional and radiological outcomes.

## FUNDING

No funding to declare.

## CONFLICT OF INTEREST

The authors declare that there is no potential conflict of interest relevant to this article.

## REFERENCES

- Mears DC. *Surgical treatment of acetabular fractures in elderly patients with osteoporotic bone. J Am Acad Orthop Surg.* 1999;7:128-41. <https://doi.org/10.5435/00124635-199903000-00006>
- Ferguson TA, Patel R, Bhandari M, Matta JM. *Fractures of the acetabulum in patients aged 60 years and older: an epidemiological and radiological study. J Bone Joint Surg Br.* 2010;92:250-7. <https://doi.org/10.1302/0301-620X.92B2.22488>
- Harper CM, Lyles YM. *Physiology and complications of bed rest. J Am Geriatr Soc.* 1988;36:1047-54. <https://doi.org/10.1111/j.1532-5415.1988.tb04375.x>
- Magu NK, Rohilla R, Arora S. *Conservatively treated acetabular fractures: a retrospective analysis. Indian J Orthop.* 2012;46:36-45. <https://doi.org/10.4103/0019-5413.91633>
- Wollmerstädt J, Pieroh P, Schneider I, et al. *Mortality, complications and long-term functional outcome in elderly patients with fragility fractures of the acetabulum. BMC Geriatr.* 2020;20:66. <https://doi.org/10.1186/s12877-020-1471-x>
- Gary JL, Lefaivre KA, Gerold F, Hay MT, Reinert CM, Starr AJ. *Survivorship of the native hip joint after percutaneous repair of acetabular fractures in the elderly. Injury.* 2011;42:1144-51. <https://doi.org/10.1016/j.injury.2010.08.035>
- Giannoudis PV, Grotz MR, Papakostidis C, Dinopoulos H. *Operative treatment of displaced fractures of the acetabulum. A meta-analysis. J Bone Joint Surg Br.* 2005;87:2-9. <https://doi.org/10.1302/0301-620X.87B1.15605>
- Weber M, Berry DJ, Harmsen WS. *Total hip arthroplasty after operative treatment of an acetabular fracture. J Bone Joint Surg Am.* 1998;80:1295-305. <https://doi.org/10.2106/00004623-199809000-00008>
- Capone A, Peri M, Mastio M. *Surgical treatment of acetabular fractures in the elderly: a systematic review of the results. EFORT Open Rev.* 2017;2:97-103. <https://doi.org/10.1302/2058-5241.2.160036>
- Daurka JS, Pastides PS, Lewis A, Rickman M, Bircher MD. *Acetabular fractures in patients aged > 55 years: a systematic review of the literature. Bone Joint J.* 2014;96-B:157-63. <https://doi.org/10.1302/0301-620X.96B2.32979>
- De Bellis UG, Legnani C, Calori GM. *Acute total hip replacement for acetabular fractures: a systematic review of the literature. Injury.* 2014;45:356-61. <https://doi.org/10.1016/j.injury.2013.09.018>
- Mears DC, Velyvis JH. *Acute total hip arthroplasty for selected displaced acetabular fractures: two to twelve-year results. J Bone Joint Surg Am.* 2002;84:1-9. <https://doi.org/10.2106/00004623-200201000-00001>
- Jauregui JJ, Weir TB, Chen JF, et al. *Acute total hip arthroplasty for older patients with acetabular fractures: a meta-analysis. J Clin Orthop Trauma.* 2020;11:976-82. <https://doi.org/10.1016/j.jcot.2020.01.003>
- Gautam D, Gupta S, Malhotra R. *Total hip arthroplasty in acetabular fractures. J Clin Orthop Trauma.* 2020;11:1090-8. Erratum in: *J Clin Orthop Trauma.* 2021;21:101558. <https://doi.org/10.1016/j.jcot.2020.10.037>
- Meek RM, Allan DB, McPhillips G, Kerr L, Howie CR. *Epidemiology of dislocation after total hip arthroplasty. Clin Orthop Relat Res.* 2006;447:9-18. <https://doi.org/10.1097/01.blo.0000218754.12311.4a>
- Patel PD, Potts A, Froimson MI. *The dislocating hip arthroplasty: prevention and treatment. J Arthroplasty.* 2007;22(4 Suppl 1):86-90. <https://doi.org/10.1016/j.arth.2006.12.111>
- Darrith B, Courtney PM, Della Valle CJ. *Outcomes of dual mobility components in total hip arthroplasty: a systematic review of the literature. Bone Joint J.* 2018;100-B:11-9. <https://doi.org/10.1302/0301-620X.100B1.BJJ-2017-0462.R1>
- De Martino I, D'Apolito R, Soranoglou VG, Poultsides LA, Sculco PK, Sculco TP. *Dislocation following total hip arthroplasty using dual mobility acetabular components: a systematic review. Bone Joint J.* 2017;99-B(ASuppl1):18-24. Erratum in: *Bone Joint J.* 2017;99-B:702-4. <https://doi.org/10.1302/0301-620X.99B1.BJJ-2016-0398.R1>
- Abdel MP. *Dual-mobility constructs in revision total hip arthroplasties. J Arthroplasty.* 2018;33:1328-30. <https://doi.org/10.1016/j.arth.2018.01.030>
- Plummer DR, Christy JM, Sporer SM, Paprosky WG, Della Valle CJ. *Dual-mobility articulations for patients at high risk for dislocation. J Arthroplasty.* 2016;31(9 Suppl):131-5. <https://doi.org/10.1016/j.arth.2016.03.021>
- Moreta J, Uriarte I, Foruria X, Urria I, Aguirre U, Martínez-de Los Mozos JL. *Cementation of a dual-mobility cup into a well-fixed cementless shell in patients with high risk of dislocation undergoing revision total hip arthroplasty. Hip Int.* 2021;31:97-102. <https://doi.org/10.1177/1120700019873617>
- Gabor JA, Feng JE, Gupta S, et al. *Cementation of a monoblock dual mobility bearing in a newly implanted porous revision acetabular component in patients undergoing revision total hip arthroplasty. Arthroplast Today.* 2019;5:341-7. <https://doi.org/10.1016/j.artd.2019.05.001>
- Evangelista PJ, Okroj K, Plummer D, Della Valle CJ, Schwarzkopf R. *Do cemented dual-mobility cups confer stability for patients at high risk of dislocation in revision total hip arthroplasty? J Hip Surg.* 2018;02:088-91. <https://doi.org/10.1055/s-0038-1661341>
- Letournel E. *Acetabulum fractures: classification and management. Clin Orthop Relat Res.* 1980;(151):81-106.
- Wasielewski RC, Cooperstein LA, Kruger MP, Rubash HE. *Acetabular anatomy and the transacetabular fixation of screws in total hip arthroplasty. J Bone Joint Surg Am.* 1990;72:501-8.
- Henry PD, Kreder HJ, Jenkinson RJ. *The osteoporotic acetabular fracture. Orthop Clin North Am.* 2013;44:201-15. <https://doi.org/10.1016/j.ocl.2013.01.002>
- Tidermark J, Blomfeldt R, Ponzer S, Söderqvist A, Törnkvist H. *Primary total hip arthroplasty with a Burch-Schneider antiprotusion cage and autologous bone grafting for acetabular fractures in elderly patients. J Orthop Trauma.* 2003;17:193-7. <https://doi.org/10.1097/00005131-200303000-00007>
- Enocson A, Blomfeldt R. *Acetabular fractures in the elderly treated with a primary Burch-Schneider reinforcement ring, autologous bone graft, and a total hip arthroplasty: a prospective study with a 4-year follow-up. J Orthop Trauma.* 2014;28:330-

7. <https://doi.org/10.1097/BOT.000000000000016>
29. Liaw F, Govilkar S, Banks D, Kankanalu P, Youssef B, Lim J. Primary total hip replacement using Burch-Schneider cages for acetabular fractures. *Hip Int.* 2022;32:401-6. <https://doi.org/10.1177/1120700020957642>
30. Heller S, Brosh T, Kosashvili Y, Velkes S, Burg A, Dudkiewicz I. Locking versus standard screw fixation for acetabular cups: is there a difference? *Arch Orthop Trauma Surg.* 2013;133:701-5. <https://doi.org/10.1007/s00402-013-1709-6>
31. Haidukewych GJ. Innovations in locking plate technology. *J Am Acad Orthop Surg.* 2004;12:205-12. <https://doi.org/10.5435/00124635-200407000-00001>
32. Milne LP, Kop AM, Kuster MS. Polyaxial locking and compression screws improve construct stiffness of acetabular cup fixation: a biomechanical study. *J Arthroplasty.* 2014;29:1043-51. <https://doi.org/10.1016/j.arth.2013.11.007>