

## 세포교정영양요법(OCNT)을 이용한 담낭용종 환자 개선 사례 연구

윤승현 약사

전라남도 무안군 삼향읍 남악5로 48번 17 정우빌딩 1층 셀메드윤약국

### A Case Study on the Improvement of Gallbladder Polyp Patient using Ortho-Cellular Nutrition Therapy (OCNT)

Pharmacist, Seung hyeon Yun

Cellmed Yun Pharmacy, 1F, 17, Namak 5-ro 48beon-gil, Samhyang-eup, Muan-gun, Jeollanam-do, Republic of Korea

#### ABSTRACT

**Objective:** Case report on the improvement of gallbladder polyp using Ortho-Cellular Nutrition Therapy (OCNT).

**Methods:** A middle-aged Korean male with gallbladder polyp presenting with mild fatigue and indigestion.

**Results:** Significant improvement in the gallbladder polyp was observed after implementing nutritional therapy.

**Conclusion:** Nutritional therapy may be beneficial in alleviating symptoms and improving the condition of patients with gallbladder polyp.

**Keywords** Ortho-Cellular Nutrition Therapy (OCNT), gallbladder polyp, fatigue, indigestion

#### Introduction

Gallbladder polyp refers to a lesion protruding from the gallbladder wall into the interior of the gallbladder. Most patients are incidentally diagnosed during routine

abdominal ultrasound examinations or after gallbladder resection for gallstones or acute cholecystitis. While the majority of gallbladder polyps are benign, some can be malignant, underscoring the importance of early detection and appropriate management. Regular monitoring is essential for the prevention of gallbladder adenocarcinoma.

Benign gallbladder polyps can be categorized into pseudotumors (cholesterol polyps, inflammatory polyps, cholesterosis, and adenomyomatosis), epithelial tumors (adenomas), and mesenchymal tumors (fibroids, lipomas, and hemangiomas).

\*Correspondence: Seung hyeon Yun

E-mail: khest@naver.com

Received Jun 27, 2023; Accepted Jun 29, 2023; Published Jun 30, 2023

doi: <http://dx.doi.org/10.5667/CellMed.spc.031>

©2023 by CellMed Orthocellular Medicine Pharmaceutical Association

This is an open access article under the CC BY-NC license.

(<http://creativecommons.org/licenses/by-nc/3.0/>)

† This report has been translated and edited by the CellMed editor-in-chief, Prof. Beom-Jin Lee.

For patients with symptoms or an increased risk of malignancy, polyps larger than 6mm should be resected, while in low-risk cases, the decision to remove the gallbladder should consider various factors.<sup>1</sup>

## Case Study

### 1. Subject

A case study was conducted on a patient with gallbladder polyp.

- 1) Name: Kim O O (M/40 years old)
- 2) Diagnosis: Gallbladder polyp (0.6cm)
- 3) Onset date: December 3, 2022
- 4) Treatment period: December 21, 2022 - Present
- 5) Presenting symptoms: Mild fatigue and indigestion
- 6) Medical history: Carrier of hepatitis B virus
- 7) Social history: Non-smoker, moderate alcohol consumption (5 bottles per week for 20 years)
- 8) Family history: Hypertension, liver disease
- 9) Current medications: None

### 2. Methods

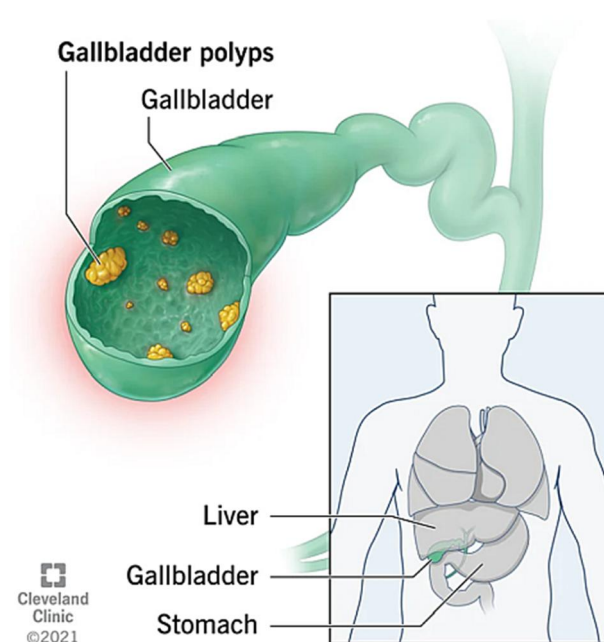
Nutritional therapy was administered as follows:

- Cyaplex F (200, once a day, 2 tablet per dose)
- Eufaplex (200, once a day, 2 tablet per dose)
- NCTplex (300, once a day, 3 tablet per dose)
- Betaplex (200, once a day, 2 tablet per dose)
- TMplex (200, once a day, 2 tablet per dose)
- Enzaplex (200, once a day, 2 tablet per dose)
- HaepoBooster (200, once a day, 2 tablet per dose)
- Curcuplex (200, once a day, 2 tablet per dose)
- Cyaplex Mineral Bamboo Salt (101, twice a day, 1 sachet per dose)
- Heartberry Lemon (101, twice a day 1 sachet per dose)
- Aqua SAC Pure (101, twice a day, 1 sachet per dose)
- Diverol (020, once a day 2 tablets per dose)

In addition, the patient was advised to follow a proper diet and engage in regular exercise. Considering the patient's alcohol consumption history, moderation was recommended rather than complete abstinence.

## Result

The patient was diagnosed with a 6mm gallbladder polyp on December 3rd. As a carrier of inactive hepatitis B virus, the patient was already concerned about their liver health. However, due to frequent alcohol consumption and stress caused by business expansion, their overall health condition had deteriorated. Given that the gallbladder polyp exceeded 10mm, surgical removal of the gallbladder was recommended. However, after undergoing nutritional therapy, the gallbladder polyp showed no trace and its size could no longer be determined.



**Figure 1. Schematic Diagram of Gallbladder or Cystic Polyp.** A gallbladder polyp refers to a tumor that appears on the inner wall of the gallbladder, excluding gallstones. The majority of gallbladder polyps are benign and do not cause symptoms. They can be caused by inflammation,

excessive cholesterol accumulation, or abnormal cell proliferation. Among them, approximately 5% can progress to cancer (Gallbladder Polyps. USA. 2021. Available at: <https://my.clevelandclinic.org/health/diseases/21821-gallbladder-polyps>).

### **Conclusion**

The patient in this case is a 40-year-old male who was diagnosed with a gallbladder polyp on December 3, 2022. In modern medicine, gallbladder polyps cannot be treated with medication, and the likelihood of a benign gallbladder polyp transforming into a malignant one is very low.<sup>2</sup> However, it is recommended to consider factors such as surveillance and observation or gallbladder resection.

The gallbladder, although not essential for life, plays important roles in the absorption of dietary fats and fat-soluble vitamins, regulation of bile acid homeostasis, and influence on glucose and lipid homeostasis.<sup>3</sup> Additionally, bile acids have been implicated in functional gastrointestinal disorders, irritable bowel syndrome, chronic diarrhea, and chronic idiopathic constipation.<sup>4</sup> Therefore, while the absence of a gallbladder may not pose a threat to life, it can significantly affect the quality of life, emphasizing the importance of avoiding gallbladder removal surgery whenever possible.

The anthocyanin-fucoidan complex in Cyaplex F has higher absorption and stability compared to conventional anthocyanins. Anthocyanins have been known to regulate cell apoptosis and have a positive impact on chronic diseases, including cancer.<sup>5,6</sup>

Additionally, the unsaturated fatty acids in Eufaplex regulate the fluidity of cell membranes, directly influencing the function of membrane proteins.<sup>7</sup>

Betaplex contains beta-glucan, which enhances the function of dendritic cells and natural killer (NK) cells, thereby increasing immune defense. Beta-glucan acts as an immune stimulant that works through the activation of dendritic cells and the cytotoxicity of NK cells, and it can also inhibit tumor growth even in the promotion stage.<sup>8</sup> In the context of tumor suppression, Chloplex's chlorella, TMplex's selenium, and Enzaplex's bromelain have been found to be beneficial.<sup>9-11</sup> Additionally, to support liver function, the inclusion of glycine in HaepoBooster, magnesium in Magplex, and curcumin in Curcuplex were recommended.<sup>12-14</sup> Furthermore, Vitamin D in Diverol has been shown to improve immune function and liver function.<sup>15,16</sup>

Lastly, Aqua SAC Calcium is recommended for improving extracellular matrix (ECM) function.<sup>17</sup> Cyaplex Mineral Bamboo Salt and Heartberry Lemon were also recommended for this purpose.

After 6 months of undergoing the nutritional therapy, an ultrasound examination on June 8, 2023, revealed that only traces of the 6mm gallbladder polyp remained, and the size could no longer be confirmed. The patient, who used to express concerns about the need for gallbladder removal as the polyp grows, also confessed that such worries had disappeared. Although the gallbladder polyp had disappeared, the patient decided to continue with the nutritional therapy for maintaining future health.

This case report represents a single case and cannot be universally applied to all patients with gallbladder polyps. However, it is a valuable example of symptom improvement in the patient. The report has been shared with the patient's consent.

### **Reference**

1. Andrén-Sandberg, A. Diagnosis and management of gallbladder polyps. *N Am J Med Sci* **4**, 203-211 (2012).

- <https://doi.org/10.4103/1947-2714.95897>
- 2 Wiles, R., Varadpande, M., Muly, S. & Webb, J. Growth rate and malignant potential of small gallbladder polyps—systematic review of evidence. *the surgeon* **12**, 221-226 (2014).
- 3 Keitel, V., Kubitz, R. & Häussinger, D. Endocrine and paracrine role of bile acids. *World journal of gastroenterology: WJG* **14**, 5620 (2008).
- 4 Appleby, R. N. & Walters, J. R. The role of bile acids in functional GI disorders. *Neurogastroenterology & Motility* **26**, 1057-1069 (2014).
- 5 Lee, J. Y. *et al.* Anthocyanin-fucoidan nanocomplex for preventing carcinogen induced cancer: Enhanced absorption and stability. *International Journal of Pharmaceutics* **586**, 119597 (2020).
- 6 Vanamala, J., Radhakrishnan, S., Reddivari, L. & Massey, A. Anthocyanins as apoptotic regulators. *Novel apoptotic regulators in carcinogenesis*, 93-122 (2012).
- 7 Murphy, M. G. Dietary Fatty Acids and Membrane Protein Function. *The Journal of Nutritional Biochemistry* **1**, 68-79 (1990).  
[https://doi.org:https://doi.org/10.1016/0955-2863\(90\)90052-M](https://doi.org/https://doi.org/10.1016/0955-2863(90)90052-M)
- 8 Akramienė, D., Kondrotas, A., Didžiapetrienė, J. & Kėvelaitis, E. Effects of  $\beta$ -glucans on the immune system. *Medicina* **43**, 597 (2007).
- 9 Ramos, A. L., Torello, C. O. & Queiroz, M. L. *Chlorella vulgaris* modulates immunomyelopoietic activity and enhances the resistance of tumor-bearing mice. *Nutrition and cancer* **62**, 1170-1180 (2010).
- 10 Zeng, H. & Combs Jr, G. F. Selenium as an anticancer nutrient: roles in cell proliferation and tumor cell invasion. *The Journal of nutritional biochemistry* **19**, 1-7 (2008).
- 11 Wen, H. K., Valle, S. J. & Morris, D. L. Bromelain and acetylcysteine (BromAc®): a novel approach to the treatment of mucinous tumours. *American Journal of Cancer Research* **13**, 1522 (2023).
- 12 Yin, M. *et al.* Glycine accelerates recovery from alcohol-induced liver injury. *Journal of Pharmacology and Experimental Therapeutics* **286**, 1014-1019 (1998).
- 13 Liu, M., Yang, H. & Mao, Y. Magnesium and liver disease. *Annals of translational medicine* **7** (2019).
- 14 Vera-Ramirez, L. *et al.* Curcumin and liver disease. *Biofactors* **39**, 88-100 (2013).
- 15 Baeke, F., Takiishi, T., Korf, H., Gysemans, C. & Mathieu, C. Vitamin D: modulator of the immune system. *Current opinion in pharmacology* **10**, 482-496 (2010).
- 16 Nair, S. Vitamin d deficiency and liver disease. *Gastroenterology & hepatology* **6**, 491 (2010).
- 17 Gopal, S., Multhaupt, H. A. & Couchman, J. R. Calcium in cell-extracellular matrix interactions. *Calcium Signaling*, 1079-1102 (2020).