



US Attenuation Imaging for the Evaluation and Diagnosis of Fatty Liver Disease

지방간 질환 진단을 위한 초음파 감쇠 영상 평가

Seung Jun Lee, MD , Youe Ree Kim, MD* ,
Young Hwan Lee, MD , Kwon-Ha Yoon, MD

Department of Radiology, Wonkwang University College of Medicine, Wonkwang University Hospital, Iksan, Korea

ORCID iDs

Seung Jun Lee <https://orcid.org/0000-0001-9948-9317>
Youe Ree Kim <https://orcid.org/0000-0001-5615-9721>
Young Hwan Lee <https://orcid.org/0000-0001-5893-6571>
Kwon-Ha Yoon <https://orcid.org/0000-0002-2634-8510>

Received April 17, 2022
Revised June 30, 2022
Accepted October 14, 2022

*Corresponding author

Youe Ree Kim, MD
Department of Radiology,
Wonkwang University
College of Medicine,
Wonkwang University Hospital,
895 Muwang-ro, Iksan 54538,
Korea.

Tel 82-63-859-1920
Fax 82-63-851-4749
E-mail sweetynn@naver.com

This is an Open Access article distributed under the terms of the Creative Commons Attribution Non-Commercial License (<https://creativecommons.org/licenses/by-nc/4.0>) which permits unrestricted non-commercial use, distribution, and reproduction in any medium, provided the original work is properly cited.

Purpose This study aimed to determine whether the attenuation coefficient (AC) from attenuation imaging (ATI) was correlated with visual US assessment in patients with hepatic steatosis. Moreover, it aimed to assess whether the patient's blood chemistry results and CT attenuation were correlated with AC.

Materials and Methods Patients who underwent abdominal US with ATI between April 2018 and December 2018 were included in this study. Patients with chronic liver disease or cirrhosis were excluded. The correlation between AC and other parameters, such as visual US assessment, blood chemistry results, liver attenuation, and liver-to-spleen (L/S) ratio, were analyzed. AC values according to visual US assessment grades were compared using analysis of variance.

Results A total of 161 patients were included in this study. The correlation coefficient between US assessment and AC was 0.814 ($p < 0.001$). The mean AC values for the normal, mild, moderate, and severe grades were 0.56, 0.66, 0.74, and 0.85, respectively ($p < 0.001$). Alanine aminotransferase levels were significantly correlated with AC ($r = 0.317$, $p < 0.001$). The correlation coefficients between liver attenuation and AC and between L/S ratio and AC were -0.702 and -0.626, respectively ($p < 0.001$).

Conclusion Visual US assessment and AC showed a strong positive correlation with the discriminative value between the groups. Computed tomography attenuation and AC showed a strong negative correlation.

Index terms Liver; Fatty Liver; Ultrasonography; Diagnostic Imaging

INTRODUCTION

Hepatic steatosis, a fatty liver disease, involves accumulation of lipids inside hepatocytes.

Various causes of fatty liver include alcohol consumption, viral hepatitis, and metabolic dysfunction (obesity, type 2 diabetes, hyperglycemia, and hypertriglyceridemia) (1, 2). The prevalence of fatty liver is high, ranging from 16% to 31% in the general population (2, 3). At least 25% of the American population has non-alcoholic fatty liver disease according to a recent population-based screening study (4). Diagnosis of fatty liver is important in terms of two clinical issues. First, patients with fatty liver should be evaluated for metabolic syndrome, which includes diabetes mellitus, hypertension, hypertriglyceridemia, and low levels of high-density lipoprotein cholesterol, which are known to be associated with high morbidity. Second, fat in the liver damages the normal liver parenchyma, which can lead to inflammation, fibrosis, and cirrhosis (5).

Liver biopsy is the gold standard for the diagnosis of fatty liver disease. Biopsy should be performed if non-alcoholic steatohepatitis (NASH) is suspected during general diagnosis (6). However, if simple fatty liver is suspected, biopsy is not performed due to its invasiveness, sampling errors, and other disadvantages (7-9). MR proton density fat fraction (PDFF) can be used for accurate inspection as an alternative to pathologic confirmation, but it is less cost-effective and the procedure is not accessible to the general population (10, 11).

US is the most commonly used imaging modality for diagnosing diffuse and fatty liver disease (12, 13). US diagnosis and severity of fatty liver are determined according to the visual diagnostic criteria based on the principle that liver fat attenuates the US beam (14, 15). However, the method itself is subjective. It has also been reported that the diagnostic accuracy is not high when liver fat accumulation is low (14, 16, 17). Efforts are being made to quantify fatty liver by measuring the attenuation coefficient (AC) in two-dimensional US with a recently developed device. Moreover, several studies have published their observations regarding diagnosis using the multiparametric US approach in patients having NASH who were diagnosed with a biopsy and a correlation between the grade of pathologic hepatic steatosis and AC of attenuation imaging (ATI) was reported (11, 18, 19). These studies correlated with pathological results. However, since they included patients with fibrosis and cirrhosis, there is a possibility that fibrosis affected the AC values. Therefore, there might be differences in the AC values among patients with simple steatosis.

This study aimed to determine whether AC from ATI was correlated with visual US assessment in patients with simple steatosis, to present the AC values for each US assessment grade, and to determine whether blood chemistry and CT attenuation were correlated with AC.

MATERIALS AND METHODS

PATIENTS

This single-center retrospective study was approved by our Institutional Review Board (IRB No. WKUH 2018-11-024). 410 patients who underwent two-dimensional abdominal US with ATI of the liver and blood chemistry between April 2018 and December 2018 were enrolled. The exclusion criteria were 1) patients with chronic liver disease (CLD) or cirrhosis (viral hepatitis, alcoholic hepatitis, autoimmune hepatitis, and biopsy confirmed NASH) (203 patients), 2) patients with CLD or cirrhosis confirmed at the 1-year follow-up (clinical examination and/or biopsy) (21 patients), 3) patients with acute hepatitis or an acute biliary condition (12 pa-

tients), 4) patients with renal parenchymal disease (2 patients), 5) patients with coarse parenchymal echogenicity on US examination (9 patients), and 6) patients whose US images were unavailable (2 patients). Altogether, 161 patients (100 male and 61 female) were included in this study. A flow diagram of patient Inclusion is depicted in Fig. 1. Additionally, patients who underwent CT examination within 2 months of the US examination were subsequently analyzed.

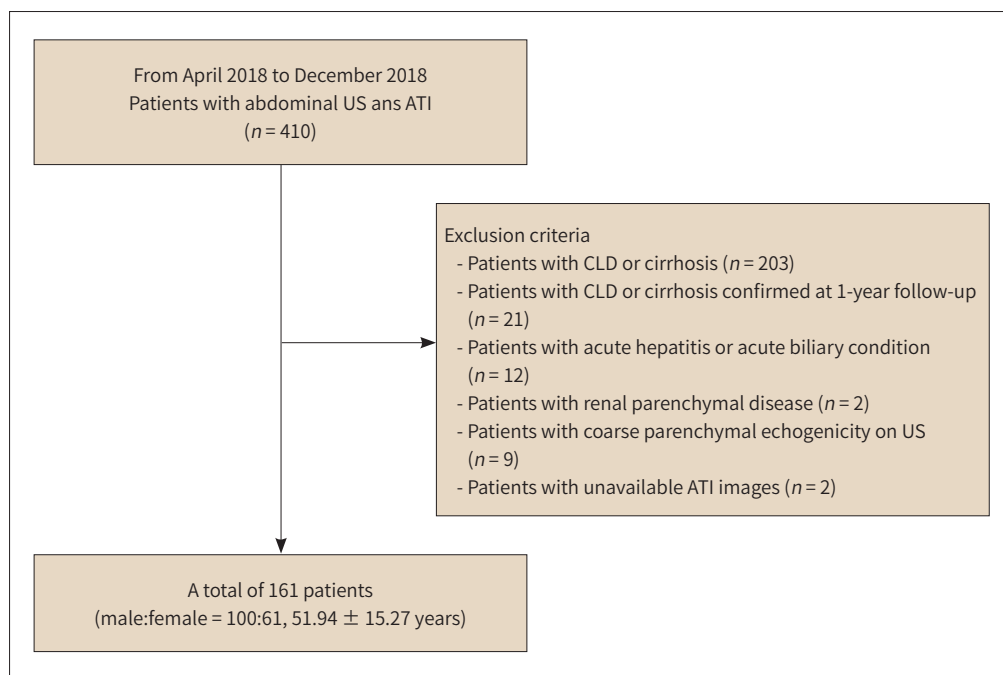
US EXAMINATION AND ATTENUATION IMAGING

Abdominal US and ATI were performed using Aplio i800 (Canon Medical Systems Corporation, Otawara, Japan) with a convex broadband probe (SC6-1, 1–8 MHz). Patients were examined after 8 hours of fasting and abdominal US was performed with the right arm raised. US images contained an intercostal view of the right hemiliver and gallbladder fossa and a sub-costal view of both right hemiliver and right kidney according to the routine abdominal US protocol. ATI was performed immediately after the US examination. Images were obtained in a plane perpendicular to the right hemiliver in the intercostal view. After placing the green box as the first region of interest (ROI) covering the whole parenchyma of the right hemiliver, a yellow box sized 2 cm × 4 cm was placed in the blue-colored area as the second ROI. The mean AC value of the ROI was displayed and the coefficient of determination, which indicates the reliability of the measurements, was also provided. Images with a coefficient of determination above 0.85 were obtained. AC was measured five times and the median value was used.

US IMAGE ANALYSIS

Two abdominal radiologists (Y.R.K. and Y.H.L.) retrospectively reviewed the abdominal US images by consensus to grade the severity of hepatic steatosis. Patients were classified ac-

Fig. 1. Flow chart of the study population.



ATI = attenuation imaging, CLD = chronic liver disease

according to the generally used definition of US hepatic steatosis (12). Grade 0 (normal) indicated homogeneous texture, fine-level echoes, and minimally hyperechoic or isoechoic areas when compared with normal renal cortex. Grade 1 (mild) indicated increased liver echogenicity compared to that of normal renal cortex. Grade 2 (moderate) indicated increased liver echogenicity and slightly impaired visualization of the intrahepatic vessels and diaphragm. Grade 3 (severe) indicated markedly increased liver echogenicity, poor penetration of the posterior segment of the right lobe of the liver, and poor or no visualization of the hepatic vessels and diaphragm.

CT EXAMINATION AND ANALYSIS

CT images were obtained using a 128-channel multidetector CT scanner (Somatom Definition Flash; Siemens Medical Solutions, Forchheim, Germany) or a 64-channel multidetector CT scanner (Somatom Sensation; Siemens Medical Solutions, Forchheim, Germany). The scanning protocol for pre-contrast imaging was as follows: 120 kVp, auto-calculated mAs using the CareDose 4D system, and a reconstructed slice thickness of 5 mm. To measure attenuation, a round ROI of more than 5 cm² was manually drawn in the hepatic and splenic parenchyma, avoiding large vessels and focal lesions. Attenuation of the liver and spleen was measured five times and the mean value was calculated. The mean value of liver attenuation and the liver-to-spleen (L/S) ratio were used to compare the AC values (20, 21).

CLINICAL DATA AND BLOOD CHEMISTRY

All clinical data were reviewed using an electronic medical record system. Patients diagnosed with CLD or cirrhosis within a 1-year follow-up period were excluded from the review. The duration between abdominal US and blood chemistry was \leq 1 week. Aspartate aminotransferase (AST), alanine aminotransferase (ALT), gamma-glutamyltransferase (GGT), alkaline phosphatase (ALP), triglyceride (TG), and total cholesterol (TC) levels were analyzed.

STATISTICAL ANALYSIS

Relationships among AC, liver attenuation, L/S ratio, and blood chemistry were analyzed using Pearson's correlation. AC values according to the visual US assessment grades were compared using one-way analysis of variance and the Bonferroni test for multiple comparisons was used as a post-hoc test. Statistical significance was set at $p < 0.05$. IBM SPSS Statistics for Windows (version 27.0; IBM Corp., Armonk, NY, USA) and MedCalc Statistical Software (version 20.015; MedCalc Software, Ostend, Belgium) were used.

RESULTS

PATIENT CHARACTERISTICS

In all of 161 patients (100 male and 61 female), the mean age of the patients was 51.94 years. Normal, mild, moderate, and severe grades of fatty liver were observed in 59, 27, 37, and 38 patients, respectively. Detailed clinical characteristics including the purpose of US examination and mean blood chemistry values are presented in Table 1.

Table 1. Patients Characteristics

Characteristic	Value
Sex	
Male	100
Female	61
Mean age, years	51.94 ± 15.27
Body mass index, kg/m ²	26.24 ± 5.65
Purposes of US examination (numbers of patients)	
LFT abnormality	52
Monitoring of fatty liver	46
Metabolic disease	13
Follow-up of focal lesions	41
Health check-up	9
Blood chemistry	
AST, IU/L	55.91 ± 104.99
ALT, IU/L	48.85 ± 47.35
ALP, IU/L	245.14 ± 128.11
GGT, IU/L	81.51 ± 120.76
Triglyceride, mg/dL	175.23 ± 199.11
Total cholesterol, g/dL	186.50 ± 39.21
Visual US assessment (numbers of patients)	
Normal (grade 0)	59
Mild (grade 1)	27
Moderate (grade 2)	37
Severe (grade 3)	38

Data are mean ± standard deviation.

ALP = alkaline phosphatase, ALT = alanine aminotransferase, AST = aspartate aminotransferase, GGT = r-glutamyltransferase, LFT = liver function test, US = ultrasonography

RELATIONSHIP BETWEEN THE ATTENUATION COEFFICIENT AND VISUAL US ASSESSMENT

The Pearson correlation coefficient between AC and visual US assessment was 0.831 ($p < 0.001$). The mean AC values for visual US assessment grades of normal, mild, moderate, and severe were 0.56 ± 0.07 (95% confidence interval [CI]: 0.55–0.58), 0.66 ± 0.04 (95% CI: 0.65–0.68), 0.74 ± 0.01 (95% CI: 0.72–0.77), and 0.85 ± 0.02 (95% CI: 0.81–0.88), respectively ($p < 0.001$). Subgroup analyses using the Bonferroni test between the groups showed statistical significance ($p < 0.001$) (Fig. 2).

CORRELATION BETWEEN THE ATTENUATION COEFFICIENT AND SEROLOGICAL TESTS

Univariate analysis with linear regression showed that ALT level was weakly correlated with AC ($r = 0.317$, $p < 0.001$). Other blood chemistry parameters were not correlated with AC (AST: $r = 0.094$, $p = 0.347$; AST to ALT ratio: $r = 0.527$, $p = 0.120$, ALP: $r = 0.037$, $p = 0.724$; GGT: $r = -0.012$, $p = 0.920$; TG: $r = 0.201$, $p = 0.120$; and TC: $r = 0.147$, $p = 0.299$) (Table 2).

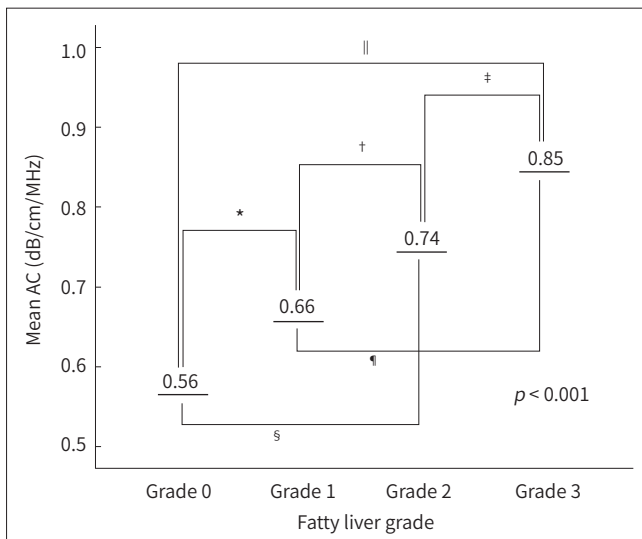


Fig. 2. Mean AC according to the visual US assessment grades of fatty liver.

The mean AC values for visual US assessment grades of normal (grade 0), mild (grade 1), moderate (grade 2), and severe (grade 3) were 0.56 ± 0.07 (95% CI: 0.55–0.58), 0.66 ± 0.04 (95% CI: 0.65–0.68), 0.74 ± 0.01 (95% CI: 0.72–0.77), and 0.85 ± 0.02 (95% CI: 0.81–0.88). The *p*-value obtained from one-way ANOVA for entire groups was < 0.001 . The Bonferroni test was used as a post-hoc test, and the *p*-value was < 0.001 for all comparisons between the two groups (*Grade 0 vs. Grade 1, †Grade 1 vs. Grade 2, ‡Grade 2 vs. Grade 3, §Grade 0 vs. Grade 2, ¶Grade 1 vs. Grade 3, ||Grade 0 vs. Grade 3). The Pearson correlation coefficient between AC and visual US grade was 0.831 ($p < 0.001$).

AC = attenuation coefficient, CI = confidence interval

Table 2. Association of the Results of Blood Chemistry Analysis with Attenuation Coefficient by Linear Regression

	Coefficient	<i>p</i> -Value
AST, IU/L	0.094	0.347
ALT, IU/L	0.317	0.001
ALP, IU/L	0.037	0.724
GGT, IU/L	-0.012	0.920
Triglyceride, mg/dL	0.201	0.120
Total cholesterol, g/dL	0.147	0.299

ALP = alkaline phosphatase, ALT = alanine aminotransferase, AST = aspartate aminotransferase, GGT = r-glutamyltransferase

CORRELATION BETWEEN THE ATTENUATION COEFFICIENT AND CT ATTENUATION

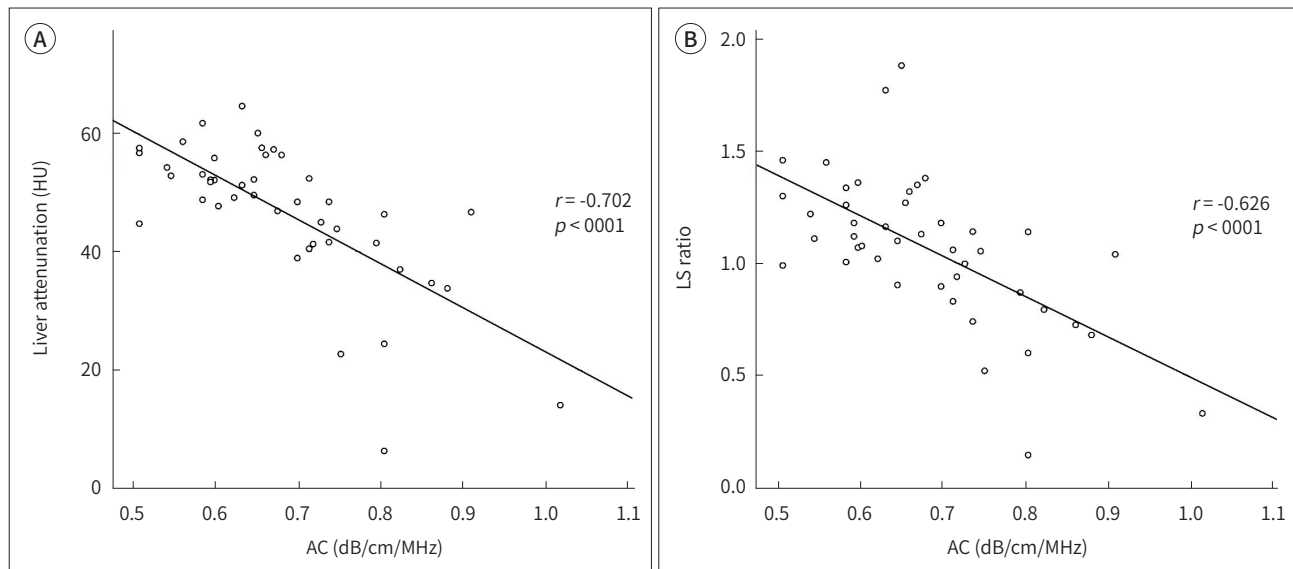
CT was performed in 46 patients. The median duration between US and CT examinations was 37 days (range: 13–46 days). The Pearson correlation coefficient between AC and liver attenuation was -0.702 ($p < 0.001$) (Fig. 3A). The Pearson correlation coefficient between AC and L/S ratio was -0.626 ($p < 0.001$) (Fig. 3B).

DISCUSSION

The present study analyzed the relationship between visual US assessment and AC values in patients with simple hepatic steatosis and showed a strong positive correlation. According to the severity of fatty liver based on visual US assessment, AC was graded without any overlap between the groups. In addition, AC showed a statistically significant correlation with ALT and a strong negative correlation with hepatic attenuation on CT and L/S ratio.

Although the existing visual US scale is widely used to diagnose hepatic steatosis, it has disadvantages such as interobserver and intraobserver variability. According to previous studies, the sensitivity and specificity for the diagnosis of hepatic steatosis based on the visual US scale

Fig. 3. Relationship between CT parameters and the AC.
A. The Pearson correlation coefficient between AC and liver attenuation was -0.702 ($p < 0.001$).
B. The Pearson correlation coefficient between AC and the LS ratio was -0.626 ($p < 0.001$).
 AC = attenuation coefficient, HU = Hounsfield unit, LS = liver-to-spleen



varied, ranging from sensitivity 60%–100% and specificity 77%–95%, respectively (6, 14, 22). Another limitation is that it can detect hepatic steatosis only when fatty infiltration is $> 30\%$ (17). Most of the patients included in this study were suspected of having simple steatosis, so they were treated with lifestyle modifications and hepatotonics. Treatment monitoring is challenging in case of a non-objective test. Quantification of the degree of deepening of the fatty liver and numerical presentation of improvement or worsening have a good effect on patient compliance (23–25). The present study attempted to correlate visual US assessment with AC in patients having clinically suspected simple steatosis without other hepatic diseases. The mean AC values were 0.56, 0.66, 0.74, and 0.85 for normal, mild, moderate, and severe grades of fatty liver disease, respectively and the 95% CIs of each group did not overlap. Thus, the results of the present study showed the discriminative value of fatty liver classification using the AC values and provided a reference value between visual assessment and AC.

Previous studies have reported that fibrosis affects AC in patients with CLD (11), while another study showed that fibrosis did not affect AC (18). In the present study, we hypothesized that coarseness would affect AC and excluded patients with CLD or cirrhosis, acute hepatitis, and coarse echogenicity on US examination. Similarly, another study comparing visual assessment and AC confirmed interobserver/intraobserver variability. In the aforementioned study, the mean AC values for grades 0, 1, 2, and 3 were 0.54, 0.65, 0.75, and 0.92 (26). These values are similar to those observed in the present study (0.56, 0.66, 0.74, and 0.85 for grades 0, 1, 2, and 3). However the AC value for grade 3 in the present study was slightly lower than that in the previous study. Although it is not a direct comparison, the present study included a greater number of patients with grade 3 disease (38 vs. 8 patients) and tried to exclude patients with fibrosis.

As a result of comparing the diagnostic accuracy of conventional US and CT for the detec-

tion of hepatic steatosis in meta-analysis, the sensitivity of US was better than CT and the specificity of CT was better than US (mean sensitivity; US: 73.3%–90.5%, CT: 46.1%–72.0%, mean specificity; US: 69.6%–85.2%, CT: 88.1%–94.6%, respectively) (21). The relationship between AC and liver attenuation or L/S ratio showed a strong negative correlation (AC vs. liver attenuation: $r = -0.702$, $p < 0.001$; AC vs. L/S ratio: $r = -0.626$, $p < 0.001$) in the present study. Few studies have compared CT with US or ATI. In a study comparing various modalities to quantify fatty liver, ATI showed better diagnostic performance than CT in mild fatty liver (> 5%) and comparable performance in severe fatty liver (> 66%). MR-PDFF was found to be the best modality for diagnosing pathologic steatosis (27).

In the present study, AC was correlated with the ALT levels, but not with serum TC or TG levels. Another study with the same vendor showed that ALT was significantly correlated with AC in the univariate analysis, but not in the multivariate analysis (11). Another study with different vendors showed a significant correlation between AC and TC ($r = 0.34$, $p < 0.001$), but not between AC and ALT ($r = -0.03$, $p = 0.05$) (27). We assumed that including CLD with different etiologies might have affected the results of our study.

The present study has several limitations. It was a single-center, retrospective study and interobserver/intraobserver variability was not assessed. However, according to a previous study, AC with ATI is a reliable method with high interobserver concordance (26, 28). In the present study, pathological results were not referenced, since patients diagnosed with simple steatosis were targeted. MR-PDFF, which showed results comparable to that of biopsy, was also not performed. Therefore, biopsy correlations of general population with those having simple steatosis will also be needed in future studies. Some patients with undetected hepatic fibrosis might have been included in this study. The number of patients who underwent CT was less than half of the total patient population and the interval between CT and US was ≤ 2 months. Since this was a retrospective study and some of the patients underwent CT on the same day, there might have been differences in the fatty liver disease status.

In conclusion, AC measurement using ATI in patients with suspected simple steatosis is a useful test for evaluating fat deposition. AC showed a strong positive correlation with visual US assessment and the ability to discriminate between the groups. AC showed a correlation with ALT levels and strong negative correlations with CT parameters including liver attenuation and L/S ratio.

Author Contributions

Conceptualization, K.Y.R., L.Y.H.; data curation, L.S.J., K.Y.R.; formal analysis, K.Y.R.; funding acquisition, K.Y.R.; investigation, L.S.J., K.Y.R.; methodology, L.S.J., K.Y.R.; supervision, K.Y.R., L.Y.H., Y.K.; validation, K.Y.R.; visualization, L.S.J.; writing—original draft, L.S.J., K.Y.R.; and writing—review & editing, K.Y.R.

Conflicts of Interest

The authors have no potential conflicts of interest to disclose.

Funding

This paper was supported by Wonkwang University in 2022.

REFERENCES

1. Farrell GC, Larter CZ. Nonalcoholic fatty liver disease: from steatosis to cirrhosis. *Hepatology* 2006;43(2 Suppl 1):S99-S112
2. Farrell GC, van Rooyen D, Gan L, Chitturi S. NASH is an inflammatory disorder: pathogenic, prognostic and therapeutic implications. *Gut Liver* 2012;6:149-171
3. Browning JD, Szczepaniak LS, Dobbins R, Nuremberg P, Horton JD, Cohen JC, et al. Prevalence of hepatic steatosis in an urban population in the United States: impact of ethnicity. *Hepatology* 2004;40:1387-1395
4. Lazo M, Hernaez R, Eberhardt MS, Bonekamp S, Kamel I, Guallar E, et al. Prevalence of nonalcoholic fatty liver disease in the United States: the Third National Health and Nutrition Examination Survey, 1988-1994. *Am J Epidemiol* 2013;178:38-45
5. Hui JM, Farrell GC. Clear messages from sonographic shadows? Links between metabolic disorders and liver disease, and what to do about them. *J Gastroenterol Hepatol* 2003;18:1115-1117
6. Angulo P. Nonalcoholic fatty liver disease. *N Engl J Med* 2002;346:1221-1231
7. Rockey DC, Caldwell SH, Goodman ZD, Nelson RC, Smith AD; American Association for the Study of Liver Diseases. Liver biopsy. *Hepatology* 2009;49:1017-1044
8. Hong YM, Yoon KT, Cho M, Chu CW, Rhu JH, Yang KH, et al. Clinical usefulness of controlled attenuation parameter to screen hepatic steatosis for potential donor of living donor liver transplant. *Eur J Gastroenterol Hepatol* 2017;29:805-810
9. Bedossa P, Dargère D, Paradis V. Sampling variability of liver fibrosis in chronic hepatitis C. *Hepatology* 2003;38:1449-1457
10. Kwon EY, Kim YR, Kang DM, Yoon KH, Lee YH. Usefulness of US attenuation imaging for the detection and severity grading of hepatic steatosis in routine abdominal ultrasonography. *Clin Imaging* 2021;76:53-59
11. Jeon SK, Lee JM, Joo I, Yoon JH, Lee DH, Lee JY, et al. Prospective evaluation of hepatic steatosis using ultrasound attenuation imaging in patients with chronic liver disease with magnetic resonance imaging proton density fat fraction as the reference standard. *Ultrasound Med Biol* 2019;45:1407-1416
12. Strauss S, Gavish E, Gottlieb P, Katsnelson L. Interobserver and intraobserver variability in the sonographic assessment of fatty liver. *AJR Am J Roentgenol* 2007;189:W320-W323
13. Sasso M, Beaugrand M, de Ledinghen V, Douvin C, Marcellin P, Poupon R, et al. Controlled attenuation parameter (CAP): a novel VCTE™ guided ultrasonic attenuation measurement for the evaluation of hepatic steatosis: preliminary study and validation in a cohort of patients with chronic liver disease from various causes. *Ultrasound Med Biol* 2010;36:1825-1835
14. Schwenzer NF, Springer F, Schraml C, Stefan N, Machann J, Schick F. Non-invasive assessment and quantification of liver steatosis by ultrasound, computed tomography and magnetic resonance. *J Hepatol* 2009;51:433-445
15. Tamaki N, Koizumi Y, Hirooka M, Yada N, Takada H, Nakashima O, et al. Novel quantitative assessment system of liver steatosis using a newly developed attenuation measurement method. *Hepatol Res* 2018;48:821-828
16. Roldan-Valadez E, Favila R, Martínez-López M, Uribe M, Méndez-Sánchez N. Imaging techniques for assessing hepatic fat content in nonalcoholic fatty liver disease. *Ann Hepatol* 2008;7:212-220
17. Clark JM, Brancati FL, Diehl AM. Nonalcoholic fatty liver disease. *Gastroenterology* 2002;122:1649-1657
18. Lee DH, Cho EJ, Bae JS, Lee JY, Yu SJ, Kim H, et al. Accuracy of two-dimensional shear wave elastography and attenuation imaging for evaluation of patients with nonalcoholic steatohepatitis. *Clin Gastroenterol Hepatol* 2021;19:797-805.e7
19. Tada T, Iijima H, Kobayashi N, Yoshida M, Nishimura T, Kumada T, et al. Usefulness of attenuation imaging with an ultrasound scanner for the evaluation of hepatic steatosis. *Ultrasound Med Biol* 2019;45:2679-2687
20. van Werven JR, Marsman HA, Nederveen AJ, Smits NJ, ten Kate FJ, van Gulik TM, et al. Assessment of hepatic steatosis in patients undergoing liver resection: comparison of US, CT, T1-weighted dual-echo MR imaging, and point-resolved 1H MR spectroscopy. *Radiology* 2010;256:159-168
21. Bohte AE, van Werven JR, Bipat S, Stoker J. The diagnostic accuracy of US, CT, MRI and 1H-MRS for the evaluation of hepatic steatosis compared with liver biopsy: a meta-analysis. *Eur Radiol* 2011;21:87-97
22. Joy D, Thava VR, Scott BB. Diagnosis of fatty liver disease: is biopsy necessary? *Eur J Gastroenterol Hepatol* 2003;15:539-543

23. Chalasani N, Younossi Z, Lavine JE, Charlton M, Cusi K, Rinella M, et al. The diagnosis and management of nonalcoholic fatty liver disease: practice guidance from the American Association for the Study of Liver Diseases. *Hepatology* 2018;67:328-357
24. Dong F, Zhang Y, Huang Y, Wang Y, Zhang G, Hu X, et al. Long-term lifestyle interventions in middle-aged and elderly men with nonalcoholic fatty liver disease: a randomized controlled trial. *Sci Rep* 2016;6:36783
25. Lăpădat AM, Gheonea DI, Florescu LM, Gheonea IA. Before and after treatment quantitative assessment of hepatic steatosis in a Romanian population using magnetic resonance liver spectroscopy. *Curr Health Sci J* 2019;45:258-262
26. Yoo J, Lee JM, Joo I, Lee DH, Yoon JH, Kang HJ, et al. Reproducibility of ultrasound attenuation imaging for the noninvasive evaluation of hepatic steatosis. *Ultrasonography* 2020;39:121-129
27. Bae JS, Lee DH, Suh KS, Kim H, Lee KB, Lee JY, et al. Noninvasive assessment of hepatic steatosis using a pathologic reference standard: comparison of CT, MRI, and US-based techniques. *Ultrasonography* 2022; 41:344-354
28. Gao J, Lee R, Trujillo M. Reliability of performing multiparametric ultrasound in adult livers. *J Ultrasound Med* 2022;41:699-711

지방간 질환 진단을 위한 초음파 감쇠 영상 평가

이승준 · 김유리* · 이영환 · 윤권하

목적 지방간 환자에서 초음파 감쇠영상(attenuation imaging; 이하 ATI)의 감쇠계수(attenuation coefficient; 이하 AC)와 시각적 평가 사이의 상관관계 여부를 파악하고 혈액화학 및 CT 감쇠계수와 AC 사이의 상관관계 여부를 평가하고자 하였다.

대상과 방법 본 후향적 연구에서는 2018년 4월부터 12월까지 ATI를 포함한 간초음파를 시행 받은 환자들 중 만성 간질환 및 간경화증을 제외한 환자들을 대상으로 하였다. AC와 초음파 시각적 평가, 혈액화학, 간 감쇠 및 간 대 비장 비율(liver to spleen ratio; 이하 L/S ratio) 사이의 상관관계를 분석하였다. 분산 분석을 통해 초음파 시각적 등급에 따른 AC 값을 비교하였다.

결과 총 161명의 환자가 포함되었다. 초음파 시각적 평가와 AC 사이의 상관 계수는 0.814였다 ($p < 0.001$). 정상, 경도, 중등도, 고도 지방간의 AC 평균값은 각각 0.56, 0.66, 0.74, 0.85였다 ($p < 0.001$). 알려진 아미노전이효소는 AC와 유의한 상관관계가 있었다($r = 0.317$, $p < 0.001$). 간 감쇠계수 및 L/S ratio와 AC 사이의 상관계수는 각각 -0.702와 -0.626이었다($p < 0.001$).

결론 초음파 시각적 평가와 AC는 강한 양의 상관관계 및 등급들 사이의 구별되는 AC 값을 보였고, CT 감쇠계수와 AC는 강한 음의 상관관계를 보였다.

원광대학교 의과대학 원광대학교병원 영상의학과