









Electronic Cigarette or Vaping-Associated Lung Injury Manifested as Acute Eosinophilic Pneumonia: A Case Report

급성호산구성폐렴으로 발현된 전자담배 관련 폐 손상: 증례 보고

Thomas J Kwack, MD¹ , Cherry Kim, MD^{1*} , Sung Ho Hwang, MD² ,
Hwan Seok Yong, MD³ , Yu-Whan Oh, MD² , Eun-Young Kang, MD³ 


¹Department of Radiology, Ansan Hospital, Korea University, Ansan, Korea


²Department of Radiology, Anam Hospital, Korea University, Seoul, Korea


³Department of Radiology, Guro Hospital, Korea University, Seoul, Korea


ORCID iDs

Thomas J Kwack  <https://orcid.org/0000-0003-4804-3600>

Cherry Kim  <https://orcid.org/0000-0002-3361-5496>

Sung Ho Hwang  <https://orcid.org/0000-0003-1850-0751>

Hwan Seok Yong  <https://orcid.org/0000-0003-0247-8932>

Yu-Whan Oh  <https://orcid.org/0000-0003-2646-0497>

Eun-Young Kang  <https://orcid.org/0000-0002-4848-509X>

Electronic cigarette or vaping-associated lung injury (EVALI) is a disease defined by lung injuries caused by e-cigarette use. It predominantly manifests in forms of organized pneumonia or diffuse alveolar damage but rarely as acute eosinophilic pneumonia (AEP). This report describes a 34-year-old male with acute respiratory symptoms and a vaping history of only nicotine. Chest CT revealed peripheral distributing multiple patchy consolidations and ground-glass opacities dominant in both lower lobes, bilateral diffuse interlobular septal thickening, and bilateral pleural effusion without cardiomegaly. Bronchoalveolar lavage fluids showed increased eosinophilia levels, while infectious laboratory results were all negative, enabling the diagnosis of both AEP and EVALI. Herein, we report a rare case of only-nicotine vaping EVALI manifested as AEP.

Index terms Electronic Cigarette; Lung Injury; Vaping; E-Cigarette Vapor; Eosinophilic Pneumonia

Received January 3, 2022

Revised May 19, 2022

Accepted June 18, 2022

*Corresponding author

Cherry Kim, MD

Department of Radiology,
Ansan Hospital, Korea University,
123 Jeokgeum-ro, Danwon-gu,
Ansan 15355, Korea.

Tel 82-31-412-5229

Fax 82-31-412-4264

E-mail cherrykim0505@gmail.com

This is an Open Access article distributed under the terms of the Creative Commons Attribution Non-Commercial License (<https://creativecommons.org/licenses/by-nc/4.0>) which permits unrestricted non-commercial use, distribution, and reproduction in any medium, provided the original work is properly cited.

INTRODUCTION

Electronic cigarette or vaping-associated lung injury (EVALI) is a disease consisted of lung injuries caused by electronic cigarettes (e-cigarettes). E-cigarettes use a battery powered heating element to vaporize substances, such as liquid nicotine, instead of burning tobacco. The usage of e-cigarettes continues to grow expecting to be a less harmful alternative to conventional cigarettes and an easier way to smoke marijuana or tetrahydrocannabinol (THC) derivatives. The usage of e-cigarettes has also increased in the Korean population, leading to the first Korean case report of EVALI (1). THC derivatives and nicotine are reported as major causative substances of EVALI, respectively reported to be associated with 86% and 64% of cases (2). Our case was considered of nicotine induced EVALI, since THC derivatives are banned in South Korea and the patient denied using them. Due to the unknown cause and nonspecific symptoms, EVALI is a diagnosis of exclusion, made when satisfying the following: use of an e-cigarette or vaping in 90 days before symptom onset, pulmonary infiltrate on chest radiography or chest CT and with the absence of an alternative plausible diagnoses, such as infection. In addition, acute eosinophilic pneumonia (AEP) can also be suspected based on abnormal radiographic findings and eosinophilic lab results. The case patient fulfilled the criteria for both EVALI and AEP, allowing us to present a rare case of only-nicotine vaping EVALI manifested as AEP.

CASE REPORT

A 34-year-old male transferred from an outside hospital presented to the emergency department with dyspnea, mild fever, and myalgia. Pulse oximetry showed an O₂ saturation of 85% at room air, which increased to 95% with the application of 4 L/min O₂ by nasal cannula. On the initial chest radiograph, diffuse ill-defined haziness with multifocal Kerley B lines was observed in both lungs, especially in both lower lobes. Bilateral pleural effusion was also seen (Fig. 1A).

On the chest CT, multiple patchy consolidations with a lower lobe predominance and peripheral distribution were demonstrated in both lungs. In addition, ill-defined ground-glass opacities and diffuse interlobular septal thickening were seen in both lungs, especially in the basal segments. Small amount of pericardial effusion and bilateral pleural effusion was present as well (Fig. 1B). Initial lab results revealed elevated erythrocyte sedimentation rate (26 mm/hr), C-reactive protein (20.570 mg/dL) levels, and leukocytosis ($21.59 \times 10^3/uL$), while the eosinophil ratio (1.7%) was within normal limits. Our first impression from the imaging and lab findings were viral pneumonia, coronavirus disease 2019 (COVID-19) pneumonia, or interstitial pneumonia such as scrub typhus. Cryptogenic organizing pneumonia and AEP were also possible differential diagnoses.

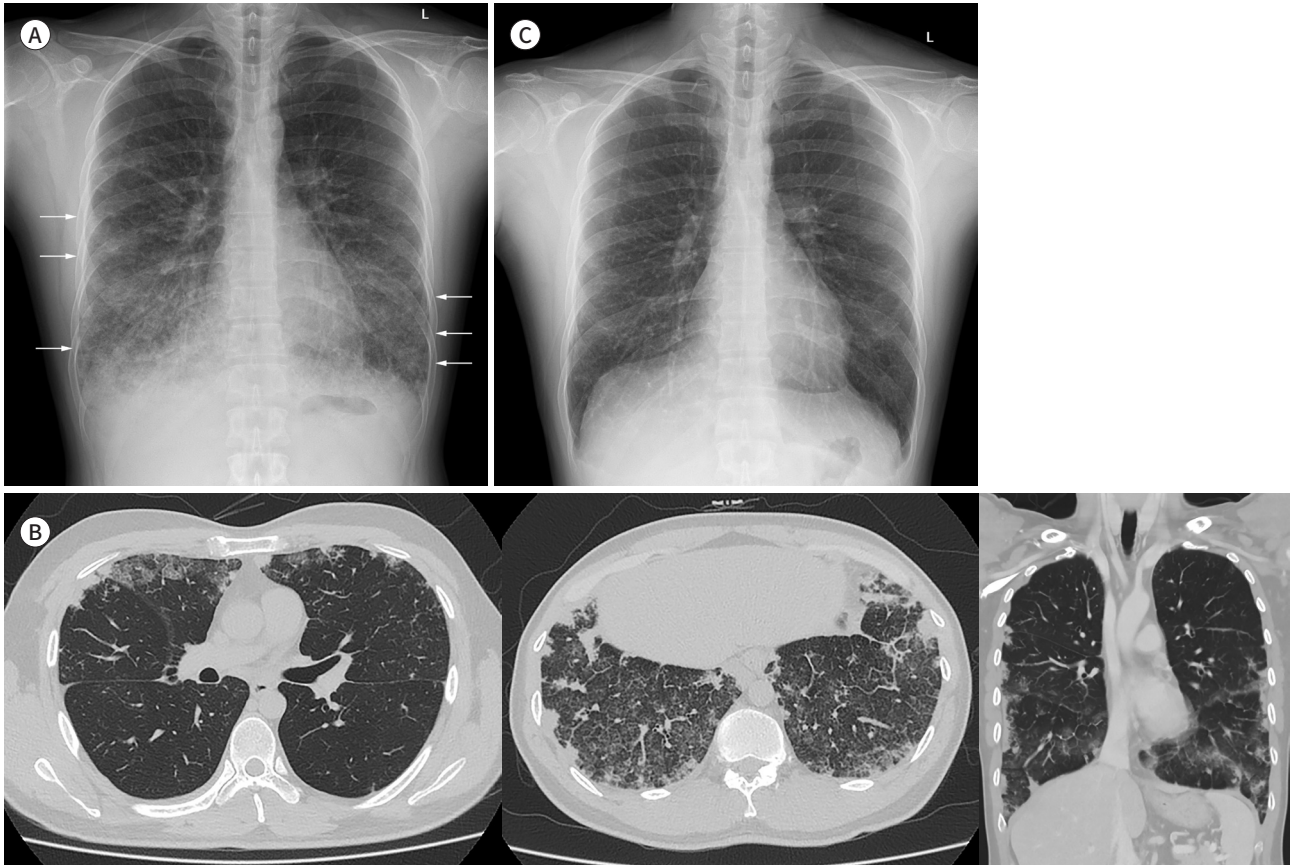
Follow-up peripheral blood eosinophil levels, apprehended four days later, were elevated (9.7%). Additional bronchoscopy showed no endobronchial lesion, however, bronchoalveolar lavage (BAL) fluids revealed increased eosinophil ratio (79%) levels, suggesting the possibility of eosinophil related lung disease. Additional culture and infectious lab results were negative for infectious causes, such as COVID-19, tuberculosis, scrub typhus, and other infectious pathogens.

Fig. 1. A 34-year-old male presenting with electronic cigarette or vaping-associated lung injury with acute eosinophilic pneumonia.

A. Initial chest radiograph shows diffuse ill-defined haziness with multifocal Kerley B lines (arrows) in both lungs, especially in both lower lobes, and bilateral pleural effusion is observed without cardiomegaly.

B. Axial and coronal CT images (mid-lung axial, lower-lung axial, and coronal views respectively) demonstrate multiple patchy consolidations, ill-defined ground-glass opacities and diffuse interlobular septal thickening in both lungs with lower lobe predominance and peripheral distribution. Small amount of pericardial effusion (not shown) and bilateral pleural effusion was present as well.

C. Follow-up chest radiograph, which was taken after two weeks of steroid therapy and cessation of vaping, demonstrates significant improvement of previous bilateral haziness, Kerley B lines and bilateral pleural effusion.



With a careful and more thorough history, the patient revealed to be a 14 pack-year smoker and used vaping e-cigarettes. Other than vaping 5 cc of nicotine a day, he denied usage of different substances such as THC. With the initiation of steroid treatment and cessation of vaping, the patient's diffuse ill-defined bilateral haziness decreased on follow-up chest radiographs (Fig. 1C). After three months of steroid treatment and then tapering, the patient did not show signs nor symptoms of relapse. By the proposed diagnostic criteria, we were able to make a final diagnosis of only-nicotine vaping EVALI manifested as AEP.

This study was approved by the Institutional Review Board of our institution and the requirement for informed consent was waived (IRB No. 2021AS0375).

DISCUSSION

EVALI is a disease consisted of lung injuries caused by e-cigarettes. It is characterized pri-

marily by acute lung injury consisting of histopathologic and imaging patterns of organized pneumonia (OP) (3). From a clinical standpoint, EVALI mostly manifests as a relatively acute disease that mimics viral infection. The Centers for Disease Control and Prevention (CDC) report of 323 EVALI patients showed that 95% had respiratory symptoms, 77% had gastrointestinal symptoms, and 85% had constitutional symptoms (4). Due to these non-specific symptoms, patients are often mistaken to have an infection. Therefore, EVALI is currently a diagnosis of exclusion. Other potential causes, such as infections, toxin exposures, malignancy, and autoimmune disease need to be excluded, while other criteria need to include a history of vaping within 90 days from the onset of symptoms and abnormality in chest radiographs (4, 5).

There are six imaging patterns of EVALI: parenchymal OP, airway-centered OP, mixed OP, diffuse alveolar damage (DAD), AEP, and diffuse alveolar hemorrhage (3). In most cases, both imaging and pathologic findings are OP, while AEP is rare (3). The occurrence of AEP in EVALI is no surprise, for AEP is highly associated with patients who have started smoking or have changed their smoking habits (6, 7). AEP is an acute lung injury that manifests as a combination of DAD with infiltration of eosinophils in the interstitium and alveoli. Eosinophilic degranulation increases vascular permeability and causes edema within alveolar spaces, alveolar walls, and interstitium. Therefore, a differential diagnosis is needed between AEP and pulmonary edema when there are findings of pleural effusion and prominent septal thickening, in the absence of left heart dysfunction (3). At chest CT, AEP usually manifests as bilateral symmetric ground-glass opacities or consolidations, and can have similar imaging to DAD and OP. AEP can be difficult to diagnose at presentation because peripheral eosinophilia is often initially absent. The disease can be confirmed when the following clinical criteria are met: duration of acute febrile illness of fewer than 5 days, progression to hypoxemic respiratory failure, abnormal finding at chest imaging, BAL eosinophils exceeding 25%, prompt response to steroid therapy, and absence of underlying infection (7). Our patient satisfied all of them, as well as the criteria for EVALI, at the same time.

The pathogenesis of EVALI is unknown. The key risk factor is the use of an e-cigarette or similar product. Although THC-derivatives are the most reported substance related to EVALI and may play a role, other causes need investigation as well. In the CDC report, 86% of EVALI patients used products containing THC, while 34% of patients used products exclusively containing THC. In the same report, 64% of patients used products containing nicotine, likewise our case (2). Another study compared BAL fluids of EVALI patients against a healthy non-vaping/smoking group, and 64% of the patient group had nicotine or its metabolites in BAL fluids, while none in the healthy counterpart, suggesting the causative effect of nicotine in EVALI (8).

A large case series of EVALI, consisted with a cohort of 98 patients, 26 BAL specimens with reported cell counts were obtained and the median eosinophil count was 1% (range 0%–18%) (4). Another recent multicenter cohort with 160 patients, had 6 cases with AEP-like patterns (3.8%). Of the 6 cases, only 4 underwent bronchoscopy and none were pathologically confirmed with AEP (3). In a search for AEP confirmed EVALI cases, likewise this one, only 4 previous case reports simultaneously matched the clinical criteria for AEP and EVALI. All of which were discharged healthy after corticosteroid therapy and without relapse. Other smaller case series of EVALI with radiologic pattern classification also revealed low percentages of AEP

pattern findings (7%–8%), however without AEP criteria satisfaction (9, 10).

In summary, we present a rare case of AEP matching the diagnostic criteria for EVALI. With the increased use of e-cigarettes, a careful history of smoking and e-cigarette usage should be taken for patients showing radiologic findings of AEP. As EVALI can be conservatively treated with corticosteroids and vaping cessation, a correct diagnosis can avoid unnecessary procedures.

Author Contributions

Conceptualization, K.C., K.T.J., Y.H.S., O.Y.; data curation, K.C., K.T.J.; formal analysis, K.C., K.T.J.; investigation, K.C., K.T.J.; methodology, K.C., K.T.J., H.S.H., O.Y.; project administration, K.C., K.T.J.; resources, K.C., K.T.J.; supervision, K.C., Y.H.S., K.E.; validation, K.C., H.S.H., O.Y., K.E.; visualization, K.C., K.T.J.; writing—original draft, K.C., K.T.J.; and writing—review & editing, all authors.

Conflicts of Interest

The authors have no potential conflicts of interest to disclose.

Funding

None

REFERENCES

1. Lim J, Nam BD, Hwang JH, Kim YK, Oh E, Lee EJ. Electronic cigarette or vaping product use-associated lung injury: a case report. *J Korean Soc Radiol* 2021;82:1581-1588
2. Moritz ED, Zapata LB, Lekiachvili A, Glidden E, Annor FB, Werner AK, et al. Update: characteristics of patients in a national outbreak of e-cigarette, or vaping, product use-associated lung injuries—United States, October 2019. *MMWR Morb Mortal Wkly Rep* 2019;68:985-989
3. Kligerman SJ, Kay FU, Raptis CA, Henry TS, Sechrist JW, Walker CM, et al. CT findings and patterns of e-cigarette or vaping product use-associated lung injury: a multicenter cohort of 160 cases. *Chest* 2021;160:1492-1511
4. Layden JE, Ghinai I, Pray I, Kimball A, Layer M, Tenforde MW, et al. Pulmonary illness related to e-cigarette use in Illinois and Wisconsin—final report. *N Engl J Med* 2020;382:903-916
5. Schier JG, Meiman JG, Layden J, Mikosz CA, VanFrank B, King BA, et al. Severe pulmonary disease associated with electronic-cigarette-product use—interim guidance. *MMWR Morb Mortal Wkly Rep* 2019;68:787-790
6. Shorr AF, Scoville SL, Cersovsky SB, Shanks GD, Ockenhouse CF, Smoak BL, et al. Acute eosinophilic pneumonia among US military personnel deployed in or near Iraq. *JAMA* 2004;292:2997-3005
7. Uchiyama H, Suda T, Nakamura Y, Shirai M, Gemma H, Shirai T, et al. Alterations in smoking habits are associated with acute eosinophilic pneumonia. *Chest* 2008;133:1174-1180
8. Blount BC, Karwowski MP, Shields PG, Morel-Espinosa M, Valentin-Blasini L, Gardner M, et al. Vitamin E acetate in bronchoalveolar-lavage fluid associated with EVALI. *N Engl J Med* 2020;382:697-705
9. Artunduaga M, Rao D, Friedman J, Kwon JK, Pfeifer CM, Dettori A, et al. Pediatric chest radiographic and CT findings of electronic cigarette or vaping product use-associated lung injury (EVALI). *Radiology* 2020;295:430-438
10. Panse PM, Feller FF, Butt YM, Smith ML, Larsen BT, Tazelaar HD, et al. Radiologic and pathologic correlation in EVALI. *AJR Am J Roentgenol* 2020;215:1057-1064

급성호산구성폐렴으로 발현된 전자담배 관련 폐 손상: 증례 보고

곽정훈¹ · 김채리^{1*} · 황성호² · 용환석³ · 오유환² · 강은영³

전자담배 관련 폐 손상(electronic cigarette or vaping-associated lung injury)은 전자담배에 의해 발생하는 폐 손상으로, 주된 병리 소견은 기질화폐렴 혹은 미만성폐포손상이며 드물게 급성호산구폐렴을 보인다. 본 증례에서 대마 추출물이 없는 니코틴 액상 전자담배 흡연력의 34세 남자 환자가 급성 호흡기 증상, 흉부 CT에서 양측 폐하엽의 주변부의 다발성 경화와 간유리음영, 미만성의 소엽간격막 비후, 흉막삼출을 보였다. 기관지폐포세척액에서는 호산구증이 있었고 감염성 검사들은 모두 음성으로 보였기에 진단기준에 부합하는 급성호산구폐렴으로 발현한 대마 추출물이 없는 니코틴 액상 전자담배 관련 폐 손상의 희귀한 증례를 보고한다.

¹고려대학교 안산병원 영상의학과,

²고려대학교 안암병원 영상의학과,

³고려대학교 구로병원 영상의학과