

후두에서 발생한 유잉육종에 대한 증례보고

김동국 · 이준용 · 강영 · 강승헌

충북대학교 의과대학 이비인후과학교실

A Case of Ewing's Sarcoma Arising from Larynx

Dongkook Kim, MD, Jun-Yong Lee, MD, Young Kang, MD, Seung Heon Kang, MD

*Department of Otorhinolaryngology-Head and Neck Surgery,
Chungbuk National University College of Medicine, Cheongju, Korea*

= Abstract =

Ewing sarcoma is a rare tumor in head and neck area. We demonstrate a rare case of sinonasal Ewing sarcoma initially suspected as olfactory neuroblastoma. After the surgery and immunohistochemical studies, it was accurately diagnosed as Ewing sarcoma. We would like to emphasize the possibility that Ewing sarcoma may originate from the head and neck area, and hence, it is important to use appropriate techniques for accurate diagnosis and treatment.

Key Words : Ewing sarcoma · Exophthalmos · Tumor

Introduction

Ewing's sarcoma, a small round cell tumor, arises from primitive mesenchymal stem cells found in the bone marrow. Typically, this tumor is distinguished by the presence of a fusion transcript involving EWS-FLI1 or EWS-ERG. The lower extremities and pelvis of adolescents are common sites of skeletal origin, and the trunk is the most common extra-skeletal site.¹⁾ It is extremely rare for Ewing's sarcoma to have its primary site in the larynx. To date, only few such cases have been reported.²⁾

Laryngeal cancer accounts for less than 1% of all cancers, and among them, squamous cell carcinoma accounts for

more than 95%.^{2,3)} Laryngeal sarcoma is very rare, accounting for less than 1% of laryngeal cancers, and among its subtypes, chondrosarcoma is much more common than other types.²⁾ As the treatment approach for cancer can vary depending on the stage, complete mass excision through laryngeal microsurgery (LMS) or radiation therapy is a common treatment option for early stage cancer.^{3,4)} The main symptoms in patients with vocal cord lesions are hoarseness or vocal fatigue, and occasionally experience difficulty in breathing. Typically, excisional biopsy via LMS is used for both diagnosis and treatment.⁵⁾

We report a case in which a vocal fold polyp was suspected preoperatively and diagnosed as an extraskeletal Ewing's sarcoma (EES) after surgical resection.

Case report

A 17-year-old man presented to the Department of Otorhinolaryngology with complaints of voice change for a month. The patient did not have any underlying comorbid-

Received: August 15, 2023

Revised: October 19, 2023

Accepted: November 14, 2023

+Corresponding author: Seung Heon Kang, MD

Department of Otorhinolaryngology-Head and Neck Surgery,
Chungbuk National University College of Medicine, 776

1sunhwan-ro, Seowon-gu, Cheongju 28644, Korea

Tel: +82-43-269-8902, Fax: +82-43-269-8902

E-mail: seunghyon.ent@gmail.com

ities and did not present with any other symptoms. The patient was a high school student with no history of voice abuse or misuse, and denied any smoking history.

Laryngoscopy revealed a mass-like lesion in the left vocal folds. A pinkish round mass approximately 1 cm in size was observed anterior to the left vocal fold, which was suspected to be a polyp based on clinical evaluation (Fig. 1). Based on the size of the mass, surgical removal was deemed necessary, and LMS was planned.

Stroboscopy examination and computed tomography (CT) scanning were not performed before surgery.

In the surgical field, we found a soft mass in the left

vocal fold, which was located at the level of the epithelium and demarcated from the surroundings. The mass was dissected from the vocal-fold epithelium using a cold instrument. Because malignancy was not suspected during surgery, the mass was dissected without a safety margin. There were no specific findings in the larynx or hypopharynx except for a vocal fold mass. Following surgery, no residual mass was observed and there were no complications such as bleeding or respiratory distress (Fig. 2).

On histopathological examination, the tumor was 1.2 x 0.9 cm in size, and hematoxylin and eosin staining revealed that the tumor was composed of spindle cells. The resection margin of the tumor was indeterminate in pathologic report. The cells stained positive for CD99 and BCL2 and were focally positive for TLE1 (Fig. 3).

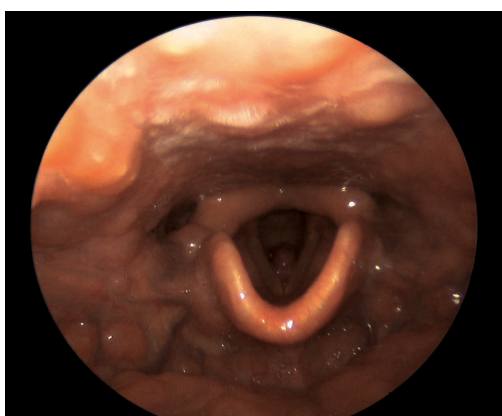

Fig. 1. Preoperative laryngoscope. A round, pinkish mass, approximately 1 cm in size, was observed anterior to the left vocal fold.

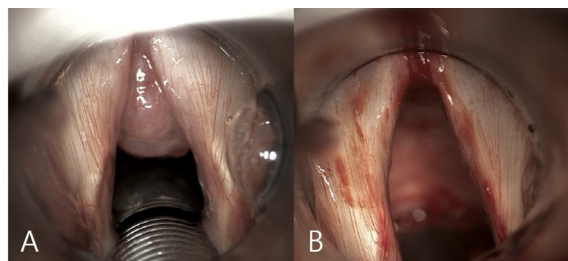


Fig. 2. Laryngeal microsurgery intraoperative microscope image. The mass previously noted on laryngoscopy was attached to the left anterior vocal cord (A), and there was no gross residual tumor after cold knife dissection (B).

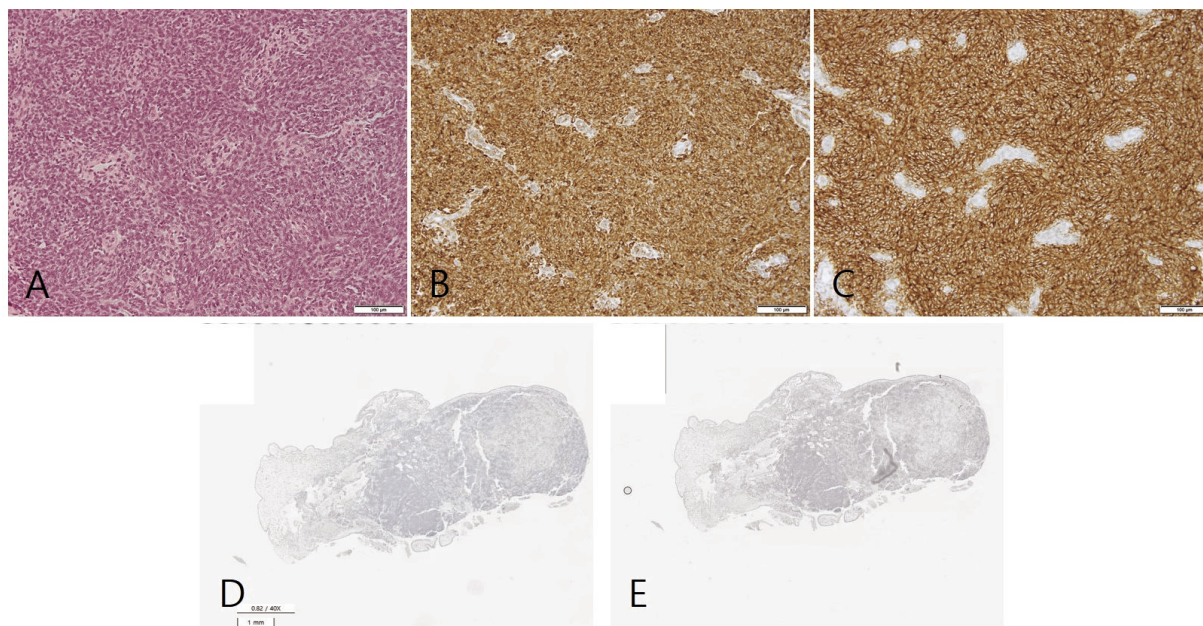


Fig. 3. Microscopic findings. The tumor was composed of oval-to-spindle cells with scant clear-to-eosinophilic cytoplasm and showed a wheel-like growth pattern. Cytoplasmic membranes were indistinct (A, x100, H&E). The tumor cells were positive for Bcl-2 (B, x100) and showed strong diffuse membranous expression of CD99 (C, x100) on immunohistochemical staining. TLE-1 (D) and SS18-SSX (E) were focally positive in the tumor (x40).

Since the tumor was composed of spindle cells that stained positive for CD99 and BCL2 and weakly positive for TLE1 on IHC, we primarily diagnosed it as a synovial sarcoma. However, ultimately TLE1 was interpreted as negative, and an additional test performed on SS18-SSX was negative (Fig. 3). Therefore, we proceeded with next-generation sequencing (NGS) to confirm the presence of the EWSR1-ERG fusion gene, which indicated Ewing's sarcoma.

Postoperative CT scanning and positron emission tomography (PET) were performed and revealed no evidence of locoregional or distant metastases. Adjuvant therapy was necessary after multidisciplinary consultation. The patient underwent chemotherapy (vincristine, doxorubicin, and cyclophosphamide alternating with ifosfamide and etoposide), followed by radiation therapy. The patient has been under 2-year follow-up after treatment, during which there was no evidence of recurrence based on medical history, physical examinations, and imaging studies.

Discussion

Extraskelatal Ewing's sarcoma primarily arising from the head and neck region accounts for approximately 4-9% of all cases, with a predominant report of cases in the nasal cavity, oral cavity, sinuses, or soft tissue of the neck.⁶⁾ Less than 10 cases have been reported to date (Table 1).⁷⁾ These cases showed a generally irregular shape and a pattern of spreading to surrounding tissues.^{2,8,9)}

To diagnose Ewing's sarcoma, it is important to perform a biopsy after clinical suspicion. Histologically, Ewing is characterized by small cells with round nuclei. CD99 is

highly sensitive, but has very low specificity. Synovial sarcoma, rhabdomyosarcoma, and chondrosarcoma are also CD99 positive. Therefore, FLI1, which has a higher specificity, is important. Currently, molecular pathology is essential for diagnosing Ewing's sarcoma, which lacks characteristic features. FISH-based detection of EWSR1 has been used for decades since the introduction of NGS technology, and it has become possible to diagnose Ewing's sarcoma by detecting fusion genes, such as EWSR1-ERG.¹⁰⁾

Ewing's sarcoma of the head and neck is rare; thus, treatment plans are based on cases involving more common sites, such as the lower extremities or pelvis.¹¹⁾ In the case of skeletal Ewing's sarcoma, standard treatment involves multiagent induction chemotherapy followed by local treatment with surgery, definitive radiation, or a combination of surgery and radiation followed by additional chemotherapy and consolidation of local treatment to metastatic sites.¹⁾ It has been reported that the treatment outcomes of head and neck Ewing's sarcoma and skeletal Ewing's sarcoma are similar.¹¹⁾

In our case, the initial impression was a benign vocal fold lesion based on the preoperative laryngoscopy findings; therefore, imaging work-up was not considered prior to surgery, and incidentally, EES was diagnosed after the LMS biopsy. Resection margins were not secured, and adjuvant therapy was administered based on postoperative evaluation and multidisciplinary discussions.

Laryngeal Ewing's sarcoma is a rare cancer, and its diagnosis has been challenging owing to the atypical presentation of reported cases. The current standard treatment of Ewing's sarcoma is neoadjuvant and adjuvant chemo-

Table 1. Summary of published articles on laryngeal wing sarcomas

Outcome	-	Local recurrence	NED	NED	NED	NED	NED
Follow-up (months)	-	-	6	30	-	60	24
Treatment	Total laryngectomy	CTx + laryngectomy	Total laryngectomy + RTx	CTx + RTx	CTx + RTx	LMS + CTx	LMS + CTx + RTx
Size (cm)	1	-	3.5 x 2.0	2.0 x 1.9 x 1.7	2.9	-	1.2 x 0.9
Lesion site	True vocal cord	-	Larynx	True & false vocal cords	True vocal cord	False vocal cord	True vocal cord
Sex / Age	M / 1 day	M / 9 months	M / 74 years	M / 68 years	F / 45 years	F / 33 years	M / 17 years
Reference	Abramowsky and Witt, 1983	Jones and McGill, 1995	Yang and Hong, 2004	Wygoda et al., 2013	Lynch et al., 2014	Ijichi et al., 2016	Current case

CTx = chemotherapy; RTx = radiotherapy; LMS = laryngeal microsurgery; NED = no evidence of disease

therapies in conjunction with surgery and/or radiotherapy to manage the primary site and potential metastatic disease. During surgery, efforts are made to achieve a resection margin, if feasible.¹⁾ In our case, due to the lack of clear margin definition, adjuvant concurrent chemoradiotherapy was administered. As of a 2-year follow-up, the patient remains under surveillance with no evidence of recurrence. We aimed to present this rare case to contribute to the diagnosis and treatment of Ewing's sarcoma in the future, with the hope of providing valuable insights and clinical evidence.

References

- 1) Eaton BR, Claude L, Indelicato DJ, Vatner R, Yeh B, Schwarz R, et al. *Ewing sarcoma. Pediatr Blood Cancer. 2021;68 Suppl 2:e28355.*
- 2) Alhomsy D, Al Asadi H, Alassaf A. *Larynx cancer diagnosed as Ewing Sarcoma in a 41-year-old man: A case report. Ann Med Surg (Lond). 2022;82:104575.*
- 3) Echanique KA, Evans LK, Han AY, Chhetri DK, St John MA. *Cancer of the larynx and hypopharynx. Hematol Oncol Clin North Am. 2021;35:933-947.*
- 4) Baird BJ, Sung CK, Beadle BM, Divi V. *Treatment of early-stage laryngeal cancer: A comparison of treatment options. Oral Oncol. 2018;87:8-16.*
- 5) Vasconcelos D, Gomes AOC, Araujo CMT. *Vocal fold polyps: Literature review. Int Arch Otorhinolaryngol. 2019;23:116-124.*
- 6) Khosla D, Verma S, Punia RS, Dass A, Dimri K, Kaur G, et al. *Extraosseous Ewing's sarcoma of the parapharyngeal space-A rare entity-with review of literature. Iran J Otorhinolaryngol. 2019;31:51-54.*
- 7) Maroun CA, Khalifeh I, Tfayli A, Moukarbel RV. *Primary Ewing sarcoma of the larynx with distant metastasis: A case report and review of the literature. Curr Oncol. 2019;26:e574-e577.*
- 8) Lynch MC, Baker A, Drabick JJ, Williams N, Goldenberg D. *Extraskelatal Ewing's sarcoma arising in the larynx. Head Neck Pathol. 2014;8:225-228.*
- 9) Yang YS, Hong KH. *Extraskelatal Ewing's sarcoma of the larynx. J Laryngol Otol. 2004;118:62-64.*
- 10) Zollner SK, Amatruda JF, Bauer S, Collaud S, de Alava E, DuBois SG, et al. *Ewing sarcoma-diagnosis, treatment, clinical challenges and future perspectives. J Clin Med. 2021;10:1685.*
- 11) Whaley JT, Indelicato DJ, Morris CG, Hinerman RW, Amdur RJ, Mendenhall WM, et al. *Ewing tumors of the head and neck. Am J Clin Oncol. 2010;33:321-326.*