

Effect of cigarette smoking on the maintenance of reduction after treatment of acute acromioclavicular joint dislocation with hook plate fixation

Jee-Hoon Choi¹, Yong-Min Chun², Tae-Hwan Yoon^{1,2}

¹Department of Orthopedic Surgery, Arthroscopy and Joint Research Institute, Gangnam Severance Hospital, Yonsei University College of Medicine, Seoul, Korea

²Department of Orthopedic Surgery, Arthroscopy and Joint Research Institute, Severance Hospital, Yonsei University College of Medicine, Seoul, Korea

Background: The purpose of this study was to determine the association between smoking and clinical outcomes of hook plate fixation for acute acromioclavicular (AC) joint injuries.

Methods: This study retrospectively investigated 82 patients who underwent hook plate fixation for acute AC joint dislocation between March 2014 to June 2022. The patients were grouped by smoking status, with 49 in group N (nonsmokers) and 33 in group S (smokers). Functional scores and active range of motion were compared among the groups at the 1-year follow-up. Coracoclavicular distance (CCD) was measured, and difference with the uninjured side was compared at initial injury and 6 months after implant removal.

Results: No significant differences were observed between the two groups in demographic factors such as age and sex, as well as parameters related to initial injury status, which included time from injury to surgery, the preoperative CCD difference value, and the Rockwood classification. However, the postoperative CCD difference was significantly higher in group S (3.1 ± 2.6 mm) compared to group N (1.7 ± 2.4 mm). Multivariate regression analysis indicated that smoking and the preoperative CCD difference independently contributed to an increase in the postoperative CCD difference. Despite the radiographic differences, the postoperative clinical outcome scores and active range of motion measurements were comparable between the groups.

Conclusions: Smoking had a detrimental impact on ligament healing after hook plate fixation for acute AC joint dislocations. This finding emphasizes the importance of smoking cessation to optimize reduction maintenance after AC joint injury.

Level of evidence: III.

Keywords: Smoking; Acromioclavicular joint injury; Hook plate fixation; Coracoclavicular joint distance

INTRODUCTION

Due to the increasing popularity of recreational activities and sports, the prevalence of acromioclavicular (AC) joint injuries is on the rise [1]. Neglected injuries can lead to chronic pain, insta-

bility, and decline in shoulder function [2,3]. Various surgical approaches including the use of Kirschner wire, hook plate, and cortical button have been employed to stabilize the AC joint [4-7]. Among them, the clavicular hook plate is anatomically contoured to fit the clavicle and features a tapered hook designed to

Received: August 17, 2023 Revised: September 8, 2023 Accepted: September 12, 2023

Correspondence to: Tae-Hwan Yoon

Department of Orthopedic Surgery, Arthroscopy and Joint Research Institute, Gangnam Severance Hospital, Yonsei University College of Medicine, 211 Eonju-ro, Gangnam-gu, Seoul 06273, Korea

Tel: +82-2-2019-3414, E-mail: uvsoul1106@gmail.com, ORCID: <https://orcid.org/0000-0002-2859-5240>

Copyright© 2023 Korean Shoulder and Elbow Society.

This is an Open Access article distributed under the terms of the Creative Commons Attribution Non-Commercial License (<http://creativecommons.org/licenses/by-nc/4.0/>) which permits unrestricted non-commercial use, distribution, and reproduction in any medium, provided the original work is properly cited.

function as a lever beneath the acromion [8]. This lever action depresses the clavicle, promoting healing of the AC and coracoclavicular (CC) ligaments [9].

Although achievement of rigid fixation and early range of motion (ROM) are advantages of hook plate fixation leading to satisfactory clinical results, complications such as subacromial impingement, bony erosion, and peri-implant fracture have been noted [10-13]. As a result of these considerations, the implant is typically removed after 3 to 4 months of initial surgery. Following plate removal, it is common for the CC distance to remain similar to that of the unaffected side. However, in some cases, the CC distance reverts to the height prior to surgery [14-17]. Various reasons can contribute to inadequate healing, including that AC joint injuries predominantly occur in young, active male patients, many of whom are also active smokers [18,19].

Smoking has a detrimental effect on the outcomes of many orthopedic treatments. Among them, procedures requiring ligament and tendon restoration, such as anterior cruciate ligament reconstruction, rotator cuff repair, and lateral ankle ligament reconstruction, have been reported in numerous studies to be adversely affected by smoking [20-24]. Likewise, considering the importance of tendon healing, it is conceivable that smoking may also adversely affect AC joint injuries. However, as of our current understanding, no study has specifically investigated the relationship between smoking and AC joint injuries.

Therefore, the purpose of this study is to determine the association between smoking and clinical outcomes of hook plate fixation for acute AC joint injuries. We hypothesized that smoking would adversely affect AC and CC ligament healing, leading to loss of reduction and unfavorable consequences for patient outcomes.

METHODS

The Institutional Review Board of Severance Hospital at the Yonsei University College of Medicine approved this study (No. 4-2023-0858), and the requirement for informed consent was waived.

This study retrospectively reviewed the data of 112 patients who had undergone hook plate fixation for acute AC joint dislocation at our institution between March 2014 to June 2022. The inclusion criteria were (1) acute Rockwood type III or V AC joint dislocation and (2) minimum 1-year follow-up after the initial surgery. Exclusion criteria were (1) fixation method other than the hook plate, (2) peri-implant complication requiring further surgical intervention such as clavicle fracture, (3) a previous history of surgery on the affected shoulder, (4) concomitant fracture of the ipsilateral shoulder, (5) former smoker (quit smoking be-

fore the surgery or during the follow-up period), and (6) individuals with a worker's compensation claim.

Overall, 82 patients were included in this study (Fig. 1). Smoking status was documented preoperatively at hospitalization and was updated on outpatient visits. Duration and quantity of smoking were obtained, and individuals who had smoked more than 100 cigarettes in their lifetime and currently smoked on a regular basis were defined as "smokers" [25]. "Nonsmokers" were defined as individuals naïve to exposure of tobacco.

Surgical Procedure and Postoperative Rehabilitation

All surgical procedures were performed by two experienced orthopedic surgeons with expertise in shoulder surgery. The surgery was conducted under general anesthesia in the 20° beach chair position. A 7- to 8-cm-sized skin incision was made over the distal clavicle and AC joint, positioned one-fourth of the width from the posterior border of the clavicle. The AC joint was identified, and the hook component was passed through the posterior aspect of the AC joint under the acromion, while the locking plate component was placed on the distal clavicle (3.5 mm LCP clavicle hook plate, Synthes). The plate's contour and reduction status were carefully examined under fluoroscopic guidance. The depth of the hook was determined using the contralateral AC joint radiograph as a reference, and slight over-compression was intended. If there was a sufficient amount of ligament remaining, the ruptured AC ligament was repaired after hook plate fixation. After achieving satisfactory reduction, locking screw fixation and secure deltotracheus fascial repair were performed

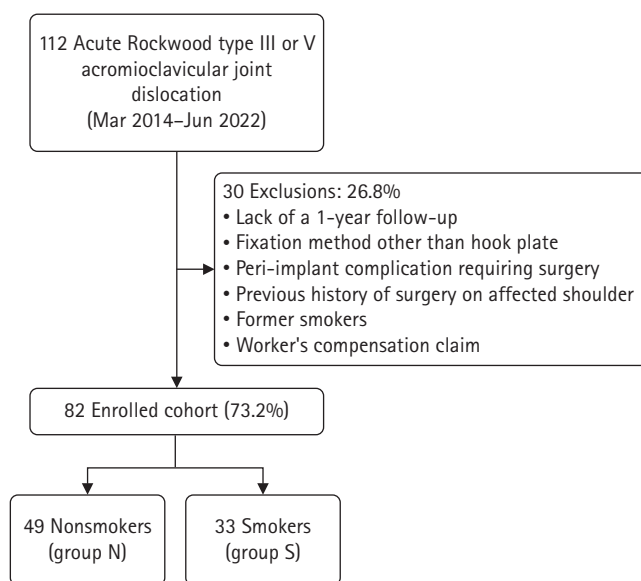


Fig. 1. Consolidated Standards of Reporting Trials (CONSORT) flow diagram presenting the flow of patients across the study.

over the plate. Self-assisted circumduction exercises were initiated the day after surgery, as tolerated. Following 2 weeks of immobilization of the operated arm, self-assisted active ROM exercises were initiated. Radiographic follow-up was conducted on a monthly basis, and plate removal was performed at 3 to 4 months postoperatively.

Clinical and Radiological Assessments

Medical records were reviewed for patient demographics and clinical factors. The demographic factors were age, sex, time from injury to surgery, and duration from hook plate fixation to implant removal. Functional outcomes were evaluated using the visual analog scale and the subjective shoulder value. Active ROM was measured, including forward flexion in the scapular plane, external rotation with the elbow at the side, and internal rotation. Internal rotation was quantified by assigning scores to the highest spinal vertebra level reached by the patient's thumb during internal rotation. T1 to T12 were scored from 1 to 12, L1–L5 were scored from 13 to 17, and the sacrum was scored 18 [26–28]. The active ROM and functional scores were assessed during every follow-up by an independent examiner who was blinded to group assignment and patient information.

Both clavicle anteroposterior views were acquired preoperatively and then monthly after surgery. Initial radiographs were used for measuring the coracoclavicular distance (CCD) and classifying the patients according to the Rockwood classification.

The CCD was defined as the perpendicular distance from the highest point of the coracoid cortex to the lower margin of the clavicle cortex. The CCD was assessed in comparison with the contralateral shoulder 6 months after implant removal to ascertain the extent of reduction maintenance (Fig. 2). Two shoulder-specialized orthopedic fellows participated in the CCD measurement, and the mean values were subjected to analysis.

Statistical Analysis

Statistical analyses were performed using SPSS software ver. 25.0 (IBM Corp.). Student t-test was used to compare continuous variables between the groups, and chi-square test was used for categorical values. Reduction maintenance status according to CCD difference was determined, and univariate regression analysis was performed. Variables with statistically significant differences were subjected to multivariate regression analysis via a stepwise method. A significance level of $P < 0.05$ was used with a 95% confidence interval.

RESULTS

Patient Demographics

A total of 82 individuals was enrolled in the study, 49 in group N (nonsmokers) and 33 in group S (smokers), with an average smoking history of 17.6 ± 15.9 pack-years for the smokers. There were no significant differences between the two groups in terms of

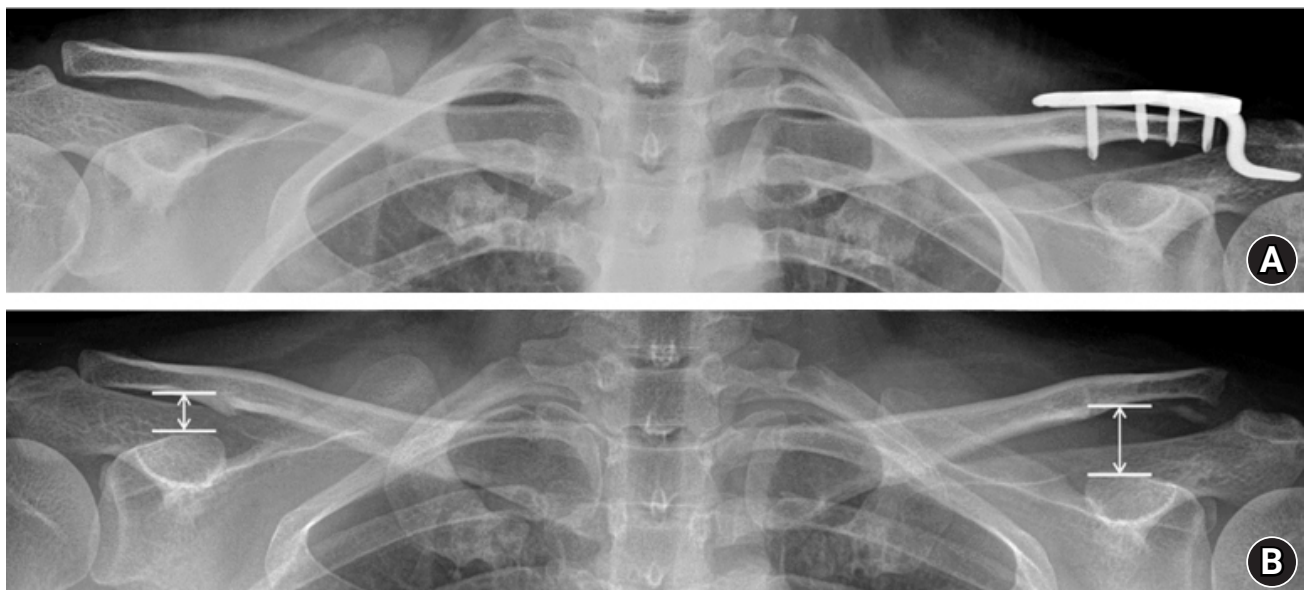


Fig. 2. Anteroposterior radiograph of a patient treated with hook plate fixation for an acromioclavicular joint injury. (A) Hook plate fixation with intentional over reduction. (B) Six months after implant removal. The coracoclavicular distance was defined as the perpendicular distance from the highest point of the coracoid cortex to the lower margin of the clavicle cortex.

demographic factors, including age, sex, time from injury to surgery, and duration from hook plate fixation to implant removal.

Clinical and Radiological Outcomes

There were no notable differences in the parameters related to initial injury status such as the preoperative CCD difference and the Rockwood classification. However, the postoperative CCD difference (the CCD difference at 6 months after plate removal) was significantly higher in group S (3.1 ± 2.6 mm) compared to group N (1.7 ± 2.4 mm) (Table 1). No discernible difference in the clinical scores and active ROM were discovered between the two groups, except for internal rotation (Table 2). Univariate regression analysis was conducted using the postoperative CCD difference as the dependent variable, and smoking status and preoperative CCD difference were identified as the significant factors. Furthermore, as confirmed by multivariate regression analysis, both factors independently influenced the postoperative CCD difference (Table 3). Among the patients in group S, two

experienced chronic pain associated with reduction loss and underwent CC ligament reconstruction.

DISCUSSION

The primary finding of this study is that smoking has a detrimental effect on ligament healing in patients with acute AC injury. Despite differences in radiographic parameters, the two groups exhibited comparable patient-reported clinical outcome scores and ROM. Furthermore, regression analysis established smoking and the initial CCD difference as independent risk factors for increase in the postoperative CCD difference.

Hook plate fixation has been recognized as a straightforward procedure with satisfactory clinical outcomes for treating acute AC joint dislocation [17,29]. Ko et al. [30] conducted a long-term outcome comparison between hook plate fixation and the suture button fixation technique. The study did not find significant differences in terms of functional outcome scores, final CCD, or

Table 1. Demographic characteristics

Variable	Nonsmoker (n = 49)	Smoker (n = 33)	P-value
Age (yr)	42.9 ± 15.9	38.9 ± 13.3	0.241
Sex			0.991
Male	46 (93.8)	31 (94.0)	
Female	3 (6.2)	2 (6.0)	
Rockwood classification			0.499
III	26 (53.1)	15 (45.5)	
V	23 (46.9)	18 (54.5)	
Time from injury to operation (day)	5.6 ± 4.7	5.0 ± 3.7	0.535
Time to implant removal (day)	114.5 ± 22.4	120.7 ± 45.1	0.415
Acromioclavicular ligament repair	9 (52.9)	8 (47.1)	0.520
Preoperative CCD difference (mm)	9.6 ± 3.1	9.7 ± 2.7	0.800
Postoperative CCD difference (mm)	1.7 ± 2.4	3.1 ± 2.6	0.017

Values are presented as mean ± standard deviation or number (%).

CCD: coracoclavicular distance, CCD preoperative: measured on plain radiographs of initial injury, CCD postoperative: measured on plain radiographs 6 months after plate removal.

Table 2. Functional scores and active range of motion between groups

Variable	Nonsmoker (n = 49)	Smoker (n = 33)	P-value
VAS score	1.57 ± 0.74	1.88 ± 0.96	0.111
SSV score	85.31 ± 7.93	81.82 ± 9.83	0.080
Forward flexion	150.71 ± 8.84	147.61 ± 9.90	0.141
External rotation	57.96 ± 4.07	56.36 ± 4.89	0.127
Internal rotation	14.10 ± 1.28	14.70 ± 1.13	0.034*

Values are presented as mean ± standard deviation. The internal rotation was measured using the highest spinal segment the patient could reach with his or her thumb up. To facilitate statistical analysis, the spinal segment levels were converted into continuous numbers: T1 to T12 were designated as 1 to 12; L1 to L5, as 13 to 17; and the sacrum, as 18.

VAS: visual analog scale, SSV: subjective shoulder value.

*Indicates $P < 0.05$.

Table 3. Uni- and multivariable regression analysis of postoperative CCD in the affected shoulder

Variable	Univariable beta coefficient	95% CI		P-value	Multivariable beta coefficient	95% CI		P-value
		Lower	Upper			Lower	Upper	
Smoking								
Nonsmoker	Ref							
Smoker	1.377	0.258	2.496	0.017*	1.296	0.364	2.228	0.007*
Sex								
Male	Ref							
Female	-0.073	-2.450	2.305	0.952				
Age	-0.033	-0.071	0.004	0.083				
Preoperative CCD difference	0.485	0.321	0.649	< 0.001*	0.479	0.321	0.636	< 0.001*
Time from injury to operation	0.026	-0.108	0.160	0.698				
Time to implant removal	0.003	-0.014	0.020	0.748				

CCD: coracoclavicular distance, CI: confidence interval, Ref: reference.

*Indicates $P < 0.05$.

complications between the two treatment groups. Therefore, both treatments were concluded to be viable and effective options for addressing AC joint dislocation. Suture button fixation does not require a second surgery for device removal, and the retained suture loop prevents further displacement, facilitating ligament healing over a longer period of time. On the contrary, for hook plate fixation, removal is necessary, which emphasizes the importance of achieving satisfactory ligament healing before plate removal. Unlike degenerative shoulder conditions such as rotator cuff tears, AC joint injuries are common among young, active male patients with a high prevalence of smoking, as evidenced by our cohort, where smoking was observed in 36% of the cases [18,19]. While smoking is well known to adversely affect ligament healing [31,32], the specific impact of smoking on healing of the ligaments after hook plate fixation for AC joint injury remains uncertain. For this reason, we initiated this study.

Reduction loss associated after hook plate removal has been reported in the literature. In a recent retrospective study of 118 patients by Lee et al. [33], risk factors for reduction loss after hook plate fixation were identified as female sex, delayed time to surgery (>7 days), and the initial coracoid clavicular displacement ratio. The initial CCD reflects the degree of damage to the soft tissue surrounding the AC joint and was found to affect reduction loss, aligning with our results. On the other hand, the duration to surgery and female sex did not significantly affect the postoperative CCD difference in our cohort. This may be because most patients (80.4%) underwent treatment within 1 week, and only five female patients were enrolled, attenuating the impact on the outcome.

Our study is focused on establishing the effect of smoking on the outcome of hook plate fixation, and we observed an increase in the postoperative CCD difference related to smoking. Smoking

is recognized for its adverse impact on the outcomes of orthopedic procedures involving ligament healing. Unfavorable outcomes, such as increased anterior translation, as well as significantly low subjective and objective clinical scores, have been found to be related to smoking in anterior cruciate ligament reconstruction [20]. Park et al. [23] performed a propensity score matched analysis to determine the effect of smoking on healing of rotator cuff tears after arthroscopic repair. They noted higher retear rates in smokers (29.4%) compared to nonsmokers (5.9%), confirming the association between smoking and compromised rotator cuff healing. Studies have shown that smoking hinders normal regeneration of musculoskeletal tissue, impairing microvascular flow and disrupting the balance of bone and collagen metabolism [34,35]. Nicotine, the main component of tobacco, impedes cell proliferation, vascular ingrowth, and collagen formation [32,36,37]. Additionally, carbon monoxide and hydrogen cyanide, along with nicotine-induced vasoconstriction, further contribute to tissue hypoxia and delay the healing process [38,39]. Based on these research findings, it is essential to emphasize the importance of smoking cessation to patients considering hook plate fixation for acute AC joint injuries.

In the current study, smoking status did not result in a statistically significant difference in clinical outcomes, such as ROM and functional score, except internal rotation. Smoking is recognized for its potential to cause synovial inflammation and contributes to the onset of stiff shoulder, which can explain the difficulty in internal rotation according to our study [40]. Although our findings are based on a short-term follow-up period, the negative effect of smoking on radiographic CCD maintenance did not lead to discernible differences in clinical outcomes. Furthermore, considering that one point in internal rotation scoring is equivalent to the height of one vertebral body, the actual clinical

cal significance may not be substantial. Similarly, the findings of Lee et al. [33] acknowledge that the loss of reduction did not exert a significant influence on short-term clinical outcomes during the 1-year follow-up. Nevertheless, two patients in the smoker group required additional CC ligament reconstruction due to chronic pain, and different conclusions may arise from longer-term studies.

There were several limitations to this study. First, it was a retrospective study with non-randomized patient assignment, which had the potential for selection bias. Second, the study was conducted with a small sample size. Conducting a multi-center study with a larger number of patients will likely provide more precise insights into the risk factors contributing to the reduction loss. Finally, the exact CCD measurement may have varied on the plain radiographs depending on the observers and the angles of radiograph acquisition.

CONCLUSIONS

Smoking was found to have a detrimental impact on ligament healing after hook plate fixation for acute AC joint dislocations. This finding emphasizes the importance of smoking cessation to optimize reduction maintenance after AC joint injury.

NOTES

ORCID

Jee-Hoon Choi <https://orcid.org/0000-0002-6732-9738>
 Yong-Min Chun <https://orcid.org/0000-0002-8147-6136>
 Tae-Hwan Yoon <https://orcid.org/0000-0002-2859-5240>

Author contributions

Conceptualization: THY. Data curation: YMC, THY. Formal Analysis: THY. Investigation: THY. Methodology: JHC, THY. Project administration: THY. Resources: THY. Software: THY. Supervision: YMC, THY. Validation: JHC, THY. Visualization: JHC, THY. Writing – original draft: JHC, THY. Writing – review & editing: THY.

Conflict of interest

Yong-Min Chun is an editorial board member of the journal but was not involved in the peer reviewer selection, evaluation, or decision process of this article. No other potential conflict of interest relevant to this article was reported.

Funding

None.

Data availability

Contact the corresponding author for data availability.

Acknowledgments

None.

REFERENCES

1. Nordin JS, Olsson O, Lunsjö K. Acromioclavicular joint dislocations: incidence, injury profile, and patient characteristics from a prospective case series. *JSES Int* 2020;4:246–50.
2. Barth J, Duparc F, Baverel L, et al. Prognostic factors to succeed in surgical treatment of chronic acromioclavicular dislocations. *Orthop Traumatol Surg Res* 2015;101(8 Suppl):S305–11.
3. Cisneros LN, Reiriz JS. Management of chronic unstable acromioclavicular joint injuries. *J Orthop Traumatol* 2017;18:305–18.
4. Beitzel K, Cote MP, Apostolakos J, et al. Current concepts in the treatment of acromioclavicular joint dislocations. *Arthroscopy* 2013;29:387–97.
5. DeBerardino TM, Pensak MJ, Ferreira J, Mazzocca AD. Arthroscopic stabilization of acromioclavicular joint dislocation using the AC graftrope system. *J Shoulder Elbow Surg* 2010;19(2 Suppl):47–52.
6. Tauber M. Management of acute acromioclavicular joint dislocations: current concepts. *Arch Orthop Trauma Surg* 2013;133:985–95.
7. Mazzocca AD, Arciero RA, Bicos J. Evaluation and treatment of acromioclavicular joint injuries. *Am J Sports Med* 2007;35:316–29.
8. Faraj AA, Ketzner B. The use of a hook-plate in the management of acromioclavicular injuries: report of ten cases. *Acta Orthop Belg* 2001;67:448–51.
9. Kashii M, Inui H, Yamamoto K. Surgical treatment of distal clavicle fractures using the clavicular hook plate. *Clin Orthop Relat Res* 2006;447:158–64.
10. Chaudry SN, Waseem M. Clavicular hook plate: complications of retaining the implant. *Injury* 2006;37:665.
11. Chiang CL, Yang SW, Tsai MY, Kuen-Huang Chen C. Acromion osteolysis and fracture after hook plate fixation for acromioclavicular joint dislocation: a case report. *J Shoulder Elbow Surg* 2010;19:e13–5.
12. Ding M, Ni J, Hu J, Song D. Rare complication of clavicular hook plate: clavicle fracture at the medial end of the plate. *J Shoulder Elbow Surg* 2011;20:e18–20.
13. Hoffler CE, Karas SG. Transacromial erosion of a locked subacromial hook plate: case report and review of literature. *J*

- Shoulder Elbow Surg 2010;19:e12-5.
14. Weinstein DM, McCann PD, McIlveen SJ, Flatow EL, Bigliani LU. Surgical treatment of complete acromioclavicular dislocations. *Am J Sports Med* 1995;23:324-31.
 15. Ejam S, Lind T, Falkenberg B. Surgical treatment of acute and chronic acromioclavicular dislocation Tossy type III and V using the hook plate. *Acta Orthop Belg* 2008;74:441-5.
 16. Hemmann P, Koch M, Gühring M, Bahrs C, Ziegler P. Acromioclavicular joint separation treated with clavicular hook plate: a study of radiological and functional outcomes. *Arch Orthop Trauma Surg* 2021;141:603-10.
 17. Kienast B, Thietje R, Queitsch C, Gille J, Schulz AP, Meiners J. Mid-term results after operative treatment of rockwood grade III-V acromioclavicular joint dislocations with an AC-hook-plate. *Eur J Med Res* 2011;16:52-6.
 18. Fraser-Moodie JA, Shortt NL, Robinson CM. Injuries to the acromioclavicular joint. *J Bone Joint Surg Br* 2008;90:697-707.
 19. Pallis M, Cameron KL, Svoboda SJ, Owens BD. Epidemiology of acromioclavicular joint injury in young athletes. *Am J Sports Med* 2012;40:2072-7.
 20. Kim SJ, Lee SK, Kim SH, Kim SH, Ryu SW, Jung M. Effect of cigarette smoking on the clinical outcomes of ACL reconstruction. *J Bone Joint Surg Am* 2014;96:1007-13.
 21. Karim A, Pandit H, Murray J, Wandless F, Thomas NP. Smoking and reconstruction of the anterior cruciate ligament. *J Bone Joint Surg Br* 2006;88:1027-31.
 22. Bishop JY, Santiago-Torres JE, Rimmke N, Flanigan DC. Smoking predisposes to rotator cuff pathology and shoulder dysfunction: a systematic review. *Arthroscopy* 2015;31:1598-605.
 23. Park JH, Oh KS, Kim TM, et al. Effect of smoking on healing failure after rotator cuff repair. *Am J Sports Med* 2018;46:2960-8.
 24. Lee DO, Eom JS, Jung HG. The effect of smoking on the outcomes of lateral ankle ligament reconstruction. *J Orthop Sci* 2018;23:88-91.
 25. Bondy SJ, Victor JC, Diemert LM. Origin and use of the 100 cigarette criterion in tobacco surveys. *Tob Control* 2009;18:317-23.
 26. Kim SJ, Choi YR, Jung M, Lee W, Chun YM. Arthroscopic repair of anterosuperior massive rotator cuff tears: does repair integrity affect outcomes. *Am J Sports Med* 2017;45:1762-8.
 27. Yoon JS, Kim SJ, Choi YR, Kim SH, Chun YM. Arthroscopic repair of the isolated subscapularis full-thickness tear: single- versus double-row suture-bridge technique. *Am J Sports Med* 2019;47:1427-33.
 28. Oh JH, Kim SH, Kwak SH, Oh CH, Gong HS. Results of concomitant rotator cuff and SLAP repair are not affected by unhealed SLAP lesion. *J Shoulder Elbow Surg* 2011;20:138-45.
 29. Oh JH, Min S, Jung JW, et al. Clinical and radiological results of hook plate fixation in acute acromioclavicular joint dislocations and distal clavicle fractures. *Clin Shoulder Elb* 2018;21:95-100.
 30. Ko SH, Lee CC, Jeon YD, Han JW, Lee KJ. Long-term clinical outcomes after tightrope versus hook plate fixation for acute acromioclavicular joint dislocation. *Orthop J Sports Med* 2023;11:23259671231165097.
 31. Kanneganti P, Harris JD, Brophy RH, Carey JL, Lattermann C, Flanigan DC. The effect of smoking on ligament and cartilage surgery in the knee: a systematic review. *Am J Sports Med* 2012;40:2872-8.
 32. Galatz LM, Silva MJ, Rothermich SY, Zaegel MA, Havlioglu N, Thomopoulos S. Nicotine delays tendon-to-bone healing in a rat shoulder model. *J Bone Joint Surg Am* 2006;88:2027-34.
 33. Lee YS, Kim DS, Jung JW, Jo YH, Lee CH, Lee BG. Risk factors of loss of reduction after acromioclavicular joint dislocation treated with a hook plate. *J Orthop Traumatol* 2023;24:10.
 34. Argintar E, Triantafyllou K, Delahay J, Wiesel B. The musculoskeletal effects of perioperative smoking. *J Am Acad Orthop Surg* 2012;20:359-63.
 35. Lee JJ, Patel R, Biermann JS, Dougherty PJ. The musculoskeletal effects of cigarette smoking. *J Bone Joint Surg Am* 2013;95:850-9.
 36. Xanthoulea S, Deliaert A, Romano A, Rensen SS, Buurman WA, van der Hulst RR. Nicotine effect on inflammatory and growth factor responses in murine cutaneous wound healing. *Int Immunopharmacol* 2013;17:1155-64.
 37. Lundgreen K, Lian OB, Scott A, Nassab P, Fearon A, Engebretsen L. Rotator cuff tear degeneration and cell apoptosis in smokers versus nonsmokers. *Arthroscopy* 2014;30:936-41.
 38. Jensen JA, Goodson WH, Hopf HW, Hunt TK. Cigarette smoking decreases tissue oxygen. *Arch Surg* 1991;126:1131-4.
 39. Whiteford L. Nicotine, CO and HCN: the detrimental effects of smoking on wound healing. *Br J Community Nurs* 2003;8:S22-6.
 40. Itoi E, Arce G, Bain GI, et al. Shoulder stiffness: current concepts and concerns. *Arthroscopy* 2016;32:1402-14.