








Penetrating chest trauma from a “less lethal” bean bag in the United States: a case report

Gloria Sanin, MD , Gabriel Cambroner, MD , Megan E. Lundy, MD , William T. Terzian, MD , Martin D. Avery, MD , Samuel P. Carmichael II, MD , Maggie Bosley, MD 

Atrium Health Wake Forest Baptist Medical Center, Winston-Salem, NC, USA

This case report presents the case of a 49-year-old man who presented to our level I trauma center after sustaining injuries in an altercation with local law enforcement in which he was shot with a less lethal bean bag and tased. In a primary survey, a penetrating left supraclavicular wound was noted in addition to a taser dart lodged in his flank. No other traumatic findings were noted in a secondary survey. Given hemodynamic stability, completion imaging was obtained, revealing a foreign body in the left lung, a left open clavicle fracture, a C5 tubercle fracture, a possible grade I left vertebral injury, and a left first rib fracture. Soft tissue gas was seen around the left subclavian and axillary arteries, although no definitive arterial injury was identified. The bean bag projectile was embedded in the parenchyma of the left lung on cross-sectional imaging. The patient underwent thoracotomy for removal of the projectile and hemostasis. A thoracotomy was chosen as the operative approach due to concerns about significant bleeding upon foreign body removal. A chest tube was placed and subsequently removed on postoperative day 5. The patient was discharged on postoperative day 7. At a 2-week outpatient follow-up visit, the patient was doing well. This case report is the first to describe this outcome for a drag-stabilized bean bag. Although law enforcement officers utilize bean bag projectiles as a “less lethal” means of crowd control and protection, these ballistics pose significant risk and can result in serious injury.

Received: April 7, 2023
Revised: May 23, 2023
Accepted: May 30, 2023

Correspondence to

Gloria Sanin, MD
Atrium Health Wake Forest Baptist
Medical Center, 1 Medical Center Blvd,
Winston-Salem, NC 27157, USA
Tel: +1-678-642-9231
Email: gsanin@wakehealth.edu

Keywords: Ballistic injury; Wounds and injuries; Bean bag injury; Case reports

INTRODUCTION

This is the first case report highlighting the management of a trauma patient who sustained a significant impact and resultant trauma from a bean bag. Given the significant trauma from the ballistic, the patient required a thoracotomy for definitive management to prevent future infectious complications or erosion into surrounding structures. To our knowledge, this is the first

case report describing this outcome for a drag-stabilized bean bag.

CASE REPORT

A 49-year-old man with no significant past medical history presented to our level I trauma center (Atrium Health Wake Forest Baptist, Winston-Salem, NC, USA) after sustaining injuries in an

altercation with local law enforcement in which he was shot with a “less lethal” bean bag and tased. Upon arrival, a primary survey revealed an intact airway, bilateral breath sounds, and a normotensive blood pressure. His Glasgow Coma Scale score was 13, and exposure revealed a penetrating left supraclavicular wound in addition to a taser dart lodged in his flank. A chest x-ray examination in the trauma bay showed a penetrating injury to the left upper chest, with the bean bag projectile retained in the left upper lobe and associated pulmonary contusion. No hemothorax or pneumothorax was noted. After a secondary survey was performed, showing no other traumatic injuries, completion imaging was obtained, revealing a foreign body in the left lung (Fig. 1) superiorly abutting the hilar vessels, left open clavicle fracture, a C5 tubercle fracture, possible grade 1 left vertebral injury and a left first rib fracture. Soft tissue gas was seen around the left subclavian and axillary arteries, although no definitive injury to the arteries was identified. The patient had strong palpable radial pulses and oxygen saturation of 94% on room air.

Due to concerns about the development of infectious complications and erosion into subjacent hilar vasculature, we decided to remove the foreign body. Given the patient’s pulmonary and hemodynamic stability, the operation was performed the following morning when additional staff were available. Although there was no obvious vascular injury, we opted for a posterolateral thoracotomy for removal instead of thoracoscopy, in case there was significant bleeding or lung repair was needed. The patient was

type- and cross-matched for blood products, and we proceeded to the operating room. He was positioned in the right lateral decubitus position. Thoracotomy was performed, revealing a bean bag ballistic lodged in the parenchyma of the left lung with the tail of the projectile still contained within the chest wall. The tail was initially mobilized and freed from the chest wall. Circumferential blunt dissection was carried out around the bean bag with gentle traction applied. While we considered stapled tractotomy down the length of the bean bag ballistic to assist in removal, this was ultimately unnecessary. After careful blunt circumferential dissection, the bean bag was removed in its entirety (Fig. 2). Fig. 3 demonstrates the bean bag ballistic after removal. The underlying lung had minimal bleeding and there was no visible vessel at the base of the wound. A topical hemostatic was applied to the ballistic cavity. A chest tube was then placed. The patient’s chest was closed in standard fashion with interrupted Vicryl sutures. Postoperatively, the patient’s chest tube was removed on day 5 and he was discharged on hospital day 7. At a 2-week outpatient follow-up visit, the patient was doing well and had no complications.

Ethics statement

Informed consent for publication of the research details and clinical images was obtained from the patient.

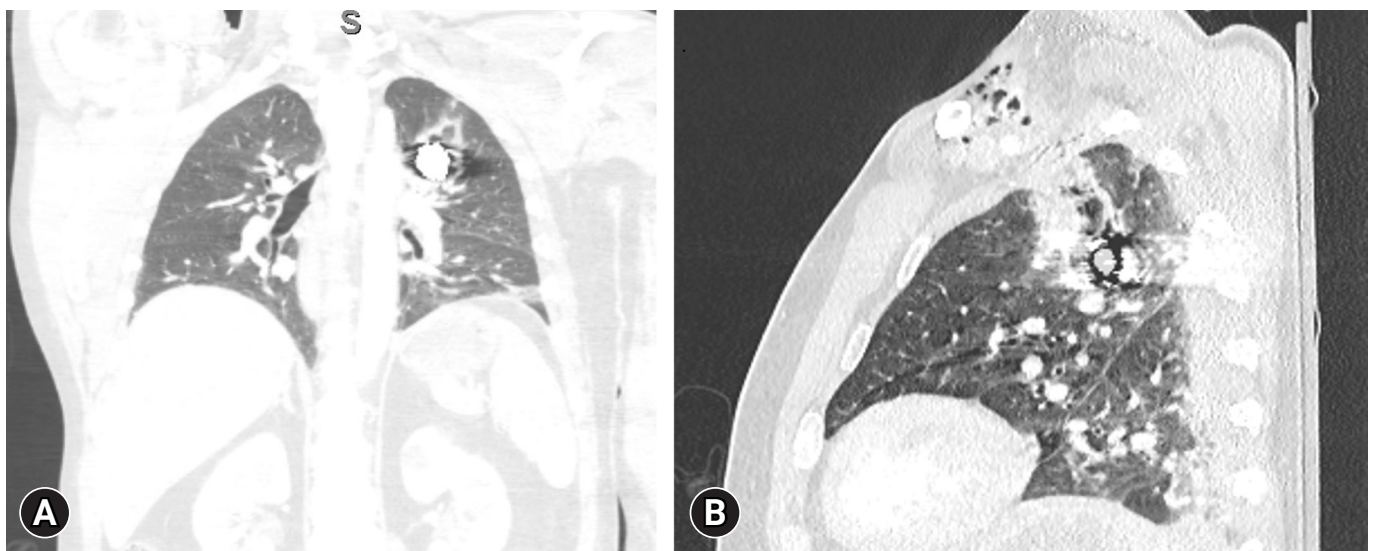


Fig. 1. Radiographic representation of the foreign body. (A) Coronal view of the foreign body in the left chest. (B) Sagittal view of the foreign body in the left chest that demonstrates the trajectory of the ballistic through the anterior left first intercostal space, with the ballistic fragment within the left upper lobe.

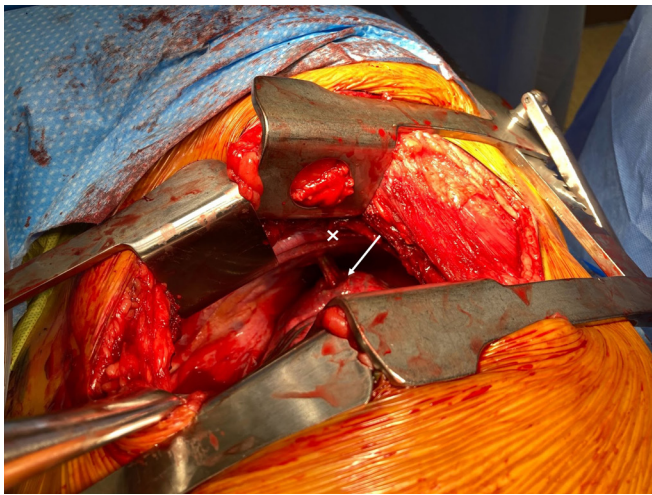


Fig. 2. Bean bag ballistic lodged within the parenchyma of the lung (arrow). The tail of the ballistic (marked as “x”) is still contained within the chest wall.

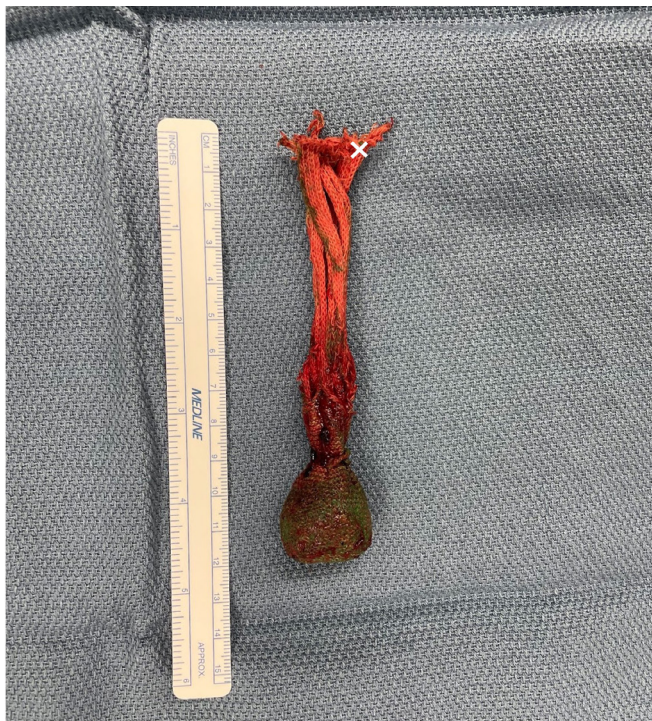

Fig. 3. Bean bag ballistic after removal. The tail is marked as “x.”

DISCUSSION

Although law enforcement officers utilize bean bag projectiles as a “less lethal” means of crowd control and protection, these ballistics pose significant risk and can result in serious injury, as demonstrated in this case report. Various “less lethal” projectiles

are used by law enforcement, including rubber bullets, paintballs, and bean bag projectiles. The increased use of “less lethals” has been accompanied by a concomitant increase in reports of significant injury [1,2]. Some reported injury patterns include soft tissue contusions, ocular damage, blunt abdominal injury, cardiac contusion, pneumothorax, hemothorax, and extremity injuries [1,2]. The most common injury is soft tissue contusion, which is considered to be mild in nature [3].

This case report presents a rare intrathoracic injury from a bean bag ballistic and is the first to describe this outcome for a drag-stabilized bean bag. One other case report has described the surgical removal of a bean bag ballistic (the flexible baton, MK-12) from the thoracic cavity [1]. Notably, uncomplicated gunshot wounds have less than a 2% infection rate and do not require removal or debridement of the retained ballistic [4]. However, the fabric covering of this ballistic increased the infectious risk and raised concerns about the potential development of a lung abscess. Thus, a thoracotomy was performed to facilitate foreign body removal and to assess the possibly injured pulmonary vasculature.

Although life-threatening injuries are rare, the kinetic impact of these “less lethals” should not be underestimated. A recent article in the *New England Journal of Medicine* [2] advocated for alternative means of crowd control due to significant morbidity experienced by patients who were struck by bean bag projectiles, including skull fractures and several intracranial hemorrhages, during recent protests in Texas, USA. Surgeons treating patients with traumatic injuries should be familiar with these projectiles and their potential associated injury patterns, as they can result in significant morbidity and mortality.

ARTICLE INFORMATION

Author contributions

Conceptualization: all authors; Methodology: all authors; Writing—original draft: MB; Writing—review & editing: all authors. All authors read and approved the final manuscript.

Conflicts of interest

The authors have no conflicts of interest to declare.

Funding

The authors received no financial support for this study.

Data availability

Data sharing is not applicable as no new data were created or analyzed in this study.

REFERENCES

1. de Brito D, Challoner KR, Sehgal A, Mallon W. The injury pattern of a new law enforcement weapon: the police bean bag. *Ann Emerg Med* 2001;38:383–90.
2. Olson KA, Haselden LE, Zaunbrecher RD, et al. Penetrating injuries from “less lethal” beanbag munitions. *N Engl J Med* 2020;383:1081–3.
3. Beatty JA, Stopyra JP, Slish JH, Bozeman WP. Injury patterns of less lethal kinetic impact projectiles used by law enforcement officers. *J Forensic Leg Med* 2020;69:101892.
4. Ordog GJ, Sheppard GF, Wasserberger JS, Balasubramaniam S, Shoemaker WC. Infection in minor gunshot wounds. *J Trauma* 1993;34:358–65.