

Radiological assessment and follow-up of a nonsurgically treated odontoid process fracture after a motor vehicle accident in Egypt: a case report

Ahmad Mokhtar Abodahab, MD 

Department of Radiology, Sohag University Faculty of Medicine, Sohag, Egypt

Received: June 13, 2023
Revised: August 18, 2023
Accepted: August 28, 2023

Correspondence to

Ahmad Mokhtar Abodahab, MD
Department of Radiology, Sohag
University Faculty of Medicine, Sohag
University St, Nasser City, Sohag
1684097, Egypt
Tel: +20-10-04349407
Email: Dr.ahmadabodahab@gmail.com

An odontoid process fracture is a serious type of cervical spine injury. This injury is categorized into three types based on the location of the fracture. Severe or even fatal neurological deficits can occur due to associated cord injury, which can result in complete quadriplegia. Computed tomography is the primary diagnostic tool, while magnetic resonance imaging is used to evaluate any associated cord injuries. These injuries can occur either directly from the injury or during transportation to the hospital if mishandled. There are two main treatment approaches: surgical fixation or external nonsurgical fixation, with various types and models of fixation devices available. In this case study, computed tomography follow-up confirmed that external fixation can yield successful results in terms of complete healing, even in cases complicated by other factors that may impede healing, such as pregnancy.

Keywords: Cervical fracture; Odontoid process fracture; Neck trauma; Case reports

INTRODUCTION

Motor vehicle accidents are a leading cause of death and severe organ injuries worldwide. Odontoid fractures, which typically occur in the C2 vertebra, are common injuries across various age groups, particularly among the elderly. This type of fracture often results from injuries such as falls that force the head into hyperextension. The most common symptom is neck pain, though neurological deficits may also occur, depending on the degree of displacement and cord injury. Less frequently, other associated pathologies such as cardiac arrest may occur [1-7]. Computed tomography (CT) scans are the primary imaging modality for diagnosing spinal fractures. If a cord injury is suspected due to as-

sociated neurological deficits, an magnetic resonance imaging (MRI) is recommended [2-8]. A type II odontoid fracture may also be associated with a loss of joint stability, known as "atlanto-axial dislocation," between the atlas (C1) and axis (C2) [3-9].

CASE REPORT

On February 13, 2016, a newlywed 25-year-old woman was traveling with her husband on a highway with a maximum speed limit of 120 km/hr. However, their car was moving at a speed exceeding 170 km/hr when the left front wheel suddenly burst. The driver immediately applied the brakes, causing the large van to spin in the air at a high speed. This resulted in most of the 14 pas-

sengers being ejected through the car windows due to the centrifugal force. After the car came to a halt on the side of the road, only the driver, her husband, and one other passenger remained inside the vehicle. The rest of the passengers were scattered over a considerable distance on both sides of the road. The woman fell from a significant height, landing headfirst onto the hard surface of the road.

The patient was transported by ambulance to Qena General Hospital (Qena, Egypt), where initial first aid measures were administered. Subsequently, the patient was transferred to Sohag University Hospital (Sohag, Egypt). The patient presented with severe neck pain and a large, contused wound on the scalp, located at the sagittal midline of the head. Despite these injuries, the patient was fully conscious and exhibited normal vital signs. The abdomen was lax, and aside from a few minor abrasions on both upper limbs, no other injuries were detected. There was no evidence of a neurological deficit.

Imaging investigations were conducted. Abdominal ultrasonography was performed, revealing no collections or injuries to the abdominal organs. A nonenhancing multislice CT scan of the head and neck was also carried out, including sagittal, coronal, and three-dimensional reformatted images (Figs. 1–3). This scan revealed a complete fracture of the odontoid process at its base, the site of connection between the dens and the C2 vertebral

body, with no displacement. No other injuries or fractures were detected. The CT scan of the brain was normal. Although MRI would be crucial for assessing this case, it was not performed due to the absence of neurological deficits.

An external neck collar was utilized for temporary fixation until a treatment plan could be determined. Some orthopedic surgeons favored internal fixation using a screw. Others recommended nonsurgical external fixation with a Minerva orthosis device, as depicted in Fig. 4. Ultimately, the decision was made to use this device. The patient was discharged with the device in place, which was prescribed for a minimum of 3 months' use. The patient took medications to promote bone formation, although the specific type was not disclosed to us.

A few weeks after the accident, the patient discovered she was pregnant. This made repeated follow-up CT scans both limited and potentially harmful to the integrity of the pregnancy. Three months later, with the detailed consent of the patient and her husband, a follow-up CT scan was deemed necessary to evaluate the case. The scan would determine whether the external fixation was effective and if the healing process had occurred, or if alternative surgical treatment would be required. To minimize radiation exposure, the CT scan was performed with very limited cut sections and the patient's abdomen and pelvis were covered with multiple layers of protective lead aprons. The CT scan revealed that complete healing had occurred with very minimal tilting to the left (Figs. 5, 6). The patient began gentle physiotherapy until she fully recovered, eventually returning to her work as a civil engineer. A few months later, in December 2016, she gave birth to her first child, who was completely healthy. The child, now approximately 6 years old, began preschool last year.

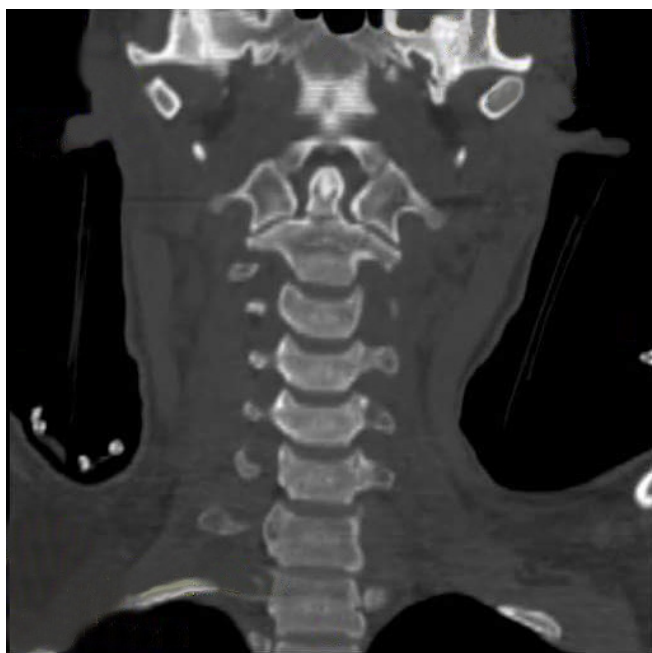

Fig. 1. A computed tomography scan of the cervical spine in a coronal reformatted view. The image clearly shows a complete fracture at the base of the odontoid process (C2).

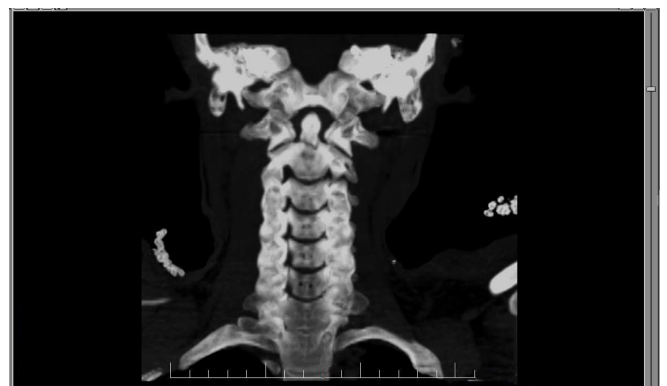

Fig. 2. A three-dimensional coronal reformatted computed tomography scan of the cervical spine. The image confirms complete irregularity. A fracture at the base of the odontoid process (C2) is shown.

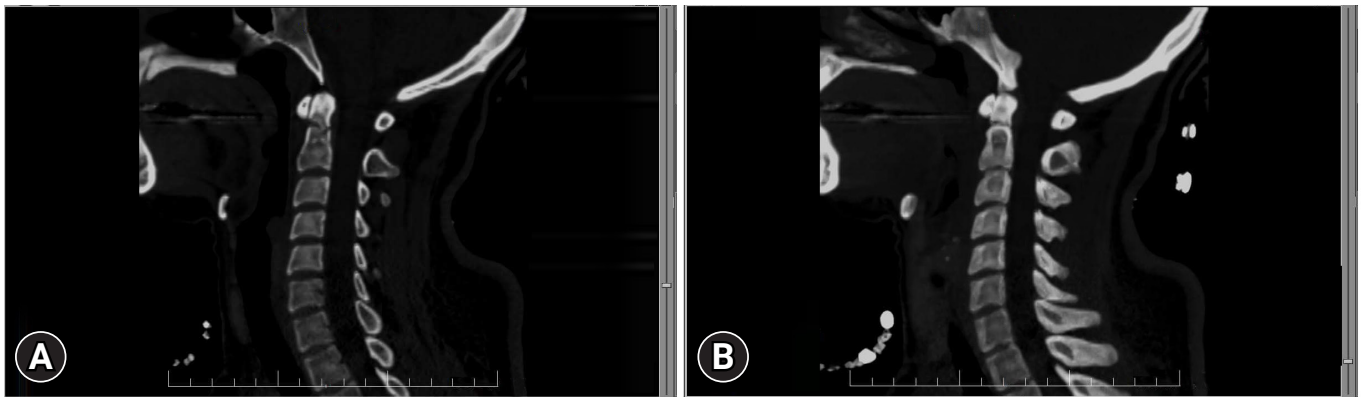


Fig. 3. A sagittal reformatted computed tomography scan of the cervical spine. (A, B) The images reveal the previously described complete, irregular fracture at the base of the odontoid process (C2).



Fig. 4. Minerva orthosis, an external support device used in patient treatment. The image demonstrates the correct method of application for this device during use.

Ethics statement

The patient and her husband provided written informed consent for publication of the research details and clinical images. No personal data or photos were used.

DISCUSSION

An odontoid process fracture, also known as a peg or dense fracture, typically results from high-force trauma to the head and

neck, such as injuries sustained in swimming pool accidents or motor vehicle collisions. There are three types of this fracture (Fig. 7). Type II fractures (as observed in our case study) have the highest rate of nonunion due to their increased propensity for displacement. CT and MRI are the primary imaging modalities for diagnosing spinal fractures in general, and odontoid process fractures in particular. X-rays have a limited role in diagnosis due to the need for special positioning, which can exacerbate the injury through further dislocation and associated cord injury. Early diagnosis is crucial, as a delayed diagnosis often leads to poor outcomes. Patients with an odontoid process fracture are susceptible to either neurogenic or cardiorespiratory shock [1–6]. Various internal stabilization techniques have been described for odontoid fractures, including screw fixation and instrumented fusion. More recently, temporary atlantoaxial stabilization with an absorbable suture has been reported as an alternative surgical treatment. However, for the majority of cases, external stabilization using a Minerva orthosis remains the preferred treatment method. Our study strongly aligns with the experience of Razii et al. [2], suggesting that even patients with a fracture pattern showing significant angulation can be successfully managed conservatively.

Atlantoaxial dislocation accompanied by an odontoid fracture is a rare condition that carries a high risk of fatal complications. These complications are the primary reasons for surgical intervention [3]. According to Anderson and D'Alonzo classification, type II and III odontoid fractures are best treated with anterior fixation in selected patients. Odontoid screw fixation provides direct stabilization of the fracture. The choice of surgical treatment depends on various factors, including anatomical, clinical, and laboratory considerations. Some patients have specific diameters

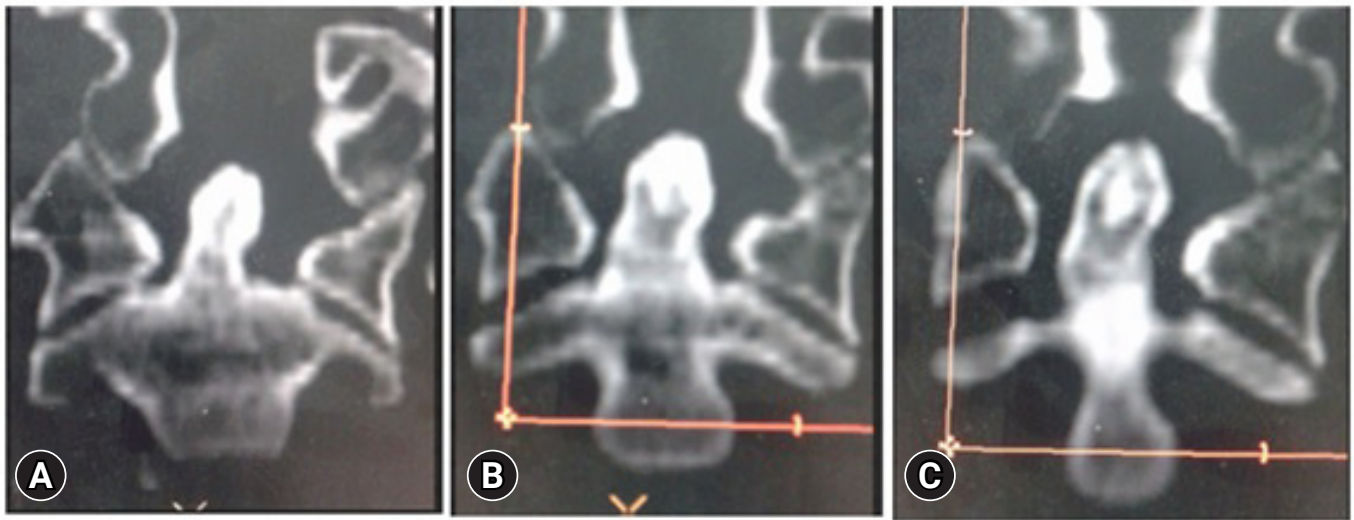


Fig. 5. (A–C) A coronal reformatted computed tomography scan of the cervical spine taken 3 months after treatment by external fixation. (A–C) Different sections show complete healing of the previously described complete irregular fracture at the base of odontoid process (C2), with minimal tilt of its vertical axis slightly to the left.

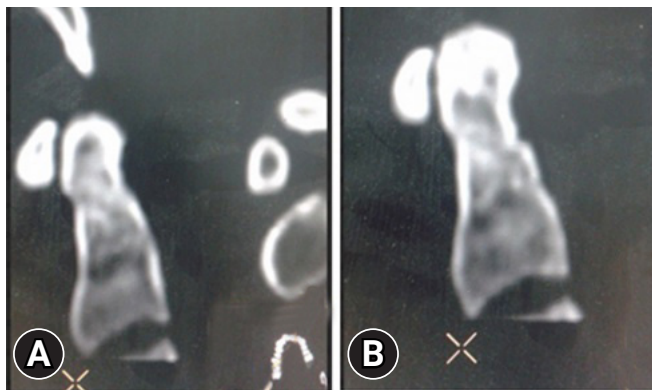


Fig. 6. (A, B) A sagittal reformatted computed tomography scan of the cervical spine taken 3 months after treatment by external fixation. (A, B) Different sections show complete healing of the previously described complete irregular fracture at the base of odontoid process (C2).

that preclude the introduction of a second implant within the odontoid process, necessitating careful preoperative planning [4]. Taher et al. [5] reported successful management of a displaced odontoid synchondrosis fracture using temporary C1–2 instrumentation. This innovative approach to managing odontoid process fractures in children preserves cervical biomechanics and range of motion. However, it is still a surgical treatment and carries all the associated risks. Even with these risks, surgical treatment remains necessary if attempts at nonsurgical external fixation fail [5–9].

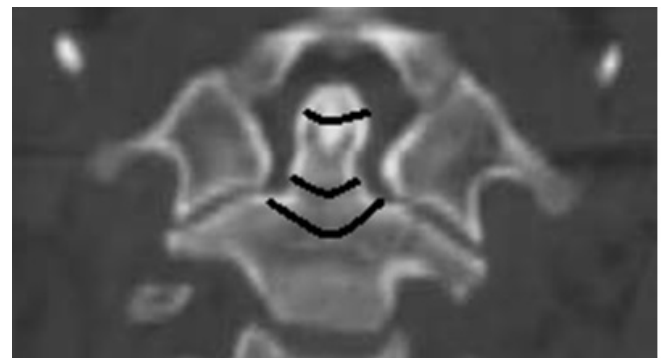


Fig. 7. Types of odontoid process, also known as "peg" or "dense" fractures. Type I involves the tip, type II occurs at the junction where the dens connects to the vertebral body, and type III involves a portion of the vertebral body itself.

Our case report and literature conclude that type II fractures are the most dangerous and have the highest incidence of non-union. CT is the preferred method for diagnosis and follow-up, as it can assess whether complete bone union has occurred with nonsurgical external fixation. This approach completely avoids exposing the patient to the risks of surgery, even when the patient is pregnant, a condition that can impede fracture healing. Unless there is a compelling surgical indication, such as the need for decompression due to encroachment on the spinal cord, this case study suggests that it is preferable to give patients with odontoid process fractures the opportunity to heal through external fixation.

tion before resorting to surgical internal fixation. Follow-up CT scans can then be used to monitor the healing process.

ARTICLE INFORMATION

Conflicts of interest

The author has no conflicts of interest to declare.

Funding

The author received no financial support for this study.

Data availability

Data sharing is not applicable as no new data were created or analyzed in this study.

REFERENCES

1. Maeda K, Ichiba T. Unusual clinical course of odontoid fracture: transient prehospital cardiopulmonary arrest. *Cureus* 2020;12:e12157.
2. Razii N, Sharma A, Ahuja S. Complete remodelling of a displaced odontoid synchondrosis fracture managed conservatively: a case report. *J Pediatr Orthop B* 2019;28:411–4.
3. Tobing SD, Makabori JC. Atlantoaxial dislocation with associated type II odontoid fracture in adolescent with cervical spondylitis tuberculosis: a case report. *Int J Surg Case Rep* 2023;104:107920.
4. Daher MT, Daher S, Nogueira-Barbosa MH, Defino HL. Computed tomographic evaluation of odontoid process: implications for anterior screw fixation of odontoid fractures in an adult population. *Eur Spine J* 2011;20:1908–14.
5. Taher AW, Falls CJ, Page PS, Stadler JA. Temporary internal bracing for pediatric odontoid synchondrosis fracture. *Cureus* 2021;13:e17639.
6. Iyer S, Hurlbert RJ, Albert TJ. Management of odontoid fractures in the elderly: a review of the literature and an evidence-based treatment algorithm. *Neurosurgery* 2018;82:419–30.
7. Guan J, Bisson EF. Treatment of odontoid fractures in the aging population. *Neurosurg Clin N Am* 2017;28:115–23.
8. Muthukumar N. Odontoid synchondrosis fracture treated by c1-2 polyaxial screw-rod fixation. *J Korean Neurosurg Soc* 2014;55:212–4.
9. Yang SY, Boniello AJ, Poorman CE, Chang AL, Wang S, Passias PG. A review of the diagnosis and treatment of atlantoaxial dislocations. *Global Spine J* 2014;4:197–210.