



# Abnormal spontaneous electromyographic activity in myasthenia gravis causing a diagnostic confusion: a case report and literature review

Sohyeon Kim<sup>1,\*</sup>, Minsung Kang<sup>2,\*</sup>, Jin-Sung Park<sup>2</sup>, Hung Youl Seok<sup>1</sup>

<sup>1</sup>Department of Neurology, Dongsan Hospital, Keimyung University School of Medicine, Daegu, Korea

<sup>2</sup>Department of Neurology, Kyungpook National University Chilgok Hospital, School of Medicine, Kyungpook National University, Daegu, Korea

**Received:** June 24, 2022

**Revised:** July 29, 2022

**Accepted:** August 13, 2022

## Correspondence to

### Hung Youl Seok

Department of Neurology, Dongsan Hospital, Keimyung University School of Medicine, 1035 Dalgubeol-daero, Dalseo-gu, Daegu 42601, Korea  
Tel: +82-53-258-7837  
Fax: +82-53-258-4380  
E-mail: shy2354@gmail.com

### Jin-Sung Park

Department of Neurology, Kyungpook National University Chilgok Hospital, School of Medicine, Kyungpook National University, 807 Hoguk-ro, Buk-gu, Daegu 41404, Korea  
Tel: +82-53-200-2753  
Fax: +82-53-200-2029  
E-mail: neurojspark@gmail.com

\*The first two authors contributed equally to this work as the first author.

## ORCID

### Sohyeon Kim

<https://orcid.org/0000-0002-5443-386X>

### Minsung Kang

<https://orcid.org/0000-0001-6206-0891>

### Jin-Sung Park

<https://orcid.org/0000-0001-5506-9206>

### Hung Youl Seok

<https://orcid.org/0000-0002-9938-5355>

<http://www.e-acn.org>

pISSN 2508-691X  
eISSN 2508-6960

Some cases of myasthenia gravis (MG) with abnormal spontaneous activity (ASA) in needle electromyography (EMG) have been reported, but the associated clinical characteristics remain to be fully elucidated. We report the case of a 36-year-old male with MG in whom ASA was observed. This study highlights that ASA may appear in needle EMG in patients with severe MG who predominantly have bulbar and/or respiratory involvement. Care is needed because this often accompanies myopathic features and can be misdiagnosed as myopathy.

**Key words:** Myasthenia gravis; Electromyography; Spontaneous activity

Clinicians occasionally observe abnormal spontaneous activity (ASA) in needle electromyography (EMG) in patients with myasthenia gravis (MG), which is not a characteristic of MG. Although some cases of MG with ASA have been reported,<sup>1-9</sup> its clinical characteristics remain to be fully elucidated. Here we report a case of MG with needle EMG findings of ASA.

## CASE

A 36-year-old male presented to our hospital with a 1-week history of dysphagia and respiratory insufficiency. He had first noticed nasal speech and facial weakness 3 months previously, and ptosis and progressive limb weakness had occurred 1 month previously. The symptoms were not fluctuating or fatigable. At admission, the patient was in severe respiratory distress and had an oxygen saturation of 80%. Mechanical ventilation was ini-

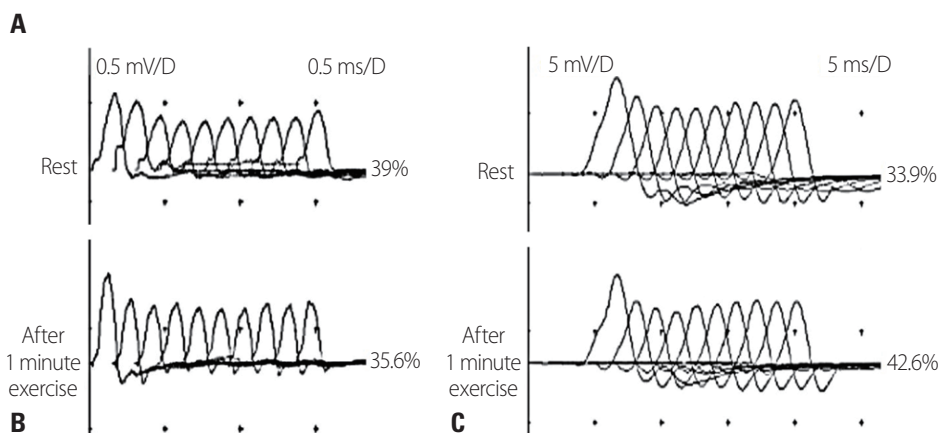
Copyright © 2022 The Korean Society of Clinical Neurophysiology

This is an Open Access article distributed under the terms of the Creative Commons Attribution Non-Commercial License (<http://creativecommons.org/licenses/by-nc/4.0>) which permits unrestricted non-commercial use, distribution, and reproduction in any medium, provided the original work is properly cited.

tiated after tracheal intubation. A neurological examination revealed bilateral ptosis, facial weakness, dysphagia, nasal speech, neck muscle weakness (Medical Research Council [MRC] grades 0/5 and 1/5 in the neck flexors and extensors, respectively), and bilateral symmetric proximal dominant limb muscle weakness (MRC grade 3/5 proximally and 4/5 distally in the upper limbs, and 4-/5 proximally and 5/5 distally in the lower limbs). No muscle atrophy was detected anywhere in the body, including the tongue. Abnormal deep tendon reflexes, ophthalmoplegia, sensory deficits, and pathological reflexes were not observed. A nerve con-

duction study showed reduced compound muscle action potential amplitudes in the bilateral facial and ulnar nerves and in the right median nerve. Sensory nerve conduction was normal. Needle EMG revealed fibrillation potentials and positive sharp waves in the right genioglossus, flexor carpi radialis, peroneus longus, and cervical paraspinal muscles, and a few small-amplitude, short-duration motor unit potentials in the right genioglossus muscle (Fig. 1A). Repetitive nerve stimulation at 5 Hz elicited decremental responses in the orbicularis oculi (-39% at rest and -35.6% postexercise, Fig. 1B) and abductor digiti minimi (-33.9% at rest and -42.6%

Muscle (Right)	Insertional activity	Spontaneous activity		Voluntary motor unit action potentials				
		Fibrillation potentials	Positive sharp waves	Activation	Recruitment	Configuration		
						Duration	Amplitude	Polyphasia
Deltoid	NL	0	0	NL	NL	NL	NL	NL
Biceps brachii	NL	0	0	NL	NL	NL	NL	NL
Triceps brachii	NL	0	0	NL	NL	NL	NL	NL
Flexor carpi radialis	↑	0	+1	NL	NL	NL	NL	NL
First dorsal interosseous	NL	0	0	NL	NL	NL	NL	NL
Rectus femoris	NL	0	0	NL	NL	NL	NL	NL
Vastus medialis	NL	0	0	NL	NL	NL	NL	NL
Tibialis anterior	NL	0	0	NL	NL	NL	NL	NL
Peroneus longus	↑	0	+1	NL	NL	NL	NL	NL
Medial gastrocnemius	NL	0	0	NL	NL	NL	NL	NL
Genioglossus	↑	+1	+2	NL	NL	-1	-1	+1
C7 paraspinal	↑	+1	+2					
T6 paraspinal	NL	0	0					
L5 paraspinal	NL	0	0					



**Fig. 1.** Electrophysiological findings for the patient. (A) Needle electromyography revealed fibrillation potentials and/or positive sharp waves in the right genioglossus, flexor carpi radialis, peroneus longus, and cervical paraspinal muscles, and myopathic motor unit potentials in the right genioglossus muscle. Repetitive nerve stimulation at 5 Hz elicited decremental responses in the orbicularis oculi (B, -39% at rest and -35.6% postexercise) and abductor digiti minimi (C, -33.9% at rest and -42.6% postexercise). NL, normal.

**Table 1.** Case reports of myasthenia gravis with abnormal spontaneous electromyographic activity

Age (years)/ sex	AChR- Ab	Symptoms	EMG findings				CK (titer, U/L)	Muscle biopsy	Initial misdiagnosis
			ASA: fibrillation potentials and positive sharp waves	Myopathic MUPs	RNS				
36/M (this case)	+	Dysarthria, dysphagia, bilateral ptosis, facial weakness, bilateral proximal limb weakness, and respiratory failure	FCR, PL, tongue, and cervical PSP	Tongue	Abnormal	Normal (124.1)	ND	None	
66/F <sup>1</sup>	+	Fatigable head drop, asymmetrical ptosis, dysarthria, and bilateral proximal weakness	Proximal upper and lower limb muscles	Proximal muscles	Abnormal	Normal	Not suggestive of inflammatory myopathy	Inflammatory myopathy	
74/M <sup>1</sup>	+	Dysphonia and respiratory failure	Bulbar muscles	NR	Abnormal	NR	NR	Anterior horn cell disease	
16/F <sup>2</sup>	+	Jaw drop, bulbar and limb-girdle fatigable weakness, and dyspnea	Deltoid, triceps, and ilopsoas	Deltoid, triceps, and ilopsoas	Normal	Abnormal (411)	Lymphorrhage	None	
55/F <sup>2</sup>	+	Head drop, bulbar and limb-girdle fatigable weakness, and shoulder atrophy	Deltoid, ISP, C5 PSP, C7 PSP, and T10 PSP	Deltoid, triceps, ISP, C5 PSP, and ilopsoas	Abnormal	Normal (114)	ND	None	
60/F <sup>2</sup>	+	Bulbar and limb-girdle fatigable weakness, head drop, shoulder atrophy, and dyspnea	Deltoid, trapezius, tongue, and temporalis	Deltoid	Abnormal	Normal (193)	ND	None	
58/F <sup>3</sup>	+	Dysarthria, dysphagia, limb-girdle weakness, and dyspnea	Deltoid and biceps	Biceps, deltoid, and VM	Abnormal	Normal (81)	Neurogenic muscle atrophy	Polymyositis	
74/M <sup>3</sup>	+	Dysarthria, dysphagia, masseter muscle weakness, and limb-girdle muscle weakness	Thoracic PSP	OO, trapezius, deltoid, FDI, VL, and TA	Abnormal	Abnormal (286)	Chronic neurogenic muscle atrophy, myopathic features, no signs of inflammation typical of myositis	Polymyositis	
60/F <sup>4</sup>	-	Diplopia, dysarthria, dysphagia, nasal regurgitation, mild proximal limb weakness, and respiratory failure	Diaphragm	NR	Abnormal	Normal	NR	None	
60/F <sup>4</sup>	-	Ptosis, bulbar muscle weakness, mild limb weakness, respiratory failure	Diaphragm and AEO	NR	Normal	Normal	NR	None	
38/F <sup>4</sup>	-	Dysphagia, diplopia, dysphonia, dyspnea, and weakness of ocular, facial, and bulbar muscles	Diaphragm and some limb muscles	Some limb muscles	Normal	Normal	NR	None	

Table 1. Continued

Age (years)/sex	AChR-Ab	Symptoms	EMG findings				CK (titer, U/L)	Muscle biopsy	Initial misdiagnosis
			ASA: fibrillation potentials and positive sharp waves	Myopathic MUPs	RNS	Myopathic MUPs			
42/M <sup>5</sup>	+	Diplopia, moderate-to-severe right ptosis, predominantly distal limb weakness	Distal hand and leg muscles	Distal hand and leg muscles	Abnormal	NR	NR	None	
37/F <sup>5</sup>	+	Ptosis, diplopia, and marked wrist extensor and intrinsic hand muscle weakness	Distal hand and forearm muscles	None	Abnormal	NR	NR	None	
28/M <sup>6</sup>	+	Diplopia, bilateral ptosis, mild dysphagia, and bilateral upper extremity weakness	Triceps, FCU, FDI, FDP III and IV, TA, and TP	None	Abnormal	Normal (185)	Neurogenic change	None	
77/M <sup>7</sup>	+	Mild left ptosis, intermittent diplopia, and severe bilateral proximal upper limb weakness	Deltoid	Deltoid	Abnormal	Normal	NR	None	
47/M <sup>8</sup>	+	Diplopia, right ptosis, and slowly progressive hand weakness	Distal upper limb muscles	Distal upper limb muscles	Abnormal	NR	NR	Distal upper limb myopathy	
28/F <sup>9</sup>	+	Non-fluctuating, progressive fatigue while talking and difficulty in swallowing, tongue atrophy and fasciculations, ptosis, and facial weakness	Tongue	Face and neck muscles	Abnormal	NR	NR	Myopathy	

AChR-Ab, acetylcholine receptor antibody; EMG, electromyography; ASA, abnormal spontaneous activity; MUPs, motor unit potentials; RNS, repetitive nerve stimulation; CK, serum creatine kinase; M, male; FCR, flexor carpi radialis; PL, peroneus longus; PSP, paraspinal muscles; ND, not done; F, female; NR, not reported; ISP, infraspinatus; VM, vastus medialis; OO, orbicularis oris; FDI, first dorsal interosseous; VL, vastus lateralis; TA, tibialis anterior; AEO, abdominal external oblique; FCU, flexor carpi ulnaris; FDP, flexor digitorum profundus; TP, tibialis posterior.

postexercise, Fig. 1C). The patient was positive for acetylcholine receptor antibodies (titer, 18.743 nmol/L; normal range,  $\leq 0.5$  nmol/L), had a normal serum creatine kinase level (124.1 U/L), and was negative for serum immunological markers, including anti-Jo-1 antibody. An anti-muscle-specific tyrosine kinase (MuSK) antibody test was not performed because it was not available in our center.

A myasthenic crisis was diagnosed. After 5 days of treatment with intravenous immunoglobulin, the patient's neck, limb, and respiratory muscle weakness improved and he was successfully weaned from mechanical ventilation; however, mild bilateral ptosis persisted. Follow-up EMG performed 15 days after the initial assessment revealed no ASA or myopathic features. Chest computed tomography revealed an anterior mediastinal mass originating from the thymus. A transsternal thymectomy was performed, and a histopathological diagnosis of thymoma of World Health Organization type B3 was made. There was no further worsening of symptoms during the 35-month follow-up period, during which oral prednisolone and azathioprine were provided as maintenance therapy.

## DISCUSSION

ASA was unexpectedly observed in needle EMG during a myasthenic crisis episode in a patient experiencing his first attack of MG. Previously reported cases of MG with ASA are summarized in Table 1.<sup>1-9</sup> Previous reports of MG with ASA have described severe disease with predominantly bulbar and/or respiratory involvement. Most of the related studies showed myopathic motor unit potentials with ASA in needle EMG, which sometimes led to an initial misdiagnosis as myopathy.<sup>1,3,8,9</sup> However, most patients had normal serum creatine kinase levels,<sup>1-4,6,7</sup> and muscle biopsies did not reveal myopathic changes.<sup>1-3,6</sup> Therefore, ASA and myopathic EMG findings in patients with MG reflect the blocking of muscle fibers due to severely impaired neuromuscular transmission rather than actual myopathy.<sup>1</sup> This is supported by the findings that ASA and myopathic motor unit potentials were more prominent in the bulbar and neck muscles, which exhibited the most-severe weakness in our patient.

Needle EMG is usually not performed for diagnosing patients with fluctuating and fatigable weakness, which are

typical of MG. However, as in our patient, needle EMG is often performed when fluctuating and fatigable weakness is absent in order to differentiate between MG and other diseases such as myopathy. In such patients, the unexpected observation of ASA and myopathic motor unit potentials in needle EMG can confuse the clinician and delay the diagnosis of MG.

Acetylcholine receptor antibody positivity was found in most of the previously reported cases,<sup>1-3,5-9</sup> suggesting that these antibodies play a more important role than other antibodies in the development of ASA in MG. However, five (41.7%) of 12 patients with MuSK-antibody-positive MG in a previous study had ASA.<sup>10</sup> Therefore, it is difficult to draw conclusions about the role of each antibody in the occurrence of ASA in patients with MG based on currently available data.

In conclusion, ASA may appear in needle EMG in patients with severe MG who predominantly have bulbar and/or respiratory involvement. Care is needed because this often accompanies myopathic features and can be misdiagnosed as myopathy.

## Conflicts of Interest

The authors have no conflicts of interest to declare.

## REFERENCES

1. Tsironis T, Catania S. Reversible spontaneous EMG activity during myasthenic crisis: two case reports. *eNeurologicalSci* 2019;14:16-18.
2. Kannaditharayil D, Napier F, Granit V, Bieri P, Herskovitz S. Abnormal spontaneous activity on needle electromyography in myasthenia gravis. *Muscle Nerve* 2017;56:E11-E12.
3. Pelzer EA, Galldiks N, Brunn A, Fink GR, Haupt WF. Evidence of spontaneous activity in two cases of severe myasthenia gravis. *J Neurol Neurophysiol* 2012;3:136.
4. Maher J, Grand'Maison F, Nicolle MW, Strong MJ, Bolton CF. Diagnostic difficulties in myasthenia gravis. *Muscle Nerve* 1998; 21:577-583.
5. Musser WS, Barbano RL, Thornton CA, Moxley RT 3rd, Herrmann DN, Logigian EL. Distal myasthenia gravis with a decrement, an increment, and denervation. *J Clin Neuromuscul Dis* 2001;3:16-19.

6. Samuraki M, Furui E, Komai K, Takamori M, Yamada M. Myasthenia gravis presenting with unusual neurogenic muscle atrophy. *Muscle Nerve* 2007;36:394-399.
7. Shah PA, Wadia PM. Reversible man-in-the-barrel syndrome in myasthenia gravis. *Ann Indian Acad Neurol* 2016;19:99-101.
8. Fearon C, Mullins G, Reid V, Smyth S. Distal myasthenia gravis presenting as isolated distal myopathy. *Muscle Nerve* 2015;52:308-309.
9. Asan F, Tütüncü M, Gündüz A, Adatepe NU. Tongue atrophy and myopathy mimicking EMG findings in a case with acetylcholine receptor-positive myasthenia gravis. *Cerrahpaşa Med J* 2022;46:75-77.
10. Sanders DB, El-Salem K, Massey JM, McConville J, Vincent A. Clinical aspects of MuSK antibody positive seronegative MG. *Neurology* 2003;60:1978-1980.