



**Joong Ho Kim, Ji An Uh,
Ho Sung Kim, Soo Kyung Lee,
Myoung Shin Kim, Un Ha Lee**
 Department of Dermatology, Inje University
 Sanggye Paik Hospital, Seoul, Korea

Received: September 30, 2022
 Accepted: October 25, 2022

Corresponding author: Un Ha Lee, MD
 Department of Dermatology, Inje University
 Sanggye Paik Hospital, 1342 Dongil-ro,
 Nowon-gu, Seoul 01757, Korea
 Tel: +82-2-950-1131, Fax: +82-2-931-8720
 E-mail: dermalee@paik.ac.kr

No potential conflict of interest relevant to this article was reported.

Livedo reticularis following administration of ChAdOx1 nCoV-19 vaccine (AZD1222): a report of two cases

The cutaneous appearance of transient or persistent livedo reticularis is characterized by violaceous, mottled, ring-shaped interconnecting lesions that form a reticular or net-like pattern. It can occur physiologically in response to cold exposure, such as in cutis marmorata, but can also be induced by pathological conditions such as vascular obliterans or venodilation. We report two cases of livedo reticularis that occurred on the lower limbs of two patients post ChAdOx1 nCoV-19 vaccination. As the patients had no other likely causes of livedo reticularis, the reticular skin lesions were suspected to occur in association with the ChAdOx1 nCoV-19 vaccination. Livedo reticularis is an uncommon adverse reaction, with few cases being reported post ChAdOx1 nCoV-19 vaccination.

Keywords: ChAdOx1 nCoV-19, Livedo reticularis, Vaccine, Case report

Introduction

The cutaneous appearance of transient or persistent livedo reticularis (LR) is characterized by violaceous, mottled, ring-shaped interconnecting lesions that form a reticular or net-like pattern [1,2]. Although LR commonly presents as a physiological response to cold exposure, it can be associated with various pathologies or underlying systemic diseases, including antiphospholipid syndrome, cryoglobulinemia, thrombosis, embolism, calciphylaxis, hyperoxaluria, and vasculitis [1]. Some medications, such as amantadine, gemcitabine, and minocycline, are also known to potentially cause LR [1]. According to a recent study, LR-like reactions account for 3.5% of skin manifestations that present during coronavirus disease 2019 (COVID-19) infection [3]. However, there are few reports of LR manifestations following COVID-19 vaccination [4,5]. In this paper, we report two rare cases of LR-like reactions following vaccination with ChAdOx1 nCoV-19 in patients without any other suspicious causes or underlying systemic diseases related to LR.

Case Report

Case 1

A 61-year-old Asian woman presented with slightly purpuric maculopatches with a reticular pattern on her legs (Fig. 1A-C). Nine days prior to her visit to Inje University Sanggye Paik Hospital, she was vaccinated with her first dose of ChAdOx1 nCoV-19;

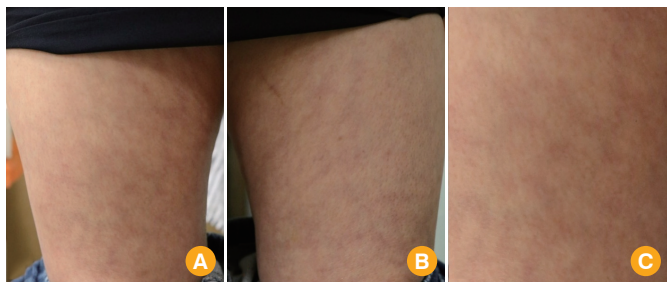


Fig. 1. Slightly purpuric maculopatches with a reticular pattern on both legs that appeared the day following ChAdOx1 nCoV-19 vaccination. (A) Right thigh. (B) Left thigh. (C) Close-up of the reticular rash on the right thigh.

the reticulated purpuric maculopatches presented on her lower extremities the day after inoculation. The skin lesions were asymptomatic and persistent without alleviation, until her presentation to our hospital. Her only underlying disease was dyslipidemia, for which she took oral medication. She denied any other history of medication or cold exposure, and she had no family history of note. Several laboratory tests were conducted, including a complete blood count (CBC) with differential count, liver function tests (LFT), blood urea nitrogen (BUN), creatinine (Cr), estimated glomerular filtration rate (e-GFR), C-reactive protein (CRP), prothrombin time (PT), international normalized ratio (INR), activated partial thromboplastin time (aPTT), D-dimer, cryoglobulin, rheumatoid factor, complement component 3 & 4, antinuclear antibody, and antineutrophil cytoplasmic antibody. However, no abnormalities were found in any of these tests. The skin rash improved after a 2-week administration of oral antihistamines (bepotastine salicylate and loratadine) in combination with the application of methylprednisolone aceponate lotion twice a day.

The patient provided written informed consent for the publication of clinical details and images.

Case 2

A 62-year-old Asian woman visited Inje University Sanggye Paik Hospital with dark violaceous reticular patches on her legs (Fig. 2A, B). She had the first dose of ChAdOx1 nCoV-19 vaccination 10 days prior to her visit to our hospital. The skin rash with violaceous net-like patches was observed nine days after her vaccination—the day before her presentation to our hospital. The skin rash was asymptomatic. She had previously been diagnosed with osteoporosis, but she did not take any medication for it. Her family history was unremarkable, and she denied any history of cold exposure. Laboratory tests—

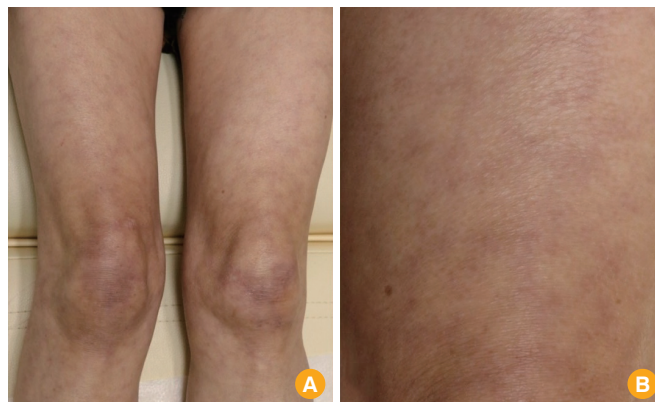

Fig. 2. (A) Dark violaceous reticular patches on both legs that occurred nine days post ChAdOx1 nCoV-19 vaccination. (B) Close-up of the net-like skin rash on the left thigh.

CBC with differential count, LFT, BUN, Cr, e-GFR, CRP, PT, INR, aPTT, and D-dimer—revealed no significant abnormal findings except for an elevated D-dimer level of 1.26 $\mu\text{g}/\text{mL}$ (reference value, $<0.55 \mu\text{g}/\text{mL}$). The D-dimer test was repeated the day after the first laboratory tests, and the level had decreased to 0.36 $\mu\text{g}/\text{mL}$, which is within the normal range. Antihistamines (bepotastine besilate and fexofenadine hydrochloride) were administered orally for 2 weeks, and her reticular skin rash almost disappeared.

The patient provided written informed consent for the publication of clinical details and images.

Discussion

Superficial venous plexuses are distributed in a reticular pattern of anastomoses, surrounding the periphery of multiple circular zones where arterial supply is predominant [1,2]. Therefore, any condition increasing the visibility of superficial venous plexuses can induce an LR appearance [1,6]. The principal mechanisms that increase the visibility of superficial venous plexus are as follows: (1) diminished cutaneous perfusion and/or (2) venodilation [1,2,6]. The former (1) arises from arterial thrombosis or embolism, venous thrombosis, increased blood viscosity, or vasospasm induced by cold temperatures or autonomic input. Reduced perfusion within the venous plexus results in deoxygenation of hemoglobin, leading to violaceous coloration that is more visible [1,2,6]. The latter (2), venodilation, also makes the venous plexuses more visually prominent and can be provoked by autonomic dysfunction, venodilators, or local hypoxia [1,2,6]. In our patients, histories of both cold exposure and administration of

venodilators were absent. Furthermore, they had no underlying systemic diseases that may have interfered with blood flow. ChAdOx1 nCoV-19 vaccination was the only notable event that happened closely before the onset of LR in our patients; therefore, we suspected that the LR might have occurred after inoculation with the ChAdOx1 nCoV-19 vaccine.

However, till date, the relationship between LR and ChAdOx1 nCoV-19 has not been completely deciphered. In the cases presented, we hypothesized that three mechanisms may result in LR after ChAdOx1 nCoV-19 vaccination: thrombosis [1,2,7,8], vasculitis [1,2,9], and autonomic dysfunction [1,2,10]. First, thrombotic conditions, which may be elicited by ChAdOx1 nCoV-19, are thought to potentially interfere with blood flow and lead to LR. Ramessur et al. [8] reported a case of cutaneous thrombosis following ChAdOx1 nCoV-19 vaccination. Another reported case of “ChAdOx1 nCoV-19 vaccine-induced immune thrombotic thrombocytopenia” accompanying LR lesions also supports our first hypothesis [7]. Second, vasculitis, which is a known underlying cause of LR [1,2], may be provoked by ChAdOx1 nCoV-19. Cavalli et al. [9] suggested that ChAdOx1 nCoV-19 can induce an abnormal immune response that can affect endothelial cells or the coagulation cascade, resulting in cutaneous vasculitis. Lastly, ChAdOx1 nCoV-19 may potentially cause autonomic dysfunction [10], which can trigger LR by inducing abnormal vasospasm or venodilation [1,2]. This is supported by a report of autonomic dysfunction appearing after ChAdOx1 nCoV-19 vaccination [10]. The patient in the aforementioned case presented with intermittent mottling in the hands, feet, and penis, although the skin lesions were not entirely consistent with the appearance of LR [10].

Our patients had no significant laboratory evidence implying a thrombotic condition, with the exception of a slightly elevated D-dimer level in one patient, which normalized the following day. Nevertheless, we could not exclude cutaneous thrombosis as the cause of LR as there has been a recent study demonstrating biopsy-proven cutaneous thrombosis following ChAdOx1 nCoV-19 vaccination, in the absence of significant laboratory findings supporting a thrombotic condition [8]. Taking into consideration a previous report of vasculitis which clinically presented as LR [11], we speculated that vasculitis could be a plausible cause of LR in our patients. Autonomic dysfunction was ruled out as a cause of LR in these patients due to the absence of autonomic symptoms such as palpitation, dizziness, and paresthesia.

Based on our literature review, LR associated with the COV-

ID-19 vaccine seems rare [4,5]. Bérezné et al. [4] reported a case of LR that appeared after ChAdOx1 nCoV-19 injection, and Mintz et al. [12] reported another case of LR after the third dose of messenger RNA-1273 SARS-CoV-2 vaccine. One case of pernio-like manifestations on both hands with intermittent appearance of an LR-like rash on the legs and another case of livedo racemosa on both thighs were also reported to have occurred after injection of the BNT162b2 messenger RNA COVID-19 vaccine [5,13]. Livedo racemosa is a pathological variant of LR, characterized by irregular and broken networks of a skin rash that is usually more widespread than LR [2,14].

LR should be differentiated from other cutaneous disorders showing reticular eruptions, including erythema ab igne, reticulated erythematous mucinosis (REM), and erythema infectiosum [2]. First, erythema ab igne is induced by heat exposure, and in our case, our patients had never been exposed to heat [2]. Second, REM, typically appearing near the midline of the back or chest, is histologically characterized by prominent dermal mucin deposition with perivascular lymphocytic infiltration [15]. Our patients' skin lesions were located on the lower extremities where REM is less likely to occur. Lastly, erythema infectiosum, a kind of viral exanthems, may also be accompanied by reticular eruptions [2]. However, our patients had no clinical symptoms of infection, such as fever or chills. Moreover, the normal CRP levels and absence of leukocytosis in our patients encouraged us to focus more on non-infectious causes.

Generally, no medical treatment is needed for primary LR, but cold avoidance, episodic leg elevation, and compression stockings may be beneficial in some cases [1,2,14]. However, in the case of LR with underlying systemic diseases, management of these related disorders should be executed appropriately [1,14]. Although we recommended observation without therapeutic intervention, our anxious patients strongly wanted to be prescribed medication for LR. In order to meet their strong demands and to reassure them, we prescribed antihistamines (for both of them) and topical corticosteroid (for one of them). Both of them showed clinical alleviation when they were followed-up 2 weeks later.

In conclusion, we report two rare cases of LR following ChAdOx1 nCoV-19 vaccination. This report broadens the database of cutaneous adverse reactions to ChAdOx1 nCoV-19. In addition, this report may help physicians bear in mind that the cutaneous adverse reactions of ChAdOx1 nCoV-19 can manifest as various patterns. Further research would be necessary to elucidate the detailed relationship between LR and

the COVID-19 vaccine.

ORCID

Joong Ho Kim <https://orcid.org/0000-0002-5979-6811>

Ji An Uh <https://orcid.org/0000-0002-4202-9843>

Ho Sung Kim <https://orcid.org/0000-0001-5027-6871>

Soo Kyung Lee <https://orcid.org/0000-0002-7460-5657>

Myoung Shin Kim <https://orcid.org/0000-0002-0660-8098>

Un Ha Lee <https://orcid.org/0000-0003-1626-5583>

References

- Gibbs MB, English JC 3rd, Zirwas MJ. Livedo reticularis: an update. *J Am Acad Dermatol* 2005;52:1009-19.
- Sajjan VV, Lunge S, Swamy MB, Pandit AM. Livedo reticularis: a review of the literature. *Indian Dermatol Online J* 2015;6:315-21.
- Freeman EE, McMahon DE, Lipoff JB, et al. The spectrum of COVID-19-associated dermatologic manifestations: an international registry of 716 patients from 31 countries. *J Am Acad Dermatol* 2020;83:1118-29.
- Berezne A, Bougon D, Blanc-Jouvan F, et al. Deterioration of vaccine-induced immune thrombotic thrombocytopenia treated by heparin and platelet transfusion: Insight from functional cytometry and serotonin release assay. *Res Pract Thromb Haemost* 2021;5:e12572.
- Cameli N, Silvestri M, Mariano M, Nistico SP, Cristaudo A. Pernio-like skin lesions after the second dose of Pfizer-BioNTech COVID-19 vaccine. *J Eur Acad Dermatol Venereol* 2021;35:e725-7.
- In SI, Han JH, Kang HY, Lee ES, Kim YC. The histopathological characteristics of livedo reticularis. *J Cutan Pathol* 2009;36:1275-8.
- Greinacher A, Selleng K, Palankar R, et al. Insights in ChAdOx1 nCoV-19 vaccine-induced immune thrombotic thrombocytopenia. *Blood* 2021;138:2256-68.
- Ramessur R, Saffar N, Czako B, Agarwal A, Batta K. Cutaneous thrombosis associated with skin necrosis following Oxford-AstraZeneca COVID-19 vaccination. *Clin Exp Dermatol* 2021;46:1610-2.
- Cavalli G, Colafrancesco S, De Luca G, et al. Cutaneous vasculitis following COVID-19 vaccination. *Lancet Rheumatol* 2021;3:e743-4.
- Karimi Galougahi K. Autonomic dysfunction post-inoculation with ChAdOx1 nCoV-19 vaccine. *Eur Heart J Case Rep* 2021;5:yt472.
- Bradford WD, Cook CD, Vawter GF. Livedo reticularis: a form of allergic vasculitis: report of 3 cases. *J Pediatr* 1962;60:266-76.
- Mintz MA, Jariwala N, Fang V, Coromilas A, Rosenbach M. Livedo reticularis on bilateral knees after the third dose of messenger RNA-1273 SARS-CoV-2 vaccine. *JAAD Int* 2022;7:52-3.
- Annabi E, Dupin N, Sohier P, et al. Rare cutaneous adverse effects of COVID-19 vaccines: a case series and review of the literature. *J Eur Acad Dermatol Venereol* 2021;35:e847-50.
- Dean SM. Livedo reticularis and related disorders. *Curr Treat Options Cardiovasc Med* 2011;13:179-91.
- Thareja S, Paghдал K, Lien MH, Fenske NA. Reticular erythematous mucinosis: a review. *Int J Dermatol* 2012;51:903-9.