



Dermoid Cyst of Nasal Tip with a Sinus Tract Extending to the Intracranium: A Case Report

Seungjun Lee, MD¹  Seong-Ik Kim, MD²  Min-Seo Kim, MD¹  Jong-Ho Kim, MD¹ 

¹Department of Plastic and Reconstructive Surgery, Seoul National University Bundang Hospital, Seoul, Republic of Korea

²Department of Pathology, Seoul National University Hospital, Seoul, Republic of Korea

Address for correspondence Jong-Ho Kim, MD, Department of Plastic and Reconstructive Surgery, Seoul National University College of Medicine, Seoul National University Bundang Hospital, 82 Gumi-ro 173beon-gil, Bundang-gu, Seongnam 463-707, Republic of Korea (e-mail: kjh6321@naver.com).

Arch Plast Surg 2022;49:648–651.

Abstract

Nasal dermoid cysts are rare congenital anomalies that affect one in 20,000 to one in 40,000 individuals. Herein, we report a case of an initially misdiagnosed nasal dermoid cyst with intracranial extension. Among nasal dermoids, the lesion of the nasal tip is considered uncommon. Therefore, this should always be considered as a differential diagnosis of midline nasal masses, and a proper diagnostic approach should be taken.

Keywords

- ▶ dermoid cyst
- ▶ diagnostic approach
- ▶ differential diagnosis
- ▶ intracranial extension

Introduction

Dermoid cysts are benign tumors of neuroectodermal origin, with the anterolateral frontozygomatic suture being the most common location.¹ Nasal dermoid cysts (NDCs) are rare congenital anomalies that affect one in 20,000 to one in 40,000 individuals and are classified according to the depth of the lesion from superficial to intradural lesion.^{2,3} The differential diagnoses of midline nasal masses include gliomas, encephaloceles, epidermoid cysts, and hemangiomas.^{4,5} The most widely accepted cranial theory states that in the early embryo, the dura is in contact with the skin and separates as the frontal bone forms between them. The failure of separation during this process leads to dermoid cyst formation.^{6,7} The importance of a correct preoperative diagnosis has been emphasized since intracranial extension may be present in some NDCs.⁸ In this aspect, dermoid cysts with intracranial extension may require preoperative imaging study with computed tomography (CT) or magnetic resonance imaging (MRI).⁹ The authors present a rare case of an initially misdiagnosed nasal dermoid cyst with an

intracranial extension. In this case, the authors present the appropriate management of a nasal dermoid cyst for correct diagnosis.

Case

A 2-year-old male child patient visited our hospital with a mass approximately 10 × 8 mm in size (▶ Fig. 1). The patient exhibited no signs of discharge, redness, swelling, or tenderness. Furthermore, the patient's mother denied any history of upper respiratory infection or fever. For differential diagnosis, ultrasonography (US) was performed which revealed a 7.7 × 8.4 × 10.1 mm, well-defined, low echoic lesion with no internal vascularity (▶ Fig. 2). No specific abnormal findings, such as sinus tract abnormalities, on US was detected. The impression on US was an epidermoid cyst, and thus, surgical excision was planned. Direct incision revealed a thin-walled mass, and the sinus tract connected to the lesion was identified during excision. The mass was sent to a pathologist intraoperatively since the authors suspected the possibility of NDC. After the specimen was confirmed to be a dermoid

received

January 2, 2022

accepted after revision

June 14, 2022

DOI <https://doi.org/10.1055/s-0042-1756353>.

ISSN 2234-6163.

© 2022. The Korean Society of Plastic and Reconstructive Surgeons. All rights reserved.

This is an open access article published by Thieme under the terms of the Creative Commons Attribution-NonDerivative-NonCommercial-License, permitting copying and reproduction so long as the original work is given appropriate credit. Contents may not be used for commercial purposes, or adapted, remixed, transformed or built upon. (<https://creativecommons.org/licenses/by-nc-nd/4.0/>)

Thieme Medical Publishers, Inc., 333 Seventh Avenue, 18th Floor, New York, NY 10001, USA

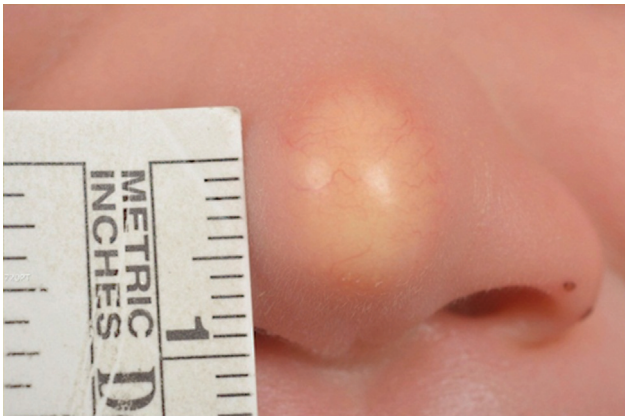


Fig. 1 Preoperative photograph showing the bulging mass of nasal midline (10 × 8 mm-sized nasal mass).

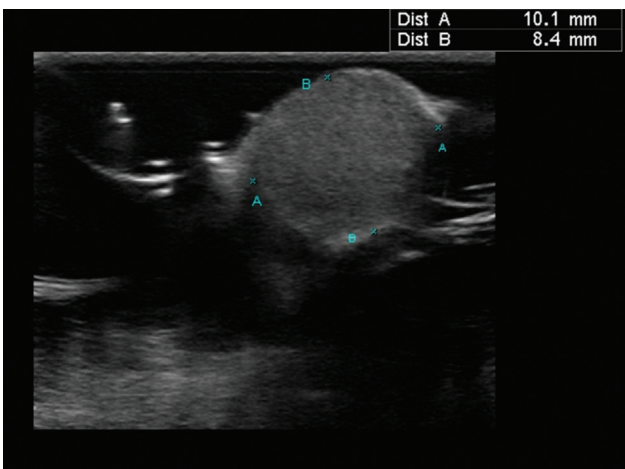


Fig. 2 Preoperative ultrasonography showing 7.7 × 8.4 × 10.1 mm-sized well-defined low echoic lesion which cannot detect intracranial tract of dermoid cyst.

cyst, meticulous dissection around the tract was performed, which revealed tract penetration of the interseptal space (► **Fig. 3**). Subsequent consultation with the neurosurgeon led to the decision to attempt the intracranial approach, if necessary, as determined by postoperative follow-up of the

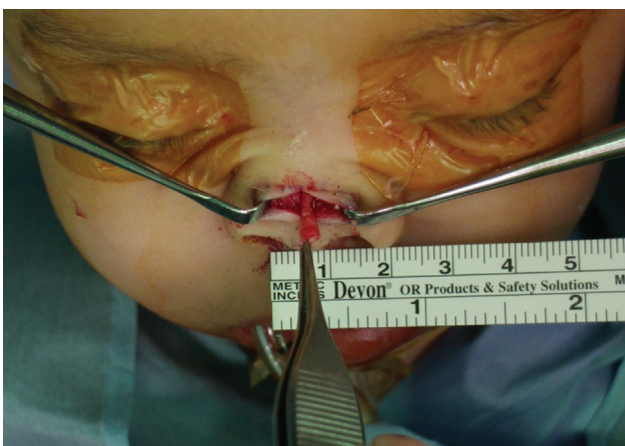

Fig. 3 Intraoperative findings. In the process of excision, intracranial tract entering into interseptal space was found.

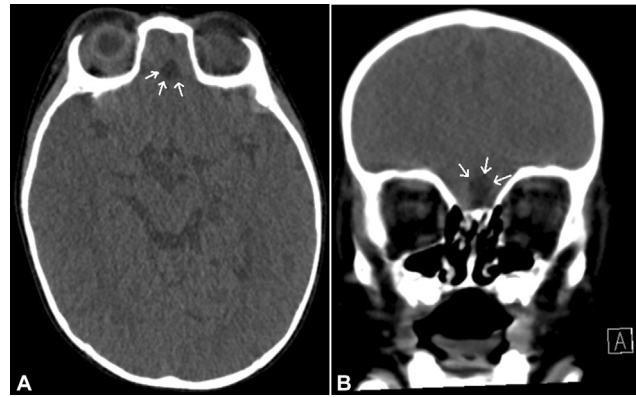


Fig. 4 Postoperative CT scanning showed cystic structure through foramen cecum (white arrow). (A) Axial view. (B) Coronal view.

lesion. The sinus tract was then ligated at the maximal superior level, and wound closure was performed. Postoperative CT revealed a cystic structure through the foramen cecum with an intracranial connection (► **Fig. 4**), while MRI revealed an approximately 1.7 cm lesion at the anterior frontal base with peripheral thin linear enhancement, which displayed T2 intermediate signal intensity and multifocal punctate T1 high signal intensity. In addition, a sinus tract between the previous and intracranial lesions and an intracranial extension to the foramen cecum were identified (► **Fig. 5**). Microscopic findings also supported the diagnosis of a nasal dermoid cyst. Examination revealed that the sinus tract was lined with a keratinized squamous epithelium (► **Fig. 6**). After the first surgery, the change in intracranial lesion was monitored using MRI and observed, as the intracranial approach was refused by the parents.

Discussion

NDCs account for 13% of all dermoids and 4 to 12% of head and neck dermoids.¹⁰ These lesions mainly present as midline masses, especially along the nasal dorsum. Moreover, the removal by external local excision is the primary management because NDCs usually present as superficial lesions.³ However, in NDCs with intracranial extension, the sinus tract passes through the cribriform plate or foramen cecum and connects to the dura, while about half of them extend to the falx cerebri or other brain structures.¹¹ Misdiagnosis and

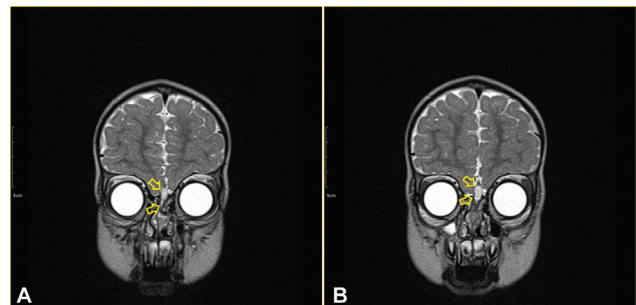


Fig. 5 (A) Postoperative magnetic resonance imaging findings. (B) T1-multifocal punctate high signal intensity lesion and dermal sinus tract between nasal cavity and intracranial lesion (yellow arrow).

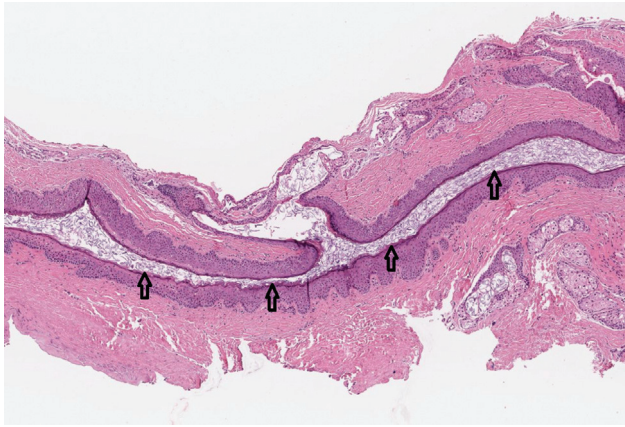


Fig. 6 Histological finding of nasal dermoid cyst (Hematoxylin eosin). The sinus tract is lined by keratinizing squamous epithelium (black arrow).

incomplete resection can lead to progressive enlargement or serious complications such as skeletal distortion, infection, meningitis, and intracranial abscess.^{12,13} Bradley reported that only three out of 74 cases had dural extension and concluded that the risk of large intracranial extension is minimal. He also recommended initial transnasal excision unless there is convincing evidence of an intracranial extension.¹⁴ Rahbar et al reported 42 cases of NDC, and only two cases of nasal tip dermoid exhibited intracranial extension.⁸ They proposed a treatment diagram of the nasal dermoid, which recommended a combined intracranial–extracranial approach in cases of intracranial extension on preoperative MRI. In addition, Winterton et al¹⁵ reported six dura-entered cases out of 19 patients and noted the presence of false positive intracranial lesions with the use of CT or MRI, which could lead to unnecessary intracranial approaches. However, in a recent large case series, they reported that lesions with intracranial extension constitute approximately 10% of all NDC. Furthermore, they proposed that classification may be performed on the basis of lesion depth or extent, which allowed proper surgical planning.³ The authors suggested that intracranial–extradural lesions could be excised through limited frontonasal osteotomy, while bicoronal flap with frontal craniotomy is suitable for intracranial–intradural lesions. Other studies advocated traditional craniotomy for the total removal of intracranial dermoid,^{16,17} but some studies have noted the success of endoscopic endonasal approach for intracranial extension of NDC.¹⁸

In the case presented, US was initially performed for differential diagnosis; however, the dermoid cyst tract could not be identified and was misdiagnosed as an epidermoid cyst. Proper diagnosis at the initial stage allows for the consideration of both intra- and extracranial approaches preoperatively.^{3,8} Hence, the suspicion of a dermoid cyst on complete physical examination prompts the use of CT or MRI.¹⁹ In cases of intracranial extension, only the extracranial or combined intracranial–extracranial approach should

be considered. As can be seen in this case, in craniofacial midline mass, we should explain to patients' parents about the possibility of intracranial dermoid cyst and the necessity of preoperative examination. In addition, if a dermoid cyst is suspected when referring to a radiologist for US, it is important to request them to confirm the presence of the stalk extending to an intracranial lesion.

This study provided an unusual presentation of NDC accompanied by intracranial extension of the dermal sinus. Preoperative misdiagnosis can lead to the loss of chance for proper treatment and unnecessary surgery. Therefore, dermoid cysts must always be considered in the differential diagnosis of midline nasal masses and prompt the use of a proper diagnostic approach.

Patient Consent

This study was approved by the institutional review board of our hospital (IRB No. B-2106–689–701) and written informed consent was obtained from the patient's parents for publication of this article and accompanying images.

Authors' Contributions

Conceptualization: J.H.K. Data curation: S.J.L., S.I.K. Formal analysis: S.J.L. Methodology: M.S.K. Project administration: J.H.K. Visualization: J.H.K., S.I.K. Writing - original draft: S.J.L., J.H.K. Writing - review & editing: S.J.L.

Conflict of Interest

None declared.

References

- Choi JS, Bae YC, Lee JW, Kang GB. Dermoid cysts: epidemiology and diagnostic approach based on clinical experiences. *Arch Plast Surg* 2018;45(06):512–516
- Hughes GB, Sharpino G, Hunt W, Tucker HM. Management of the congenital midline nasal mass: a review. *Head Neck Surg* 1980;2(03):222–233
- Hartley BE, Eze N, Trozzi M, et al. Nasal dermoids in children: a proposal for a new classification based on 103 cases at Great Ormond Street Hospital. *Int J Pediatr Otorhinolaryngol* 2015;79(01):18–22
- Sessions RB. Nasal dermal sinuses—new concepts and explanations. *Laryngoscope* 1982;92(8 Pt 2, suppl 29):1–28
- Kang KR, Lim H, Jung SW, Koh SH. Bilateral dermoid cysts on the lateral ends of eyebrows. *Arch Plast Surg* 2016;43(06):608–609
- Pratt LW. Midline cysts of the nasal dorsum: embryologic origin and treatment. *Laryngoscope* 1965;75:968–980
- Ishii N, Fukazawa E, Aoki T, Kishi K. Combined extracranial and intracranial approach for resection of dermoid cyst of the sphenoid bone with a cutaneous sinus tract across the frontal branch of the facial nerve. *Arch Craniofac Surg* 2019;20(02):116–120
- Rahbar R, Shah P, Mulliken JB, et al. The presentation and management of nasal dermoid: a 30-year experience. *Arch Otolaryngol Head Neck Surg* 2003;129(04):464–471
- Yan C, Low DW. A rare presentation of a dermoid cyst with draining sinus in a child: case report and literature review. *Pediatr Dermatol* 2016;33(04):e244–e248
- Kelly JH, Strome M, Hall B. Surgical update on nasal dermoids. *Arch Otolaryngol* 1982;108(04):239–242

- 11 Wardinsky TD, Pagon RA, Kropp RJ, Hayden PW, Clarren SK. Nasal dermoid sinus cysts: association with intracranial extension and multiple malformations. *Cleft Palate Craniofac J* 1991;28(01):87-95
- 12 Kim CS, Yoon SH, Oh JW, Lee KC. Epidermoid cyst in temple area with skull perforation. *Arch Craniofac Surg* 2020;21(02):137-140
- 13 Hanikeri M, Waterhouse N, Kirkpatrick N, Peterson D, Macleod I. The management of midline transcranial nasal dermoid sinus cysts. *Br J Plast Surg* 2005;58(08):1043-1050
- 14 Bradley PJ. The complex nasal dermoid. *Head Neck Surg* 1983;5(06):469-473
- 15 Winterton RI, Wilks DJ, Chumas PD, Russell JL, Liddington MI. Surgical correction of midline nasal dermoid sinus cysts. *J Craniofac Surg* 2010;21(02):295-300
- 16 van Aalst JA, Luerssen TG, Whitehead WE, Havlik RJ. "Keystone" approach for intracranial nasofrontal dermoid sinuses. *Plast Reconstr Surg* 2005;116(01):13-19
- 17 Rogers GF, Proctor MR, Greene AK, Mulliken JB. Frontonasal osteotomy to facilitate removal of an intracranial nasal dermoid. *J Craniofac Surg* 2005;16(04):731-736
- 18 Pinheiro-Neto CD, Snyderman CH, Fernandez-Miranda J, Gardner PA. Endoscopic endonasal surgery for nasal dermoids. *Otolaryngol Clin North Am* 2011;44(04):981-987, ix
- 19 Yoon SH, Kim CS, Oh JW, Lee KC. Schwannoma on the nasal dorsum and tip with sensory changes. *Arch Craniofac Surg* 2020; 21(06):380-383