

Scapulothoracic Mobilization for the Management of Lateral Epicondylalgia: a Case Report

Jong Won Kim¹, tae jun Heo², Ji-Won Park¹

¹Department of Physical Therapy, Daegu Catholic University, Gyongsan, Republic of Korea; ²Pureun Cheong Neurology Clinic, Daegu, Republic of Korea

Purpose: The purpose of this study was to investigate the effects of the scapulothoracic mobilization on subject with lateral epicondylalgia. This was done through lateral slide scapular test, grip strength, visual analogue scale, glenohumeral joint external rotation range of motion.

Methods: Before the experiment, Lateral slide scapular test, grip strength, visual analogue scale, glenohumeral joint external rotation range of motion were measured. Scapulothoracic joint mobilization was applied and then measurements were taken again to compared the changes.

Results: After applying the scapulothoracic joint mobilization, lateral slide scapular test, grip strength, visual analogue scale, glenohumeral joint external rotation range of motion significantly improved.

Conclusion: This study found that the scapulothoracic mobilization was effective in improving functional aspects and pain on subject with lateral epicondylalgia. The results suggest that the scapulothoracic joint mobilization is a significant considered intervention method that could be used for subject with lateral epicondylalgia.

Keywords: Lateral epicondylalgia, Scapular, Thoracic vertebrae

INTRODUCTION

The lateral epicondylitis, often called tennis elbow, is an tendinopathy involving the extensor digitorum of the lateral epicondylitis.¹ It is commonly found in people exposed to repeated and vigorous use of the forearm, biased wrist posture, and repeated grabbing.² In accordance with Shiri,³ about 12.2% of working population have lateral epicondylitis. In addition, extensor tendons of the patients who experienced pain during the extension resistance test showed changes in the fibroblast and vessels, which is part of the degenerative change. Such degenerative tendinosis results from the excessive stress on the extensor carpi radialis brevis among the extensor tendons.⁴ In response to such research results, most curative approaches tend to focus on intervening the elbow parts under the assumptions on damaged elbow joint mobility and extensor muscles of the wrist.⁵

When considering the arm lines of the fascia, however, the problems associated with arm, hand, and shoulder are caused by the compensation

pattern related to the arm lines. In addition, tender points in elbow are caused by the bad posture and lack of support. The front arm lines pass along the thumb, radius, biceps brachii muscle, and pectoralis minor muscle while superficial back line passes along the backhand, lateral epicondyle, deltoid, acromion, spine of scapula, and trapezius. Especially, the superficial back arm line is involved in the external rotation of the shoulder and it is often overused in the bad postures such as crooked shoulder and crooked vertebrae.⁶ When expanding this to the concept of kinetic chain exercise, the scapula, shoulders, and arms harmoniously cooperate together to deliver, absorb, and generate force.⁷ On the other hand, the intermediate back muscles surrounding the scapula are associated with the stability of neck, shoulders, and elbows. These muscles provide a strong surface for all shoulder and arm movements. Theoretically, the tissues of the distal limb segments require much more energy to function when the ability to maintain the scapular stability is damaged.⁸ When the upper limbs perform the functional movement, the kinetic energy gets delivered

Received Jul 18, 2022 Revised Aug 18, 2022

Accepted Aug 29, 2022

Corresponding author Ji-Won Park

E-mail mylovept@hanmail.net

Copyright ©2022 The Korean Society of Physical Therapy

This is an Open Access article distribute under the terms of the Creative Commons Attribution Non-commercial License (<https://creativecommons.org/licenses/by-nc/4.0/>) which permits unrestricted non-commercial use, distribution, and reproduction in any medium, provided the original work is properly cited.

from the upper body part to distal segments. If the scapular motion changes during the daily living, the distal segments increase the energy demand during the activities of daily living. This would result in reducing the shoulder stability and the increased energy demand would cause injuries due to overused elbows.^{9,10} Generally, the external force generated by the ground reaction force and gravitational force acting on joints are offset by joint's soft tissues and other muscles. When the center of gravity change with bad posture, however, this results in excessive external force from the gravitation and the body requires excessive internal force to balance the gravitational force and external force.^{11,12}

Especially, scapula has a significant effect on the upper limbs. According to the research by Alexander and Harrison,¹³ the research claimed that there exist a reflexive relation between hand muscle's afferent nerves and scapular muscles. The research also pointed out that serratus anterior and trapezius are activated during the flexion of lower arms and hand muscles while the scapular is adjusted and maintained during the arm lifting. The previous researches also showed the close relationship between the overused elbow and symptoms in shoulders or scapula.¹⁴ The researches by Smidt et al.¹⁵ also pointed out that the lateral epicondylitis patient's negative prognosis is related to the shoulder pain. The research by Suzuki et al.¹⁶ examined the changes in the elbow kinetics caused by the scapular muscle fatigue of the healthy men. According to this research, the scapular fatigue is assumed as the result of the compensatory motion of the elbows in relation to the elbow disorders. The research also pointed out that changes in scapular motion are related with shoulder disorder, affect the functions of distal upper muscles, and cause injuries due to overused muscles including the wrist extensor.¹⁷ Such scapular dyskinesis is defined as the alteration in the scapular position and movement pattern and it is commonly associated with the shoulder disorders.¹⁸ According to the research by Tripp et al.¹⁹ on the change of body alignment due to scapular dyskinesis, the mechanism responsible for fatigue causes the change in position of scapula, glenohumeral joint, and elbow joint and such defects affected on changing the arm position. According to research by Phadke,²⁰ it may also lead to deformity in the articular surface of the elbow, scapula, and glenohumeral joint. This also increases the risk of neck pain, shoulder pain, and non-specific arm pain.²¹ The research by Day¹⁰ also reported that the lateral epicondylitis patients showed scapular dyskinesis due to weakening of scapular muscles.

The sway-back posture also influences on the kinetics of the scapula and glenohumeral joint.²² The increased flexion of the back spine may reduce the range of raising the glenohumeral joint.²² In addition, the re-

duced range of scapular tilting and increased range of scapular raise are observed while raising the shoulders.²³ The sway-back posture also changes the center of gravity and causes the compensation movement.²² Such misaligned body posture is widely known as a slumped posture.²⁴ The curves of the changed thoracic spine influence on the shoulder girdle through the muscle insertion points and eventually change the length-tension relationship of the scapular muscles.²⁵ The increased sway-back posture observed in the slumped posture decreases the shoulder joint's range of motion.²⁶ The slumped posture also has a negative kinematic impact on the scapular and glenohumeral joint while the increased flexion of back spine results in reducing the glenohumeral joint's range of motion.²⁷ The shoulder girdle is a complex musculoskeletal system which requires the coordination of muscle fascicles branching from the thoracic wall and elbows. The bones consisting the shoulder girdle influence on each other. The increased scapulothoracic joint movement for raising the arm glenohumeral joint leads to higher shoulder joint strength. The increase in space between the humerus head's radius and glenohumeral joint results in more shoulder joint strength. The space between the humerus head's radius, acromion, and humerus and movement of scapula leads to kinematic influence on the glenohumeral joint.²⁸ The increase in space between humerus head's radius and humerus also increase the muscle weight. Eventually, the muscle force, in other words, joint force, will decrease.²⁹ Thus, the change in shoulder girdle due to severe sway-back posture may result in narrowing the subacromial space and shortening the humerus head's radius. Furthermore, the tension in the shoulder girdle may increase the kinematic on the glenohumeral joint and elbow joint.

The movement of scapulothoracic joint is also considered as an important clinical index and recovering the normal kinematics of scapulothoracic joint is one of the main goals in the non-surgical physical therapy and post-surgical rehabilitation.²⁹ Surenkok et al.³⁰ applied a scapular joint manipulation on patients with shoulder pain and limited shoulder movement and reported that the manipulation had positive effects on the upward scapular rotation and shoulder joint's range of motion. There are also various potential mechanisms, such as the referred pain from neck or back, which may influence on the lateral on patients.³¹ The disorders caused by neck and back pain are commonly known for causing the referred pain in the lateral elbow areas³² and other numbers of researches also pointed out that lateral epicondylitis patients show extensive mechanical pain and hyperalgesia at the same time.^{33,34}

The first phase of hyperalgesia is the tissue injuries and this leads to changes in the afferent nerve's pain receptors and peripheral sensitization

associated with increasing the neural reaction against the harmful stimulation, and lowering the threshold level against the harmful stimulation.^{35,36} The according hyperalgesia is defined as the lowering of the pain threshold level against the harmful stimulation and it is divided into two types; The primary hyperalgesia occurs at the site of injury and the secondary hyperalgesia occurs at areas surrounding the injury site. The primary hyperalgesia is associated with the lowering of pain threshold level against the mechanical pain and thermal stimulation while the secondary hyperalgesia is associated with lowering of pain threshold level against the mechanical pain.³⁷ Since lateral epicondylitis patients often show mechanical pains more than thermal hyperalgesia, the patients show the characteristics of the secondary hyperalgesia.^{38,39} Considering such grounds, Scapulothoracic mobilization on neck is effective for treating the lateral epicondylitis patients.⁴⁰

For the purpose and hypothesis, this paper targeted on the influence of back spine joint and scapular muscle relaxation on the balance of scapula, functional recovery of upper body, and elbow pain relief. This paper examined the effects of joint manipulation intervention on back spine joint and scapula for balancing the scapular, recovering the upper body functions, and relieving the pains of lateral epicondylitis. There are only few researches that targeted on the organically connected segments in the elbow pain patients. While there have been researches on the topical elbow treatments, there needs to be active clinical researches on the elbow pain caused by the functional defects of the organically connected body segments. Such clinical researches hold a significance for allowing the therapists to have more diverse intervention approaches to elbow pain patients by assuming the organic connection between the multiple segments.

METHODS

1. Subjects

This paper targeted on a subject who has been experiencing the trigger points on the lateral epicondyle for about 1 year without getting any musculoskeletal surgery and past treatment history. In addition, no other treatment was performed during the experimental period. This paper conducted Cozen Test and Maudsley widely used for the medical diagnosis of lateral epicondylitis and the subject was positive for lateral epicondylitis.⁴¹ The subject also showed sway-back posture, uneven scapula, and pain during glenohumeral joint external rotation. The subject was a right-handed, 59-year-old male with height, weight, and BMI of 172.4cm, 71.0 kg, and 23.3kg/m². The subject signed an agreement form before the tests

and was given the detailed explanations in advance.

2. Experimental methods

1) Procedure

This paper was conducted by adopting the format of case report. Total of 10 interventions were performed for 10 minutes and twice a week. The last 10th intervention was performed in two-week interval from the previous intervention to track the effects. After measuring the pre-intervention range of motion for shoulder, lateral slide scapular test (LSST), grip strength, and visual analogue scale (VAS), this paper referred to the Osteopathy Articulation and Manipulation Techniques, performed the scapulothoracic mobilization and scapular mobilization for five minutes respectively, and measured the post-intervention range of motion, LSST, grip strength, and VAS.

2) Measurement

(1) Range of Motion for Shoulder

For the objective measurement of the range of motion for shoulders, this paper used an integrated musculoskeletal analysis system, Exbody 720 PA (Exbody Inc., Seoul, Korea), and used the Exbody posture analyzer software program to quantify. To secure the reliability of measurement, the same tester instructed the measurement posture of the subject for every session. To measure the angle, the subject was instructed to step on a measurement device, stand on side, and perform the shoulder joint external rotation while abducting the shoulder joint to 90 degrees and bending the elbow to 90 degrees (Figure 1).

(2) Lateral Scapular Slide Test (LSST)

To quantify the uneven scapular in objective figures, this paper conducted a reliable assessment method, LSST Test. The test was performed in three positions. Position 1 involves standing on a neutral position, with the arms




Figure 1. The picture of measurement of the range of motion using the X-body.

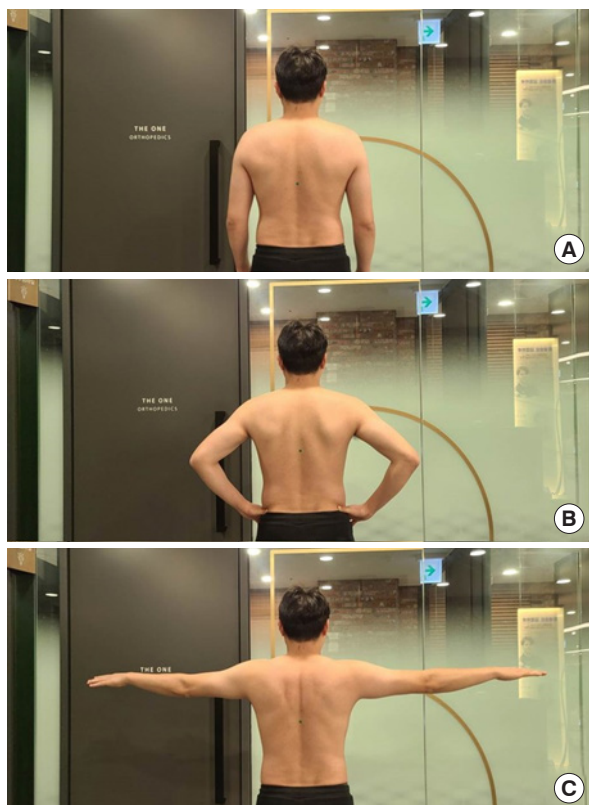


Figure 2. Three position for the lateral scapular slide test. (A) First position: arms at the side. (B) Second position: hands on the hips. (C) Third position: arms at or below 90° abduction, with glenohumeral internal rotation.

relaxed at the sides. Position 2 involves placing the hands on the lateral iliac crest and putting the thumb to back. Position 3 involves keeping the arms abducted to left and right sides. In the test, the differences in left and right sides were compared by moving horizontally in spinal directions from the inferior angle of the scapula and measuring the distance to the vertical line formed by the spinous process of the vertebra (Figure 2).⁷

(3) Grip strength

For the objective measurement of the grip strength, this paper used a digital dynamometer (Commander™ Grip Track, J-Tech™, Chester springs, USA). The subject was made to keep a sedentary position, bend knee joints by 90-degrees, and put the arms on a desk for a natural 90-degree elbow angle to put the low arms in a neutral position. The grip strength was measured total of three times for 5 seconds from the measurer's signals of "Start" to "Stop". The subject was also given a one-minute break time between each measurement to prevent the variables associated with the muscle fatigue.⁴²

(4) Visual Analog Scale (VAS)

To measure the subjective pain of the subject before and after the treatment, this paper used VAS (Visual Analog Scale) to measure the degree of pain felt at the trigger points at lateral epicondyle. Then, the subject was instructed to place a mark on a 100 millimeter-long line to describe the pain. The subject was given the explanation on the left (no pain) and the right (extreme pain) of the line. The subjective pain was measured by measuring the length from the mark placed by the subject to the left side.⁴³

To enhance the reliability of the measurement, the range of motion, LSST, grip strength, and VAS of the subject were measured before and after the intervention by a physical therapist with over 9 years of clinical experiences. To minimize the confounding variables, the measurement and intervention were performed by different people. All the interventions were performed by a physical therapist with over 8 years of clinical experiences. In addition, the measurement and intervention were performed under the identical conditions and procedures from January 21, 2022 to March 7, 2022 for the standardization.

3) Intervention

This paper referred to Osteopathy Articulation and Manipulation Techniques and performed the two types of interventions, Scapulothoracic mobilization and scapular mobilization, for five minutes respectively.

(1) Scapulothoracic mobilization

The subject lied flat on a pillow and the interventionist crossed the both arms of the subject so that each hand would touch the scapular of the opposite side. Then, interventionist used a distal arm to hold the overlapping elbow part in place and to hold and pull the distal shoulders. The other arm was placed on vertebrae with a loosely clenched fist. After the subject lied flat on the back and crossed the elbows, the subject's low arm was pressured to mobilize the vertebrae. The Scapulothoracic mobilization was performed by checking on the various ranges of motion including rotation, lateral flexion, flexion, and translational motion in the spinal traction direction (Figure 3).

(2) Scapular mobilization

The subject lied in a lateral recumbent position on a pillow facing the interventionist, bended elbow and placed the upper arm on a navel, and bended both knees. The interventionist stood close to the subject's trunk and placed fingers under the medial border of the scapula to hold the scapula. Then, the interventionist placed the sternum to hold the subject's

shoulders in place, hold scapular in both hands, and perform the mobilization (Figure 3).

3. Statistical Analysis

To verify the effects of Scapulothoracic mobilization and scapular mobilization, this paper came up with the descriptive statistics on the pre-inter-

vention and post-intervention measurements for the first and the last day. To examine the changes in the subject during the test, this paper made a visual graph on the pre-intervention and post-intervention measurements for every session and compared the changes in range of motion, LSST, grip strength, and VAS.

RESULTS

After applying the scapulothoracic joint mobilization on the subject with lateral epicondylalgia, lateral slide scapular test and grip strength of the function significantly improved. In addition, visual analogue scale of pain significantly decreased.

1. Change in ROM

In Figure 4A, this paper visualized the changes in the range of motion for the shoulder external rotation before and after the Scapulothoracic mobilization and scapular mobilization. On the first day, the range of motion started from 84° and improved to 91° after the intervention. The subject showed constant improvements throughout the test. In the 9th session, the range of motion started from 99° to 150° after the intervention. Compared to the first day, the pre-intervention angle improved by 15° and post-intervention angle improved by 14°. The follow-up test was performed after two weeks and the subject maintained the intervention effects with pre-intervention and post-intervention angles of 100° and 105° respectively (Figure 4).

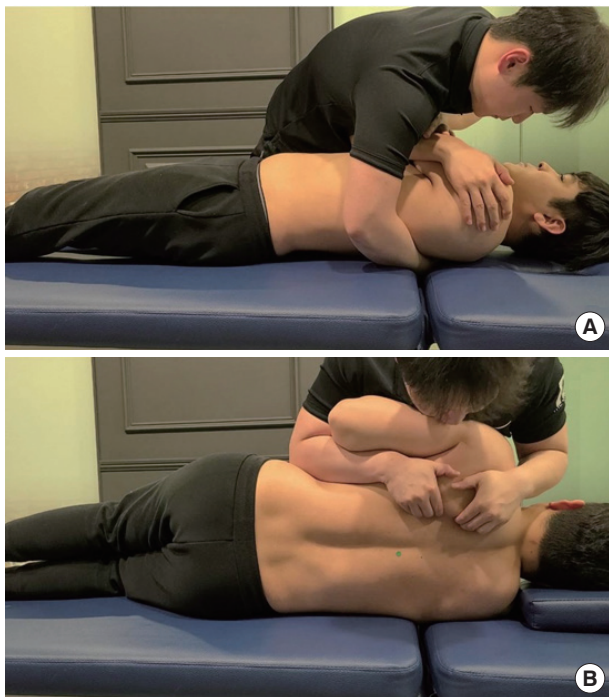

Figure 3. The picture of application of therapeutic interventions. (A) Scapulothoracic mobilization. (B) Scapular mobilization.

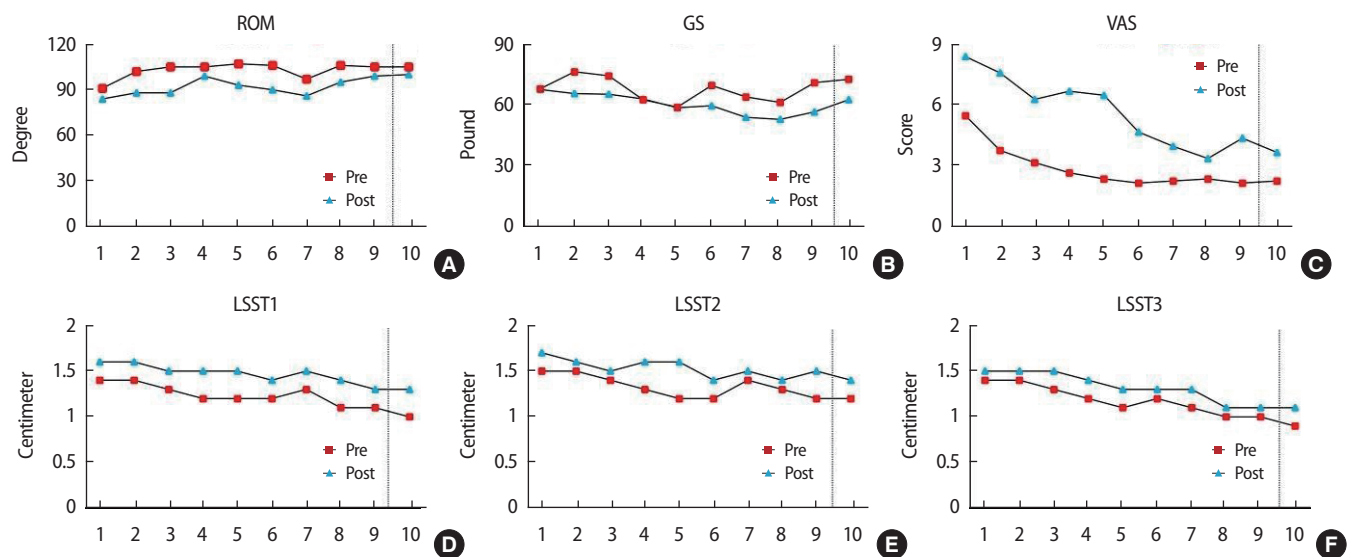


Figure 4. Graph of changes in measurements during the experiment.

2. Change in Grip strength

In Figure 4B, this paper visualized the changes in the grip strength before and after the Scapulothoracic mobilization and scapular mobilization with a graph. On the first day, the grip strength started from 67.67lb and slightly improved to 68lb after the intervention. Throughout the test, the pre-intervention grip strength slightly decreased while post-intervention grip strength remained. In the 9th session, the pre-intervention grip strength was 56.67lb and post-intervention grip strength was 71lb. Compared to the first day, pre-intervention grip strength reduced by 11lb while post-intervention grip strength increased by 3lb. The follow-up test was performed after two weeks and the subject maintained the intervention effects with pre-intervention and post-intervention grip strengths of 62.67lb and 72.67lb respectively (Figure 4).

3. Change in VAS

In Figure 4C, this paper visualized the changes in the VAS before and after the Scapulothoracic mobilization and scapular mobilization with a graph. On the first day, the pre-intervention VAS was 8.4 and post-intervention VAS was 5.5. The subject showed gradual improvements in VAS throughout the test. In the 9th session, the pre-intervention VAS was 4.4 and post-intervention VAS was 2.2. When compared to the first day, the pre-intervention VAS decreased by 4 while post-intervention VAS decreased by 3.3 on the 9th session. In the follow-up test given after two weeks, the subject maintained the intervention effects with pre-intervention and post-intervention VAS of 3.7 and 2.3 respectively (Figure 4).

4. Change in LSST

In Figure 4D-F this paper visualized the changes in the LSST for measuring uneven scapular before and after the Scapulothoracic mobilization and scapular mobilization with a graph. In position 1, the subject started with 1.6cm difference before the intervention and improved to 1.4cm after the intervention. The subject gradually improved LSST as the test proceeded. In the 9th session, the subject showed the pre-intervention and post-intervention of 1.3cm and 1.1cm respectively. Compared to the first day, the pre-intervention and post-intervention difference decreased by 0.3cm respectively on the 9th session. In the follow-up test performed two weeks later, the subject maintained the intervention effects with pre-intervention and post-intervention difference of 1.3cm and 1cm respectively. In the position 2, the subject started with 1.7cm and improved to 1.5cm on the first day and the subject consistently improved along the test. In the 9th session, the subject showed the pre-intervention and post-intervention

of 1.5cm and 1.2cm respectively by decreasing 0.2cm and 0.3cm. In the follow-up test performed two weeks later, the subject kept the intervention effect with pre-intervention and post-intervention difference of 1.4cm and 1.2cm respectively. In position 3, the pre-intervention difference was 1.5cm and post-intervention difference was 1.4 on the first day with gradual improvements along the sessions. In the 9th session, the pre-intervention and post-intervention differences were 1.1cm and 1cm respectively showing the decrease by 0.4cm compared to the first day. In the follow-up test given two weeks later, the subject maintained the intervention effect with pre-intervention and post-intervention difference of 1.1cm and 0.9 cm respectively (Figure 4).

DISCUSSION

The scapulothoracic joint movement is closely associated with the humerothoracic axial rotation during the arm raise, external rotation, and lateral adduction with the upward scapular rotation.⁴⁴ According to the research by Smidt et al.¹⁵ the lateral epicondylitis patient's negative prognosis is related to the shoulder pain. The vertebral posture also has kinematic influence on the scapular and glenohumeral joint. The increased vertebral flexion results in reducing the range of motion for the glenohumeral joint.²⁷ Ucurum et al.⁹ also pointed out that the muscles associated with shoulder external rotation are weakened by the compensatory injuries from the wrist extensor. The research also found out that lateral epicondylitis patients show weaker shoulder external rotation compared to the normal group. Lucado et al.¹⁷ also claimed that the weakening of the shoulder external rotation muscles increases the movement of distal segments and causes the lateral epicondylitis. In this paper, the subject also showed a limited range of motion due to the pain during the shoulder external rotation. To examine the increase in the shoulder joint's range of external rotation from increased functional movement of the spine, this paper measured the range of lateral glenohumeral joint rotation before and after the intervention. According to results, the subject showed improvement in the range of shoulder external rotation, which was limited due to the shoulder pain. The subject also maintained and improved the range of motion for each session. In the follow-up test given after two weeks, the subject maintained the intervention effect, too.

In the kinematic chain, shoulder girdle is composed of the scapular, shoulder, and arms and these components organically cooperate together to deliver and absorb force for the movement.⁷ The previous researches pointed out that the overused elbow is mainly associated with shoulder

and scapular dyskinesis¹⁴ and that the uneven scapular is associated with dysfunction and injuries of the upper limbs. In addition, Kibler et al.⁷ used the lateral scapular side test (LSST) to examine the relationship between the reduced muscle stability and distance between scapular and vertebrae in the shoulder and shoulder joint dysfunction. To examine the scapular alignment, the muscular force was quantified as a scapular stabilizer and reliable LSST test was adopted to measure the uneven scapular. In LSST, lateral epicondylitis patients showed higher positive rates and also involved the low shoulder external rotation, grip strength, and low muscular force of trapezius and middle trapezius.⁹ According to the research results, the lateral epicondylitis patient showed lower positive rates in 3 LSST positions after the treatment and the rates also decreased over the sessions. The lateral epicondylitis also maintained the intervention effect in the follow-up test performed after two weeks.

Numbers of researches reported the reduction of grip strength in the lateral epicondylitis patients.⁴⁵ Such weakening of grip strength is related to weakening of upper body due to closed kinetic chain in the distal segments.⁴⁶ It was also observed that the lateral epicondylitis patient shows higher grip strength by holding the scapula in place.⁵ In the test, the subject showed remarkable increase in the grip strength after the intervention. However, the grip strength gradually weakened over the session and eventually returned to the original grip strength. In addition, the subject showed the same results in the follow-up test given after two weeks. The weakening of grip strength is associated with weakening of upper body due to distal segments' closed kinetic chain.⁵ Mandalidis et al.⁴⁷ also showed the relationship between the grip strength and shoulder muscle strength of the healthy people. Thus, it is assumed that the subject's grip strength weakened over the session due to lack of interventions for strengthening the muscles around scapula and shoulder girdle.

The scapular mobilization recovers the range of scapular motion, reduces frozen shoulders, and strengthens the proprioception to sense location. In addition, joint manipulation technique reduces the pressure to recover the contracted tissues such as shortened or fibrosis muscle tissues around the joint.⁴⁸ In a research by Fanti,⁴⁹ it was reported that scapular mobilization relieves the anterior tilt, medial rotation, downward rotation, and protrusion. The scapular mobilization also changed the scapular stabilizer position. In the research by Berglund,⁵⁰ 16 of patient groups didn't experience pain while 70% of lateral epicondylitis patients experienced pain in cervical vertebrae and back vertebrae. In addition, lateral epicondylitis patients were highly positive in the provocation test on the cervical and back vertebrae as well as the neural manipulation on the radial nerve.

The back vertebral manipulation improves the limited range of motion in the spine, recovers the sliding in the articular surface, and normalizes the articular capsules to relieve the sway-back posture and strengthen the flexibility in the back extension. Such improved range of motion in the vertebrae is reported to improve the pulmonary function.⁵¹ Moreover, the Scapulothoracic mobilization is reported to alter the muscular strain, relieve the excessive strain,⁵² facilitates the neural pathway, and controls inhibition to enhance the muscular functions.⁵³ In accordance with the research by Bisset,⁵⁴ the lateral epicondylitis patients were given a Scapulothoracic mobilization and 19.8% of them showed higher grip strength after the manipulation. The groups treated with a spinal correction also showed less symptoms of sway-back posture by recovering the angle of spinal flexion.⁵⁵ In this paper, the subject showed remarkably less pain after the intervention. As the subject proceeded with the test, the subject showed less pain and maintained the intervention effects. The subject also maintained the intervention effects in the follow-up test given after two weeks.

This paper involves following limitations. First, this paper is a single subject research with limited number of subject and thus hard to generalize from the results. The further researches need to expand the subjects with test groups and control groups. Second, this paper could not limit the daily living activities of the subject which may influence on the dependent variables during the intervention period. The further researches need to extend the intervention period and prove the long-term effects on the elbow pain.

REFERENCES

1. Kraushaar BS, Nirschl RP. Tendinosis of the elbow (tennis elbow). clinical features and findings of histological, immunohistochemical, and electron microscopy studies. *J Bone Joint Surg Am.* 1999;81(2):259-78.
2. Shiri R, Viikari-Juntura E, Varonen H et al. Prevalence and determinants of lateral and medial epicondylitis: a population study. *Am J Epidemiol.* 2006;164(11):1065-74.
3. Shiri R, Viikari-Juntura E. Lateral and medial epicondylitis: role of occupational factors. *Best Pract Res Clin Rheumatol.* 2011;25:43-57.
4. Micheal A, Scott C, Brian G. *NASM essentials of corrective exercise training.* 1st ed. Massachusetts, Jones & Bartlett Learning, 2013:355.
5. Bhatt JB, Glaser R, Chavez A et al. Middle and lower trapezius strengthening for the management of lateral epicondylalgia: a case report. *J Orthop Sports Phys Ther.* 2013;43(11):841-7.
6. Myers TW. *Anatomy trains: myofascial meridians for manual and movement therapists.* 3rd ed. France, Elsevier Masson, 2013:161-84.
7. Kibler WB. The role of the scapula in athletic shoulder function. *Am J Sports Med.* 1998;26(2):325-37.

8. Putnam CA. Sequential motions of body segments in striking and throwing skills: descriptions and explanations. *J Biomech.* 1993;26(1):125-35.
9. Ucurum SG, Karabay D, Ozturk BB et al. Comparison of scapular position and upper extremity muscle strength in patients with and without lateral epicondylalgia: a case-control study. *J Shoulder Elbow Surg.* 2019;28(6):1111-9.
10. Day JM, Bush H, Nitz AJ et al. Scapular muscle performance in individuals with lateral epicondylalgia. *J Orthop Sports Phys Ther.* 2015;45(5):414-24.
11. Carol A. *The mechanics and pathomechanics of human movement.* 2nd ed. Philadelphia, Lippincott Williams & Wilkins, 2008:113.
12. Bullock-Saxton J. Normal and abnormal postures in the sagittal plane and their relationship to low back pain. *Physiother Pract.* 1988;4(2):94-104.
13. Alexander CM, Harrison PJ. Reflex connections from forearm and hand afferents to shoulder girdle muscles in humans. *Exp Brain Res.* 2003;148(3):277-82.
14. Ellenbecker TS, Nirschl R, Renstrom P. Current concepts in examination and treatment of elbow tendon injury. *Sports Health.* 2013;5(2):186-94.
15. Smidt N, Lewis M, Van der Windt DA et al. Lateral epicondylitis in general practice: course and prognostic indicators of outcome. *J Rheumatol.* 2006;33(10):2053-9.
16. Suzuki H, Swanik KA, Huxel KC et al. Alterations in upper extremity motion after scapular-muscle fatigue. *J Sports Rehabil.* 2006;15(1):71-88.
17. Lucado AM, Kolber MJ, Cheng MS et al. Upper extremity strength characteristics in female recreational tennis players with and without lateral epicondylalgia. *J Orthop Sports Phys Ther.* 2012;42(12):1025-31.
18. Ludewig PM, Cook TM. Alterations in shoulder kinematics and associated muscle activity in people with symptoms of shoulder impingement. *Phys Ther.* 2000;80(3):276-91.
19. Tripp BL, Yochem EM, Uhl TL. Functional fatigue and upper extremity sensorimotor system acuity in baseball athletes. *J Athl Train.* 2007;42(1):90-8.
20. Phadke V, Camargo P, Ludewig P. Scapular and rotator cuff muscle activity during arm elevation: a review of normal function and alterations with shoulder impingement. *Rev Bras Fisioter.* 2009;13(1):1-9.
21. Lewis JS, Wright C, Green A. Subacromial impingement syndrome: the effect of changing posture on shoulder range of movement. *J Orthop Sports Phys Ther.* 2005;35(2):72-87.
22. Borstad JD. Resting position variables at the shoulder: evidence to support a posture-impairment association. *Phys Ther.* 2006;86(4):549-57.
23. Erkan S, Yercan HS, Okcu G et al. The influence of sagittal cervical profile, gender and age on the thoracic kyphosis. *Acta Orthop Belg.* 2010;76(5):675-80.
24. Jung SI, Lee NK, Kang KW et al. The effect of smartphone usage time on posture and respiratory function. *J Phys Ther Sci.* 2016;28(1):186-9.
25. Michener LA, McClure PW, Karduna AR. Anatomical and biomechanical mechanisms of subacromial impingement syndrome. *Clin Biomech.* 2003;18(5):369-79.
26. Barrett E, O'Keeffe M, O'Sullivan K et al. Is thoracic spine posture associated with shoulder pain, range of motion and function? a systematic review. *Man Ther.* 2016;26:38-46.
27. Kebaetse M, McClure P, Pratt NA. Thoracic position effect on shoulder range of motion, strength, and three-dimensional scapular kinematics. *Arch Phys Med Rehabil.* 1999;80(8):945-50.
28. Flores-Hernandez C, Eskinazi I, Hoenecke HR et al. Scapulothoracic rhythm affects glenohumeral joint force. *JSES Open Access.* 2019;3(2):77-82.
29. Uhl TL, Kibler WB, Gecewich B et al. Evaluation of clinical assessment methods for scapular dyskinesis. *Arthroscopy.* 2009;25(11):1240-8.
30. Surenkok O, Aytar A, Baltaci G. Acute effects of scapular mobilization in shoulder dysfunction: a double-blind randomized placebo-controlled trial. *J Sport Rehabil.* 2009;18(4):493-501.
31. Vicenzino B, Collins D, Wright A. The initial effects of a cervical spine manipulative physiotherapy treatment on the pain and dysfunction of lateral epicondylalgia. *Pain.* 1996;68(1):69-74.
32. DeFranca GG, Levine LJ. The T4 syndrome. *J Manipulative Physiol Ther.* 1995;18(1):34-7.
33. Fernández-Carnero J, Fernández-de-Las-Peñas C, de la Llave-Rincón AI et al. Widespread mechanical pain hypersensitivity as sign of central sensitization in unilateral epicondylalgia: a blinded, controlled study. *Clin J Pain.* 2009;25(7):555-61.
34. Fernández-Carnero J, Fernández-de-las-Peñas C, de la Llave-Rincón AI et al. Bilateral myofascial trigger points in the forearm muscles in patients with chronic unilateral lateral epicondylalgia: a blinded, controlled study. *Clin J Pain.* 2008;24(9):802-7.
35. Graven-Nielsen T. Fundamentals of muscle pain, referred pain, and deep tissue hyperalgesia. *Scand J Rheumatol Suppl.* 2006;122:1-43.
36. Mense S. Peripheral mechanism of muscle nociception and local muscle pain. *J Musculoskelet Pain.* 1993;1(1):133-70.
37. Wall P, McMahon SB, Koltzenburg M. Wall and Melzack's textbook of pain. In: Meyer R, eds. *Peripheral mechanisms of cutaneous nociception.* New York, Churchill Livingstone, 2006:3-34.
38. Vicenzino B, Wright A. Lateral epicondylalgia I: epidemiology, pathophysiology, aetiology and natural history. *Physical Ther Rev.* 1996;1:23-34.
39. Wright A, Thurnwald P, Smith J. An evaluation of mechanical and thermal hyperalgesia in patients with lateral epicondylalgia. *Pain Clin.* 1992;5:221-7.
40. Vicenzino B. Lateral epicondylalgia: a musculoskeletal physiotherapy perspective. *Man Ther.* 2003;8(2):66-79.
41. Fairbank SM, Corlett RJ. The role of the extensor digitorum communis muscle in lateral epicondylitis. *J Hand Surg Br.* 2002;27:405-9.
42. Pienimäki TT, Siira PT, Vanharanta H. Chronic medial and lateral epicondylitis: a comparison of pain, disability, and function. *Arch Phys Med Rehabil.* 2002;83:317-21.
43. Jensen MP, Chen C, Brugger AM. Interpretation of visual analogue scale rating and change score: a reanalysis of two clinical trials of post operative pain. *J Pain.* 2003;4(7):407-14.
44. Aliaj K, Lawrence RL, Bo Foreman K et al. Kinematic coupling of the glenohumeral and scapulothoracic joints generates humeral axial rotation. *J Biomech.* 2022;136:111059.
45. De Smet L, Fabry G. Grip force reduction in patients with tennis elbow: influence of elbow position. *J Hand Ther.* 1997;10(3):229-31.
46. Alizadehkhayat O, Fisher AC, Kemp GJ et al. Upper limb muscle imbalance in tennis elbow: a functional and electromyographic assessment. *J Orthop Res.* 2007;25(12):1651-7.

47. Mandalidis D, O'Brien M. Relationship between hand-grip isometric strength and isokinetic moment data of the shoulder stabilisers. *J Bodyw Mov Ther.* 2010;14(1):19-26.
48. Maitland GD, Hengeveld E, Banks K. *Maitland's peripheral manipulation.* 1st ed. Oxford, Butterworth-Heinemann, 2005:336-8.
49. Fani M, Ebrahimi S, Ghanbari A. Evaluation of scapular mobilization and comparison to pectoralis minor stretching in individuals with rounded shoulder posture: a randomized controlled trial. *J Bodyw Mov Ther.* 2020;24(4):367-72.
50. Berglund KM, Persson BH, Denison E. Prevalence of pain and dysfunction in the cervical and thoracic spine in persons with and without lateral elbow pain. *Manual Therapy.* 2008;13(4):295-9.
51. Hwangbo PN, Hwangbo G, Park J et al. The effect of thoracic joint mobilization and self-stretching exercise on pulmonary functions of patients with chronic neck pain. *J Phys Ther Sci.* 2014;26(11):1783-6.
52. Esposito S, Philipson S. *Spinal adjustment technique: the chiropractic art.* 1st ed. New South Wales, S Philipson and S. Esposito, 2005:234-78.
53. Pickar JG. Neurophysiological effects of spinal manipulation. *Spine J.* 2002;2(5):357-71.
54. Bisset L, Smidt N, Van der Windt DA et al. Conservative treatments for tennis elbow do subgroups of patients respond differently? *Rheumatology.* 2007;46(10):1601-5.
55. Moodley M, Branco KC. Chiropractic manipulative therapy of the thoracic spine in combination with stretch and strengthening exercises, in improving postural kyphosis in woman. *Health SA.* 2016;21(1):303-8.