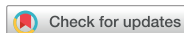

Images in
Cardiovascular Medicine



Left Ventricular Apical Aneurysm: Atypical Feature of Cardiac Sarcoidosis Diagnosed by Multimodality Imaging

Shin-Jae Kim , MD, PhD, Soe Hee Ann , MD, PhD, Yong-Giun Kim , MD, PhD,
and Sangwoo Park , MD

Division of Cardiology, Department of Internal Medicine, Ulsan University Hospital, University of Ulsan
College of Medicine, Ulsan, Korea

OPEN ACCESS

Received: Sep 7, 2021
Revised: Oct 28, 2021
Accepted: Nov 17, 2021
Published online: Dec 7, 2021

Correspondence to
Shin-Jae Kim, MD, PhD

Division of Cardiology, Department of
Internal Medicine, Ulsan University Hospital,
University of Ulsan College of Medicine, 877,
Bangeojinsunhwando-ro, Dong-gu, Ulsan
44033, Korea.
Email: kimsj226@gmail.com

Copyright © 2022. The Korean Society of
Cardiology

This is an Open Access article distributed
under the terms of the Creative Commons
Attribution Non-Commercial License ([https://
creativecommons.org/licenses/by-nc/4.0](https://creativecommons.org/licenses/by-nc/4.0))
which permits unrestricted noncommercial
use, distribution, and reproduction in any
medium, provided the original work is properly
cited.

ORCID iDs

Shin-Jae Kim
<https://orcid.org/0000-0003-0426-8947>
Soe Hee Ann
<https://orcid.org/0000-0001-8743-4298>
Yong-Giun Kim
<https://orcid.org/0000-0002-0816-9025>
Sangwoo Park
<https://orcid.org/0000-0003-3943-8029>

Funding

The authors received no financial support for
the research, authorship, and/or publication
of this article.

Conflict of Interest

The authors have no financial conflicts of
interest.

<https://e-kcj.org>

A 57-year-old man was admitted for cardiac sarcoidosis work-up. He had been suffering from dermal sarcoidosis in both his lower legs for 7 years. He denied symptom of chest pain. Transthoracic echocardiography revealed akinesia and a focal aneurysm at the left ventricular (LV) apex (**Figure 1A and B, Supplementary Video 1**). Coronary angiography and coronary computed tomography revealed dual left anterior descending artery (LAD) type 4¹⁾; a short LAD from the left main coronary artery (**Figure 2B**) and a long LAD of anomalous origin from the right coronary sinus with mild compression by right ventricular outflow tract (**Figure 2A and B**). Cardiac magnetic resonance imaging (CMR) revealed an aneurysmal change and transmural late-gadolinium enhancement (LGE) at the LV apex, and subendocardial LGE of anterior and lateral walls (**Figure 3**) which were not compatible with typical cardiac sarcoidosis because of aneurysmal change of LV apex and subendocardial involvement.²⁾ On a resting ¹⁸F-fluorodeoxyglucose positron emission tomography (FDG-PET) scan, there was high uptake at the LV apex, including the lateral and anterior walls (**Figure 4**), indicative of cardiac sarcoidosis.³⁾ It is assumed that myocardial necrosis due to granulomatous inflammation induced LV apical aneurysm in this patient.⁴⁾

This case reflects the importance of screening for cardiac sarcoidosis in patients with extracardiac sarcoidosis.⁵⁾ Although the findings of CMR in this case are not typical of cardiac sarcoidosis, in a case with past history of extracardiac sarcoidosis, they should be regarded as diagnostic clues for cardiac sarcoidosis. Such a situation warrants further imaging assessments, such as an FDG-PET scan.³⁾

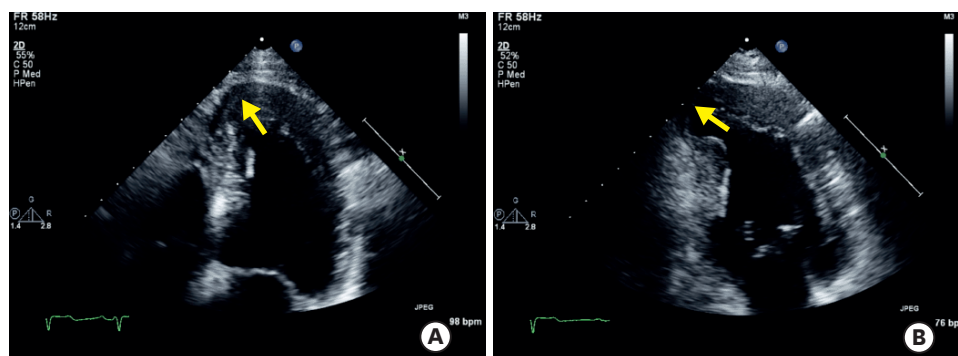


Figure 1. Apical 4-chamber (A) and 2-chamber view (B) revealing akinesia and a focal aneurysm at the left ventricular apex (yellow arrows).

Data Sharing Statement

The data generated in this study is available from the corresponding author upon reasonable request.

Author Contributions

Conceptualization: Kim SJ; Writing - original draft: Kim SJ; Writing - review & editing: Kim SJ, Ann SH, Park S, Kim YG.

The Institutional Review Board (IRB) of Ulsan University Hospital approved this study and the patient's informed consent was waived (IRB number: UUH202108038-HE003).

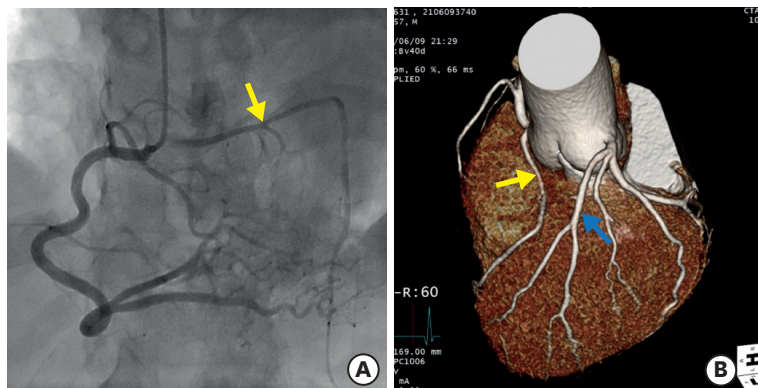


Figure 2. Coronary angiography (A) and coronary computed tomography (B) revealing dual LAD type 4; the long LAD of anomalous origin from the right coronary sinus with mild compression by right ventricular outflow tract (yellow arrows) and the short LAD from the left main coronary artery (blue arrow). LAD = left anterior descending artery.

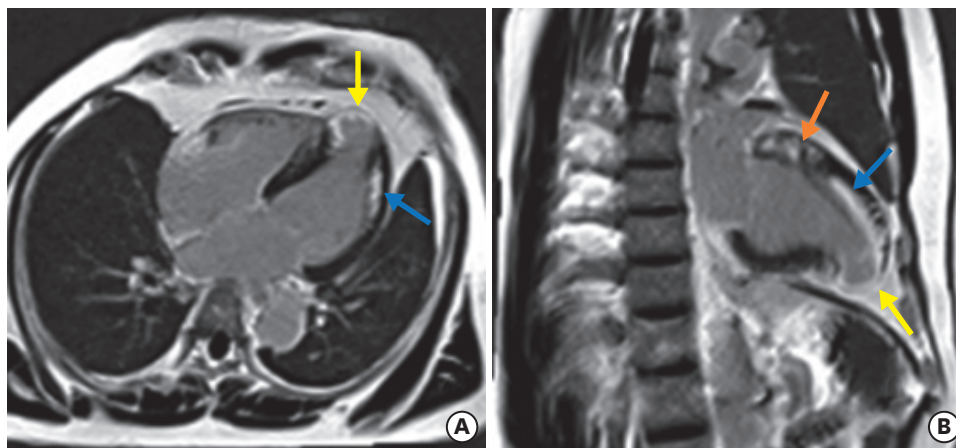


Figure 3. Horizontal (A) and vertical long axis view (B) of cardiac magnetic resonance imaging revealing wall thinning with aneurysmal change and transmural LGE of the LV apex (yellow arrows), subendocardial LGE of the anterior and lateral walls (blue arrows), and intramural patchy LGE of the LV base (orange arrow). LGE = late-gadolinium enhancement, LV = left ventricle.

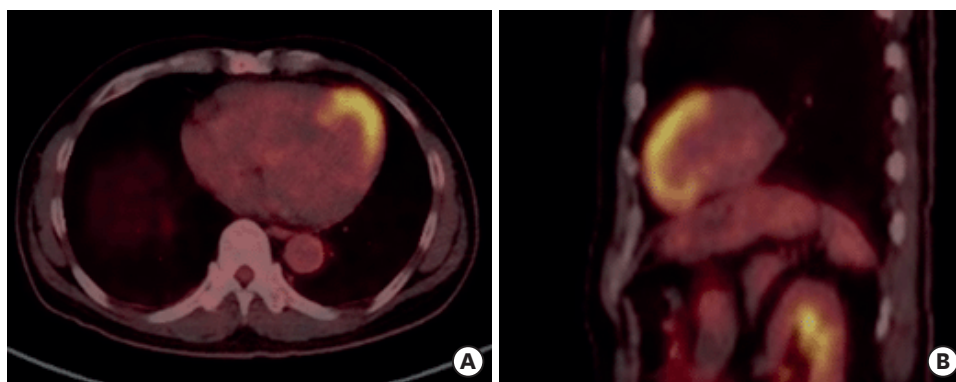


Figure 4. Transverse view (A) and sagittal view (B) of ¹⁸F-fluorodeoxyglucose positron emission tomography scan revealing hot uptake at the apex and the lateral and anterior walls of the left ventricle.

SUPPLEMENTARY MATERIAL

Supplementary Video 1

Apical 2-chamber view of transthoracic echocardiography revealing normal ventricular function but also the akinesia and focal aneurysm of the left ventricle

[Click here to view](#)

REFERENCES

1. Agarwal PP, Kazerooni EA. Dual left anterior descending coronary artery: CT findings. *AJR Am J Roentgenol* 2008;191:1698-701.
[PUBMED](#) | [CROSSREF](#)
2. Mahrholdt H, Wagner A, Judd RM, Sechtem U, Kim RJ. Delayed enhancement cardiovascular magnetic resonance assessment of non-ischaemic cardiomyopathies. *Eur Heart J* 2005;26:1461-74.
[PUBMED](#) | [CROSSREF](#)
3. Oyama-Manabe N, Manabe O, Aikawa T, Tsuneta S. The role of multimodality imaging in cardiac sarcoidosis. *Korean Circ J* 2021;51:561-78.
[PUBMED](#) | [CROSSREF](#)
4. Kosuge H, Noda M, Kakuta T, Kishi Y, Isobe M, Numano F. Left ventricular apical aneurysm in cardiac sarcoidosis. *Jpn Heart J* 2001;42:265-9.
[PUBMED](#) | [CROSSREF](#)
5. Birnie DH, Sauer WH, Bogun F, et al. HRS expert consensus statement on the diagnosis and management of arrhythmias associated with cardiac sarcoidosis. *Heart Rhythm* 2014;11:1305-23.
[PUBMED](#) | [CROSSREF](#)