



Radiographic changes of mandibular cortical bone in bisphosphonate drug holiday

Dae-Hoon Lee, Ja-In Seo, Seung-II Song, Jeong-Keun Lee

Division of Oral and Maxillofacial Surgery, Department of Dentistry, Ajou University School of Medicine, Suwon, Korea

Abstract (J Korean Assoc Oral Maxillofac Surg 2022;48:219-224)

Objectives: There have been few studies to date on the residual effect of bisphosphonate. This study investigated the radiographic changes of mandibular cortical thickness upon bisphosphonate drug holiday.

Materials and Methods: This retrospective study includes 36 patients diagnosed with MRONJ (medication-related osteonecrosis of the jaw) at Ajou University Dental Hospital in 2010-2021. All patients stopped taking bisphosphonate under consultation with the prescribing physicians. Panoramic radiographs were taken at the start of discontinuation (T_0), 12 months after (T_1), and 18 months after (T_2) discontinuation of bisphosphonate, respectively. Mental index and panoramic mandibular index were calculated using Ledgerton's method. Paired *t*-tests were used to analyze differences over time.

Results: The difference in indices (mental index and panoramic mandibular index) between T_0 and T_1 was not statistically significant (paired *t*-test, $P>0.05$). However, the difference in these indices between T_1 and T_2 was statistically significant (paired *t*-test, $P<0.05$).

Conclusion: The cortical thickness of the mandible decreased in the late stage (after 18 months) as observed by panoramic radiograph.

Key words: Bisphosphonate-associated osteonecrosis of the jaw, Panoramic radiography, Bisphosphonate holidays

[paper submitted 2022. 6. 27 / accepted 2022. 7. 26]

I. Introduction

Medication-related osteonecrosis of the jaw (MRONJ) was first reported by Marx in 2003, and reports related to the disease have since gradually increased. Bisphosphonate drugs are widely used as a treatment for osteoporosis through the mechanism of inhibiting osteoclasts; they are also used for malignant tumors (i.e., multiple myeloma), hypercalcemia, and metastatic bone tumor.

MRONJ is a disease that can be diagnosed when bone is exposed in the oral cavity or there is a fistula that can be probed into bone for more than eight weeks despite proper management. In addition, there should be no history of radia-

tion therapy or metastatic tumor in the skeleton.

The pathophysiology of MRONJ is multifactorial, but low bone turnover rate due to bisphosphonate treatment and pre-existing inflammation are sufficient for MRONJ diagnosis. While reduced bone remodeling due to bisphosphonate is expected to be the major cause, parathyroid hormone can help treat MRONJ by reversing reduced bone turnover^{1,2}.

There is no consensus on whether MRONJ should be treated surgically or medically. Currently, conservative and surgical treatment are used interchangeably. The American Association of Oral and Maxillofacial Surgeons issued a revised position paper for MRONJ in 2022, recommending both conservative and surgical approaches for MRONJ patients³.

When it comes to treatment via drug holiday, controversy remains. Some authors recommend consulting with a physician to discontinue MRONJ-related drugs such as bisphosphonate or denosumab, until the lesion is cured to prevent exacerbation during the treatment process⁴. Others reported that drug holiday was not useful for preventing MRONJ. Meanwhile, it is still unknown whether or when bone density decreased after bisphosphonate discontinuation. If bone density decreases, we consider when it decreases might be

Jeong-Keun Lee

Division of Oral and Maxillofacial Surgery, Department of Dentistry, Ajou University School of Medicine, 164 WorldCup-ro, Yeongtong-gu, Suwon 16499, Korea

TEL: +82-31-219-5328

E-mail: arcady@ajou.ac.kr

ORCID: <https://orcid.org/0000-0002-5561-6297>

© This is an open-access article distributed under the terms of the Creative Commons Attribution Non-Commercial License (<http://creativecommons.org/licenses/by-nc/4.0/>), which permits unrestricted non-commercial use, distribution, and reproduction in any medium, provided the original work is properly cited.

Copyright © 2022 The Korean Association of Oral and Maxillofacial Surgeons.

the radiologic evidence of a bisphosphonate drug holiday. This study tries to answer these questions by investigating changes in mandibular cortical thickness.

II. Materials and Methods

1. Study sample

The medical records of 277 patients diagnosed with MRONJ at Ajou University Hospital from January 2010 to May 2021 were analyzed. After we reviewed the records, only patients who discontinued bisphosphonate treatment and whose follow-up period was at least 12 months were selected. Demographics of the patients involved are described in Table

Table 1. Patient demographics

No.	Sex	Age (yr)	Drug type	Indication	Follow-up duration (mo)
1	F	83	Alendronate	Osteoporosis	24
2	F	77	Risedronate	Osteoporosis	14
3	F	65	Alendronate	Osteoporosis	60
4	F	70	Alendronate	Osteoporosis	12
5	F	63	Unknown type	Osteoporosis	15
6	F	78	Unknown type	Osteoporosis	12
7	F	85	Risedronate	Osteoporosis	12
8	F	64	Alendronate	Osteoporosis	71
9	F	60	Zoledronate	Bone tumor	19
10	F	72	Ibandronate	Osteoporosis	12
11	F	73	Alendronate	Osteoporosis	24
12	F	74	Risedronate	Osteoporosis	24
13	F	73	Alendronate	Osteoporosis	12
14	F	79	Unknown type	Osteoporosis	52
15	F	87	Ibandronate	Osteoporosis	12
16	M	65	Alendronate	Osteoporosis	14
17	F	75	Ibandronate	Osteoporosis	28
18	F	78	Alendronate	Osteoporosis	12
19	F	87	Alendronate	Osteoporosis	13
20	F	87	Zoledronate	Osteoporosis	16
21	F	88	Ibandronate	Osteoporosis	12
22	F	70	Risedronate and ibandronate	Osteoporosis	24
23	F	69	Ibandronate	Osteoporosis	28
24	F	69	Unknown type	Osteoporosis	13
25	F	76	Unknown type	Osteoporosis	12
26	F	90	Unknown type	Osteoporosis	15
27	F	77	Unknown type	Osteoporosis	36
28	F	74	Alendronate	Osteoporosis	12
29	F	81	Pamidronate	Bone tumor	12
30	M	77	Alendronate	Osteoporosis	12
31	F	66	Risedronate	Osteoporosis	20
32	F	82	Unknown type	Osteoporosis	22
33	F	87	Alendronate	Osteoporosis	21
34	F	83	Risedronate and denosumab	Osteoporosis	12
35	F	70	Risedronate	Osteoporosis	17
36	M	41	Zoledronate	Bone tumor	28

(F: female, M: male)

Dae-Hoon Lee et al: Radiographic changes of mandibular cortical bone in bisphosphonate drug holiday. J Korean Assoc Oral Maxillofac Surg 2022

1. This study was conducted after approval from the Institutional Review Board of Ajou University Hospital (approval No. AJIRB-MED-MDB-21-538), and the informed consent was waived by the IRB.

2. Panoramic mandibular index and mental index

1) Panoramic mandibular index (PMI)

After marking the position of the mental foramen on panoramic radiographs using the method of Ledgerton et al.⁵, the line (b) is drawn perpendicular to the tangent line (a) of the mandibular inferior border and crossing the center of the mental foramen. A PMI value is obtained by dividing the thickness of the mandibular cortex (C) by the distance from the mandibular border to either the upper or lower end of

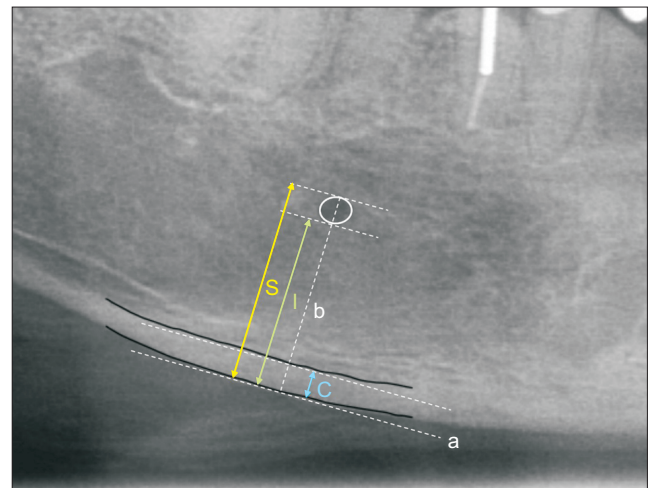


Fig. 1. Defining landmarks by Ledgerton's method. Panoramic mandibular index (PMI) and mental index (MI), S=the distance from the superior border of mental foramen to mandibular border, l=the distance from the inferior border to mandibular border, C=cortical bone thickness, that is MI.

Dae-Hoon Lee et al: Radiographic changes of mandibular cortical bone in bisphosphonate drug holiday. J Korean Assoc Oral Maxillofac Surg 2022

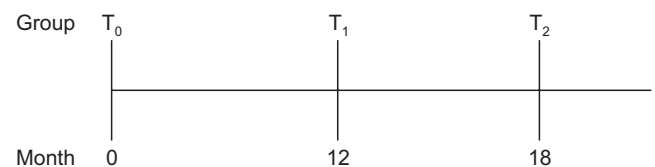


Fig. 2. Groups of patients according to drug holiday length. When comparing T₀ and T₁, the size of group was 24, patients of which have taken dental panoramic radiograph at starting point of drug discontinuation and 12 months from the start. When comparing T₀ and T₂, the size of group was 13, patients of which have taken the radiograph at starting point of drug discontinuation and 18-24 months from the start.

Dae-Hoon Lee et al: Radiographic changes of mandibular cortical bone in bisphosphonate drug holiday. J Korean Assoc Oral Maxillofac Surg 2022

mental foramen (I and S)⁵.(Fig. 1) Thereby, we obtain the following equations:

$$\text{PMI(I)}=C/I$$

$$\text{PMI(S)}=C/S$$

2) Mental index (MI)

MI is defined as the gap between the upper and lower tangent line of the mandibular cortex.(C in Fig. 1)

Panoramic X-rays (CS 8100, 73 kVp, 10 mA, 10.8 seconds; Careream Dental, Atlanta, GA, USA) were taken for each of the patients. Measurement was done using INFINITT PACS software (Infinit HealthCare, Seoul, Korea). All measurements were performed at 100% and 150% magnification. The mandibular cortex line was marked on a 100%-magnified radiograph, and the indices (PMI and MI) for statistical comparison were measured on a 150%-magnified image. They were measured on either the left or right side of the patient. In patients who underwent sequestrectomy, followed by rhBMP-2 (recombinant human bone morphogenetic protein-2) regeneration, indices on the surgically treated area were excluded. As a result, only non-surgically treated areas of the mandible were selected in this study. After first measurement, another measurement was executed after a period time (at least 90 days) to evaluate the intra-observer reliability. Nine patients were randomly selected for re-measurement. Fifty-nine sets of data comparing 1st and 2nd measurement were produced.

Data from a total of 36 patients who met the inclusion cri-

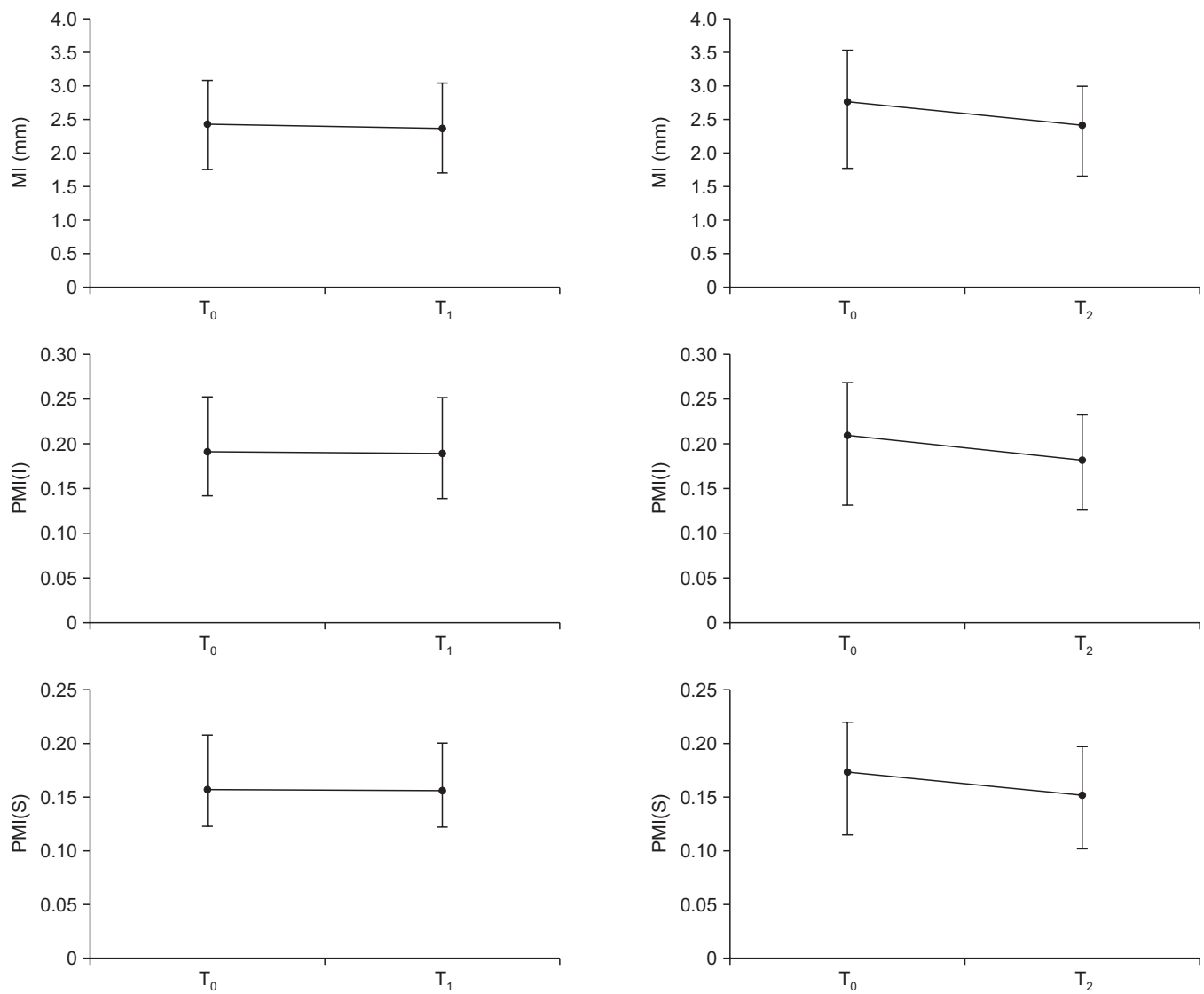


Fig. 3. Comparison of index values. MI=mental index, PMI(I and S)=panoramic mandibular index. When comparing T₀ and T₁, the size of the group was 24. When comparing T₁ and T₂, the size of the group was 13.

Dae-Hoon Lee et al: Radiographic changes of mandibular cortical bone in bisphosphonate drug holiday. J Korean Assoc Oral Maxillofac Surg 2022

teria were used. For these patients, index values at the starting point of discontinuation (T_0), 12 months after discontinuation (T_1), and 18 months after discontinuation (T_2) were compared. Not all 36 patients underwent radiographic examination at the exact same time interval. Therefore, when comparing indices at different time points, the size of the group was smaller than 36. When comparing T_0 and T_1 , the group size was 24, and when comparing T_0 and T_2 , it was 13.(Fig. 2)

3. Statistical analysis

Data were statistically analyzed through IBM SPSS Statistics (ver. 25.0; IBM, Armonk, NY, USA). A Shapiro–Wilk test was used to determine the normality of the data. Intra-class correlation coefficient (ICC) and Pearson correlation coefficient were calculated to evaluate intra-rater reliability. Paired *t*-tests with a significance level of 5% were used to compare the cortical thickness of patients from each group.

III. Results

The medical records from 36 patients were analyzed. The mean age of the patients was 74.86 years, three of whom were male and the others were female.(Table 1) Mean follow-up length was 20.9 months. Index values of T_0 , T_1 , and T_2 were compared with paired *t*-test, because all values showed a normal distribution (Shapiro–Wilk test, $P>0.05$). Results of comparison are summarized in Fig. 3.

Table 2. Mean measurement values and *P*-value of comparison, PMI(I)

Group size	T_0	T_1	T_2	<i>P</i> -value
n=24	0.191	0.190	-	0.683
n=13	0.209	-	0.182	0.007

(T_0 : at the starting point of discontinuation, T_1 : 12 months after discontinuation, T_2 : 18 months after discontinuation)

Dae-Hoon Lee et al: Radiographic changes of mandibular cortical bone in bisphosphonate drug holiday. J Korean Assoc Oral Maxillofac Surg 2022

Table 3. Mean measurement values and *P*-value of comparison, PMI(S)

Group size	T_0	T_1	T_2	<i>P</i> -value
n=24	0.157	0.156	-	0.740
n=13	0.173	-	0.152	0.006

(T_0 : at the starting point of discontinuation, T_1 : 12 months after discontinuation, T_2 : 18 months after discontinuation)

Dae-Hoon Lee et al: Radiographic changes of mandibular cortical bone in bisphosphonate drug holiday. J Korean Assoc Oral Maxillofac Surg 2022

1. PMI(I)

When comparing PMI(I) values at the starting point of drug discontinuation (T_0) and 12 months after (T_1), mean values were 0.191 and 0.190, respectively. This difference was not statistically significant ($P>0.05$).

When comparing the starting point of drug discontinuation (T_0) and 18-24 months after (T_2), the mean values were 0.209 and 0.182, respectively. This difference was statistically significant ($P<0.05$).(Table 2)

2. PMI(S)

When comparing PMI(S) values at the starting point of drug discontinuation (T_0) and 12 months after (T_1), the mean values were 0.157 and 0.156, respectively. This difference was not statistically significant ($P>0.05$).

When comparing the starting point of drug discontinuation (T_0) and 18-24 months after (T_2), the mean values were 0.173 and 0.152, respectively. This difference was statistically significant ($P<0.05$).(Table 3)

3. MI

When comparing MI values at the starting point of drug discontinuation (T_0) and 12 months after (T_1), mean values were 2.54 and 2.47, respectively. This difference was not statistically significant ($P>0.05$).

When comparing the starting point of drug discontinuation (T_0) and 18-24 months (T_2), mean values were 2.77 and

Table 4. Mean measurement values and *P*-value of comparison, MI (unit: mm)

Group size	T_0	T_1	T_2	<i>P</i> -value
n=24	2.54	2.47	-	0.299
n=13	2.77	-	2.42	0.003

(T_0 : at the starting point of discontinuation, T_1 : 12 months after discontinuation, T_2 : 18 months after discontinuation)

Dae-Hoon Lee et al: Radiographic changes of mandibular cortical bone in bisphosphonate drug holiday. J Korean Assoc Oral Maxillofac Surg 2022

Table 5. Intra-rater reliability evaluation

	I	S	C
ICC (3,1)	0.994	0.995	0.993
Pearson correlation	0.990	0.991	0.988

(I: the distance from the inferior border of mental foramen to mandibular border, S: the distance from the superior border of mental foramen to mandibular border, C: cortical bone thickness)

Dae-Hoon Lee et al: Radiographic changes of mandibular cortical bone in bisphosphonate drug holiday. J Korean Assoc Oral Maxillofac Surg 2022

2.42, respectively. This difference was statistically significant ($P < 0.05$). (Table 4)

4. Intra-rater reliability

Intra-rater reliability was evaluated using the ICC and Pearson correlation coefficient. Fifty-nine sets of data pair (1st and 2nd measurement) from randomly selected 9 patients were used. The ICC (3,1) for each variable (I, S, and C) was 0.994, 0.995, and 0.993, respectively. The Pearson correlation coefficient was 0.990, 0.991, and 0.988, respectively. (Table 5)

IV. Discussion

Horner and Devlin⁶ found a correlation between bone mineral density, PMI, and MI. Taguchi et al.⁷ also found a linear correlation between TBMD (total mean bone mineral density) and mandibular inferior cortex height. In Klemetti's study⁸, there was a high correlation between patient OST (osteoporosis self-assessment tool) score, PMI, and cortical height. Further, this correlation is still utilized by several recent studies on bone density. Koh et al.⁹ used fractal analysis on dental panoramic imaging, showing the fractal dimension value decreasing as bone mineral density decreased. Vlasidis et al.¹⁰ reported a connection between T-score and mandibular cortical width. Kavitha et al.¹¹ used a support-vector machine with cortical thickness on panoramic view to diagnose postmenopausal women with low BMD, which showed good efficacy. In summary, PMI and MI are correlated with bone mineral density and are still in use today. In this way, we inferred changes in bone remodeling rate by changes in mandibular cortical thickness (PMI and MI). To our knowledge, this is the first attempt to observe changes during bisphosphonate drug holiday.

In case of mandibles not affected by bisphosphonate or any other bone-modifying drugs, Roberts et al.¹² found a quadratic decrease in mandibular cortical thickness in female individuals after 42.5 years of age and a slow linear decrease in males after 36 years. On the other hand, if the mandible is under bisphosphonate's effect, Torres et al.¹³ found that mandibular cortical thickness on cone-beam computed tomography was higher with MRONJ patients compared to control patients. They further reported the same result using dental panoramic radiographs while comparing patients taking bisphosphonate with control patients¹⁴. It could be assumed that bisphosphonate increases cortical thickness or at least

prevents its decrease, which needs to be confirmed by future longitudinal study.

This study shows that PMI and MI do not decrease until after 12 months of drug holiday (T_1). This may be due to bisphosphonate accumulation in the human body. Studies revealed that bisphosphonates bind to free hydroxyapatite, which results in retention in the human body for several years^{15,16}. However, there was a decrease in indices after 18 months of drug discontinuation (T_2). Contrary to the estimated half-life of the drug, cortical height change was observed before the actual half-life of the drug.

Drug holiday recommendations for MRONJ patients remain controversial. Ottesen et al.¹⁷ concluded that bisphosphonate drug holiday lacked solid evidence on systemic review. Ruggiero et al.³ reported they could not reach a consensus on the use of drug holiday for prevention of MRONJ as the committee was evenly divided on drug holiday efficacy. On the other hand, for established MRONJ patients, it was suggested that drug holiday be considered for those with risk factors such as rheumatoid arthritis, a history of glucocorticoid use, or diabetes mellitus⁴. An animal study by Zandi et al.¹⁸ found that discontinuation of bisphosphonate before and after dentoalveolar surgery contributes to resolution of MRONJ. On the other hand, another animal study found that discontinuation of bisphosphonate did not prevent development of MRONJ in rats. Bisphosphonate's high affinity to bone was expected to be the cause¹⁹. This study also confirmed this effect in that PMI and MI did not show a decrease at 12 months (T_1). However, cortical height and PMI showed decrease in 18-24 months (T_2). This could indicate osteoclastic activity resumes in 18-24 months. A future study comparing bisphosphonate patients and control patients is needed to confirm this point.

This study could not avoid limitations, including small group size, indirectly quantified bone turnover rate, two-dimensional imaging, and human error in defining the border of mandible. Computed tomography imaging and computer-automated process of measurement would be great additions to future studies.

V. Conclusion

Thickness change of mandibular cortical bone was evaluated on panoramic radiographs during discontinuation of bisphosphonate (drug holiday). Although there was little change in the first 12 months (T_1), the cortical thickness of the mandible decreased after 18 months (T_2), which presents

radiologic evidence of the skeletal effects of drug holiday.

ORCID

Dae-Hoon Lee, <https://orcid.org/0000-0001-5028-8848>

Ja-In Seo, <https://orcid.org/0000-0002-8898-589X>

Seung-Il Song, <https://orcid.org/0000-0001-9504-6471>

Jeong-Keun Lee, <https://orcid.org/0000-0002-5561-6297>

Authors' Contributions

D.H.L. participated in data collection and wrote the manuscript. D.H.L., J.I.S., J.K.L., and S.I.S. participated in the study design. D.H.L. and J.I.S. performed the statistical analysis. J.K.L. and S.I.S. helped to draft the manuscript. All authors read and approved the final manuscript.

Ethics Approval and Consent to Participate

This study was conducted after approval from the Institutional Review Board of Ajou University Hospital (approval No. AJIRB-MED-MDB-21-538).

Conflict of Interest

No potential conflict of interest relevant to this article was reported.

References

1. Dayisoylu EH, Şenel FÇ, Üngör C, Tosun E, Çankaya M, Ersöz S, et al. The effects of adjunctive parathyroid hormone injection on bisphosphonate-related osteonecrosis of the jaws: an animal study. *Int J Oral Maxillofac Surg* 2013;42:1475-80. <https://doi.org/10.1016/j.ijom.2013.05.001>
2. Harper RP, Fung E. Resolution of bisphosphonate-associated osteonecrosis of the mandible: possible application for intermittent low-dose parathyroid hormone [rhPTH(1-34)]. *J Oral Maxillofac Surg* 2007;65:573-80. <https://doi.org/10.1016/j.joms.2006.10.076>
3. Ruggiero SL, Dodson TB, Aghaloo T, Carlson ER, Ward BB, Kademani D. American Association of Oral and Maxillofacial Surgeons' position paper on medication-related osteonecrosis of the jaw--2022 update. *J Oral Maxillofac Surg* 2022;80:920-43. <https://doi.org/10.1016/j.joms.2022.02.008>
4. Ruggiero SL, Dodson TB, Fantasia J, Goodday R, Aghaloo T, Mehrotra B, et al.; American Association of Oral and Maxillofacial Surgeons. American Association of Oral and Maxillofacial Surgeons position paper on medication-related osteonecrosis of the jaw--2014 update. *J Oral Maxillofac Surg* 2014;72:1938-56. <https://doi.org/10.1016/j.joms.2014.04.031>
5. Ledgerton D, Horner K, Devlin H, Worthington H. Panoramic mandibular index as a radiomorphometric tool: an assessment of precision. *Dentomaxillofac Radiol* 1997;26:95-100. <https://doi.org/10.1038/sj.dmf.4600215>
6. Horner K, Devlin H. The relationship between mandibular bone mineral density and panoramic radiographic measurements. *J Dent* 1998;26:337-43. [https://doi.org/10.1016/s0300-5712\(97\)00020-1](https://doi.org/10.1016/s0300-5712(97)00020-1)
7. Taguchi A, Sueti Y, Ohtsuka M, Otani K, Tanimoto K, Ohtaki M. Usefulness of panoramic radiography in the diagnosis of postmenopausal osteoporosis in women. Width and morphology of inferior cortex of the mandible. *Dentomaxillofac Radiol* 1996;25:263-7. <https://doi.org/10.1259/dmfr.25.5.9161180>
8. Klemetti E, Kolmakov S, Kröger H. Pantomography in assessment of the osteoporosis risk group. *Scand J Dent Res* 1994;102:68-72. <https://doi.org/10.1111/j.1600-0722.1994.tb01156.x>
9. Koh KJ, Park HN, Kim KA. Prediction of age-related osteoporosis using fractal analysis on panoramic radiographs. *Imaging Sci Dent* 2012;42:231-5. <https://doi.org/10.5624/isd.2012.42.4.231>
10. Vlasidis KZ, Skouteris CA, Velegarakis GA, Fragouli I, Neratzoulakis JM, Damilakis J, et al. Mandibular radiomorphometric measurements as indicators of possible osteoporosis in postmenopausal women. *Maturitas* 2007;58:226-35. <https://doi.org/10.1016/j.maturitas.2007.08.014>
11. Kavitha MS, Asano A, Taguchi A, Kurita T, Sanada M. Diagnosis of osteoporosis from dental panoramic radiographs using the support vector machine method in a computer-aided system. *BMC Med Imaging* 2012;12:1. <https://doi.org/10.1186/1471-2342-12-1>
12. Roberts M, Yuan J, Graham J, Jacobs R, Devlin H. Changes in mandibular cortical width measurements with age in men and women. *Osteoporos Int* 2011;22:1915-25. <https://doi.org/10.1007/s00198-010-1410-3>
13. Torres SR, Chen CS, Leroux BG, Lee PP, Hollender LG, Santos EC, et al. Mandibular cortical bone evaluation on cone beam computed tomography images of patients with bisphosphonate-related osteonecrosis of the jaw. *Oral Surg Oral Med Oral Pathol Oral Radiol* 2012;113:695-703. <https://doi.org/10.1016/j.oool.2011.11.011>
14. Torres SR, Chen CS, Leroux BG, Lee PP, Hollender LG, Lloid M, et al. Mandibular inferior cortical bone thickness on panoramic radiographs in patients using bisphosphonates. *Oral Surg Oral Med Oral Pathol Oral Radiol* 2015;119:584-92. <https://doi.org/10.1016/j.oool.2015.02.005>
15. Ruggiero SL, Fantasia J, Carlson E. Bisphosphonate-related osteonecrosis of the jaw: background and guidelines for diagnosis, staging and management. *Oral Surg Oral Med Oral Pathol Oral Radiol Endod* 2006;102:433-41. <https://doi.org/10.1016/j.tripleo.2006.06.004>
16. Cremers SC, Pillai G, Papapoulos SE. Pharmacokinetics/pharmacodynamics of bisphosphonates: use for optimisation of intermittent therapy for osteoporosis. *Clin Pharmacokinet* 2005;44:551-70. <https://doi.org/10.2165/00003088-200544060-00001>
17. Ottesen C, Schiodt M, Gotfredsen K. Efficacy of a high-dose anti-resorptive drug holiday to reduce the risk of medication-related osteonecrosis of the jaw (MRONJ): a systematic review. *Heliyon* 2020;6:e03795. <https://doi.org/10.1016/j.heliyon.2020.e03795>
18. Zandi M, Dehghan A, Ghadermazi K, Malekzadeh H, Akbarzadeh M. Perioperative discontinuation of intravenous bisphosphonate therapy reduces the incidence and severity of bisphosphonate-related osteonecrosis of the jaw: a randomized, controlled, prospective experimental study in rats. *J Craniomaxillofac Surg* 2015;43:1823-8. <https://doi.org/10.1016/j.jcms.2015.08.008>
19. de Molon RS, Shimamoto H, Bezouglaia O, Pirihi FQ, Dry SM, Kostenuik P, et al. OPG-Fc but not zoledronic acid discontinuation reverses osteonecrosis of the jaws (ONJ) in mice. *J Bone Miner Res* 2015;30:1627-40. <https://doi.org/10.1002/jbmr.2490>

How to cite this article: Lee DH, Seo JI, Song SI, Lee JK. Radiographic changes of mandibular cortical bone in bisphosphonate drug holiday. *J Korean Assoc Oral Maxillofac Surg* 2022;48:219-224. <https://doi.org/10.5125/jkaoms.2022.48.4.219>