



Klebsiella pneumoniae and *Enterobacter cloacae* Induced Septic Arthritis in a Healthy Adolescent: A Rare Case Report

Reza Zandi, MD, Shahin Talebi, MD, Shirin Sheibani, Medical Student (MD Candidate)*, Akbar Ehsani, MD
Department of Orthopedic Surgery, Taleghani Hospital Research Development Committee, School of Medicine,
Shahid Beheshti University of Medical Sciences, Tehran, Iran
Student Research Committee, School of Medicine, Mazandaran University of Medical Science, Sari, Iran*

Septic arthritis (SA) is a joint inflammation that develops secondary to infectious causes. SA in children is associated with a high rate of morbidity and mortality; therefore, it is regarded as an orthopedic emergency. Because SA of the hip joint usually mimics other musculoskeletal diseases, diagnosis remains challenging. Although this lesion usually shows a good outcome, treatment at an inappropriate time, neglect, or inadequate treatment could lead to poor outcomes. We report on the case of a healthy adolescent who complained of episodes of fever and chills, weight loss, pain in his left hip, and limping. After performing necessary workups, two differential diagnoses of tumor and SA were made. The results of Gram stain and culture of the synovial fluid after surgical excision showed *Klebsiella pneumoniae* and *Enterobacter cloacae* complex. To the best of our knowledge, this is the first report of SA due to co-infection with *K. pneumoniae* and *E. cloacae* in a healthy patient.

Key Words: Adolescents, *Enterobacter cloacae*, *Klebsiella pneumoniae*, Septic arthritis, Suppurative arthritis

Septic arthritis (SA), also known as pyogenic arthritis or suppurative arthritis¹⁾, is a joint inflammation that develops secondary to infectious causes²⁾. This condition is most frequently caused by bacteria; other causes of SA include fun-

gal infections, mycobacterial, viral, and other pathogens³⁾. The monoarticular type of this disease is more common (90%)⁴⁾ and involves one large joint such as the knee or hip³⁾. SA of the hip is more common in children^{3,5)}.

Different etiologic agents can be considered based on the age group and underlying medical condition²⁻⁴⁾. However, SA is often caused by gram-positive bacteria⁶⁾, particularly *Staphylococcus aureus*⁴⁾. *Klebsiella pneumoniae* and *Enterobacter cloacae*, two gram-negative bacteria, are members of the *Enterobacteriaceae* family. SA caused by *K. pneumoniae* is an infrequent condition⁶⁾ and has only been reported in certain conditions such as trauma, neonates, elderly, intravenous drug abuser, and immunocompromised patients⁷⁾. *E. cloacae*-associated SA is rare and usually occurred after invasive surgical procedures and traumatic patients⁸⁾. Common causes of SA include the following: *Kingella kingae* in patients with a previous history of upper respiratory tract infection⁹⁾, *Streptococcus pneumoniae* and gram-negative enteric

Submitted: March 21, 2022 1st revision: May 16, 2022

Final acceptance: May 26, 2022

Address reprint request to

Shahin Talebi, MD

(<https://orcid.org/0000-0002-2290-4575>)

Department of Orthopedic Surgery, Taleghani Hospital Research Development Committee, School of Medicine, Shahid Beheshti University of Medical Sciences, Koodakyar St. Danshjoor Blvd, Velenjak, Shahid Chamran Highway, Tehran 1985711151, Iran

TEL: +98-9124070518 FAX: +98-2122126238

E-mail: sh.talebi1365@gmail.com

This is an Open Access article distributed under the terms of the Creative Commons Attribution Non-Commercial License (<http://creativecommons.org/licenses/by-nc/4.0>) which permits unrestricted non-commercial use, distribution, and reproduction in any medium, provided the original work is properly cited.

organisms in neonates¹⁰, Haemophilus influenzae type B (Hib) in unvaccinated children¹¹, Neisseria gonorrhoeae in adolescents with a history of sexual activity or sexual abuse¹², and Salmonella species in patients with sickle cell disease¹³.

SA in children is associated with a high rate of morbidity and mortality, thus urgent diagnosis and treatment are required¹⁴. The potential for joint destruction, avascular necrosis, bacteremia, and finally sepsis is high¹³. SA of the hip joint usually mimics other musculoskeletal diseases such as osteoarthritis exacerbation, psoas tendinopathy, piriformis syndrome, etc.^{6,7} or tumors like fibrous dysplasia, solitary bone cyst, osteoid osteoma, chondroblastoma, giant cell tumor, osteochondroma, aneurysmal bone cyst, and Langerhans cell histiocytosis¹⁵; therefore, diagnosis is a challenge for general orthopedic surgeons or even hip surgeons.

The aim of this study was to report on a healthy male adolescent with SA of the hip caused by *K. pneumoniae* and *E. cloacae* complex.

CASE REPORT

A 17-year-old male presented to our center complaining of episodes of fever and chills lasting one month, approximately 6-kg weight loss, pain in his left hip, and limping due to an antalgic gait. The pain was non-radiating, and progressive in severity, which was associated with refusal to move the left hip and inability to bear weight.

The symptoms started with sudden pain; two days later, he presented to a general practice clinic where he received oral acetaminophen 325 mg every 6 hours, without further assessment. After 3-4 days, the patient developed other symptoms, and, unfortunately, he did not visit a specialist during this period and arbitrarily used azithromycin 250 mg every 12 hours. He denied history of trauma, surgery, sexual activity, drug abuse, and underlying disease. His family history was unremarkable.

Upon arrival, he had a high fever (39° C axillary) and he appeared to be ill. Swelling, warmth, brief erythema, and severe tenderness in the lateral of the left hip were observed on physical examination. In addition, he was not able to perform an active straight leg raise and range of motion was painful. The examination of his remaining musculoskeletal system and other organs showed normal findings.

The results of the laboratory test showed a normal white blood cell count ($10.8 \times 10^3/\mu\text{L}$) with neutrophilic predominance (78.2%-8,445.6/ μL). An increased erythrocyte sedimentation rate (ESR) (81 mm/hr) and C-reactive protein (CRP) (64 mg/L) were also noted. The hemoglobin level

was 11.3 g/dL and blood culture was negative.

A pelvic X-ray, computed tomography (CT) scan, and magnetic resonance imaging (MRI) were requested. A concentric hyper-dense mass measuring approximately 2×1 cm was observed in the central part of the femoral neck on the pelvic X-ray. The cartilage of the femoral head and acetabulum was normal, with no evidence of degenerative changes. A tubular hypo-dense area with hyper-dense foci was observed at the head of the left femur on the CT scan. Pelvic coronal T1 sequence MRI detected an abnormal bone marrow low signal intensity at the left femoral neck and proximal part of the body. In addition, on pelvic axial T2-Fat Sat sequence MRI, a heterogeneous signal was observed around the proximal left femur and left femoral neck and in the internal vicinity of the insertion site of the Iliopsoas muscle and deep in the rectus femoris and sartorius muscles, extending to the subcutaneous soft tissue and the left adductor longus muscle as well as to the femoral head and neck (Fig. 1). The results of a bone scan ordered for further assessment suggested the presence of a tumoral lesion in the proximal left femur accompanied by inflammation of perilesional soft tissue. The results of a core needle biopsy, which was requested due to suspicion of a tumor, showed fragments of synovium and dense fibro-connective tissue and skeletal muscle fibers with focal mild to moderate infiltration of mixed inflammatory cells. Based on all assessments, two differential diagnoses of tumor and SA were made.

Because the result of the biopsy was equivocal surgical excision of the lesion was planned. After controlling the fever, the patient underwent surgery under general anesthesia. Cefazolin 1,000 mg intravenous was administered 30 minutes prior to surgery for prophylaxis of surgical site infection. After performing a sterile preparation and draping, the approach to the hip was performed using a modified Watson-Jones approach. An arthrotomy was performed using a T-shaped capsulotomy, and the hip joint was full of pus; approximately 5 mL of secretions was sent for Gram stain and culture. Open irrigation and drainage of the joint was performed using 3-L sterile normal saline. A dough-shape yellow mass resembling abscess formation was observed in the femoral neck, which communicated with the joint through the cortical defect.

Through the cortical damage, on the anterior surface of the femoral neck with guidance from the fluoroscope, the lesion was completely enucleated using a curette and the walls of the lesion were burred down until visual normal cancellous bone was reached (Fig. 2). The structural con-

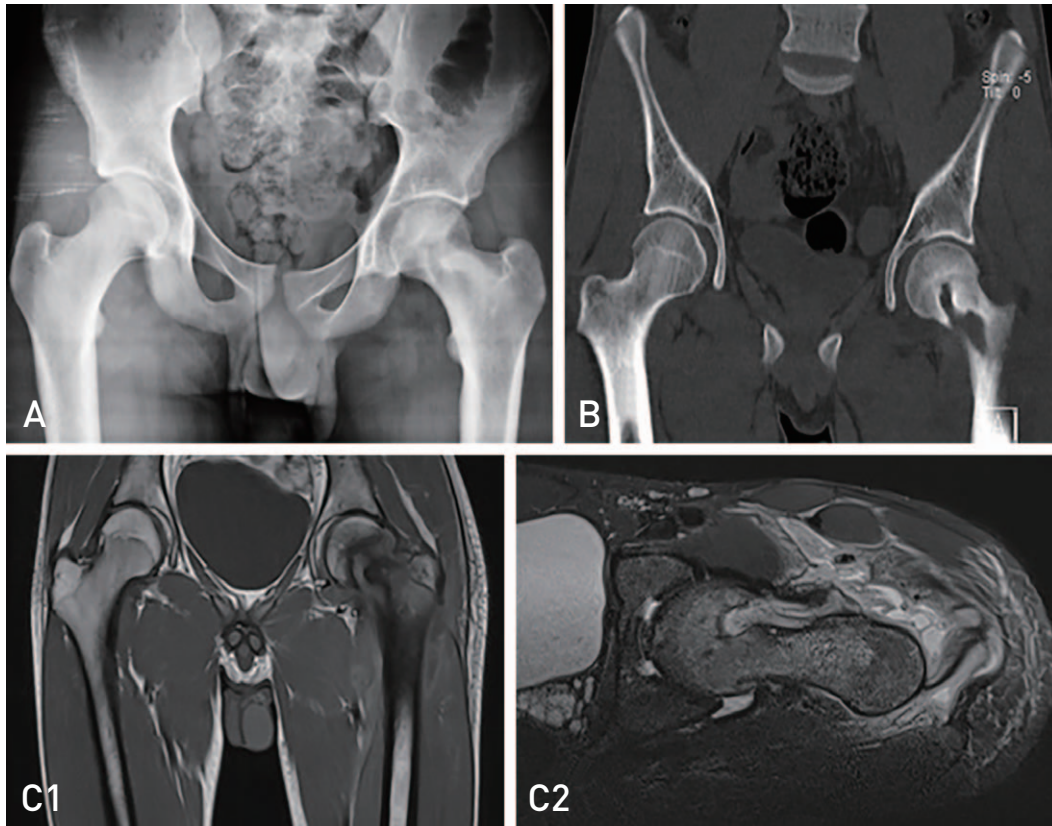


Fig. 1. (A) Pelvic X-ray revealed a concentric hyper-dense approximately 2×1 cm mass in the central part of the femoral neck. (B) The computed tomography scan showed a tubular hypo-dense area with hyper-dense foci at the head of the left femur. (C) C1: coronal T1 sequence revealed a low signal intensity at the site of head and neck of the femur junction in line with femoral neck mass. C2: axial T2- fat suppression showed an abnormal bone marrow high signal intensity at left neck and proximal part of the body.




Fig. 2. The lesion was completely enucleated using curette and burred down the walls of the lesion.

tinuity of the femoral neck was maintained so that no additional fixation was required. Complete removal of the lesion was confirmed fluoroscopically and the tissue obtained was sent for pathology and evaluation of the culture. After additional irrigation and debridement, loose suturing of the capsulotomy site was performed over a drain and the remaining layers were sutured. Dramatic improvement of hip pain was observed the day after surgery and the patient was allowed partial weight-bearing on his left hip with two crutches for six weeks; he was then allowed to increase weight-bearing (approximately 70-80% of body weight) with a crutch on the right side; full weight-bearing was finally allowed after three months.

The results of cytological analysis of the synovial fluid showed a total protein concentration of 5.1 g/dL, 26,000 cells/mL nucleated cells with a neutrophilic predominance (81%). The results of Gram stain and culture of the synovial fluid showed *K. pneumoniae* and *E. cloacae* complex. Consultation with the Infectious Diseases Service was requested, and according to their recommendation, an antibiotic regimen of ceftazidime 2 g intravenous every 8 hours, levofloxacin 500 mg intravenous every 24 hours, and colistin 4.5 million units intravenous every 12 hours was initiated. After 26 days, his condition showed significant improvement, with a decrease of ESR and CRP to 27 mm/hr and 8 mg/L, respectively. The patient was discharged with oral antibiotics (levofloxacin 750 mg daily and coamoxiclav 625 mg every 8 hours) for three weeks. After a follow-up period of six months, his hip was free of pain, and he mentioned no specific complaint. No evidence

of residual lesion or pathological fractures was observed on the radiograph (Fig. 3).

DISCUSSION

SA is defined as a joint inflammation following invasion of a pathogen⁴. The estimated incidence of SA in the pediatric population is 4 to 37 cases per 100,000 people². This rate can vary according to the region and age¹⁶. The rate in developing countries is approximately 5 to 20 cases per 100,000 people¹⁷ while it is 1 in 100,000 cases in developed countries¹⁸. This condition is more frequent in patients younger than two years².

In general, *S. aureus* is the pathogen most commonly responsible for this complication, while the cause of this lesion can be classified according to age and underlying diseases, such as: *K. kingae* in children under 2-3 years⁴, Group B *Streptococcus*, *S. aureus*, *Neisseria gonorrhoea*, and gram-negative bacilli in infants, *N. gonorrhoeae* in sexually active adolescents, *Salmonella* in patients with sickle cell disease, fungal infections in patients who received long-term antibiotic therapy, and *Pseudomonas aeruginosa* in patients with puncture wounds and injecting drug abusers³. *K. pneumoniae* is a rare cause of SA at any age⁶. SA caused by *K. pneumoniae* usually occurred after an episode of liver abscesses, pneumonia, and urinary tract infections¹⁹. On the other hand, *E. cloacae*, known as an opportunistic pathogen, is rarely considered as an infectious agent in orthopedics⁸. Infection with this pathogen usually occurred in patients with underlying disease, those who were immunosuppressed,

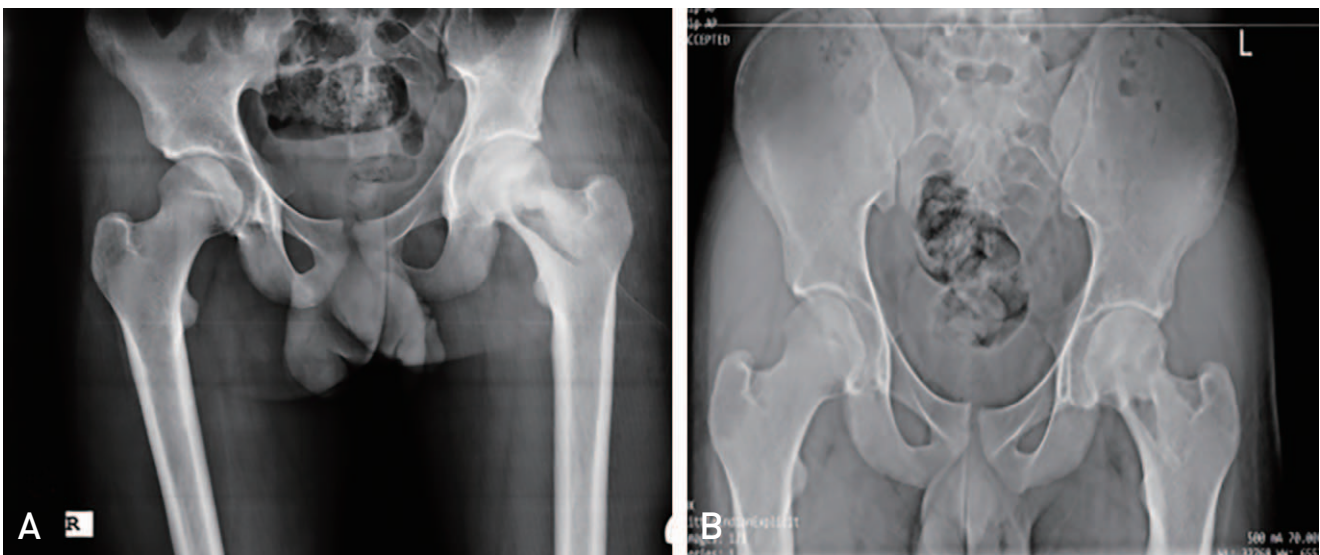


Fig. 3. (A) Pelvic X-ray postoperatively. (B) Pelvic X-ray after 6 months of follow-up revealed no sign of residual lesion or pathological fractures.

and those who were hospitalized for a long period of time and those hospitalized in burn wards²⁰. According to this report, a healthy 17-year-old male developed SA of the hip caused by *K. pneumoniae* and *E. cloacae* in the absence of any underlying disease or other risk factors. To the best of our knowledge, this is the first reported case of SA in an adolescent patient without any previous lesion or underlying disease that occurred due to a concomitant infection with *K. pneumoniae* and *E. cloacae* complex.

SA usually presents with a sudden onset of acute pain, limited movement, and swelling. A non-specific fever may also be observed in 40-60% of patients³. Hip pain and limping are common symptoms of SA of the hip in children but they are not specific. Patients may present with a wide range of signs and symptoms²¹. Findings from some studies have suggested that Kocher criteria could be a reliable option for use in distinguishing between SA and transient synovitis⁵. However, transient synovitis is not the only differential diagnosis. This lesion can mimic protean manifestations of other musculoskeletal conditions such as trauma, hemarthrosis, reactive effusion, juvenile rheumatoid arthritis, arthritis of acute rheumatic fever, osteomyelitis, pyomyositis, septic bursitis, tumor, leukemia, slipped capital femoral epiphysis, Legg Calve-Perthes disease, Lyme arthritis, Henoch-Schonlein purpura, sickle cell anemia, and transient or toxic synovitis¹³. As in the current case, our suspicion was mainly towards the tumor of the femoral neck.

History and physical examination, laboratory tests, radiographs, ultrasound, and arthrocentesis can be helpful in the diagnosis of SA⁵. Nevertheless, diagnosis of SA remains challenging⁷. Treatments for SA include surgical drainage, intravenous antibiotics, and continuing with oral antibiotics¹³. Administration of empirical antibiotics with good penetrance into the joint and synovial fluid should begin immediately after sending the sample of blood and synovial fluid. Recommendations include penicillinase-resistant penicillin (second generation penicillins) for gram-positive cocci, vancomycin or clindamycin in areas with a high rate of methicillin-resistant *S. aureus*, third generation of cephalosporin for gram-negative germs¹³, and addition of ampicillin or amoxicillin to the antibiotic regimen in countries where Hib is common²². The recommended treatment includes urgent open arthrotomy and decompression of the joint, with irrigation and debridement. Surgical intervention as soon as possible is very important, particularly in cases where the femoral head is at risk for avascular necrosis following SA¹³. Indications for surgical drainage include large collections, thick pus, joint loculations, and spread-

ing of the pus into the surrounding soft tissues⁹. The success of single-port arthroscopy in the treatment of pelvic, shoulder, knee, and ankle SA in children three weeks to six years of age has been reported in recent studies^{23,24}. However, the use of arthroscopy in uncomplicated cases of SA of the hip is increasing²⁵.

Although this lesion usually shows a good outcome⁵, treatment at an inappropriate time, neglect, or inadequate treatment could lead to poor outcomes such as osteonecrosis, chondrolysis, limb-length discrepancy, subluxation, dislocation, growth arrest, femoral osteomyelitis, and progressive ankyloses²⁶.

In conclusion, it is certain that the consequences of SA of the hip in children are severe, and the residual damage is much greater when this joint is involved. Of particular importance, in management of a hip mass in pediatric patients, in addition to common tumors that occur at this age, consideration should be given to abscesses and SA even in healthy patients without underlying disease or a history of trauma. In this group of patients, despite the rarity of infection with pathogens such as *K. pneumoniae* and *E. cloacae*, there is never a zero probability of its occurrence. In management of these patients, to prevent and reduce the risk of recurrence, use of the devices should be avoided, if possible. As in this patient, preservation of the structure of the neck and femoral head was attempted in the effort to prevent fixation or premature prosthesis and its complications.

ACKNOWLEDGEMENTS

Written informed consent was obtained from the patient's legal guardian for publication of their anonymized information in this article.

CONFLICT OF INTEREST

The authors declare that there is no potential conflict of interest relevant to this article.

REFERENCES

1. Nade S. *Septic arthritis. Best Pract Res Clin Rheumatol.* 2003;17:183-200. [https://doi.org/10.1016/s1521-6942\(02\)00106-7](https://doi.org/10.1016/s1521-6942(02)00106-7)
2. Cohen E, Katz T, Rahamim E, Bulkowstein S, Weisel Y, Leibovitz R, et al. *Septic arthritis in children: updated epidemiologic, microbiologic, clinical and therapeutic correlations. Pediatr Neonatol.* 2020;61:325-30. <https://doi.org/10.1016/j.pedneo.2020.02.006>

3. Momodu II, Savaliya V. *Septic arthritis. Treasure Island (FL): StatPearls Publishing LLC.; 2022.*
4. Agarwal A, Aggarwal AN. *Bone and joint infections in children: septic arthritis. Indian J Pediatr.* 2016;83:825-33. <https://doi.org/10.1007/s12098-015-1816-1>
5. Swarup I, LaValva S, Shah R, Sankar WN. *Septic arthritis of the hip in children: a critical analysis review. JBJS Rev.* 2020;8:e0103. <https://doi.org/10.2106/JBJS.RVW.19.00103>
6. Moon JB, Lee JH, Ryu BJ. *Septic arthritis of the hip joint caused by Klebsiella pneumoniae: a case report. J Yeungnam Med Sci. Published online January 13, 2022; https://doi.org/10.12701/yujm.2021.01613*
7. Chee YC, Lim CH. *Klebsiella pneumoniae sacroiliac septic arthritis: first case report. IDCases.* 2018;14:e00459. <https://doi.org/10.1016/j.idcr.2018.e00459>
8. Huang J, Xu Q, Liu F, Xiong H, Yang J. *Enterobacter cloacae infection of the shoulder in a 52-year-old woman without apparent predisposing risk factor: a case report and literature review. BMC Infect Dis.* 2021;21:13. <https://doi.org/10.1186/s12879-020-05699-9>
9. de Groot R, Glover D, Clausen C, Smith AL, Wilson CB. *Bone and joint infections caused by Kingella kingae: six cases and review of the literature. Rev Infect Dis.* 1988;10:998-1004. <https://doi.org/10.1093/clinids/10.5.998>
10. Oblatz BE. *Acute suppurative arthritis of the hip in the neonatal period. J Bone Joint Surg Am.* 1960;42-A:23-30.
11. Luhmann JD, Luhmann SJ. *Etiology of septic arthritis in children: an update for the 1990s. Pediatr Emerg Care.* 1999;15:40-2. <https://doi.org/10.1097/00006565-199902000-00012>
12. Kohen DP. *Neonatal gonococcal arthritis: three cases and review of the literature. Pediatrics.* 1974;53:436-40. <https://doi.org/10.1542/peds.53.3.436>
13. Montgomery NI, Epps HR. *Pediatric septic arthritis. Orthop Clin North Am.* 2017;48:209-16. <https://doi.org/10.1016/j.ocl.2016.12.008>
14. Wall C, Donnan L. *Septic arthritis in children. Aust Fam Physician.* 2015;44:213-5.
15. Bloem JL, Reidsma II. *Bone and soft tissue tumors of hip and pelvis. Eur J Radiol.* 2012;81:3793-801. <https://doi.org/10.1016/j.ejrad.2011.03.101>
16. García-Arias M, Balsa A, Mola EM. *Septic arthritis. Best Pract Res Clin Rheumatol.* 2011;25:407-21. <https://doi.org/10.1016/j.berh.2011.02.001>
17. Lavy CB, Peek AC, Manjolo G. *The incidence of septic arthritis in Malawian children. Int Orthop.* 2005;29:195-6. <https://doi.org/10.1007/s00264-005-0643-9>
18. Gafur OA, Copley LA, Hollmig ST, Browne RH, Thornton LA, Crawford SE. *The impact of the current epidemiology of pediatric musculoskeletal infection on evaluation and treatment guidelines. J Pediatr Orthop.* 2008;28:777-85. <https://doi.org/10.1097/BPO.0b013e318186eb4b>
19. Lee HC, Chuang YC, Yu WL, et al. *Clinical implications of hypermucoviscosity phenotype in Klebsiella pneumoniae isolates: association with invasive syndrome in patients with community-acquired bacteraemia. J Intern Med.* 2006;259:606-14. <https://doi.org/10.1111/j.1365-2796.2006.01641.x>
20. Sanders WE Jr, Sanders CC. *Enterobacter spp.: pathogens poised to flourish at the turn of the century. Clin Microbiol Rev.* 1997;10:220-41. <https://doi.org/10.1128/CMR.10.2.220>
21. Mooney JF 3rd, Murphy RF. *Septic arthritis of the pediatric hip: update on diagnosis and treatment. Curr Opin Pediatr.* 2019;31:79-85. <https://doi.org/10.1097/MOP.0000000000000703>
22. Peltola H, Kallio MJ, Unkila-Kallio L. *Reduced incidence of septic arthritis in children by Haemophilus influenzae type-b vaccination. Implications for treatment. J Bone Joint Surg Br.* 1998;80:471-3. <https://doi.org/10.1302/0301-620x.80b3.8296>
23. Sanpera I, Raluy-Collado D, Sanpera-Iglesias J. *Arthroscopy for hip septic arthritis in children. Orthop Traumatol Surg Res.* 2016;102:87-9. <https://doi.org/10.1016/j.otsr.2015.10.008>
24. Thompson RM, Gourineni P. *Arthroscopic treatment of septic arthritis in very young children. J Pediatr Orthop.* 2017;37:e53-7. <https://doi.org/10.1097/BPO.0000000000000659>
25. El-Sayed AM. *Treatment of early septic arthritis of the hip in children: comparison of results of open arthrotomy versus arthroscopic drainage. J Child Orthop.* 2008;2:229-37. <https://doi.org/10.1007/s11832-008-0094-0>
26. Samora JB, Klingele K. *Septic arthritis of the neonatal hip: acute management and late reconstruction. J Am Acad Orthop Surg.* 2013;21:632-41. <https://doi.org/10.5435/JAAOS-21-10-632>