



Periprosthetic Fracture around a Cemented Stem in Total Hip Arthroplasty

Jun-Young Heu, MD, Ju-Yeong Kim, MD*, Se-Won Lee, MD, PhD

Department of Orthopedic Surgery, Yeouido St. Mary's Hospital, College of Medicine, The Catholic University of Korea, Seoul, Korea

*Department of Orthopedic Surgery, Gyeongsang National University Changwon Hospital, College of Medicine, Gyeongsang National University, Changwon, Korea**

The increase in the number of primary total hip arthroplasties that will be performed over the next several decades will lead to an increase in the incidence of periprosthetic fractures around the femoral stem. A search of targeted articles was conducted using on-line databases of PubMed (National Library of Medicine) and articles were obtained from January 2008 to November 2021. Reliable prediction of treatment can be achieved using the Vancouver classification; internal fixation is indicated in fractures involving a stable implant and revision arthroplasty is indicated in those with unstable prostheses. To the best of our knowledge, relatively fewer studies regarding periprosthetic proximal femur fractures of cemented stems have been reported. The focus of this review is on the risk factors and strategies for treatment of these fractures for periprosthetic femoral fractures around a cemented hip arthroplasty.

Key Words: Arthroplasty, Hip, Cementation, Periprosthetic fractures, Classification

INTRODUCTION

Cases involving performance of hip joint arthroplasty are increasing as a result of the aging society; therefore, periprosthetic fractures (PPFs) of hip arthroplasties are emerging as an important issue. Abdel et al.¹⁾ reported a frequency of near-

ly 3.5% at 20 years after primary arthroplasty. The use of cementless stems has recently become a major practice. However, intraoperative fractures occur 14 times more often in uncemented stems, compared with cemented stems. In addition, postoperative fractures occur most commonly in cementless stems, independent of age or gender¹⁾. Based on these findings, the rate of PPF of hip arthroplasties will increase consequently.

Sarcopenia is a result of aging; therefore, elderly arthroplasty patients are vulnerable to fall incidents, and osteopenic or osteoporotic bones of the elderly are hardly able to withstand the impact. A significant increase in the revision rate, almost twofold, is predicted, and the emergence of PPF as an increasing cause has been reported²⁾. Therefore, strategizing the treatment plan is important. The etiology of postoperative periprosthetic femur fractures appears to be multifactorial and the course may also be influenced by the type of stem implant used for arthroplasty.

Relatively fewer studies regarding periprosthetic proximal femur fractures of cemented stems have been reported

Submitted: December 21, 2021 **1st revision:** April 9, 2022

2nd revision: May 2, 2022 **Final acceptance:** May 7, 2022

Address reprint request to

Se-Won Lee, MD, PhD

(<https://orcid.org/0000-0002-8467-1957>)

Department of Orthopedic Surgery, Yeouido St. Mary's Hospital, College of Medicine, The Catholic University of Korea, 10 63-ro, Yeongdeungpo-gu, Seoul 07345, Korea

TEL: +82-2-3779-1068 **FAX:** +82-2-783-0252

E-mail: ssewon@naver.com

This is an Open Access article distributed under the terms of the Creative Commons Attribution Non-Commercial License (<http://creativecommons.org/licenses/by-nc/4.0>) which permits unrestricted non-commercial use, distribution, and reproduction in any medium, provided the original work is properly cited.

ed. This study was conducted in order to review current up-to-date articles on fracture patterns of PPFs focusing on cemented proximal femoral stems, and recent classification issues, various outcomes and mainstream of treatment plans.

METHODOLOGY

A search of targeted articles was conducted using on-line databases of PubMed (National Library of Medicine) and articles were obtained from January 2008 to November 2021. The search was performed on 6, December, 2021 and the search terms used were as follows: ‘periprosthetic fracture’ [title]+‘hip’ [title], and ‘periprosthetic fracture’ [title]+‘cemented’ [title], and ‘periprosthetic fractures’ [title]+‘hip’ [title]+‘cemented’ [title], and ‘periprosthetic fractures’ [title]+‘femoral’ [title]+‘cemented’ [title]. Additional articles related to cemented femoral stem were searched and cited.

CLASSIFICATION

The Vancouver classification is currently the most widely used method of classification for periprosthetic femoral fracture of hip joint arthroplasty³⁾ (Table 1). In classification of a certain fracture, there are two pivotal requirements for surgeons when communicating and strategizing treatment plans; the classification system should require simple communication, and should be both valid and reliable. The Vancouver classification has been reported to satisfy these conditions in a number of studies^{4,5)}. Based on the location of the fracture, the Vancouver classification is classified as A, B, and C. For classification A, the fracture is classified as AG when there is involvement of the greater trochanteric region, and the fracture is classified as AL when there is involvement of the lesser trochanteric region. The fracture around the femoral stem implant is classified as B. For classification B, there is a subdivision sys-

tem; B1, B2, and B3. B1 is a diaphyseal fracture with a stable femoral stem implant. Adequate bone stock with an unstable femoral stem implant is classified as B2, and an unstable stem with inadequate bone stock is classified as B3. Classification C is a fracture pattern that occurs distal to the stem tip.

FRACTURE PATTERN AROUND A CEMENTED FEMORAL STEM

Karam et al.⁶⁾ conducted an analysis of fracture patterns of PPF in both cemented and cementless stems based on the Vancouver classification. The authors reported that there were no significant differences in Vancouver classification (30 type A fractures [12 cemented vs 18 uncemented, $P>0.05$], 125 type B fractures [63 cemented vs 62 uncemented, $P>0.05$], and 17 type C fractures [nine cemented vs eight uncemented, $P>0.05$]) between cemented and cementless stems. In addition, there were no significant differences with regard to the subdivisions for Vancouver B (B1, B2, and B3). Vancouver B2 classification accounted for the largest number of patients, and was further divided into four distinct fracture patterns: (A) comminuted burst, (B) clamshell, (C) reverse clamshell, and (D) spiral (Fig. 1). A comminuted ‘burst’ fracture type in tapered cemented stems with splitting along the cement mantle was described by Phillips et al.⁷⁾. A ‘clamshell’ fracture pattern, which is especially associated with uncemented stems, was reported by Capello et al.⁸⁾. This fracture originates at the medial base of the greater trochanter and extends to the medial cortex distal to the lesser trochanter with preservation of the lateral cortex. A ‘spiral’ fracture pattern is often associated with a separate wedge fragment with significant comminution⁹⁾. A ‘reverse clamshell’ fracture, which is the mirror image of the ‘clamshell’ type, originates in the medial calcar and exits through the lateral cortex with an intact medial cortex. This fracture pattern is similar to that of a reverse oblique proximal femoral fracture, with similar

Table 1. Vancouver Classification¹⁾

Vancouver classification	Subtype
A	Fractures of the trochanteric region, stem stable AG: Fracture of the greater trochanter AL: Fracture of the lesser trochanter
B	Fractures around or just distal to the stem B1: Stem stable B2: Stem loose, good bone stock B3: Stem loose, poor bone stock
C	Fractures well distal to the stem, stem stable

supero-lateral displacement of the proximal fragment due to abductor force. According to Karam et al.⁹, ‘comminuted burst’ and ‘spiral’ types of fractures showed a relatively greater association with cemented femoral stems, whereas the ‘clamshell’ pattern showed a greater association with cementless stems.

A study on the risk factors of fracture characteristics around the femoral stem implant after primary total hip arthroplasties (THAs) was reported by Jain et al.¹⁰. The authors performed an analysis of X-rays of patients with PPFs and classified them according to both Unified Classification System (UCS) grade and AO classification. The most common type for UCS grade was type B1 and the most common type for AO classification was spiral type. Metaphyseal split fracture occurred exclusively for polished taper-slip stem type, with an incidence of 10.1%. For male patients, the incidence of type B fracture was approximately five times greater than that for type C fractures (odds ratio [OR], 0.22). Compared to the polished taper-slip stem type, the possibility of transverse fracture (OR, 9.51) and wedge fracture (OR, 3.72) is greater with the composite beam stem type. In addition, Wu et al.¹¹ reported that the fracture around the distal aspect of the stem tip occurred more commonly years after implantation in patients for whom cemented stem implants were used in the primary THA.

OUTCOMES REGARDING CEMENTATION FOR PPF OF PRIMARY HIP ARTHROPLASTY

A high level of surgical skill is required in treatment of PPFs of the femur after primary hip arthroplasty and management is often difficult. The numerical increment of primary THAs also results in the increment of revision operations in elderly patients due to trauma. Sponer et al.¹² reported on the outcomes of revision arthroplasties in a comparison of cemented stems and cementless stems. According to the authors, use of a long stem cemented stem implant would provide a greater possibility of pain-free weight-bearing without compromising the process for healing fractures of osteoporotic bones associated with old age¹².

OUTCOMES REGARDING PPF OF CEMENTED STEMS OF PRIMARY HIP ARTHROPLASTY

According to the Nordic Arthroplasty Register Association database which includes 437,629 THAs, compared with cementless stems, cemented stems are preferable because they are associated with a much lower possibility of PPF. The authors reported a result of 0.47% for cementless stems and 0.07% for cemented stems at two years¹³.

In addition, an experimental cadaveric *in-vitro* study comparing the tolerated force between cemented and cementless stems was reported by Thomsen et al.¹⁴. Ten matched

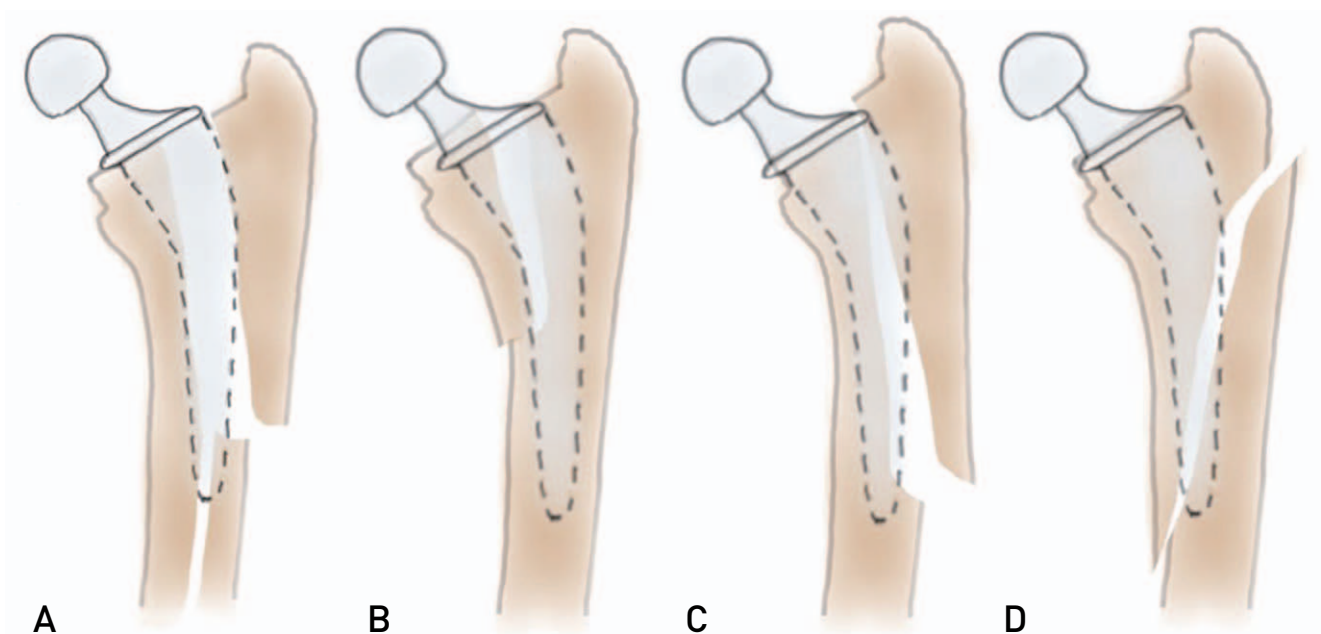


Fig. 1. Vancouver B2 classification was divided into four distinct fracture patterns: (A) comminuted burst, (B) clamshell, (C) reverse clamshell, and (D) spiral⁶.

paired fresh-frozen femurs were selected and stems were implanted for each type of stem. The upper limitation of maximum force was 10,000 N. For the cementless group, all ten fresh-frozen femurs were fractured before reaching 10,000 N, and the average threshold force applied was 2,626 N. On the other hand, for the cemented group, five out of ten fresh-frozen femurs were eventually fractured; five femurs sustained the maximum force of 10,000 N. The average threshold force applied for five fractured femurs was 9,127 N. In a comparison of fracture characteristics, dominance of Vancouver A was observed in the cementless group and dominance of Vancouver C was observed in the cemented group. Bone mineral density (BMD) score showed significant correlation in the cementless group, whereas no significant correlation was observed in the cemented group. A higher risk of PPFs was demonstrated for patients with lower BMD scores who were treated with cementless stem implants¹⁴⁾. A number of other previous studies reported that cementation of a femoral stem implant resulted in a decreased risk of PPF^{1,15)}.

DESIGN OF A CEMENTED STEM ON THE RISK OF PPF

Only a few articles have reported on the idea that the design of a cemented stem would influence the rate of risk for PPFs¹⁶⁾. A study on the effect of the choice of stem implant on the incidence of PPF revision rate was reported by Palan et al.¹⁷⁾. In an analysis of 257,202 cases of primary cemented THAs, the authors identified 390 cases of first revision surgeries due to PPF of primary THA using a cemented stem implant. Brands that were used in more than 10,000 cases were selected; (1) Exeter V40, (2) Charnley, (3) CPT, and (4) C-Stem. These brands accounted for approximately 80% of cemented THAs. For all revisions performed, 12% (390 cases) corresponded to PPF. The time interval distribution from primary THA

to revision operation differed brand by brand. The authors reported that the median time to revision for any reason was 1.9 years (interquartile range, 0.6 to 4.0) among all cemented stems and that for revision due to PPF was 2.1 years. The first 25% of revision surgeries due to PPFs for Exeter V40, C-Stem, and CPT occurred up to approximately six months; however, the interval time for Charnley occurred up to 2.1 years after the primary THA. The median time to revision for PPF is five years for the Charnley compared with 3.9, 2.3, and 1.8 for the C-Stem, CPT, and Exeter V40, respectively. The revision rate of PPF for CPT stem was exclusively higher compared with the three other common cemented stem implant brands (Exeter V40, C-Stem, and Charnley). Compared with the Exeter V40, the grade-adjusted revision rates for age, sex, and American Society of Anesthesiologists were 3.89 for cemented CPT stems, 0.89 for C-Stem, and 0.41 for Charnley stems¹⁷⁾.

According to a statistical report from Sweden, a relatively lower incidence of PPF was observed for the Lubinus stem compared with the Charnley and Exeter stems, and the authors suggested that the results were affected by differences in the shape and design of stems^{18,19)}. According to the authors, the Charnley and Exeter stems were shorter and straighter compared with the Lubinus stem, causing difficulty for surgeons in correctly positioning the stem and maintaining sustainable thickness of the cement mantle¹⁸⁾. Mohammed et al.²⁰⁾ reported a single institute study that included 1,077 patients who underwent cemented hip arthroplasty using either collarless, polished, tapered stem, or anatomical stem. According to the authors, the PPF rate was lowered from 3.3% in the PTS group (CPT stem) to 0.4% in the AS group (Lubinus stem)²⁰⁾. Currently, orthopedic surgeons have made frequent use of collarless, polished, tapered (CPT) over conventional composite beam stems; however, findings from recent studies indicate that the risk of periprosthetic femoral fracture is higher in CPT.

In a report by Thien et al.¹³⁾, according to the Nordic

Table 2. Review of Studies on the Rate of PPF in Cemented Stems Reported in the Literature within the Last 10 Years

Study	PPF of CPT types (%)	PPF of composite beam (%)
Mohammed et al. ²⁰⁾ (2019)	3.30	0.14
Scott et al. ²¹⁾ (2018)	2.20	0.24
Palan et al. ¹⁷⁾ (2016)	0.71	N/A
Mukka et al. ¹⁶⁾ (2016)	3.80	0.20
Broden et al. ²²⁾ (2015)	3.30	N/A
Thien et al. ¹³⁾ (2014)	0.14	0.03

PPF: periprosthetic fracture, CPT: collarless, polished, tapered, N/A: not available.

Arthroplasty Register Association database, which includes 437,629 THAs, the incidence of PPF was 0.14% at two years for the Exeter stem, while that for Lubinus SP II, the most proven composite beam stem, was 0.03%.

As reported by Scott et al.²¹⁾, CPT cemented stems for primary hip arthroplasty were more vulnerable to PPF at short-term follow-up. The study was conducted in order to evaluate the possible association between the design of cemented stem implants and risk of PPF. CPT stems are designed to subside into the cement mantle inside the femoral canal, resulting in transmission of hoop stresses to the cement mantle and surrounding bone structure. Because no mechanical or chemical bonding occurs between the polished surface of the stem and the cement mantle, application of a sudden incidence of axial loading results in an abrupt increase of hoop stresses, which are directly transmitted to the cement mantle, resulting in PPF of the femur²¹⁾. Results from the overall comparison of PPF incidence according to the various articles are organized in Table 2^{13,16,17,20-22)}.

In addition, five cases of atypical PPF in CPT cemented stems of THA were reported by Oe et al.²³⁾. According to the authors, taper-slip types of stems may cause PPF without a traumatic event. The SC-stem and C-stem were included in this study. The SC-stem, which has a curved triple-tapered design, is made from a cobalt-chromium alloy (CoCr), whereas the C-stem, which has a straight triple-tapered design, is made from a stainless-steel alloy. Treatment with the SC-stem was administered in nine cases of PPF and five cases were treated with the C-stem. Of the 3,349 cases of THAs, development of an atypical PPF occurred in five cases (0.1%): five of the 1,572 cases with the SC-stem (0.3%) and none of the 1,777 cases with the C-stem. None of the five patients complained of severe pain. Revision arthroplasties were performed and “split wood-like” fracture patterns were found intraoperatively²³⁾. A summary of incidences reported in the literature is shown in Table 2^{13,16,17,20-22)}.

MANAGEMENT ISSUES ON THE CEMENTED STEM

1. Type AG

First, the principle is nearly the same for the cemented stem. Nonoperative treatment such as limitation of weight bearing and limitation of abduction for a certain period of time (approximately six to 12 weeks) can be administered²⁴⁾. However, if the displacement is greater or a nonunion

occurs, open reduction and internal fixation using claw-plate implants is recommended²⁵⁾.

2. Type AL

For both cemented stem and cementless stem, type AL, an uncommon PPF pattern, is generally insignificant, even if the fragment is displaced. In general, nonoperative treatment is usually administered. However, the stability of the stem should be questioned when the fracture pattern has the calcar femorale extension. In a worst-case scenario, additional wires or revision by exchanging the stem with a longer type may be required²⁵⁾.

3. Type B1

Surgical fixation is usually required for fractures with displacement that emerges around a stable femoral prosthesis. There is still controversy regarding the ideal surgical method, including revision arthroplasty and internal fixation. Options for treatment of Vancouver B1 fractures may include plate fixation with or without cortical strut allografts, wires, and cables²⁶⁻²⁹⁾. Some surgeons argue that revision arthroplasty should be actively performed even for Vancouver B1 fractures³⁰⁾. In a case of periprosthetic cemented stem implant fracture with a well-fixed cement mantle, some authors described performing a cement-in-cement technique³¹⁻³³⁾. When it is determined that the cement mantle is well-fixed and defect-free, the fracture fragment is reduced anatomically and the smaller femoral stem is re-cemented into the existing cement mantle. The surgical process involves use of plates and strut allografts along with cerclage wires or cables. However, extrusion of cement between fracture fragments may interfere with fusion of the fracture. Of 23 Vancouver B fractures treated with cement-in-cement techniques mentioned above, the authors reported radiographic union of 18 fractures at a mean of 4.4 months³²⁾. According to the authors, use of this technique shortens operative time, is less technically demanding, and is ideal for geriatric patients who are not able to tolerate longer surgeries³²⁾.

Treatment of PPFs around firmly fixed and properly located implants with revision arthroplasty requires that the patient endure an operation with unnecessary relative risk. However, treatment of loosened stem implants solely with internal fixation can result in failure. The effectiveness of internal fixation with a locking plate has been demonstrated for treatment of PPFs around a stable implant^{26,34,35)}. Nevertheless, some authors insist that internal fixation with

a locking plate alone may result in fixation failure. Buttaro et al.²⁷⁾ reported failure of six cases in 14 cases of Vancouver B1 PPF with cemented stems. In all six cases failure was caused by breakage of the locking plate or loosening of screws. In particular, five out of six cases of failure occurred in patients who did not undergo cortical strut allograft augmentation in addition to locking plate fixation²⁷⁾.

4. Type B2

Some authors reviewed radiologic characteristics on plain radiographs in order to properly identify a loosened cemented femoral stem. The study was conducted on general radiographs of 21 patients who underwent revision hip arthroplasty from January 2002 to December 2011 due to loosening of a cemented femoral stem. In addition, 33 patients who underwent hip arthroplasty using cemented femoral stems without clinical suspicion of stem loosening between January 2004 and December 2007 were used as control subjects. According to the authors, the following factors were indicative of loosening of the cemented femoral stem: (1) An increase of the cement-bone interface more than 2 mm, (2) Subsidence, which is measured by the radiolucent line between the supero-lateral portion of stem and cement, more than 2 mm, (3) Inadequate cementation which is mainly measured by cement thickness less than 2 mm in any Gruen zone³⁶⁾.

A PPF of the femur around an unstable prosthesis with

adequate bone stock should be fixed with fracture reduction and revision arthroplasty using a longer cemented or cementless stem. Bypassing the most distal cortical defect by no less than two cortical diameters in order to obtain firm fixation of the implant is of paramount importance^{25,37,38)}.

Use of cemented femoral stems and cementless proximally porous-coated stems for treatment of Vancouver B fractures has previously been reported. However, these treatment methods are no longer preferred due to reports of poor outcome^{30,39)}. Mont and Maar⁴⁰⁾ reported a non-union rate of 31% in cemented femoral revision arthroplasties for Vancouver B2 fractures.

In addition Springer et al.³⁰⁾ performed revision arthroplasties on 42 cases of Vancouver B fracture using cemented stems. At a mean follow-up of 68 months, the stem was stable and union of the fracture was observed in 60% of cases. However, at an average follow-up of 85 months, the authors found evidence of radiographic loosening in 48% of stems that did not undergo revision arthroplasties. Only 36% of treated Vancouver B fractures had well-fixed stems without revision procedures. The authors acknowledged that the outcomes were generally poor, and explained the current use of cementless extensively porous-coated stems³⁰⁾.

5. Type B3

A retrospective study of 106 cases of Vancouver B2 and B3 fractures treated with revision arthroplasties with long

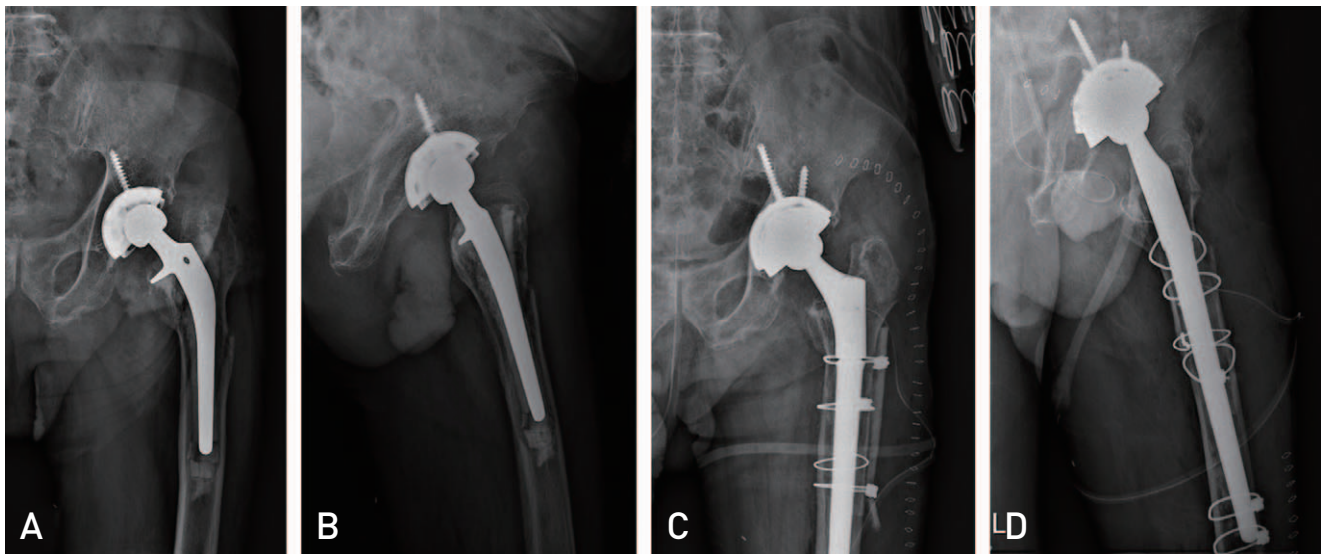


Fig. 2. (A, B) Simple radiographs of an 86-year-old male patient who underwent primary total hip arthroplasty 25 years ago due to thigh pain after a simple fall. Periprosthetic fracture of a cemented stem in addition to loosening with poor bone stock, and wear of acetabular cup polyethylene was detected. (C, D) Revision total hip arthroplasty was performed using a cementless long stem with wires, cables, and strut allograft strut bone with a cup change to a dual-mobility system.

or short stem and either with or without impaction bone grafting was reported by Tsiridis et al.⁴¹⁾. As reported by the authors, at an average follow-up of 7.44 months, the use of impaction bone grafting was four times more helpful in bone healing when a long stem cemented stem implant was used. The authors also emphasized the use of a longer stem implant, because the length bypassing the distal cortical defects should be at least two cortical diameters in order to achieve a greater possibility of fracture union. Compared to a shorter stem, the OR for fracture union was 5.5.

In a study analyzing 35 cases involving patients who underwent revision THA surgeries, Masterson et al.⁴²⁾ identified seven patients with femoral stem implant subsidence of 10 mm or greater within the first six months after hip revision

using an impaction bone graft. Radiographic signs of cement mantle fractures and fragments were observed on plain radiographs of four of seven patients with stem subsidence. The authors reported that improvements in surgical technique and advances in instruments could result in increased consistency of cement mantles around prostheses, ultimately resulting in a slow decrease of the possibility of stem subsidence. However, it is important to note that this study did not include any cases involving revision surgery for PPFs⁴²⁾.

With similar results, Eldridge et al.⁴³⁾ reported subsidence of early components within three months of surgery greater than 10 mm in nine of 79 cases (11%) using impacted femoral stem grafting with cemented femoral stem in revision hip arthroplasty. Of particular interest, the stem implant

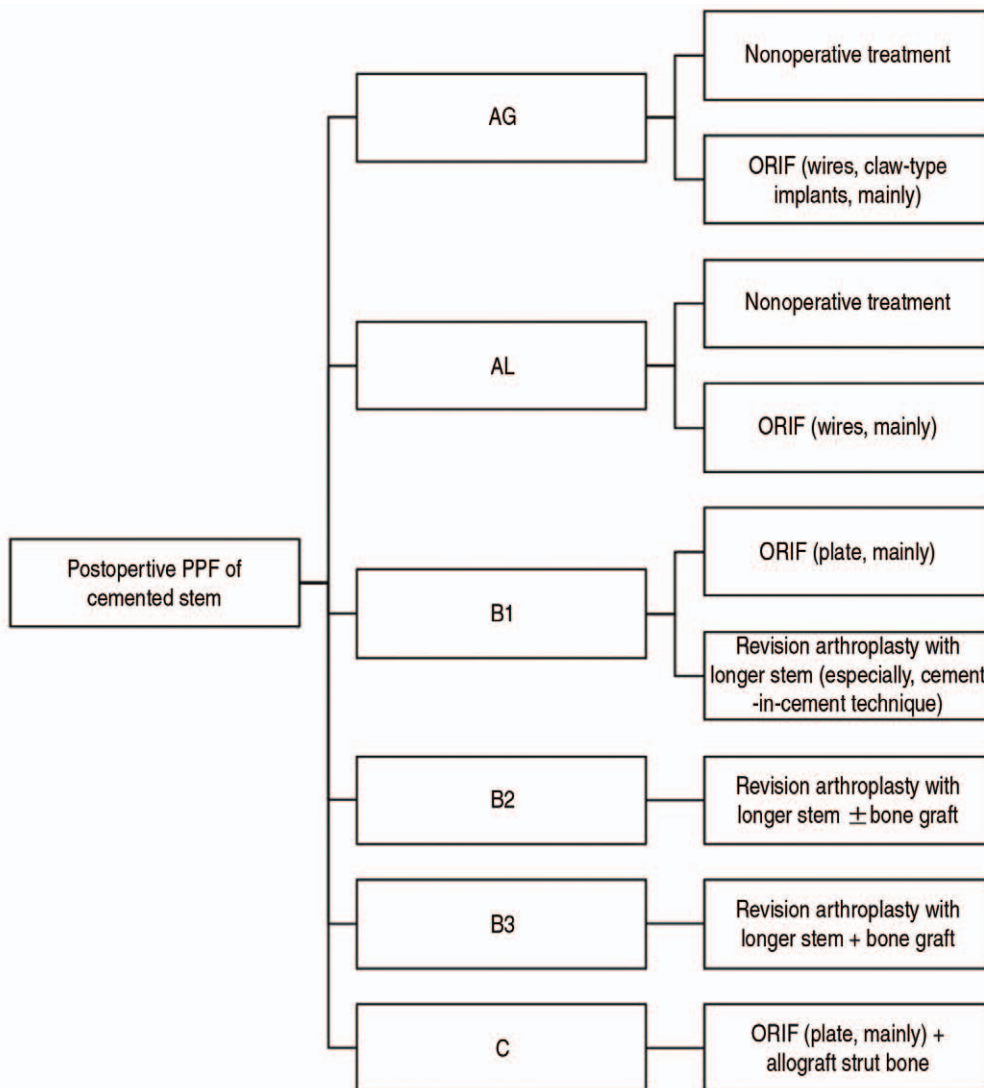


Fig. 3. Management algorithm for postoperative periprosthetic fracture (PPF) of cemented stems. ORIF: open reduction and internal fixation.

was inserted in a varus alignment in seven of nine patients. Impaction bone grafting for femoral defects is a technically demanding procedure and mixed results for use of this technique in revision hip surgery have been reported in the literature. The reason appears to be multifactorial: (1) patient factor, (2) surgeon factor, (3) surgical technical difference, and (4) stem implant difference⁴³. Currently, use of an additional extramedullary internal fixation system along with an intramedullary fixation system supplied by impaction bone grafting is recommended by most authors since at least one year is required for incorporation and remodeling⁴⁴.

The results of using a cortical strut allograft for Vancouver B2 and B3 fractures in order to achieve stability were described and summarized by Pavone et al.⁴⁵. According to the authors, additional fixation with extramedullary cortical strut grafts is an effective measure for enhancing stability and promoting bone healing in fractures with inadequate bone stock⁴⁵. An example of an elderly patient with a PPF who underwent revision surgery with a longer stem and additional cortical strut allograft is shown in Fig. 2.

6. Type C

Vancouver C fractures account for approximately 10% of all PPFs¹⁹. Fractures occurring distal to the stem at the metaphysis or metaphysis can be treated independently from the stem according to the basic principles of the fracture fixation protocol of AO^{25,38}. In cases involving elderly patients, the immobilization period should be prolonged and the possibility of various medical complications increases with application of non-surgical treatment, therefore surgical intervention is often preferred. Options for surgical treatment may include use of a conventional locked plating technique with or without cortical support allograft augmentation. Intramedullary fixation or cortical strut allograft bones alone may be used in treatment of Vancouver C fractures²⁸. In cases where locking plate internal fixation is used, auxiliary cables and/or circle large wires can be added in setups where unicortical screws are not properly secured around the stem. In order to reduce the possibility of refracture, avoiding factors that can cause escalated concentration of stress between the stem and fixation device as well as between the most distal aspect of the plate and remaining host bone is critical. A description of the summarized algorithm for management of cemented stem PPFs is shown in Fig. 3.

CONCLUSION

The risk of PPF is lower for cemented femoral stems compared with that for cementless stems. However, compared with the cementless stem, there are some differences in fracture type and treatment policy. Non-surgical treatment can usually be administered for fractures around cement stem implants for type AG and type AL. For Type B1, although open reduction and internal fixation is generally considered, use of a cement-in-cement technique may be considered for fractures of a cement stem implant around a prosthesis with a well-fixed cement mantle, which usually requires internal fixation. For type B2 fractures, reduction and revision surgery are usually performed with use of a longer cemented or cementless stem. The helpfulness of impaction bone grafts for type B3 fractures has been demonstrated. For type C fractures, internal fixation is used according to the AO protocol. Overall, even if cementless stems become the mainstream, clinicians should also pay attention to the PPF of cemented stems because they are used in some cases.

CONFLICT OF INTEREST

The authors declare that there is no potential conflict of interest relevant to this article.

REFERENCES

1. Abdel MP, Watts CD, Houdek MT, Lewallen DG, Berry DJ. *Epidemiology of periprosthetic fracture of the femur in 32 644 primary total hip arthroplasties: a 40-year experience. Bone Joint J. 2016;98-B:461-7. Erratum in: Bone Joint J. 2020;102-B:1782. <https://doi.org/10.1302/0301-620X.98B4.37201>*
2. Malchau H, Herberts P, Eisler T, Garellick G, Söderman P. *The Swedish total hip replacement register. J Bone Joint Surg Am. 2002;84-A Suppl 2:2-20. Erratum in: J Bone Joint Surg Am. 2004;86-A:363. <https://doi.org/10.2106/00004623-200200002-00002>*
3. Duncan CP, Masri BA. *Fractures of the femur after hip replacement. Instr Course Lect. 1995;44:293-304.*
4. Naqvi GA, Baig SA, Awan N. *Interobserver and intraobserver reliability and validity of the Vancouver classification system of periprosthetic femoral fractures after hip arthroplasty. J Arthroplasty. 2012;27:1047-50. <https://doi.org/10.1016/j.arth.2011.11.021>*
5. Rayan F, Dodd M, Haddad FS. *European validation of the Vancouver classification of periprosthetic proximal femoral fractures. J Bone Joint Surg Br. 2008;90:1576-9. <https://doi.org/10.1302/0301-620X.90B12.20681>*
6. Karam J, Campbell P, Desai S, Hunter M. *Periprosthetic proximal femoral fractures in cemented and uncemented stems according to Vancouver classification: observation of a new fracture pattern. J Orthop Surg Res. 2020;15:100.*

- <https://doi.org/10.1186/s13018-020-01619-4>
7. Phillips JR, Moran CG, Manktelow AR. *Periprosthetic fractures around hip hemiarthroplasty performed for hip fracture. Injury.* 2013;44:757-62. <https://doi.org/10.1016/j.injury.2012.09.015>
 8. Capello WN, D'Antonio JA, Naughton M. *Periprosthetic fractures around a cementless hydroxyapatite-coated implant: a new fracture pattern is described. Clin Orthop Relat Res.* 2014; 472:604-10. <https://doi.org/10.1007/s11999-013-3137-x>
 9. Grammatopoulos G, Pandit H, Kambouroglou G, et al. *A unique peri-prosthetic fracture pattern in well fixed femoral stems with polished, tapered, collarless design of total hip replacement. Injury.* 2011;42:1271-6. <https://doi.org/10.1016/j.injury.2011.01.008>
 10. Jain S, Lamb J, Townsend O, et al. *Risk factors influencing fracture characteristics in postoperative periprosthetic femoral fractures around cemented stems in total hip arthroplasty: a multicentre observational cohort study on 584 fractures. Bone Jt Open.* 2021;2:466-75. <https://doi.org/10.1302/2633-1462.27.BJO-2021-0027.R1>
 11. Wu ES, Cherian JJ, Kapadia BH, Banerjee S, Jauregui JJ, Mont MA. *Outcomes of post-operative periprosthetic femur fracture around total hip arthroplasty: a review. Expert Rev Med Devices.* 2015;12:61-72. <https://doi.org/10.1586/17434440.2015.958076>
 12. Sponer P, Korb M, Grinac M, Prokes L, Bezrouk A, Kucera T. *The outcomes of cemented femoral revisions for periprosthetic femoral fractures in the elderly: comparison with cementless stems. Clin Interv Aging.* 2021;16:1869-76. <https://doi.org/10.2147/CIA.S306463>
 13. Thien TM, Chatziagorou G, Garellick G, et al. *Periprosthetic femoral fracture within two years after total hip replacement: analysis of 437,629 operations in the nordic arthroplasty register association database. J Bone Joint Surg Am.* 2014;96:e167. <https://doi.org/10.2106/JBJS.M.00643>
 14. Thomsen MN, Jakubowitz E, Seeger JB, Lee C, Kretzer JP, Clarius M. *Fracture load for periprosthetic femoral fractures in cemented versus uncemented hip stems: an experimental in vitro study. Orthopedics.* 2008;31:653. <https://doi.org/10.3928/01477447-20110505-12>
 15. Della Valle AG, Zoppi A, Peterson MG, Salvati EA. *A rough surface finish adversely affects the survivorship of a cemented femoral stem. Clin Orthop Relat Res.* 2005;(436):158-63. <https://doi.org/10.1097/00003086-200507000-00024>
 16. Mukka S, Mellner C, Knutsson B, Sayed-Noor A, Sköldenberg O. *Substantially higher prevalence of postoperative periprosthetic fractures in octogenarians with hip fractures operated with a cemented, polished tapered stem rather than an anatomic stem. Acta Orthop.* 2016;87:257-61. <https://doi.org/10.3109/17453674.2016.1162898>
 17. Palan J, Smith MC, Gregg P, et al. *The influence of cemented femoral stem choice on the incidence of revision for periprosthetic fracture after primary total hip arthroplasty: an analysis of national joint registry data. Bone Joint J.* 2016;98-B:1347-54. <https://doi.org/10.1302/0301-620X.98B10.36534>
 18. Franklin J, Malchau H. *Risk factors for periprosthetic femoral fracture. Injury.* 2007;38:655-60. <https://doi.org/10.1016/j.injury.2007.02.049>
 19. Lindahl H, Malchau H, Herberts P, Garellick G. *Periprosthetic femoral fractures classification and demographics of 1049 periprosthetic femoral fractures from the Swedish National Hip Arthroplasty Register. J Arthroplasty.* 2005;20:857-65. <https://doi.org/10.1016/j.arth.2005.02.001>
 20. Mohammed J, Mukka S, Hedbeck CJ, Chammout G, Gordon M, Sköldenberg O. *Reduced periprosthetic fracture rate when changing from a tapered polished stem to an anatomical stem for cemented hip arthroplasty: an observational prospective cohort study with a follow-up of 2 years. Acta Orthop.* 2019;90:427-32. <https://doi.org/10.1080/17453674.2019.1624339>
 21. Scott T, Salvatore A, Woo P, Lee YY, Salvati EA, Gonzalez Della Valle A. *Polished, collarless, tapered, cemented stems for primary hip arthroplasty may exhibit high rate of periprosthetic fracture at short-term follow-up. J Arthroplasty.* 2018; 33:1120-25. <https://doi.org/10.1016/j.arth.2017.11.003>
 22. Broden C, Mukka S, Muren O, et al. *High risk of early periprosthetic fractures after primary hip arthroplasty in elderly patients using a cemented, tapered, polished stem. Acta Orthop.* 2015;86:169-74. <https://doi.org/10.3109/17453674.2014.971388>
 23. Oe K, Iida H, Hirata M, et al. *An atypical periprosthetic fracture in collarless, polished, tapered, cemented stems of total hip arthroplasty: a report of five SC-stem cases and literature review. J Orthop Sci. Published online May 24, 2021; https://doi.org/10.1016/j.jos.2021.04.003*
 24. Pritchett JW. *Fracture of the greater trochanter after hip replacement. Clin Orthop Relat Res.* 2001;(390):221-6. <https://doi.org/10.1097/00003086-200109000-00025>
 25. Callaghan JJ, Rosenberg AG, Rubash HE. *The adult hip. 2nd ed. Philadelphia: Lippincott Williams & Wilkins; 2007.*
 26. Bryant GK, Morshed S, Agel J, et al. *Isolated locked compression plating for Vancouver Type B1 periprosthetic femoral fractures. Injury.* 2009;40:1180-6.
 27. Buttaro MA, Farfalli G, Paredes Núñez M, Comba F, Piccaluga F. *Locking compression plate fixation of Vancouver type-B1 periprosthetic femoral fractures. J Bone Joint Surg Am.* 2007; 89:1964-9. <https://doi.org/10.2106/JBJS.F.01224>
 28. Haddad FS, Duncan CP. *Cortical onlay allograft struts in the treatment of periprosthetic femoral fractures. Instr Course Lect.* 2003;52:291-300.
 29. Laurer HL, Wutzler S, Possner S, et al. *Outcome after operative treatment of Vancouver type B1 and C periprosthetic femoral fractures: open reduction and internal fixation versus revision arthroplasty. Arch Orthop Trauma Surg.* 2011; 131:983-9. <https://doi.org/10.1007/s00402-011-1272-y>
 30. Springer BD, Berry DJ, Lewallen DG. *Treatment of periprosthetic femoral fractures following total hip arthroplasty with femoral component revision. J Bone Joint Surg Am.* 2003;85: 2156-62. <https://doi.org/10.2106/00004623-200311000-00015>
 31. Brew CJ, Wilson LJ, Whitehouse SL, Hubble MJ, Crawford RW. *Cement-in-cement revision for selected Vancouver Type B1 femoral periprosthetic fractures: a biomechanical analysis. J Arthroplasty.* 2013;28:521-5. <https://doi.org/10.1016/j.arth.2012.08.016>
 32. Briant-Evans TW, Veeramootoo D, Tsiridis E, Hubble MJ. *Cement-in-cement stem revision for Vancouver type B periprosthetic femoral fractures after total hip arthroplasty. A 3-year follow-up of 23 cases. Acta Orthop.* 2009;80:548-52. <https://doi.org/10.3109/17453670903316827>
 33. Richards CJ, Duncan CP, Crawford RW. *Cement-in-cement femoral revision for the treatment of highly selected vancou-*

- ver B2 periprosthetic fractures. *J Arthroplasty*. 2011;26:335-7. <https://doi.org/10.1016/j.arth.2010.03.014>
34. Chakravarthy J, Bansal R, Cooper J. Locking plate osteosynthesis for Vancouver Type B1 and Type C periprosthetic fractures of femur: a report on 12 patients. *Injury*. 2007;38:725-33. <https://doi.org/10.1016/j.injury.2007.02.038>
35. Graham SM, Moazen M, Leonidou A, Tsiridis E. Locking plate fixation for Vancouver B1 periprosthetic femoral fractures: a critical analysis of 135 cases. *J Orthop Sci*. 2013;18:426-36. <https://doi.org/10.1007/s00776-013-0359-4>
36. Wong WY, Chan WCS, Chu PY, Ng KW, Hui PK, Yuen MK. Cemented femoral stem loosening of hip arthroplasty: ten-year radiographic analysis. *Hong Kong J Radiol*. 2013;16:41-9. <https://doi.org/10.12809/hkjr1312155>
37. Larson JE, Chao EY, Fitzgerald RH. Bypassing femoral cortical defects with cemented intramedullary stems. *J Orthop Res*. 1991;9:414-21. <https://doi.org/10.1002/jor.1100090314>
38. Pike J, Davidson D, Garbuz D, Duncan CP, O'Brien PJ, Masri BA. Principles of treatment for periprosthetic femoral shaft fractures around well-fixed total hip arthroplasty. *J Am Acad Orthop Surg*. 2009;17:677-88. <https://doi.org/10.5435/00124635-200911000-00002>
39. Beals RK, Tower SS. Periprosthetic fractures of the femur. An analysis of 93 fractures. *Clin Orthop Relat Res*. 1996;(327):238-46. <https://doi.org/10.1097/00003086-199606000-00029>
40. Mont MA, Maar DC. Fractures of the ipsilateral femur after hip arthroplasty. A statistical analysis of outcome based on 487 patients. *J Arthroplasty*. 1994;9:511-9. [https://doi.org/10.1016/0883-5403\(94\)90098-1](https://doi.org/10.1016/0883-5403(94)90098-1)
41. Tsiridis E, Narvani AA, Haddad FS, Timperley JA, Gie GA. Impaction femoral allografting and cemented revision for periprosthetic femoral fractures. *J Bone Joint Surg Br*. 2004;86:1124-32. <https://doi.org/10.1302/0301-620x.86b8.14854>
42. Masterson EL, Masri BA, Duncan CP. The cement mantle in the Exeter impaction allografting technique. A cause for concern. *J Arthroplasty*. 1997;12:759-64. [https://doi.org/10.1016/s0883-5403\(97\)90005-x](https://doi.org/10.1016/s0883-5403(97)90005-x)
43. Eldridge JD, Smith EJ, Hubble MJ, Whitehouse SL, Learmonth ID. Massive early subsidence following femoral impaction grafting. *J Arthroplasty*. 1997;12:535-40. [https://doi.org/10.1016/s0883-5403\(97\)90176-5](https://doi.org/10.1016/s0883-5403(97)90176-5)
44. Callaghan JJ, Heiner AD, Brown TD. The basic science of impaction allografting in revision hip surgery. *Instr Course Lect*. 2000;49:103-10.
45. Pavone V, de Cristo C, Di Stefano A, Costarella L, Testa G, Sessa G. Periprosthetic femoral fractures after total hip arthroplasty: an algorithm of treatment. *Injury*. 2019;50 Suppl 2:S45-51. <https://doi.org/10.1016/j.injury.2019.01.044>